

Coronal Primary Caries Codes

Pits and fissures

Sound tooth surface: Code 0

There should be no evidence of caries (either no or questionable change in enamel translucency after prolonged air drying (suggested drying time 5 seconds)). Surfaces with developmental defects such as enamel hypoplasias; fluorosis; tooth wear (attrition, abrasion and erosion), and extrinsic or intrinsic stains will be recorded as **sound**. The examiner should also score as sound a surface with multiple stained fissures if such a condition is seen in other pits and fissures, a condition which is consistent with non-carious habits (e.g. frequent tea drinking). Table 1 provides a useful guide for differential diagnosis for carious opacities versus other opacities.

First visual change in enamel: Code 1

Code 1 is assigned for the following pits and fissures:

When seen wet there is no evidence of any change in color attributable to carious activity, but after prolonged air drying (approximately 5 seconds is suggested to adequately dehydrate a carious lesion in enamel) a carious opacity or discoloration (white or brown lesion) is visible that is not consistent with the clinical appearance of sound enamel

OR

When there is a change of color due to caries which is not consistent with the clinical appearance of sound enamel and is limited to the confines of the pit and fissure area (whether seen wet or dry). The appearance of these carious areas is not consistent with that of stained pits and fissures as defined in code 0.

Distinct visual change in enamel: Code 2

The tooth must be viewed wet. When wet there is a (a) carious opacity (white spot lesion) and/or (b) brown carious discoloration which is wider than the natural fissure/fossa that is not consistent with the clinical appearance of sound enamel (Note: the lesion must still be visible when dry).

Localized enamel breakdown due to caries with no visible dentin or underlying shadow: Code 3

The tooth viewed wet may have a clear **carious opacity (white spot lesion) and/or brown carious discoloration which is wider than the natural fissure/fossa that is not consistent with the clinical appearance of sound enamel**. Once dried for approximately 5 seconds there is carious loss of tooth structure at the entrance to, or within, the pit or fissure/fossa. This will be seen visually as evidence of demineralization (opaque (white), brown or dark brown walls) at the entrance to or within the fissure or pit, and although the pit or fissure may appear substantially and unnaturally wider than normal. The base and walls of the cavity are within enamel and dentin is NOT visible.

If in doubt, or to confirm the visual assessment, the WHO/CPI/PSR probe can be used **gently across a tooth surface** to confirm the presence of a cavity apparently confined to the enamel.

This is achieved by sliding the ball end along the suspect pit or fissure and a limited discontinuity is detected if the ball drops into the surface of the enamel cavity/discontinuity.

Underlying dark shadow from dentin with or without localized enamel breakdown: Code 4

This lesion appears as a shadow of discolored dentin visible through an apparently intact enamel surface which may or may not show signs of localized breakdown (loss of continuity of the surface that is not showing the dentin). The shadow appearance is often seen more easily when the tooth is wet. The darkened area is an intrinsic shadow which may appear as grey, blue or brown in color. The shadow must clearly represent caries within a tooth surface area from a clinical view that is perpendicular to that surface.

Code 3 and 4, histologically may vary in depth with one being deeper than the other and vice versa. This will depend on the population and properties of the enamel. For example more translucent and thinner enamel in primary teeth may allow the undermining discoloration of the dentin to be seen before localized breakdown of enamel. However, in most cases code 4 is likely to be deeper into dentin than code 3.

Distinct cavity with visible dentin: Code 5

Cavitation in opaque or discolored enamel exposing the dentin beneath involving less than half of the tooth surface.

The tooth viewed wet may have darkening of the dentin visible through the enamel. Once dried for 5 seconds there is visual evidence of loss of tooth structure at the entrance to or within the pit or fissure – frank cavitation. There is visual evidence of demineralization (opaque (white), brown or dark brown walls) at the entrance to or within the pit or fissure and dentin is exposed.

The WHO/CPI/PSR probe can be used to confirm the presence of a cavity in dentin. This is achieved by sliding the ball end along the suspect pit or fissure and a dentin cavity is detected if the ball enters the opening of the cavity and the base is in dentin. (In pits or fissures the thickness of the enamel is between 0.5 and 1.0 mm. Note the deep pulpal dentin should not be probed).

Extensive distinct cavity with visible dentin: Code 6

Cavitation in opaque or discolored enamel exposing the dentin beneath involving at least half of the tooth surface.

Obvious loss of tooth structure and dentin is clearly visible on the walls and at the base in a cavity that involves at least half of the tooth surface.

Smooth surface (mesial and distal)

This requires visual inspection from the occlusal, buccal and lingual directions.

Sound tooth surface: Code 0

There should be no evidence of caries (either no or questionable change in enamel translucency after prolonged air drying (suggested drying time 5 seconds)). Surfaces with developmental

defects such as enamel hypoplasias; fluorosis; tooth wear (attrition, abrasion and erosion), and extrinsic or intrinsic stains will be recorded as **sound**.

First visual change in enamel: Code 1

When seen wet there is no evidence of any change in color attributable to carious activity, but after prolonged air drying a carious opacity (white or brown lesion) is visible that is not consistent with the clinical appearance of sound enamel. This will be seen from the buccal or lingual surface.

Distinct visual change in enamel when viewed wet: Code 2

There is a carious opacity or discoloration (white or brown lesion) that is not consistent with the clinical appearance of sound enamel (Note: the lesion is still visible when dry). This lesion may be seen directly when viewed from the buccal or lingual direction. In addition, when viewed from the occlusal direction, this opacity or discoloration may be seen as a shadow confined to enamel, seen through the marginal ridge.

Initial breakdown in enamel due to caries with no visible dentin: Code 3

Once dried for approximately 5 seconds there is distinct loss of enamel integrity, viewed from the buccal or lingual direction. The base and walls of the cavity are within enamel and dentin is NOT visible.

If in doubt, or to confirm the visual assessment, the CPI probe can be used gently across the surface to confirm the loss of surface integrity.

Underlying dark shadow from dentin with or without localized enamel breakdown: Code 4

This lesion appears as a shadow of discolored dentin visible through an apparently intact marginal ridge, buccal or lingual walls of enamel. This appearance is often seen more easily when the tooth is wet. The darkened area is an intrinsic shadow which may appear as grey, blue or brown in color.

Distinct cavity with visible dentin: Code 5.

Cavitation in opaque or discolored enamel exposing the dentin beneath involving less than half of the tooth surface.

The WHO/CPI/PSR probe can be used to confirm the presence of a cavity in dentin. This is achieved by sliding the ball end along the surface and a dentin cavity is detected if the ball enters the opening of the cavity.

Extensive distinct cavity with visible dentin: Code 6

Cavitation in opaque or discolored enamel exposing the dentin beneath involving at least half of the tooth surface. Obvious loss of tooth structure, and dentin is **clearly visible** on the walls and at the base in a cavity that involves at least half of a tooth surface. The marginal ridge may or may not be present.

Free Smooth surface (buccal and lingual and direct examination of mesial and distal surfaces (with no adjacent teeth))

Sound tooth surface: Code 0

There should be no evidence of caries (either no or questionable change in enamel translucency after prolonged air drying (approximately 5 seconds)). Surfaces with developmental defects such as enamel hypoplasias; fluorosis; tooth wear (attrition, abrasion and erosion), and extrinsic or intrinsic stains will be recorded as sound.

First visual change in enamel: Code 1

When seen wet there is no evidence of any change in color attributable to carious activity, but after prolonged air drying a carious opacity is visible that is not consistent with the clinical appearance of sound enamel

Distinct visual change in enamel when viewed wet: Code 2

There is a carious opacity or discoloration that is not consistent with the clinical appearance of sound enamel (Note: the lesion is still visible when dry). The lesion is located in close proximity (in touch or within 1 mm) of the gingival margin **or adjacent to orthodontic or prosthetic attachments on a tooth surface.**

Localized enamel breakdown due to caries with no visible dentin: Code 3

Once dried for approximately 5 seconds there is distinct loss of enamel surface integrity. The base and walls of the cavity are within enamel and dentin is NOT visible.

If in doubt, or to confirm the visual assessment, the WHO/CPI/PSR probe can be used with NO digital pressure to confirm the loss of surface integrity.

Underlying dark shadow from dentin with or without localized enamel breakdown: Code 4

This lesion appears as a shadow of discolored dentin visible through the enamel surface beyond the white or brown spot lesion, which may or may not show signs of localized breakdown. This appearance is often seen more easily when the tooth is wet and is a darkening and intrinsic shadow which may be grey, blue or brown in color.

Distinct cavity with visible dentin: Code 5

Cavitation in opaque or discolored enamel exposing the dentin beneath involving less than half of the tooth surface.

The WHO/CPI/PSR probe can be used to confirm the presence of a cavity in dentin. This is achieved by sliding the ball end along the surface and a dentin cavity is detected if the ball enters the opening of the cavity.

Extensive distinct cavity with visible dentin: Code 6

Cavitation in opaque or discolored enamel exposing the dentin beneath involving at least half of the tooth surface.

Obvious loss of tooth structure, and dentin is **clearly visible** on the walls and at the base in a cavity that involves at least half of a tooth surface. The marginal ridge may or may not be present.

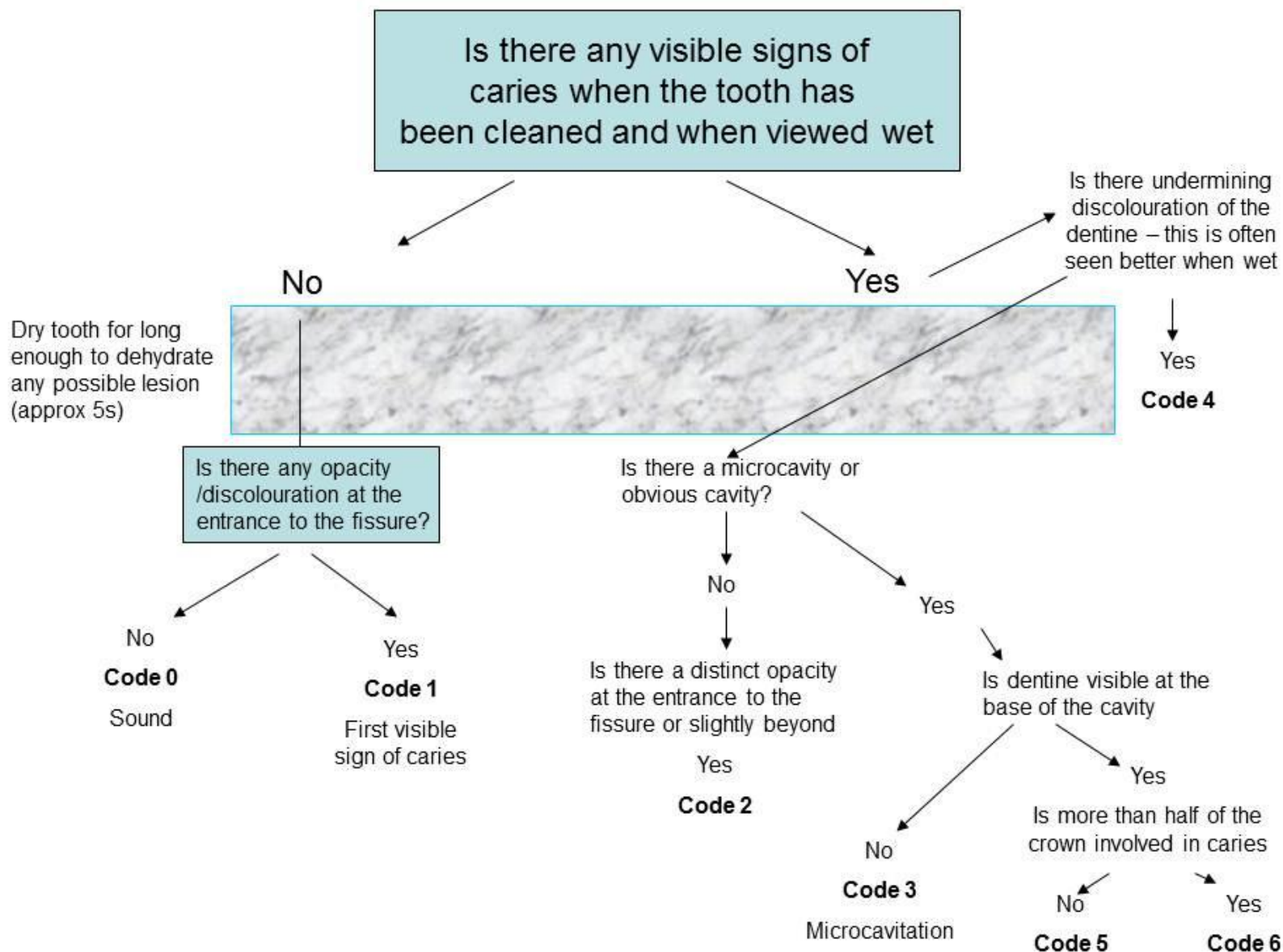
Figure 1 depicts a simple decision tree for applying the 7-code for classifying coronal tooth surfaces following the ICDAS criteria.

Table 1. Differential Diagnosis between Milder Forms of Dental Fluorosis (Questionable, Very Mild, And Mild) and Nonfluoride Opacities of Enamel.

Characteristic	Milder Forms of Fluorosis	Nonfluoride Enamel Opacities
Area affected	Usually seen on or near tips of cusps or incisal edges.	Usually centred in smooth surface; may affect entire crown.
Shape of lesion	Resembles line shading in pencil sketch; lines follow incremental lines in enamel, form irregular caps on cusps.	Often round or oval.
Demarcation	Shades off imperceptibly into surrounding normal enamel.	Clearly differentiated from adjacent normal enamel.
Color	Slightly more opaque than normal enamel; paper-white. Incisal edges, tips of cusps may have frosted appearance. Does not show stain at time of eruption (in these milder degrees, rarely at any time).	Usually pigmented at time of eruption often creamy-yellow to dark reddish-orange.
Teeth Affected	Most frequent on teeth that calcify slowly (cuspids, bicuspid, second and third molars). Rare on lower incisors. Usually seen on six or eight homologous teeth. Extremely rare in deciduous teeth.	Any tooth may be affected. Frequent on labial surfaces of lower incisors. May occur singly. Usually one to three teeth affected. Common in deciduous teeth.
Gross hypoplasia	None. Pitting of enamel does not occur in the milder forms. Enamel surface has glazed appearance, is smooth to point of explorer.	Absent to severe. Enamel surface may seem etched, be rough to explorer.
Detection	Often invisible under strong light; most easily detected by line of sight tangential to tooth crown.	Seen most easily under strong light on line of sight perpendicular to tooth surface.

Russell AL. The differential diagnosis of fluoride and non-fluoride enamel opacities. *J Public Health Dent* 1961;21:143-6.

Figure 1. DECISION TREE FOR PRIMARY CORONAL CARIES DETECTION



Caries-Associated with Restorations and Sealants (CARS) Detection Criteria

Caries Associated with Restorations and Sealants Codes

Sound tooth surface with restoration or sealant: Code 0

A sound tooth surface adjacent to a restoration/sealant margin. There should be no evidence of caries (either no or questionable change in enamel translucency after prolonged air drying for 5 seconds). Surfaces with marginal defects less than 0.5mm in width (i.e. will not admit the ball end of the CPI Probe), developmental defects such as enamel hypoplasias; fluorosis; tooth wear (attrition, abrasion and erosion), and extrinsic or intrinsic stains will be recorded as sound. Stained margins consistent with non-cariious habits (e.g. frequent tea drinking) and which do not exhibit signs consistent with demineralization should be scored as sound

First visual change in enamel: Code 1

When seen wet there is no evidence of any change in color attributable to carious activity, but after prolonged air drying (for approximately 5 seconds) an opacity or discoloration consistent with demineralisation is visible that is not consistent with the clinical appearance of sound enamel.

Distinct visual change in enamel/dentin adjacent to a restoration/sealant margin: Code 2

- **If the restoration margin is placed on enamel** the tooth must be viewed wet. When wet there is an opacity consistent with demineralisation or discoloration that is not consistent with the clinical appearance of sound enamel (Note: the lesion is still visible when dry).
- **If the restoration margin is placed on dentin: Code 2** applies to discoloration that is not consistent with the clinical appearance of sound dentin or cementum.

Cariious defects of <0.5 mm with the signs of code 2: Code 3

Cavitation at the margin of the restoration/sealant less than 0.5mm, in addition to either an opacity or discoloration consistent with demineralisation that is not consistent with the clinical appearance of sound enamel or with a shadow of discolored dentin.

Marginal caries in enamel/dentin /cementum adjacent to restoration/sealant with underlying dark shadow from dentin: Code 4

The tooth surface may have characteristics of code 2 and has a shadow of discolored dentin which is visible through an apparently intact enamel surface or with localized breakdown in enamel but no visible dentin. This appearance is often seen more easily when the tooth is wet and is a darkening and intrinsic shadow which may be grey, blue, orange, or brown in color. Note: view tooth wet and then dry. This lesion should be distinguished from amalgam shadows.

Distinct cavity adjacent to restoration/sealant: Code 5

Distinct cavity adjacent to restoration/sealant with visible dentin in the interfacial space with signs of caries as described in code 4, in addition to a gap > 0.5mm in width.
OR

In those instances where margins are not visible, there is evidence of discontinuity at the margin of the restoration/sealant and tooth substance of the dentin as detected by 0.5mm ball-ended probe run along the restoration/sealant margin.

Extensive distinct cavity with visible dentin: Code 6

Obvious loss of tooth structure, the extensive cavity may be deep or wide and dentin is **clearly visible** on both the walls and at the base.

ICDAS two-digit coding method

A two-number coding system is suggested to identify restorations/sealants with the first digit, followed by the appropriate caries code, for example a tooth restored with amalgam which also exhibited an extensive distinct cavity with visible dentin would be coded 4 (for an amalgam restoration) 6 (distinct cavity), an unrestored tooth with a distinct cavity would be 06. The suggested restoration/sealant coding system is as follows:

0 = Sound: i.e. surface not restored or sealed (use with the codes for primary caries)

1 = Sealant, partial

2 = Sealant, full

3 = Tooth colored restoration

4 = Amalgam restoration

5 = Stainless steel crown

6 = Porcelain or gold or PFM (porcelain fused to metal crown) crown or veneer or inlay or onlay or other restorative material

7 = Lost or broken restoration

8 = Temporary restoration

9 = Used for the following conditions

90 = Implant for other non-carious related reasons

91 = Implant placed due to caries

92 = Pontic placed for reasons other than caries

93 = Pontic placed for carious reasons

96 = Tooth surface cannot be examined: surface excluded

97 = Tooth missing because of caries (tooth surfaces will be coded 97)

98 = Tooth missing for reasons other than caries (all tooth surfaces will be coded 98)

99 = Unerupted (tooth surfaces coded 99)

Further considerations (Guidelines of ICDAS in Epidemiology and Clinical Research setting)

In case of doubt the examiner should score low.

Non-vital teeth should be scored in the same manner as vital teeth.

Banded or bracketed teeth. All visible surfaces should be examined as well as possible and scored in the usual manner. When a surface is completely covered by a band or bracket and there is no evidence of caries the tooth status code is “0”.

In the case of supernumerary teeth, the examiner should decide which tooth is the legitimate occupant of the space. Only that tooth should be scored.

When both a primary and permanent tooth occupy the same space, only the permanent tooth is coded.

Where more than one carious lesion exists on a surface, the worst lesion should be scored, though scoring pits and fissures separately to free smooth surfaces is an option.

Whenever both the coronal and root surface are affected by a single carious lesion that extends at least 1 mm or more past the CEJ in both cervical-incisal and cervical-apical directions, both surfaces should be scored separately. For a lesion affecting both crown and root surfaces with extension from the CEJ of less than 1 mm, only that surface of tooth with the greater portion (more than 50%) of the lesion involvement should be scored. When it is impossible to invoke the 50% rule (i.e., when both coronal and root surfaces appear equally affected), both surfaces should be scored as carious.

All tooth surfaces of retained roots should be scored as (06).

If part of a restoration is lost on a surface, the surface should be coded as “7” (first number), even when not all the restoration is missing.

It is important that there is a code to record the instances where there are non-carious cavities, i.e. where a restoration has been lost. It could be argued that such cases are analogous with temporary restorations although it is the convention in some epidemiological studies to record these in a way that means that they are recorded within the “filled” rather than “decayed” element of the study findings.

A root surface adjacent to a crown margin that is free of decay should be scored sound.

If more than one lesion is present on the same root surface, the most severe lesion is scored.

Root Caries Criteria

Codes for the detection and classification of carious lesions on the root surfaces

One score will be assigned per root surface. The facial, mesial, distal and lingual root surfaces of each tooth should be classified as follows:

Code E

If the root surface cannot be visualized directly as a result of gingival recession or by gentle air-drying, then it is excluded. Surfaces covered entirely by calculus can be




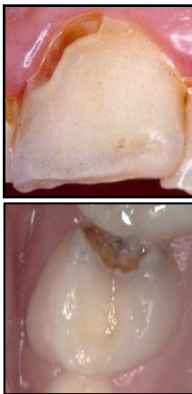
Definition of ICCMS™ Caries Merged categories		
Caries categories	Sound surfaces (ICDAS™ code 0)	 <p>Sound tooth surfaces show no evidence of visible caries (no or questionable change in enamel translucency) when viewed clean and after prolonged air-drying (5 seconds). 8-9</p> <p><i>(Surfaces with developmental defects such as enamel hypomineralisation (including fluorosis), tooth wear (attrition, abrasion and erosion), and extrinsic or intrinsic stains will be recorded as sound).</i></p>
	Initial stage caries (ICDAS™ codes 1 and 2)	 <p>First or distinct visual changes in enamel seen as a carious opacity or visible discolouration (white spot lesion and/or brown carious discolouration) not consistent with clinical appearance of sound enamel (ICDAS™ code 1 or 2) and which show no evidence of surface breakdown or underlying dentine shadowing.</p>
	Moderate stage caries (ICDAS™ codes 3 and 4)	 <p>A white or brown spot lesion with Localised enamel breakdown, without visible dentine exposure (ICDAS™ code 3), or an Underlying dentine shadow (ICDAS™ code 4), which obviously originated on the surface being evaluated.</p> <p><i>(To confirm enamel breakdown, a WHO/CPI/PSR ball-end probe can be used gently across the tooth area - a limited discontinuity is detected if the ball drops into the enamel micro-cavity/discontinuity).</i></p>
	Extensive stage caries (ICDAS™ codes 5 and 6)	 <p>A distinct cavity in opaque or discoloured enamel with visible dentine (ICDAS™ code 5 or 6).</p> <p><i>(A WHO/CPI/PSR probe can confirm the cavity extends into dentine).</i></p>

Table 2. Definition of ICCMS™ Caries categories (merged codes).