


# MAXILLA, ORBIT & PTERYGOPALATINE FOSSA

Neophytos C Demetriades MD, DDS, MSc

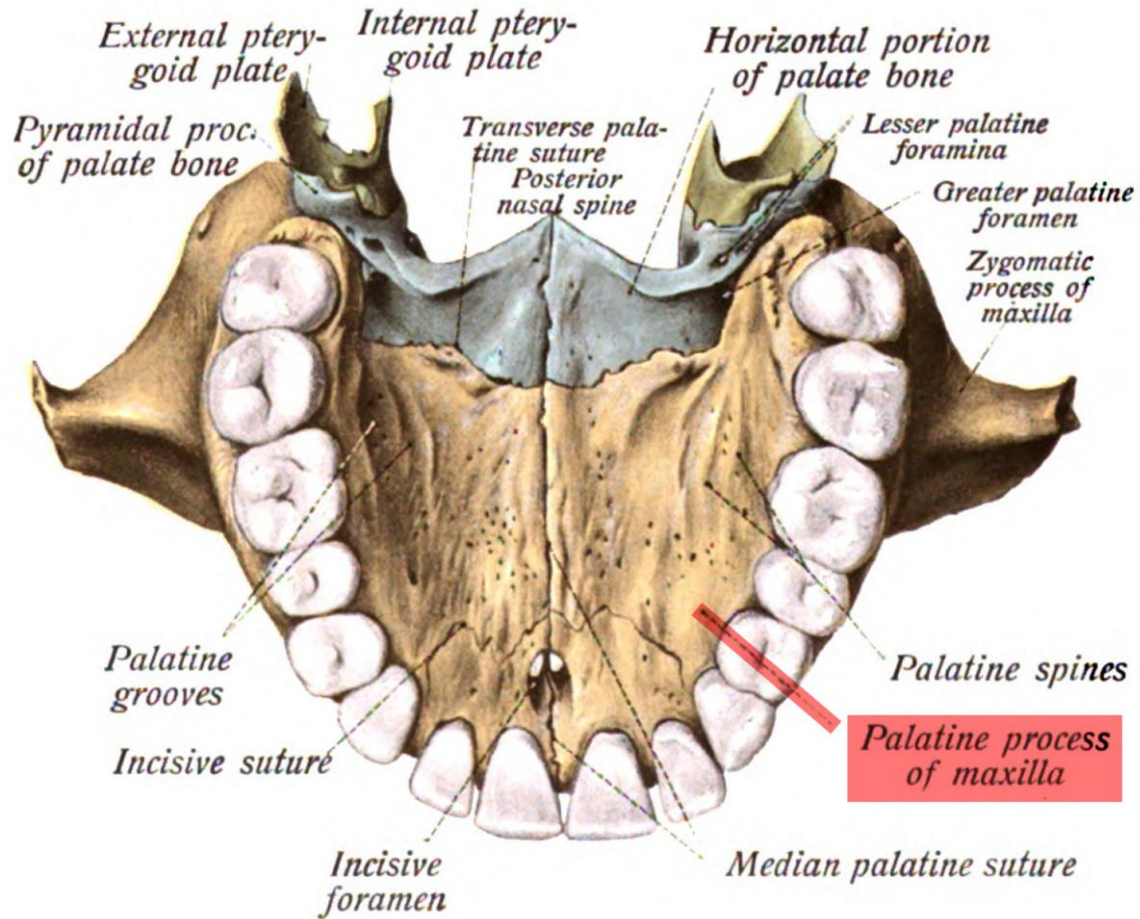

Associate professor

European University of Cyprus

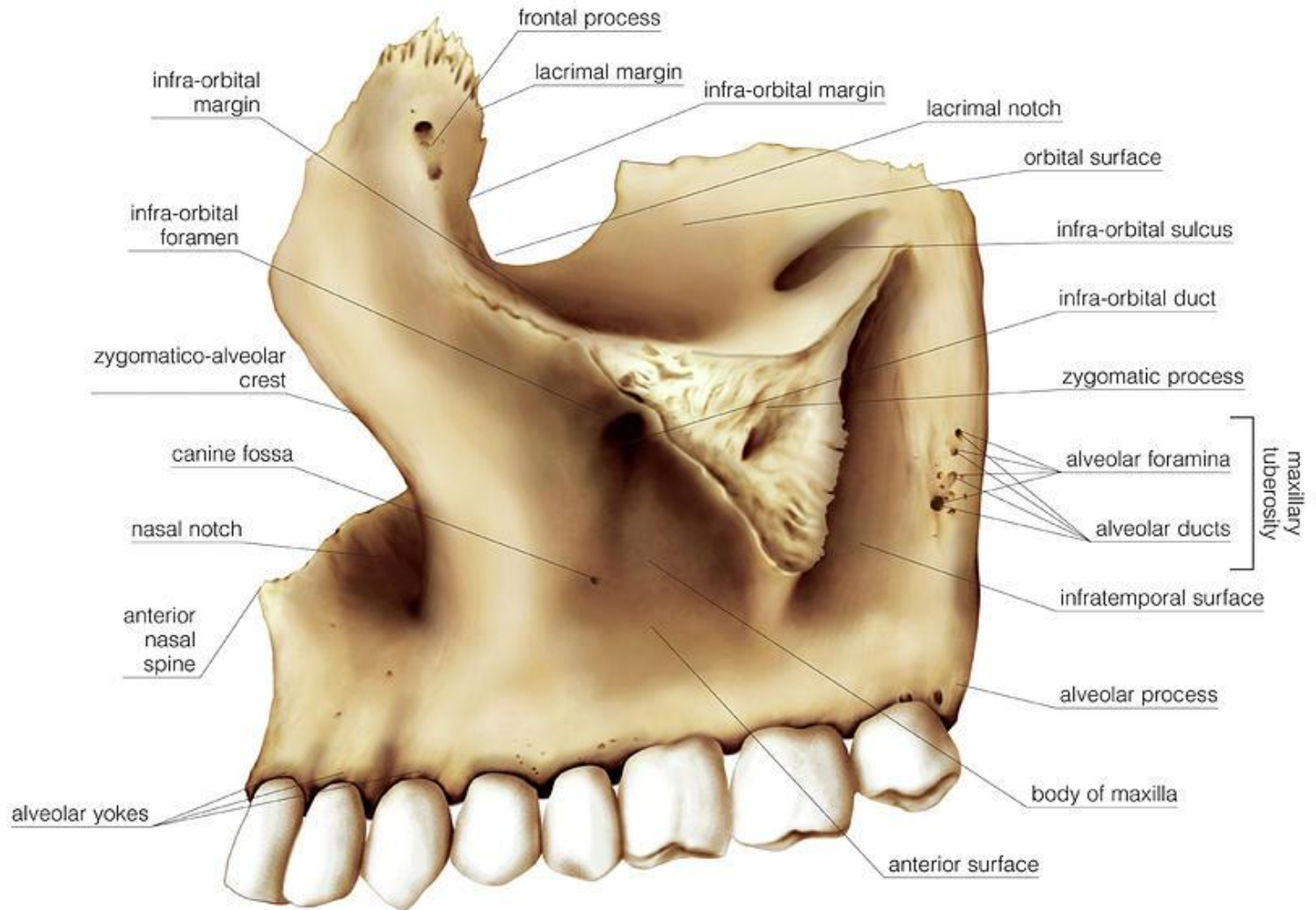
School of Medicine

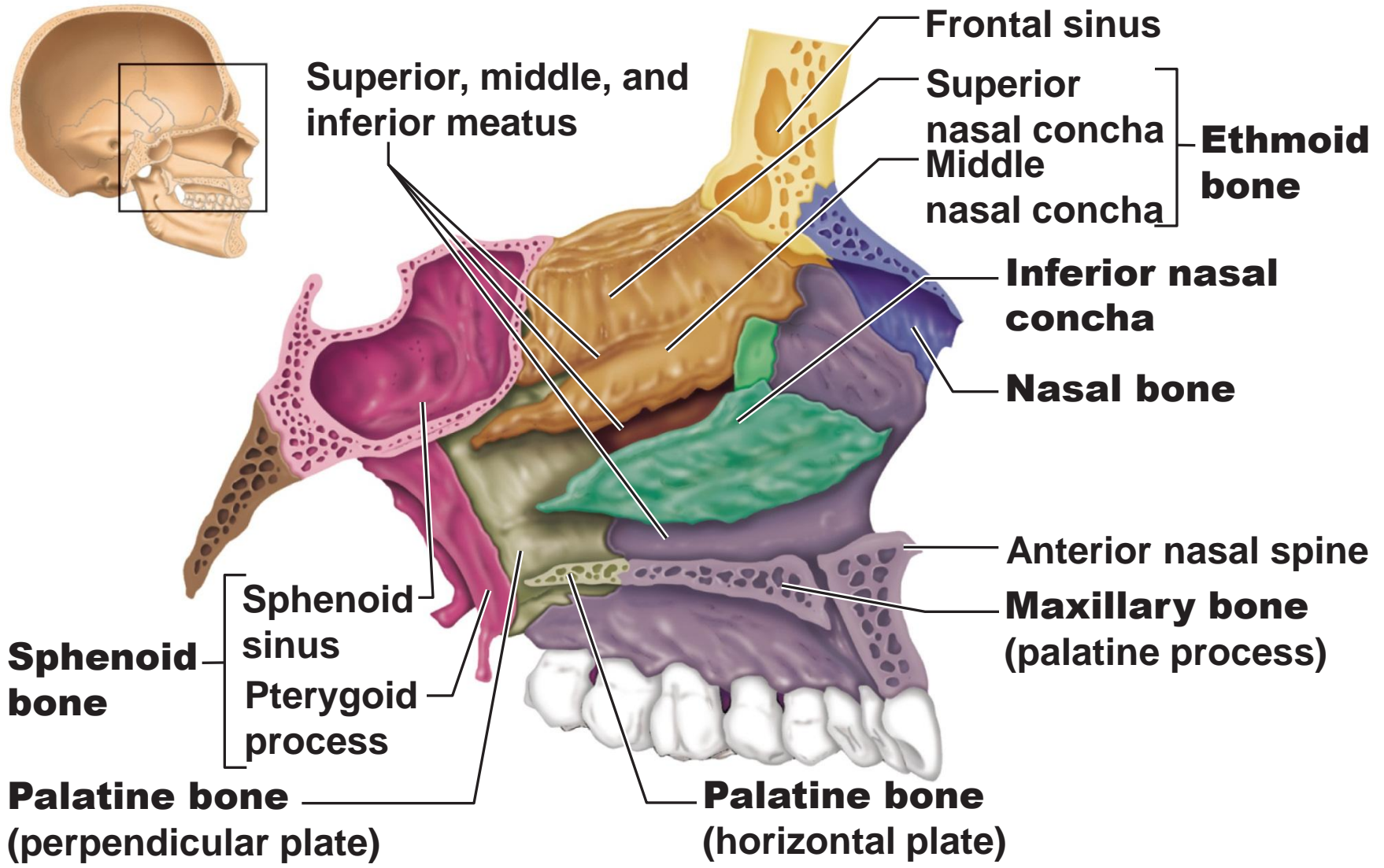



# Maxilla



# MAXILLA






**(a) Bones forming the left lateral wall of the nasal cavity (nasal septum removed)**


# ORBIT

## SALIENT ANATOMICAL FEATURES

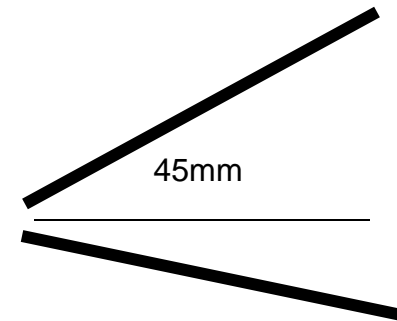
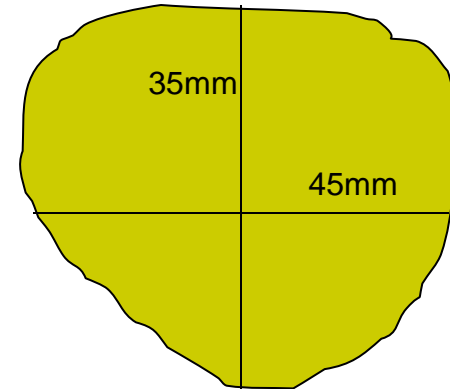


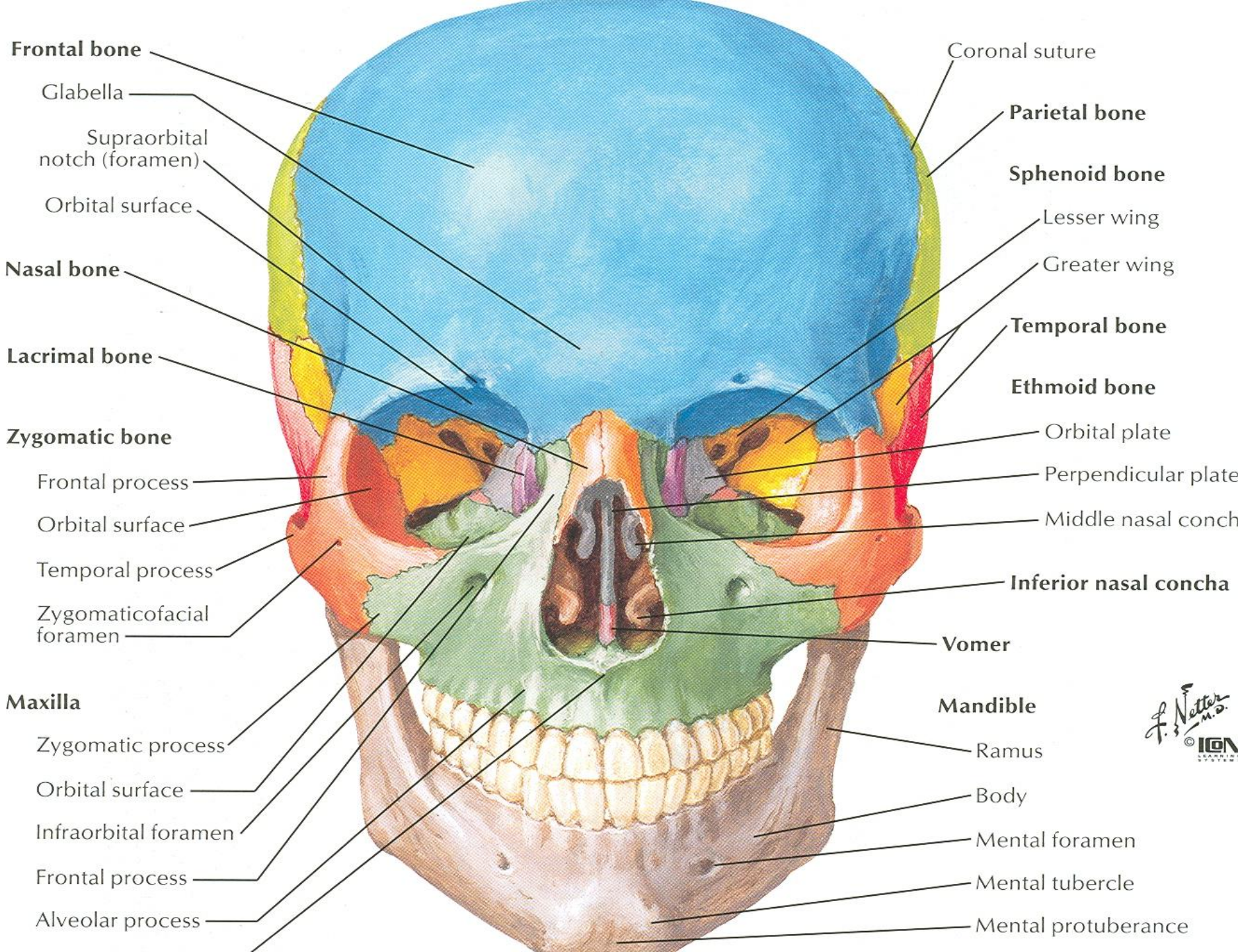
- 7 bones
- 4 walls
- 4 margins
- 4 important openings
- 6 contents
- 5 important relationships

# Adult orbital dimensions



Entrance height	35 mm
Entrance width	40 mm
Medial wall length / depth	45 mm
Volume	30 cc
Distance from the back of the globe to the optic foramen	18 mm





**Frontal bone**

Glabella

Supraorbital notch (foramen)

Orbital surface

**Nasal bone**

**Lacrimal bone**

**Zygomatic bone**

Frontal process

Orbital surface

Temporal process

Zygomaticofacial foramen

**Maxilla**

Zygomatic process

Orbital surface

Infraorbital foramen

Frontal process

Alveolar process

Coronal suture

**Parietal bone**

**Sphenoid bone**

Lesser wing

Greater wing

**Temporal bone**

**Ethmoid bone**

Orbital plate

Perpendicular plate

Middle nasal concha

**Inferior nasal concha**

**Vomer**

**Mandible**

Ramus

Body


Mental foramen

Mental tubercle

Mental protuberance

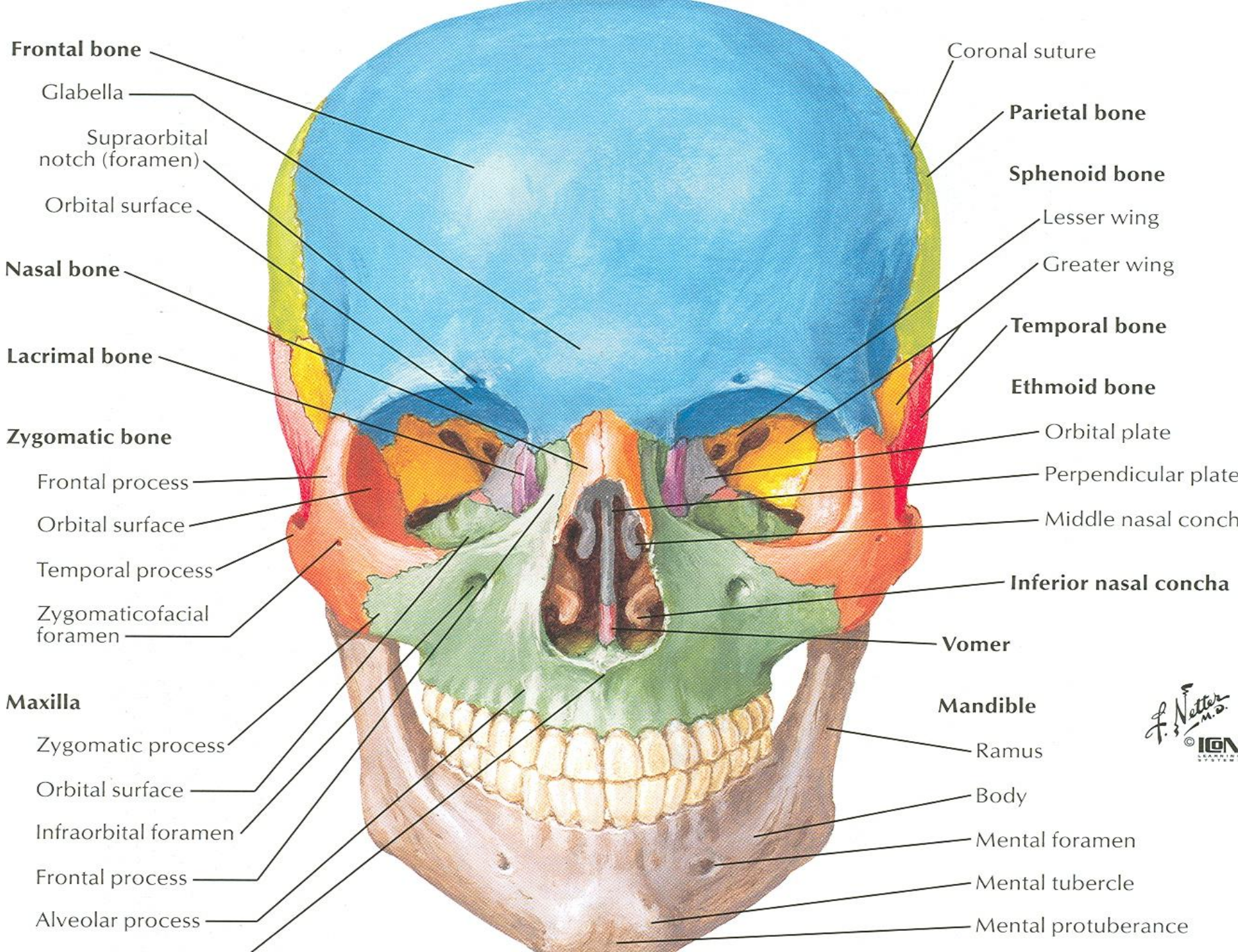


# Supraorbital Notch



- The supraorbital notch is situated on the superior orbital margin
- It transmits the supraorbital nerve and blood vessels





**Frontal bone**

Glabella

Supraorbital notch (foramen)

Orbital surface

**Nasal bone**

**Lacrimal bone**

**Zygomatic bone**

Frontal process

Orbital surface

Temporal process

Zygomaticofacial foramen

**Maxilla**

Zygomatic process

Orbital surface

Infraorbital foramen

Frontal process

Alveolar process

Coronal suture

**Parietal bone**

**Sphenoid bone**

Lesser wing

Greater wing

**Temporal bone**

**Ethmoid bone**

Orbital plate

Perpendicular plate

Middle nasal concha

**Inferior nasal concha**

**Vomer**

**Mandible**

Ramus

Body


Mental foramen

Mental tubercle

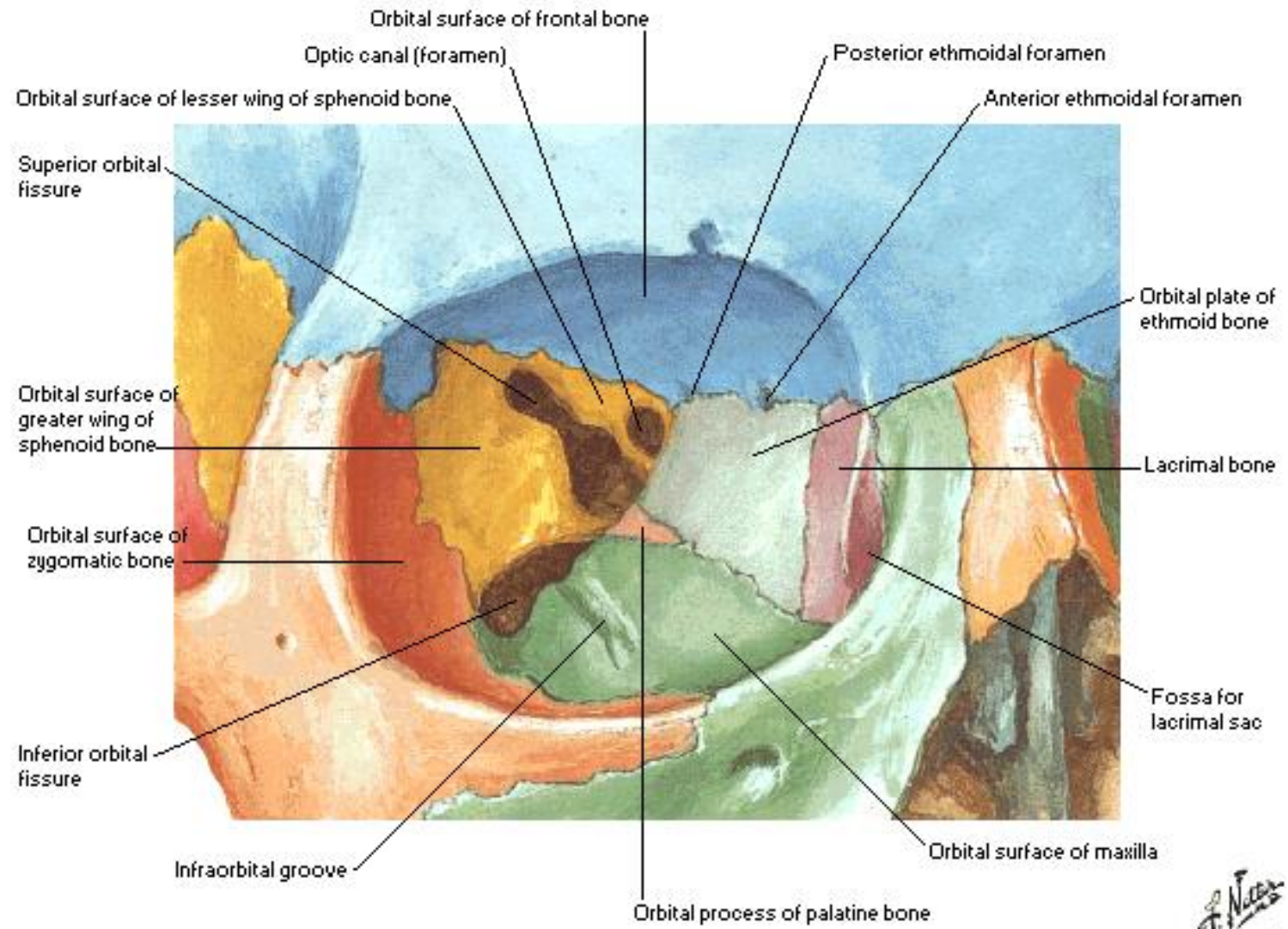

Mental protuberance




# Infraorbital Groove & Canal



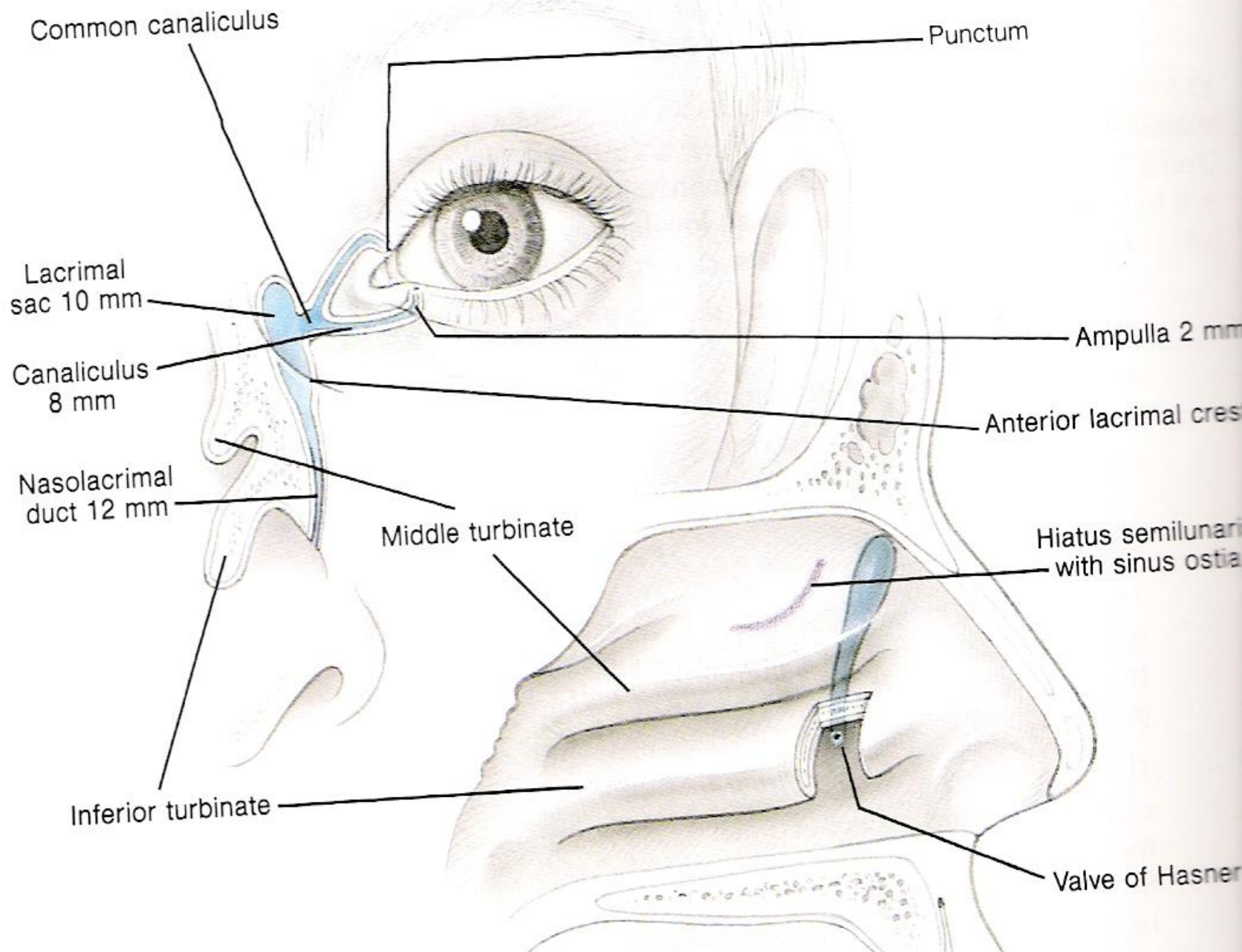
- Situated on the floor of the orbit in the orbital plate of the maxilla
- They transmit the infraorbital nerve (a continuation of the maxillary nerve) and blood vessels




# Nasolacrimal Canal



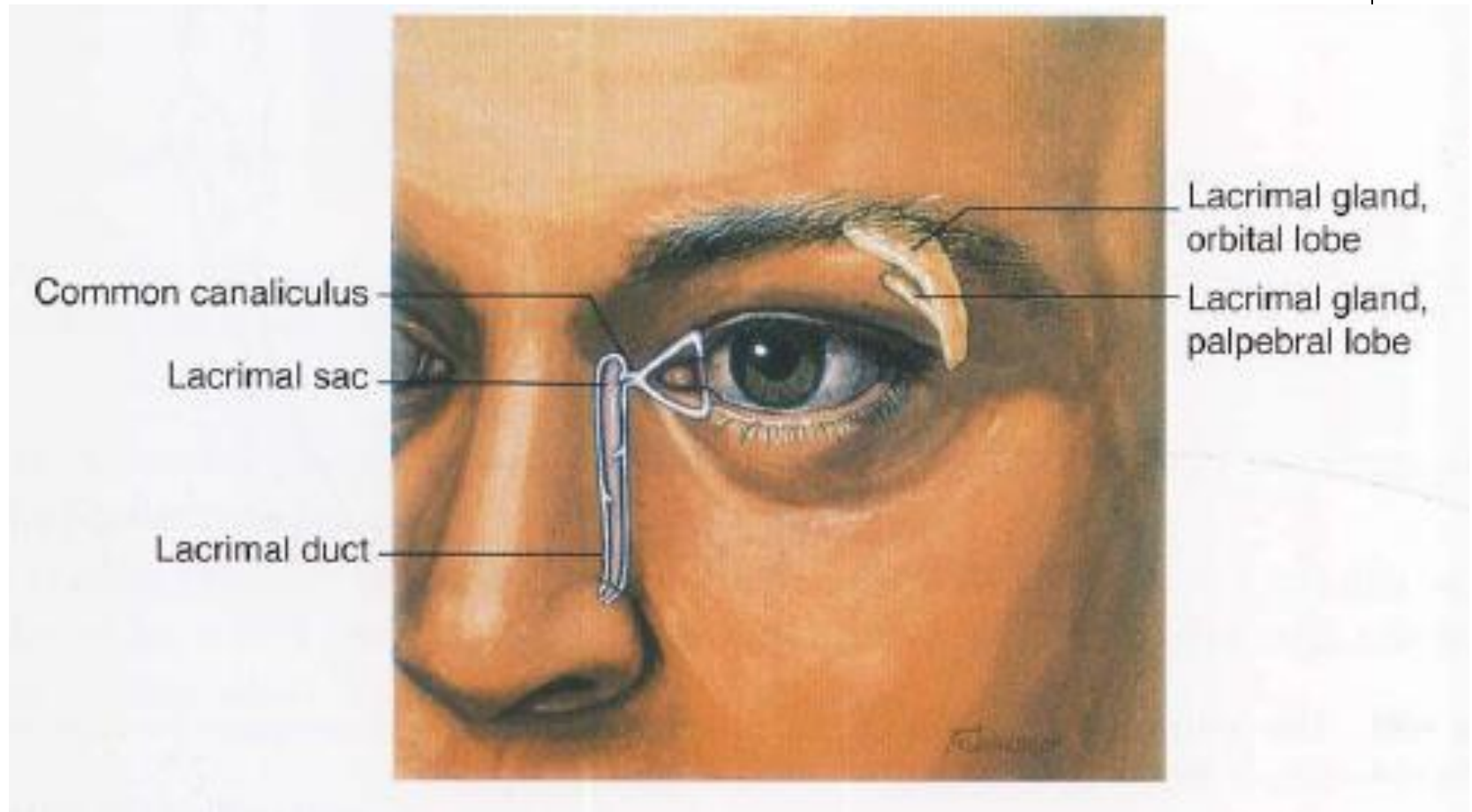

- Located anteriorly on the medial wall
- It communicates with the inferior meatus of the nose
- It transmits the nasolacrimal duct



# Lacrimal Gland and Excretory System



- The main lacrimal gland is located in a shallow depression within the orbital part of the frontal bone.
- The gland is divided into 2 parts.
- When the upper eyelid is everted, the smaller, palpebral part can be seen in the superolateral conjunctival fornix.




Common canaliculus

Lacrimal sac

Lacrimal duct

Lacrimal gland,  
orbital lobe

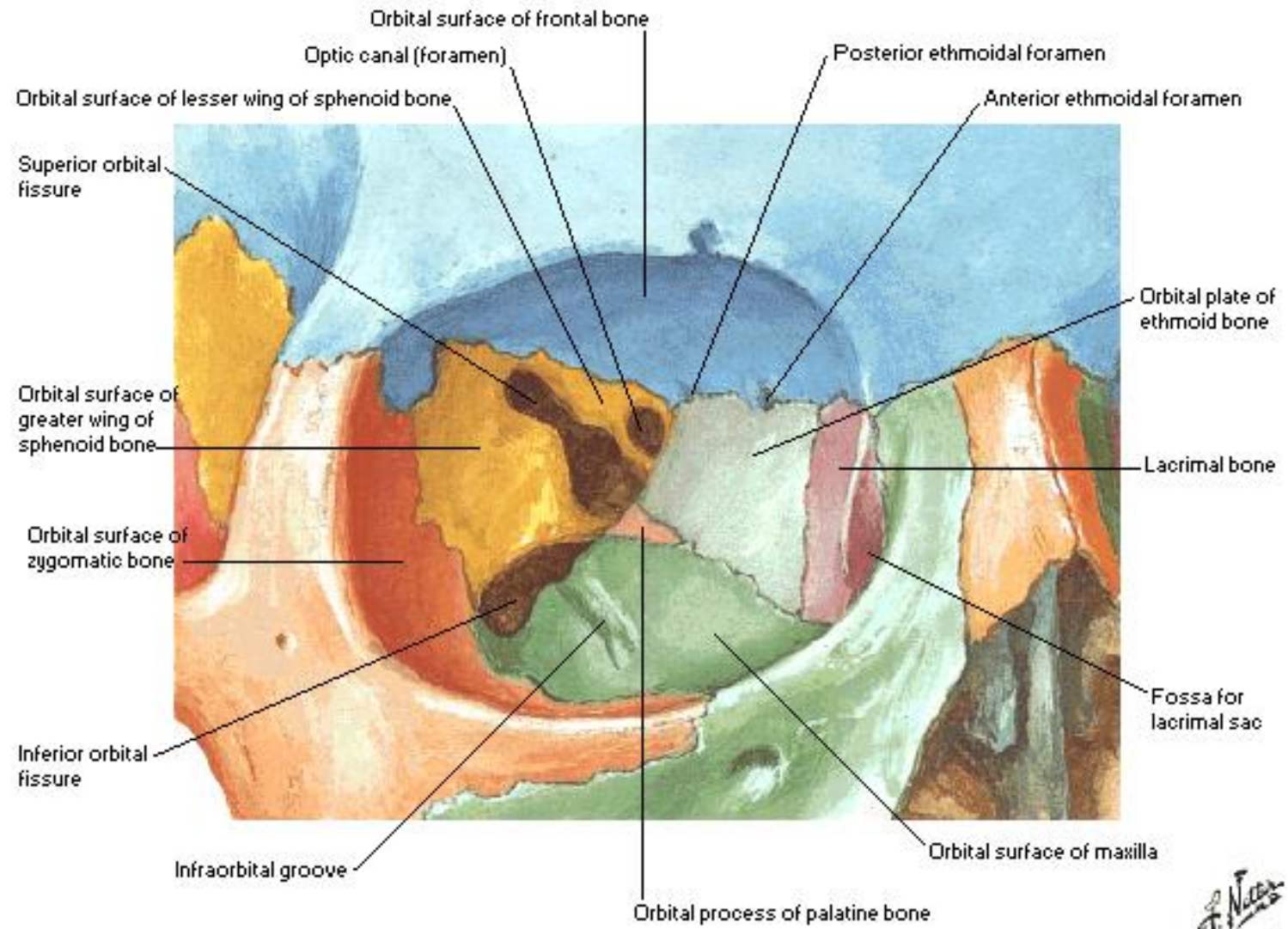

Lacrimal gland,  
palpebral lobe




# Inferior Orbital Fissure

- Located posteriorly between the maxilla and the greater wing of the sphenoid
- It communicates with the pterygopalatine fossa
- It transmits the maxillary nerve and its zygomatic branch, the inferior ophthalmic vein, and sympathetic nerves

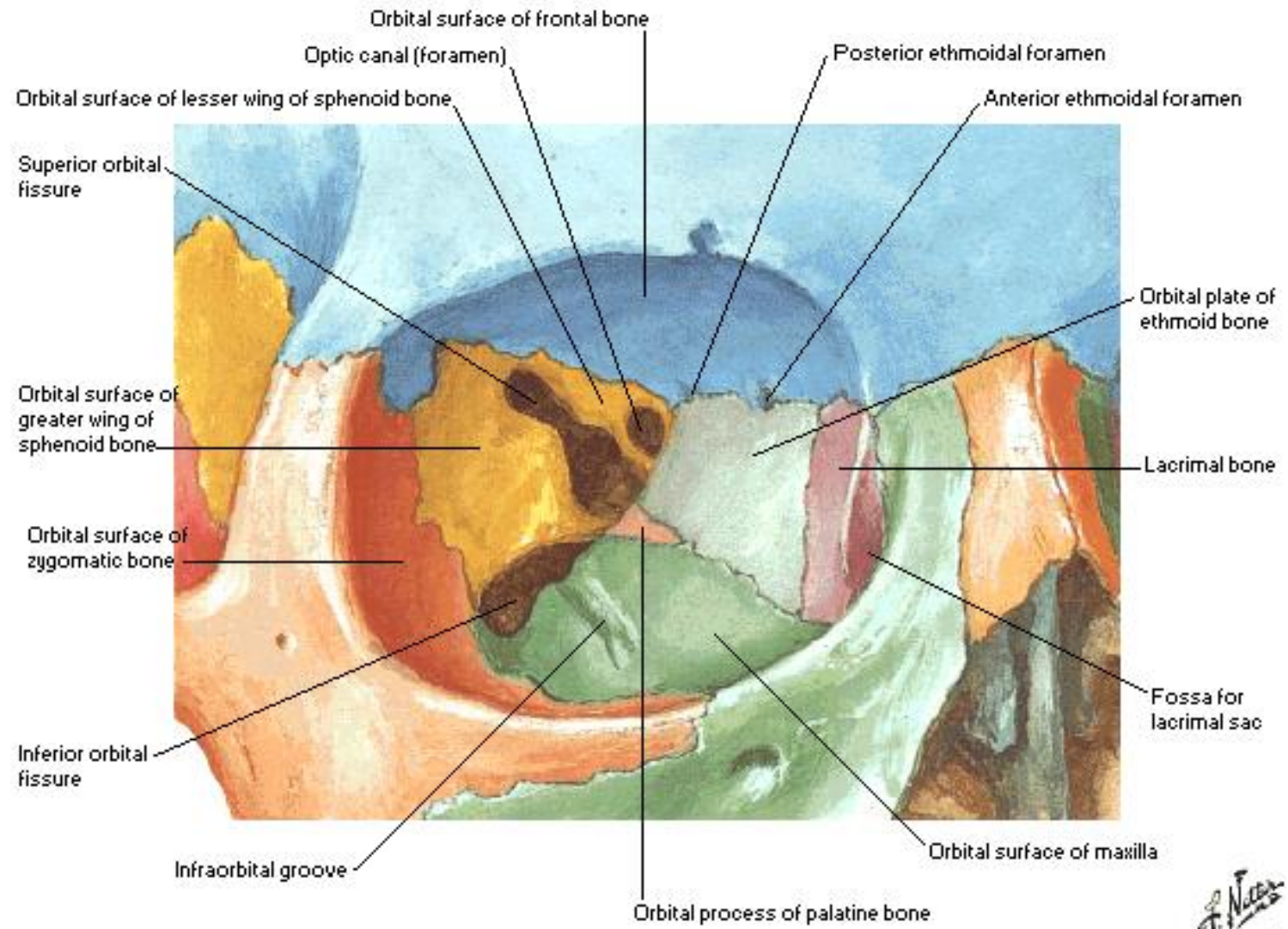






# Superior Orbital Fissure



- Located posteriorly between the greater and lesser wings of the sphenoid
- It communicates with the middle cranial fossa
- It transmits the lacrimal nerve, the frontal nerve, the trochlear nerve, the oculomotor nerve (upper and lower divisions), the abducent nerve, the nasociliary nerve, and the superior ophthalmic vein



# Optic Canal



- Located posteriorly in the lesser wing of the sphenoid
- It communicates with the middle cranial fossa
- It transmits the optic nerve and the ophthalmic artery

# Optic nerve



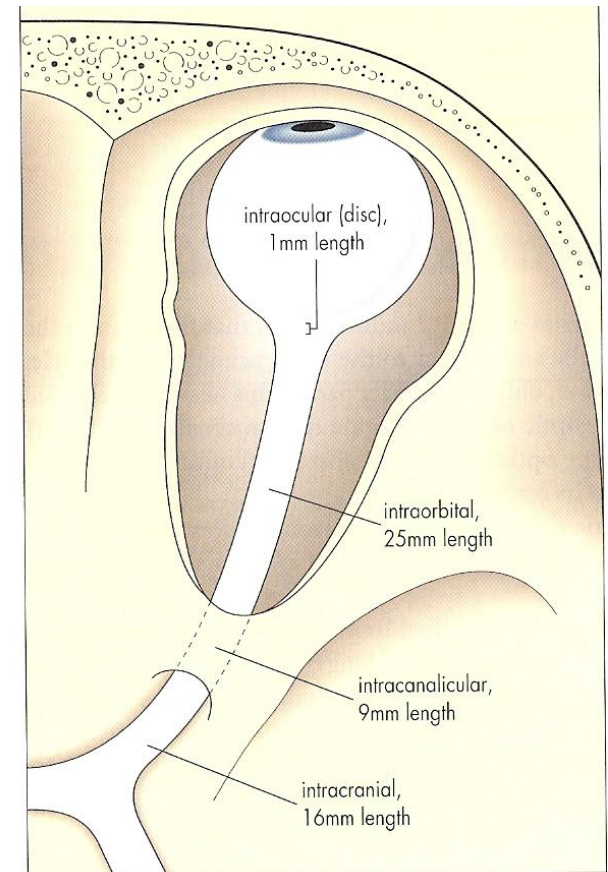
## The optic nerve may be divided into the following topographic areas:


Intraocular portion of the optic nerve: optic disc, or nerve head; prelaminar; and lamellar portions

Intraorbital portion (located within the muscle cone)

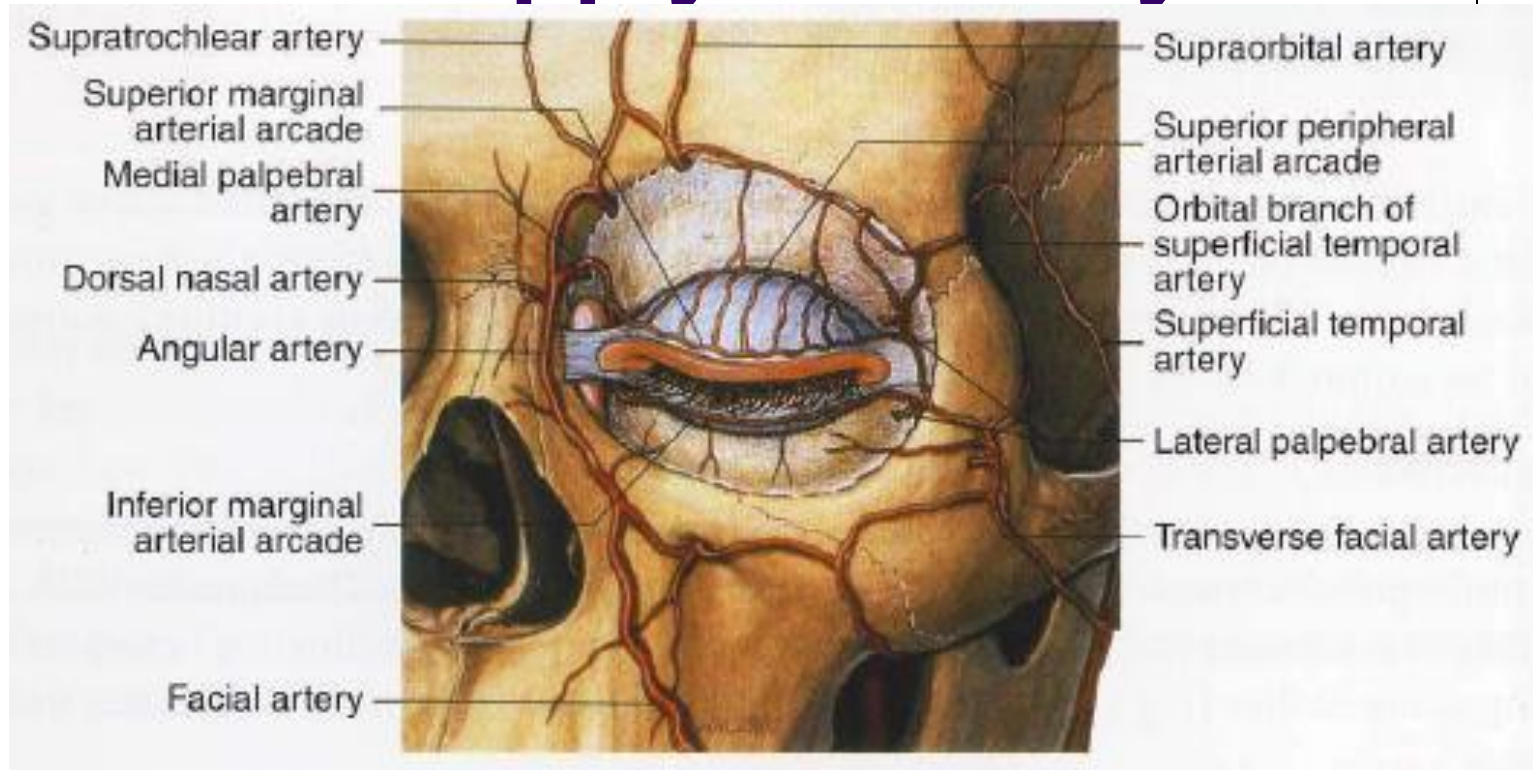
Intracanalicular portion (located within the optic canal)

Intracranial portion (ending in the optic chiasm)






# Vascular Supply of the Eyelids


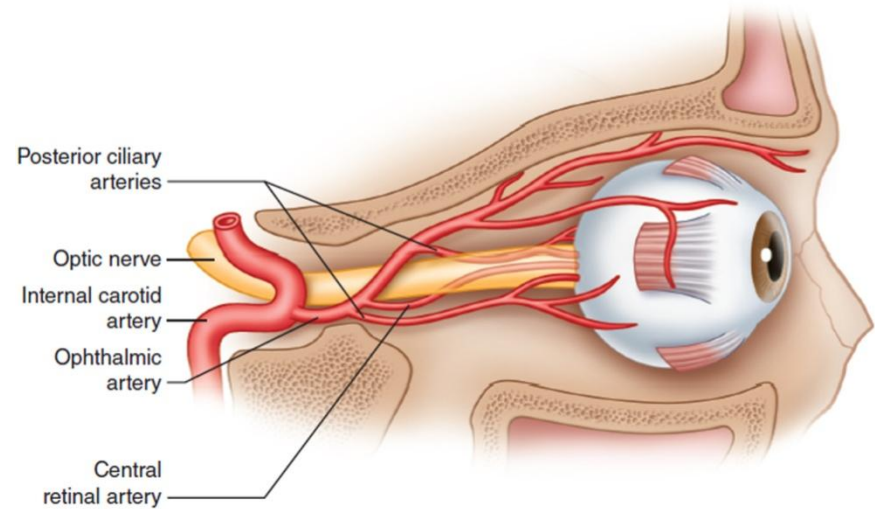



- The blood supply of the eyelids is derived from the facial system, which arises from the external carotid artery, and the orbital system, which originates from the internal carotid artery.

# Vascular Supply and Drainage of the Orbit



- The posterior ciliary vessels supply the whole uveal tract, the cilioretinal arteries, the sclera, the margin of the cornea, and the adjacent conjunctiva.
- The anterior ciliary arteries supply the rectus muscles.





- The venous drainage of the eyelids can be divided into 2 portions:
  1. Superficial system which drains into the internal and external jugular veins.
  2. Deep system which flows into the cavernous sinus.





Supratrochlear a.

Supra-orbital a.

Lacrimal gland

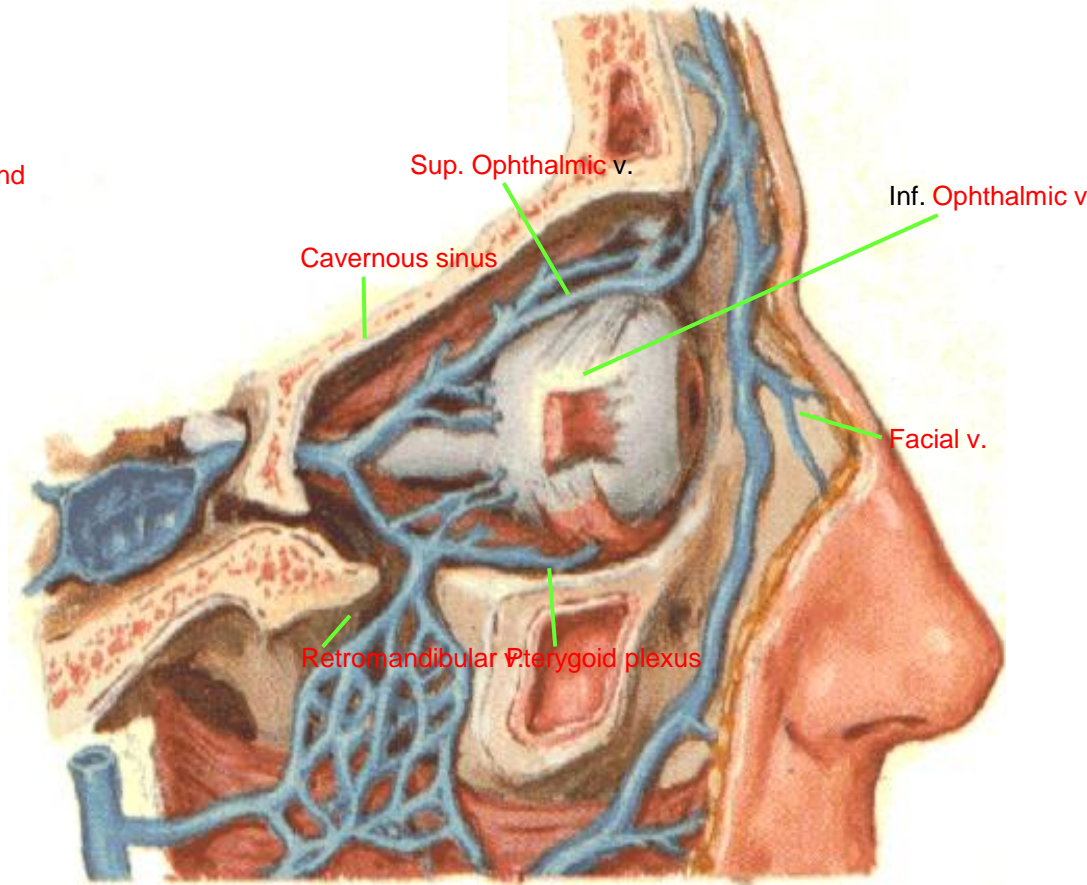
Ant. ethmoidal a.

Post. ethmoidal a.


Lacrimal a.

Ophthalmic a.

Internal carotid a.




# Muscles of Orbit



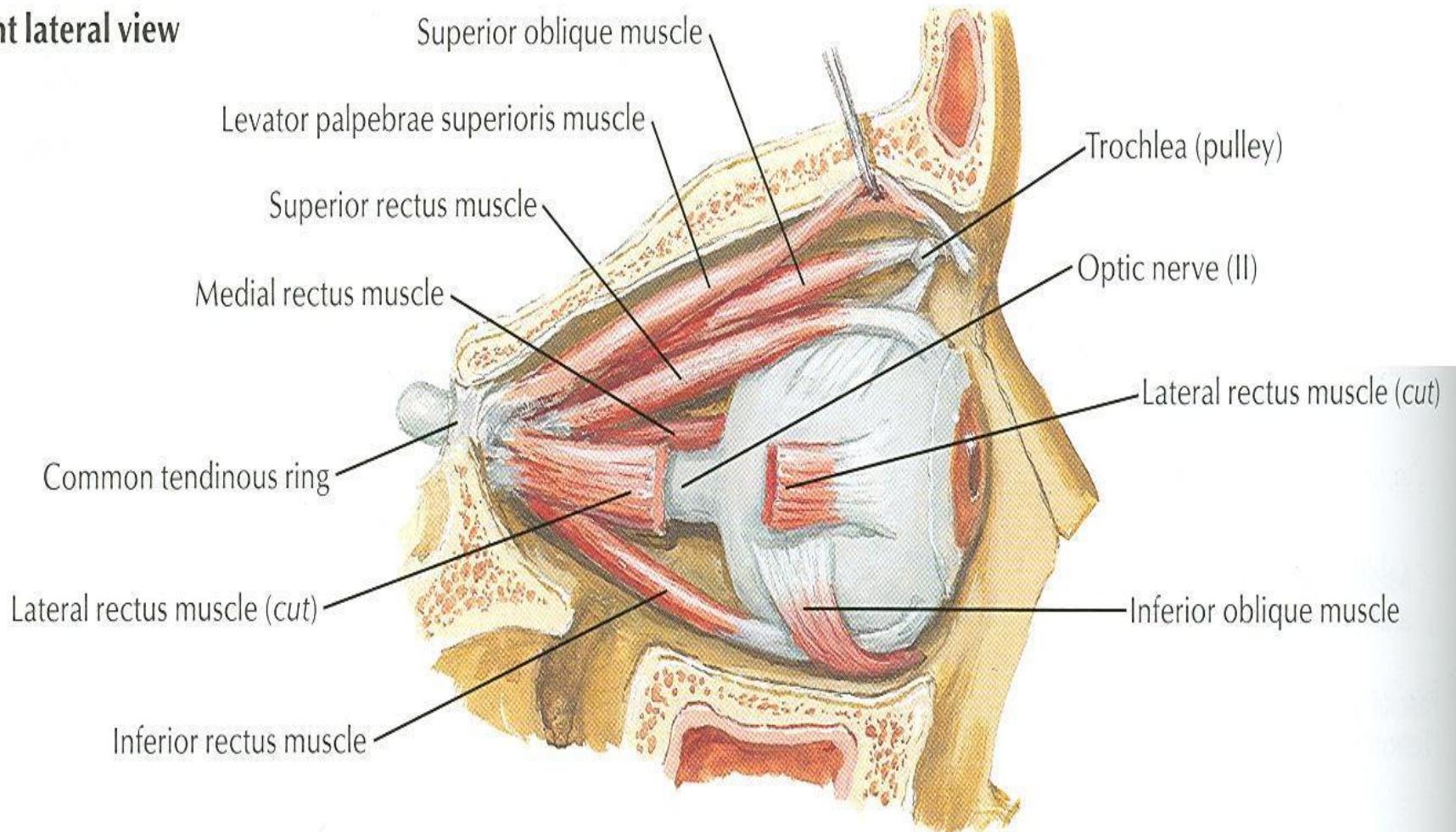
Muscles of the orbit are the levator palpebrae superioris, the four recti and two oblique muscles

# Levator Palpebrae Superioris




- Origin: Undersurface of lesser wing of sphenoid bone
- Insertion: Splits into 2 lamellae, superior into tarsal plate & skin of upper lid, inferior into upper margin of superior tarsal plate
- NS: Oculomotor nerve
- Action: Raises the upper lid

## Right lateral view



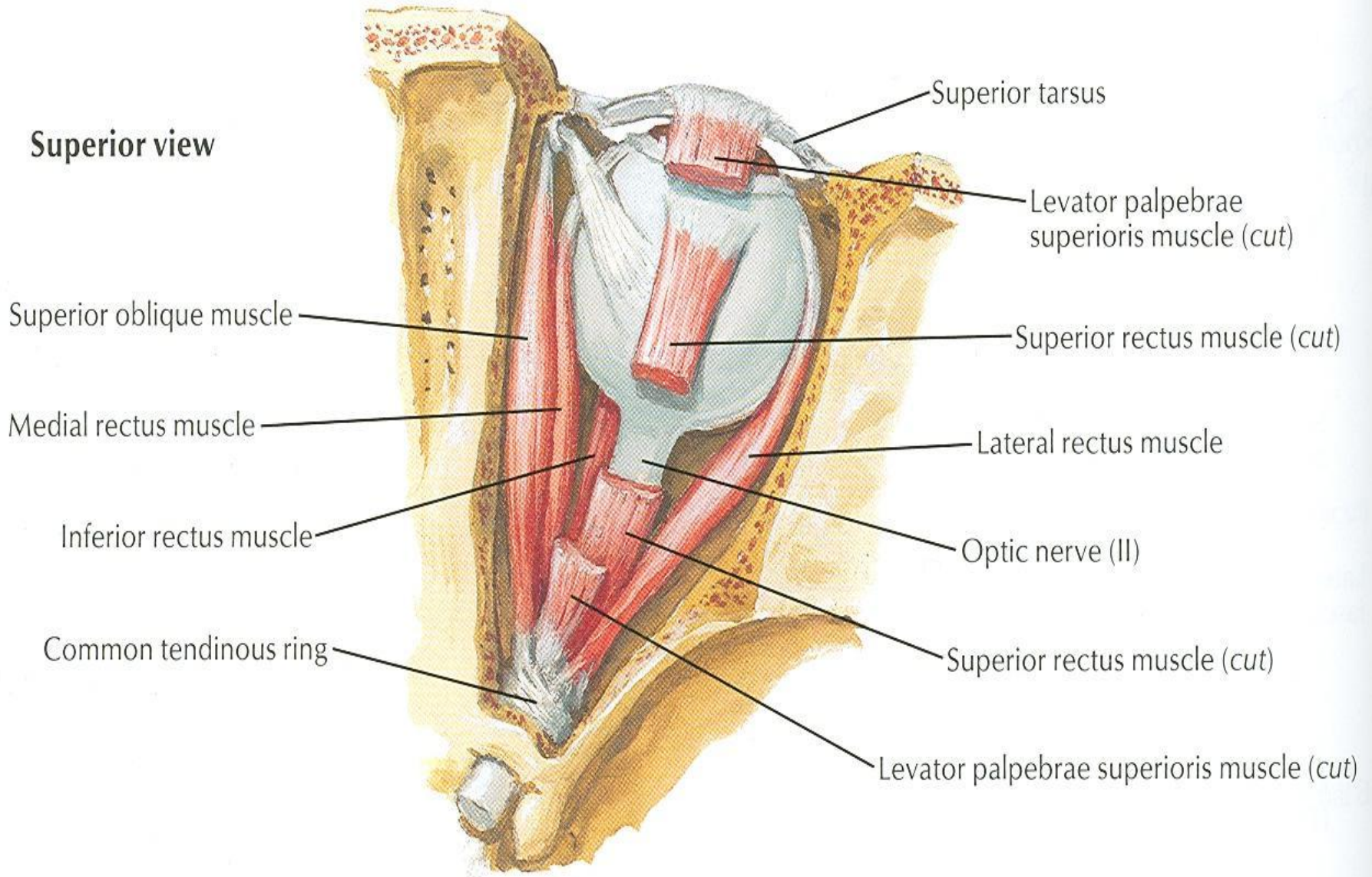
# The Recti



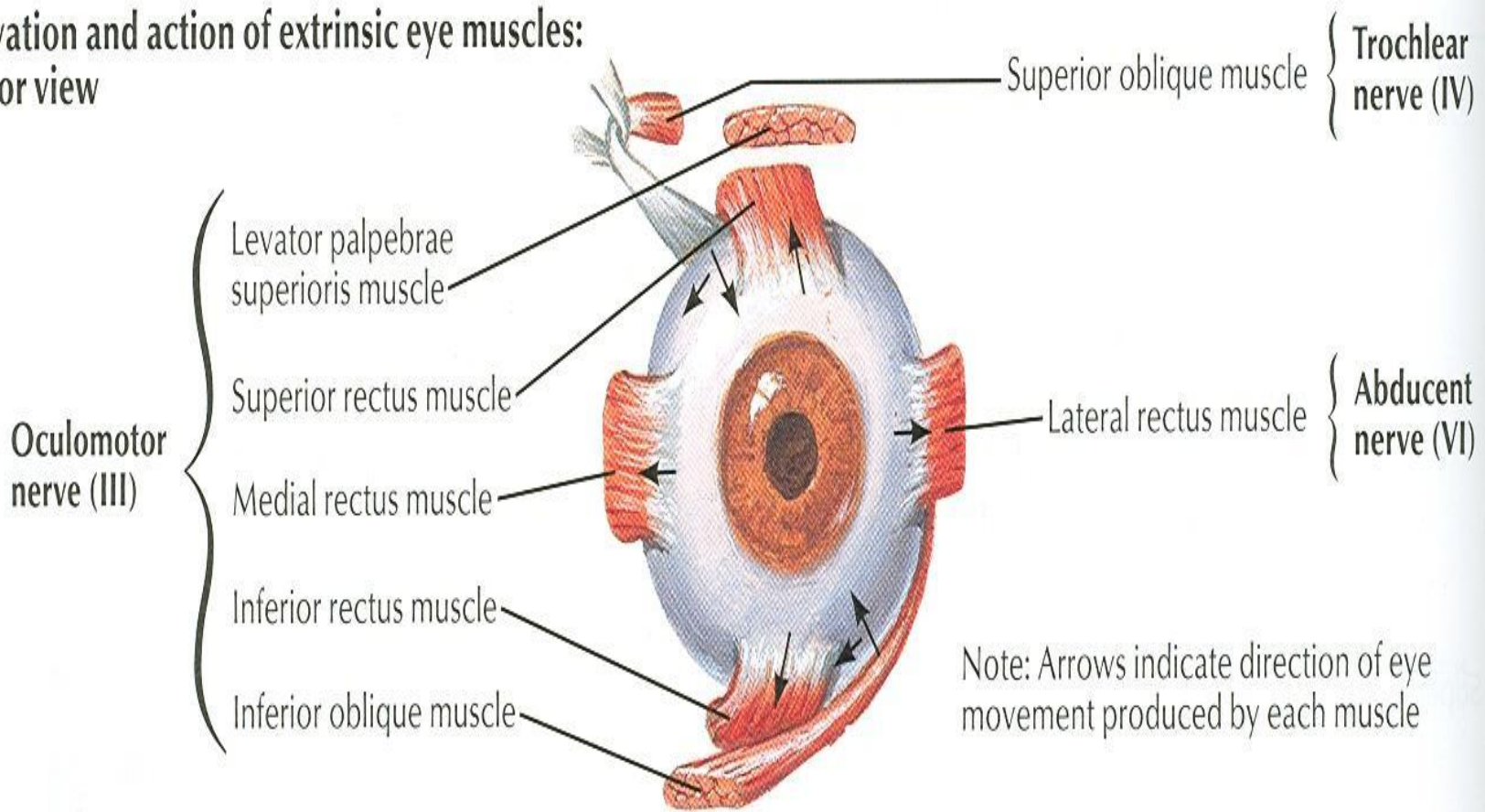
- Arise from a fibrous ring called common tendinous ring
- Insertion: form the muscular cone that encloses the optic nerve, pierces the facial sheath of the eyeball, in the sclera about 6 mm behind the margin of cornea




### Superior view




# Innervation and action of extrinsic eye muscles: anterior view





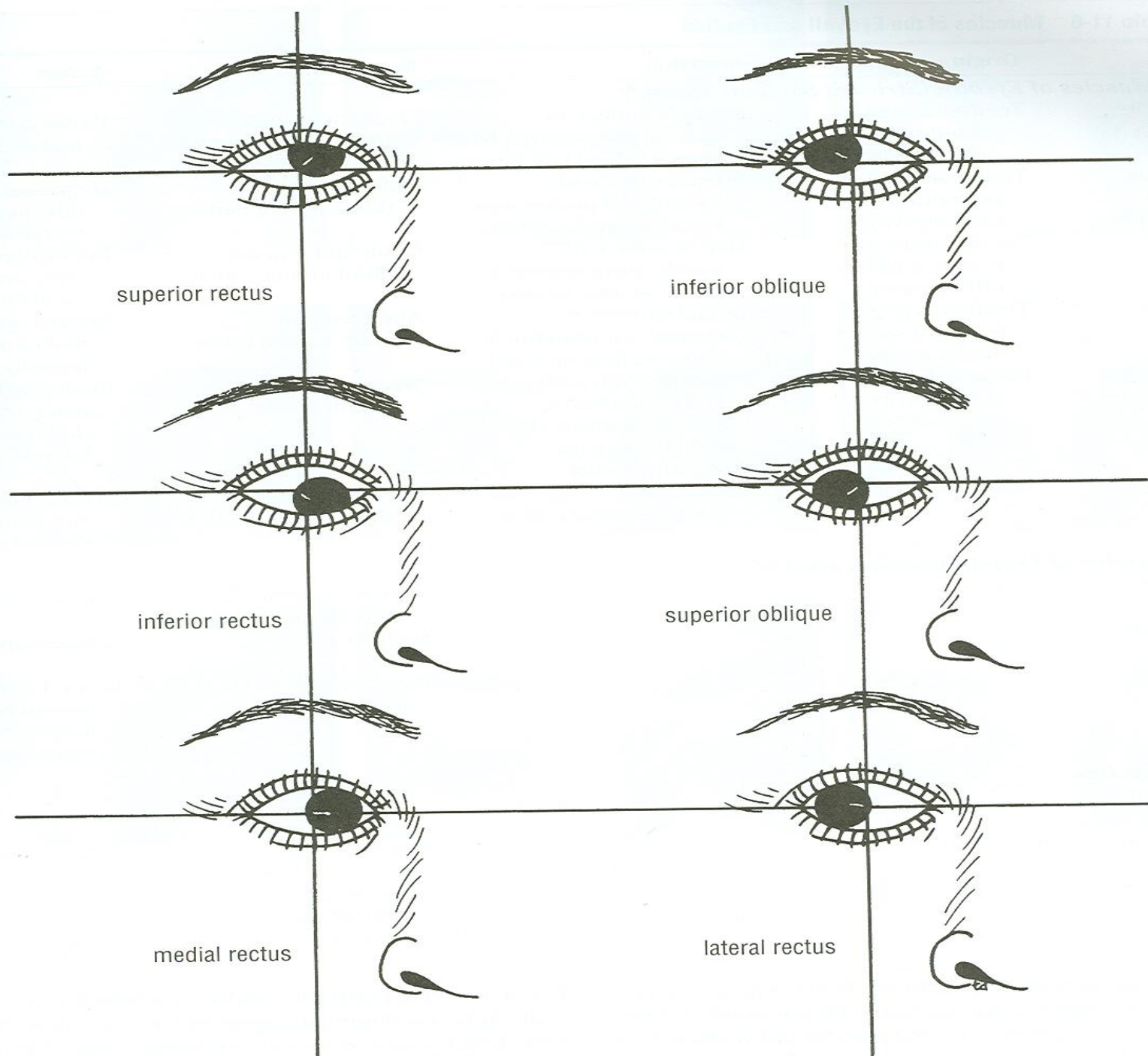
Muscle	Innervation	Movement
Lateral rectus	Abducens (VI)	Abduction
Medial rectus	Oculomotor (III)	Adduction
Superior rectus	Oculomotor (III)	Elevation and intorsion
Inferior rectus	Oculomotor (III)	Depression and extorsion
Inferior oblique	Oculomotor (III)	Extorsion and elevation
Superior oblique	Trochlear (IV)	Intorsion and depression






# The Recti


- NS: Lateral by abducent, all others by oculomotor
- Action: lateral rectus rotates the eyeball so that the cornea looks laterally  
Medial rectus rotates the eyeball so that the cornea looks medially



# The Recti



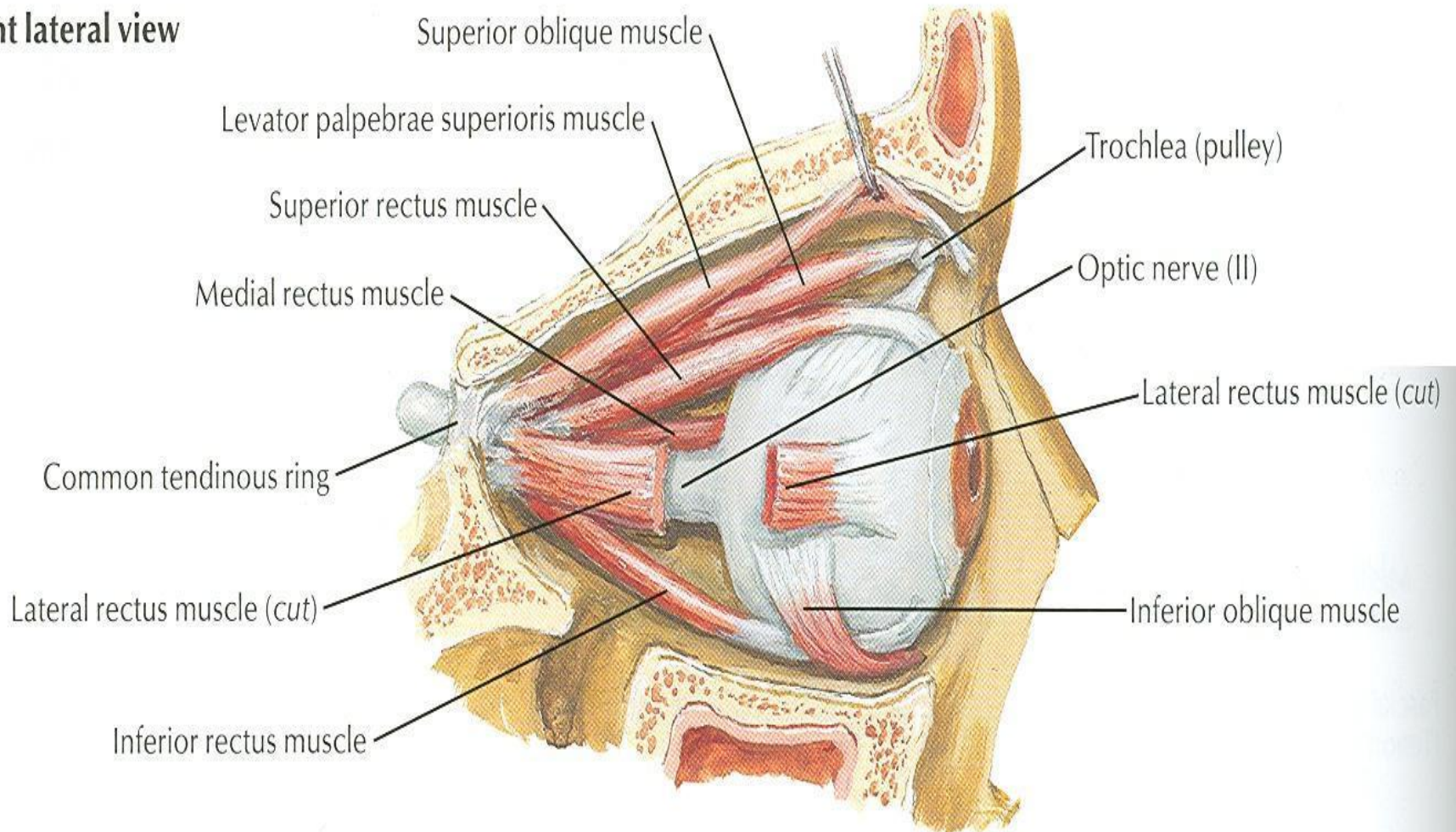
- Superior and inferior recti are inserted on the medial side of the vertical axis of the eyeball
- Superior rectus raises the cornea and rotates it medially
- Inferior rectus depresses the cornea and rotates it medially



# Superior Oblique

- Origin: From body of the sphenoid bone
- Insertion: into the sclera beneath the superior rectus after passing through the fibrocartilaginous pulley
- NS: Trochlear nerve
- Action: Rotates the eyeball so that the cornea looks downward & laterally


## Right lateral view





# Inferior Oblique

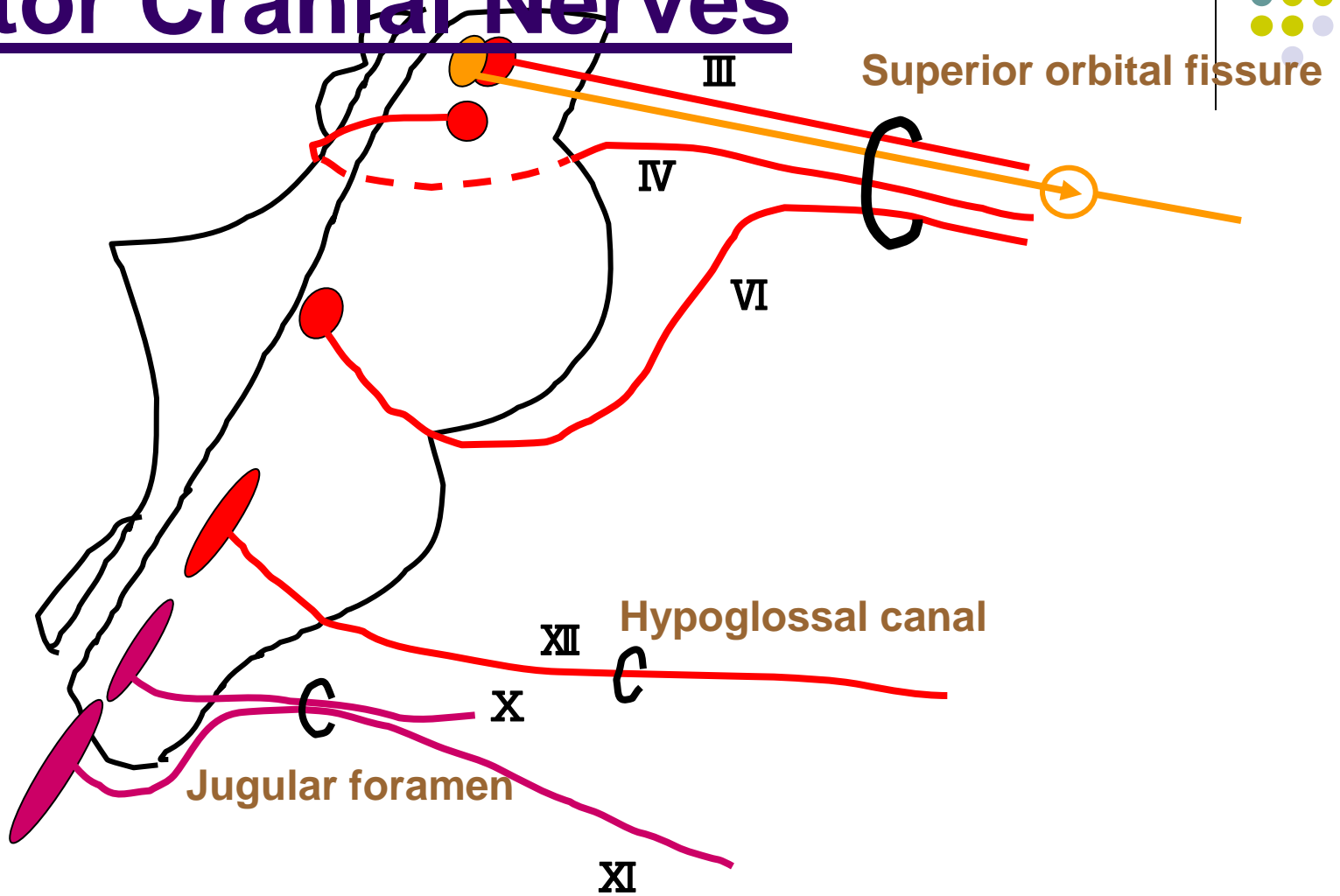
- Origin: Anterior part of floor of the orbit
- Insertion: In the sclera behind the coronal equator
- NS: Oculomotor
- Action: Rotates the eyeball so that the cornea looks upward and laterally



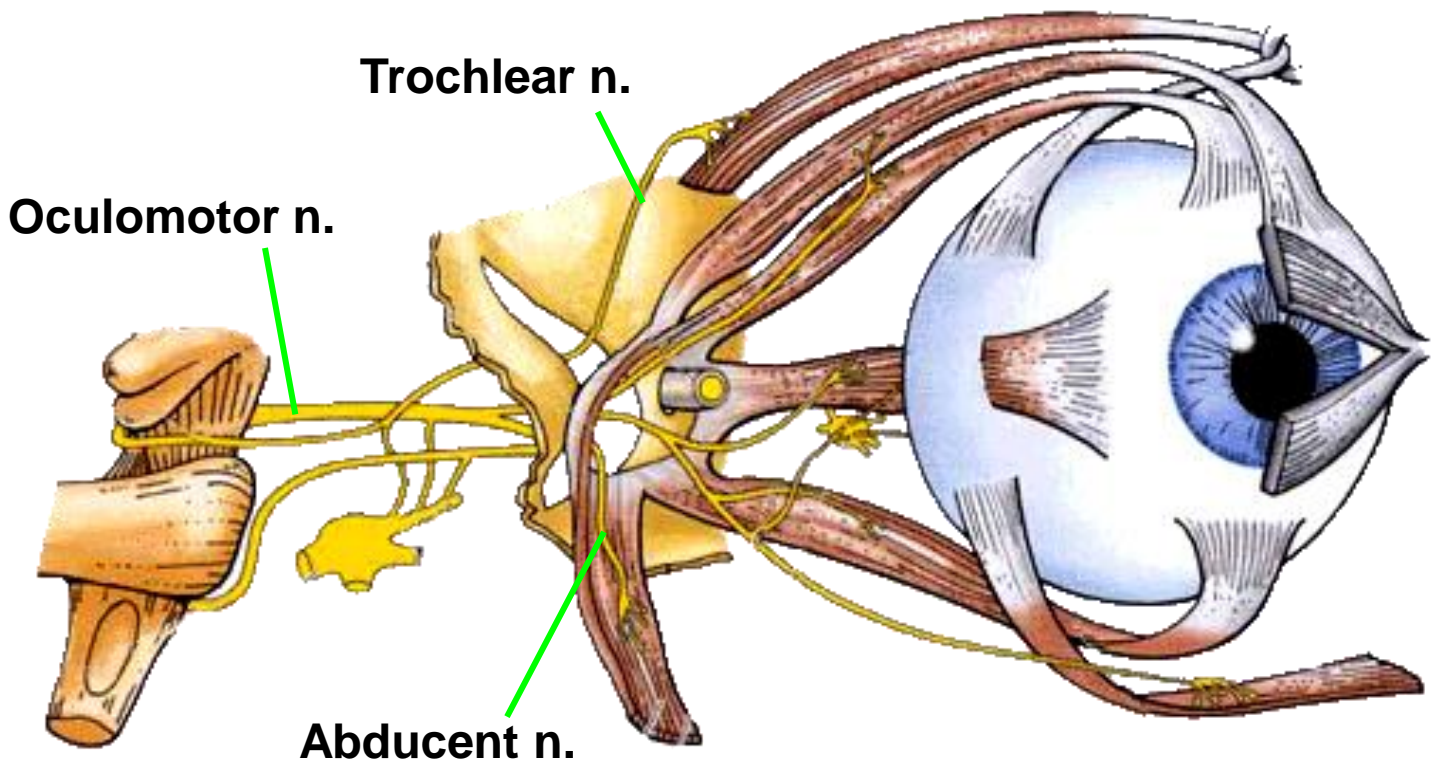
# Motor Supply

- Lacrimal Nerve
- Frontal Nerve
- Trochlear Nerve
- Oculomotor Nerve
- Abducent Nerve

# Motor Cranial Nerves








Oculomotor n.

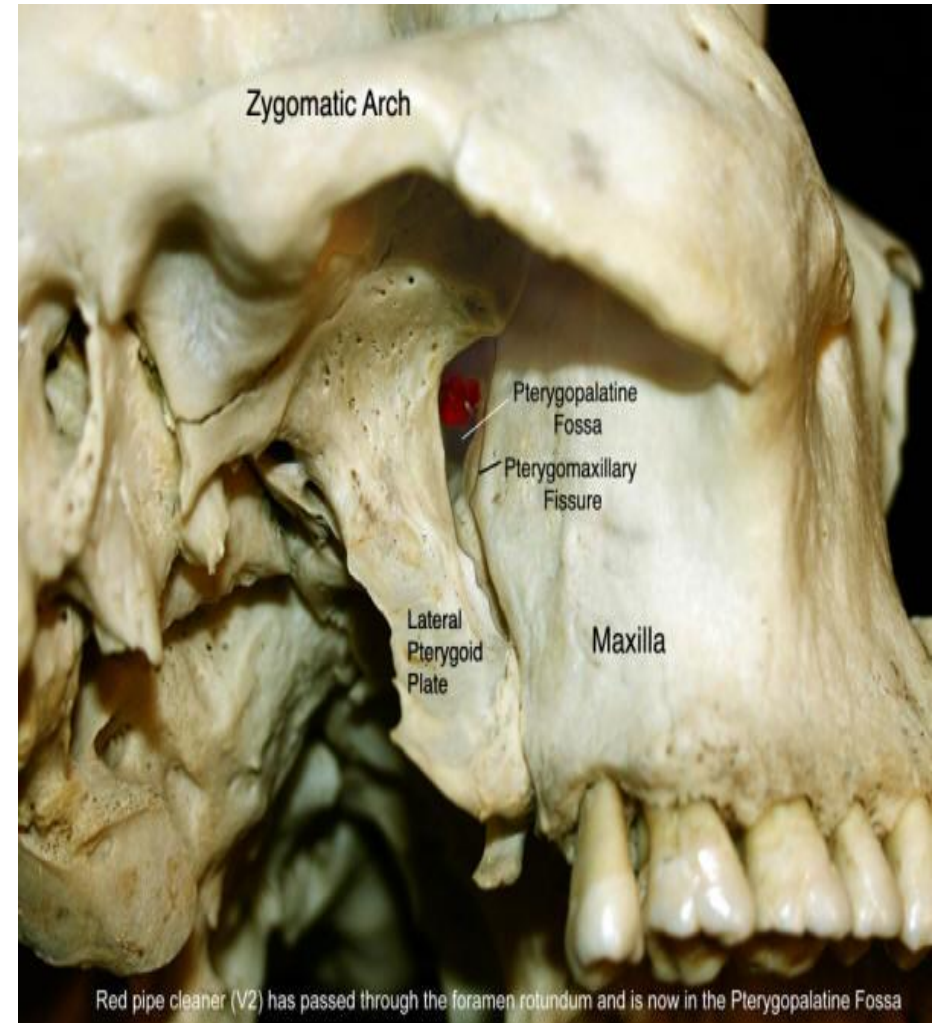
Trochlear n.

Abducent n.


# The Pterygopalatine fossa



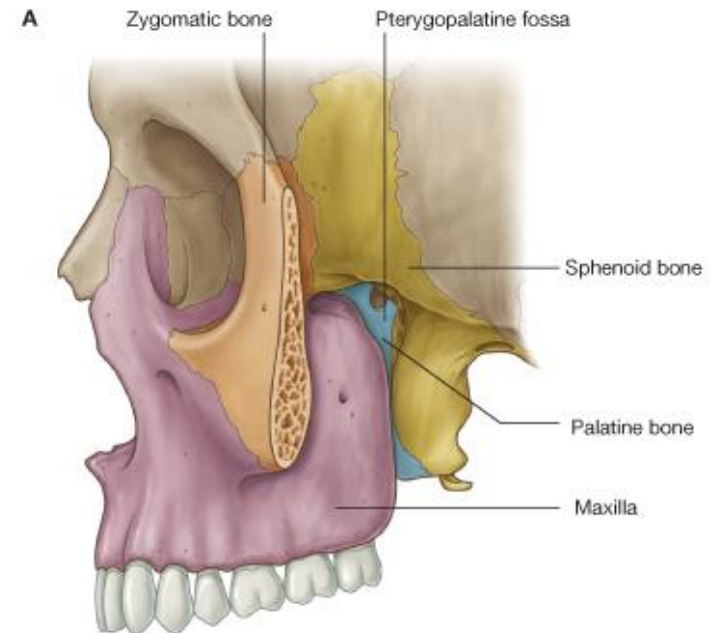
- Inverted '**tear-drop**' shaped space
- Between bones on the lateral side of the skull
- Immediately posterior to the maxilla
- Small in size



# Skeletal framework



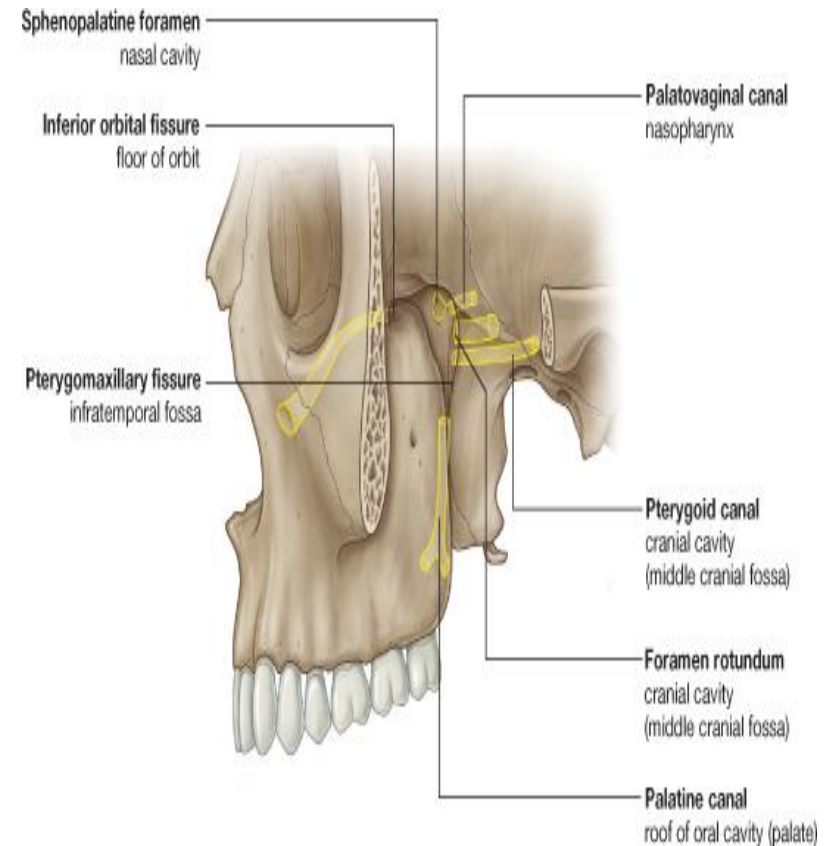
- The walls of the pterygopalatine fossa are formed by:
- The anterior wall is formed by the posterior surface of the **maxilla**;
- The medial wall is formed by the lateral surface of the **palatine bone**;
- The posterior wall and roof are formed by parts of the **sphenoid bone**.



# Gateways


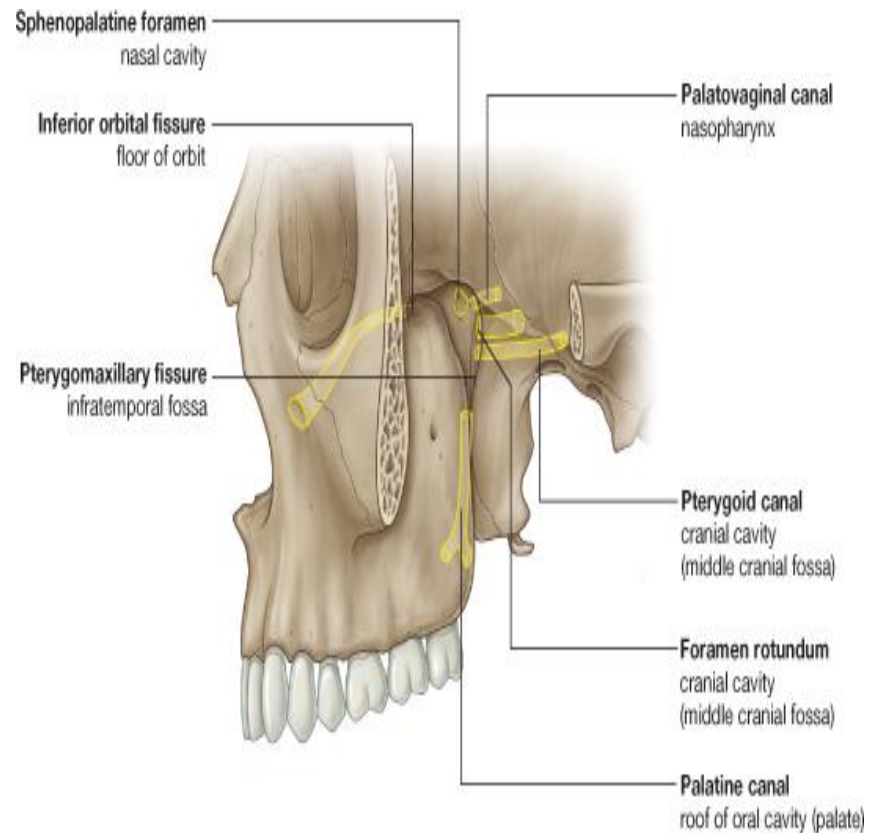


- Seven foramina and fissures provide apertures through which structures enter and leave the pterygopalatine fossa
- 1. **Foramen rotundum and pterygoid canal** communicate with the middle cranial fossa
- 2. **Palatovaginal canal** opens onto the posterior wall and leads to the nasopharynx;
- 3. **Palatine canal** leads to the roof of the oral cavity (hard palate) and opens inferiorly;
- 4 **Sphenopalatine foramen** opens onto the lateral wall of the nasal cavity and is in the medial wall;




# Gateways

- **5. Pterygomaxillary fissure** between lateral aspect of the pterygopalatine fossa and the infratemporal fossa;
- **6. Inferior orbital fissure** between the superior aspect of the fossa into the floor of the orbit




# Contents




- 1. The maxillary nerve [V2]
- 2. Terminal part of the maxillary artery
- 3. Nerve of the pterygoid canal
- 4. The pterygopalatine ganglion
- 5. Veins and lymphatics also pass through the pterygopalatine fossa.

# Pterygopalatine ganglion

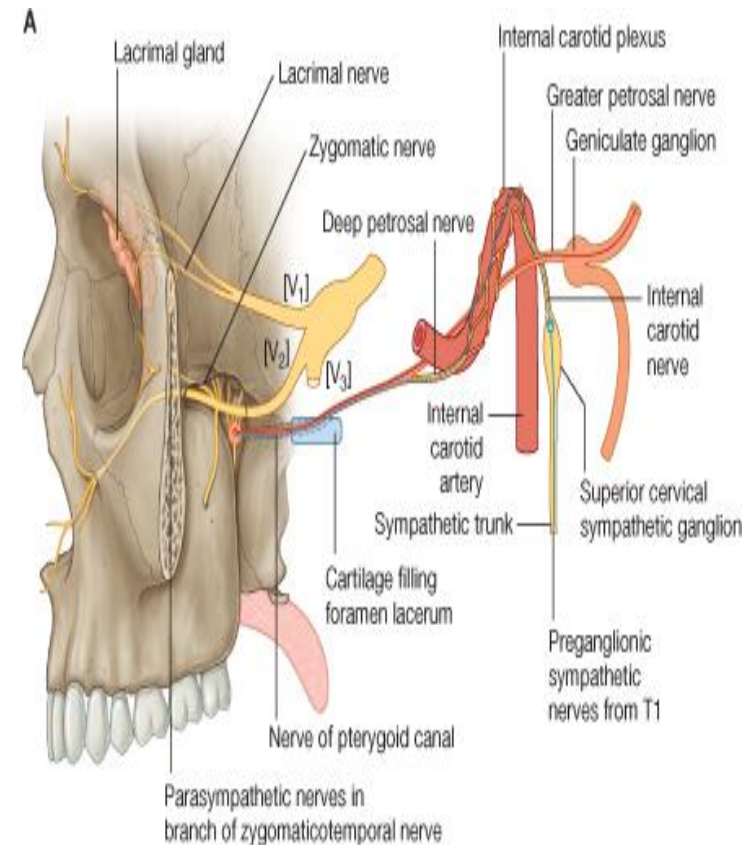
---




# Nerve of the pterygoid canal



- Formed in the middle cranial fossa by the union of:
  - 1. The greater petrosal nerve (a branch of the facial nerve [VII]);
  - 2. The deep petrosal nerve (a branch of the internal carotid plexus).
- Joins the pterygopalatine ganglion
- Carries mainly **preganglionic parasympathetic** (great petrosal) and **postganglionic sympathetic** (deep petrosal) fibers.

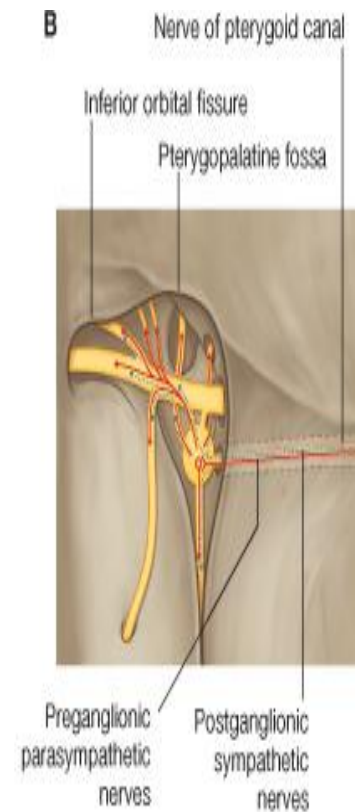







# Pterygopalatine ganglion

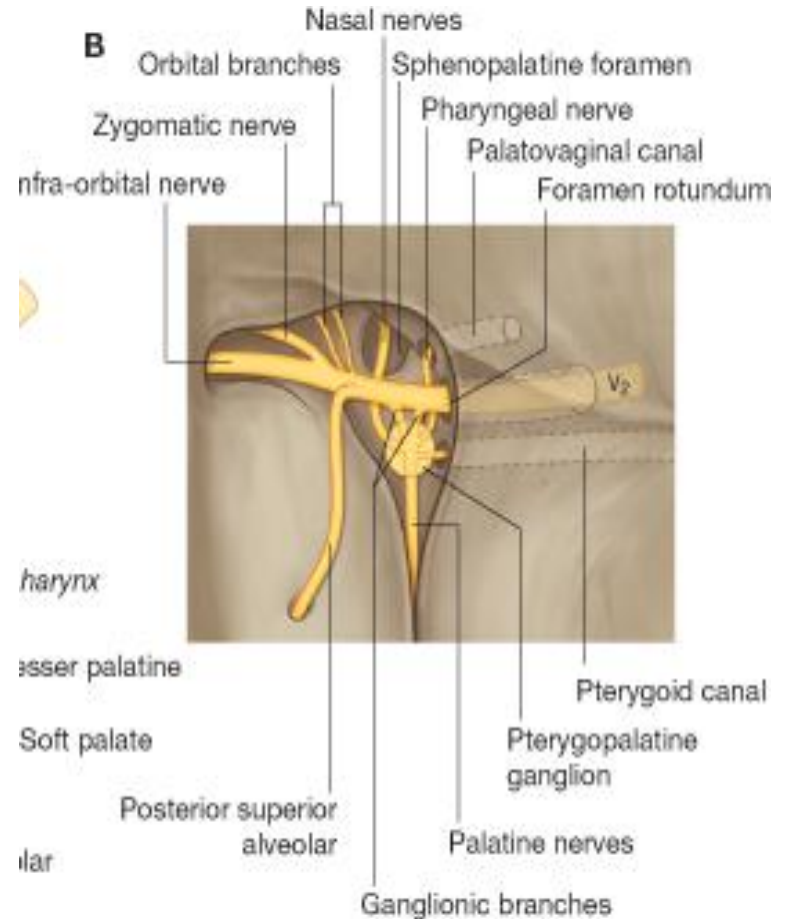
- Largest of the four parasympathetic ganglia in the head
- Formed by the cell bodies neurons associated with:
  1. **Preganglionic parasympathetic** fibers of the facial nerve carried by the **greater petrosal nerve** and the **nerve of the pterygoid canal**.
  2. **Sensory and ganglionic** branches of the **maxillary nerve**
  3. **Postganglionic sympathetic** fibers (**deep petrosal**)



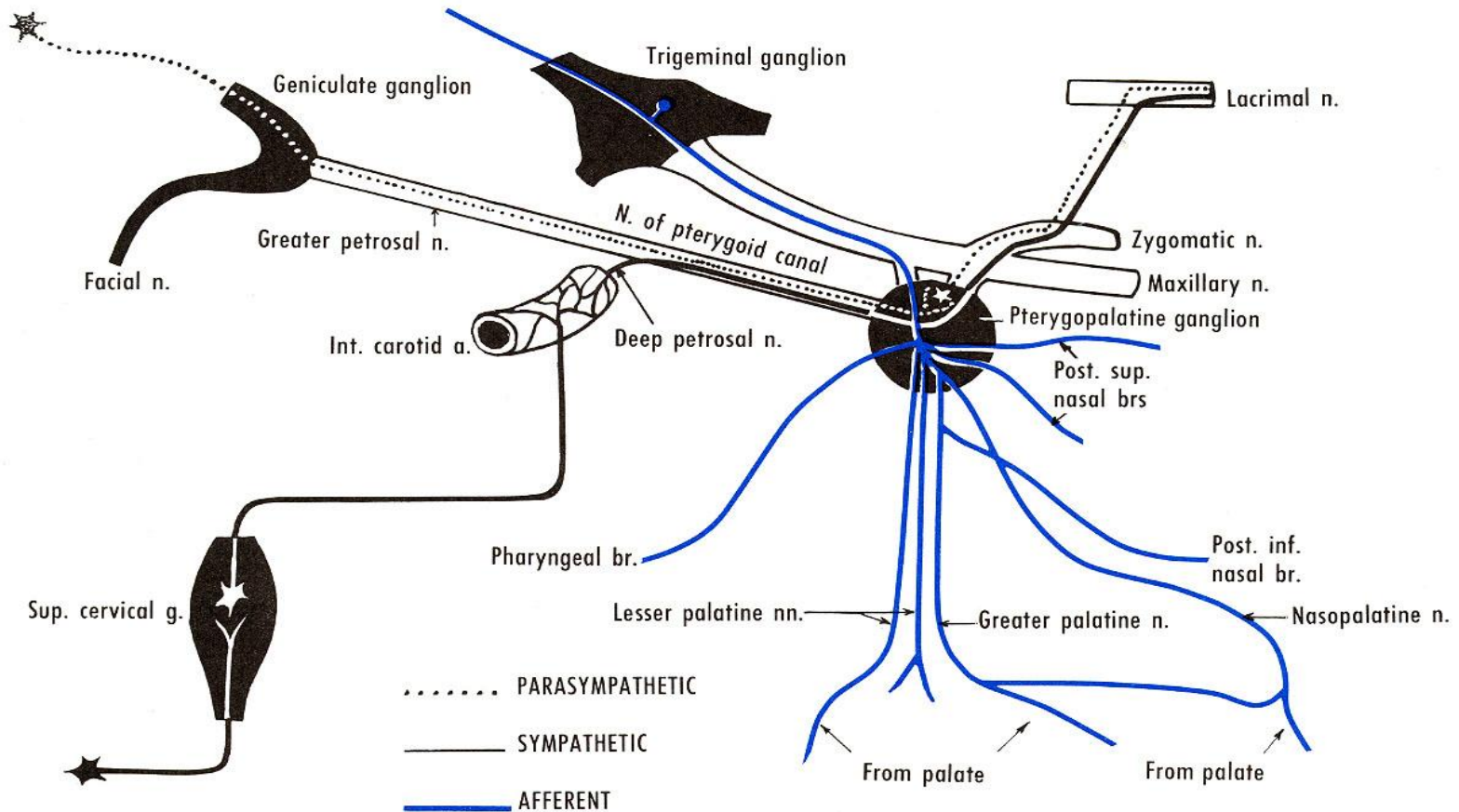




# Pterygopalatine ganglion

- These fibers form **orbital, palatine, nasal, and pharyngeal branches**, which leave the ganglion.
- Other fibers pass superiorly through the ganglionic branches of the maxillary nerve to enter the main trunk of the maxillary nerve
- And then **distributed with the zygomatic, posterior superior alveolar, and infra-orbital nerves**



# Pterygopalatine ganglion



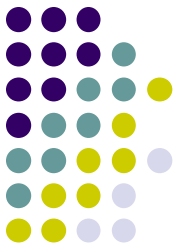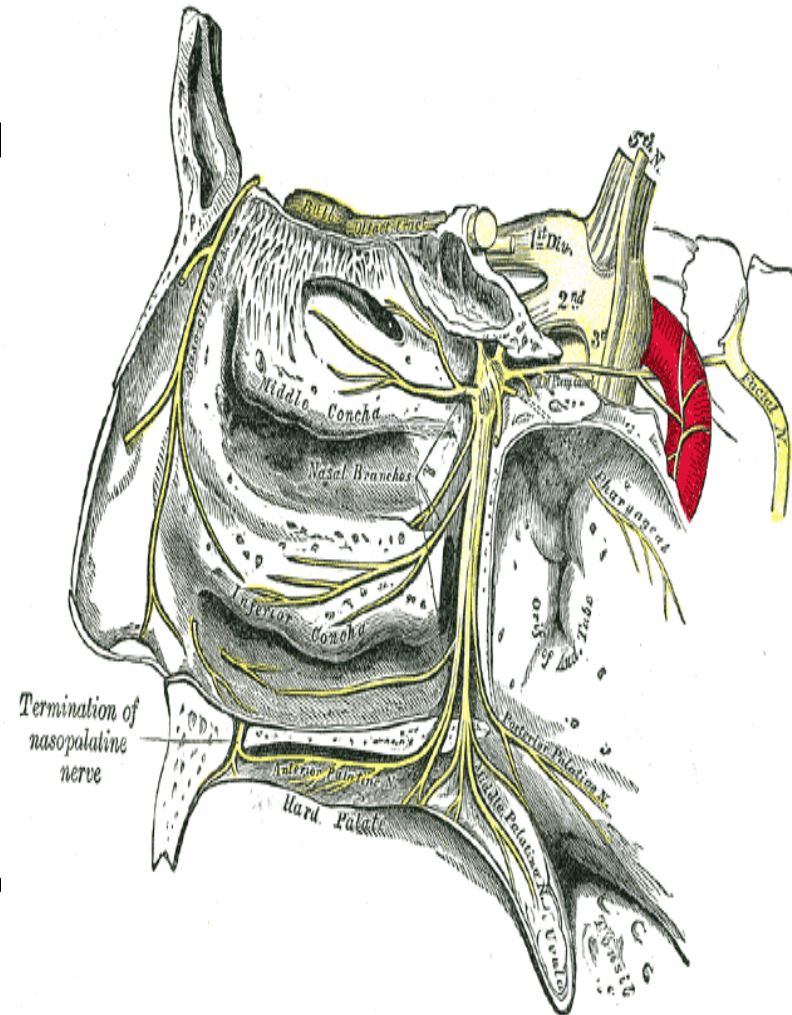


# Orbital branches

- Pass through the inferior orbital fissure
- Supply of the orbital wall (periosteum) and lacrimal gland
- Supply the sphenoidal and ethmoidal sinuses.

# Pharyngeal nerve

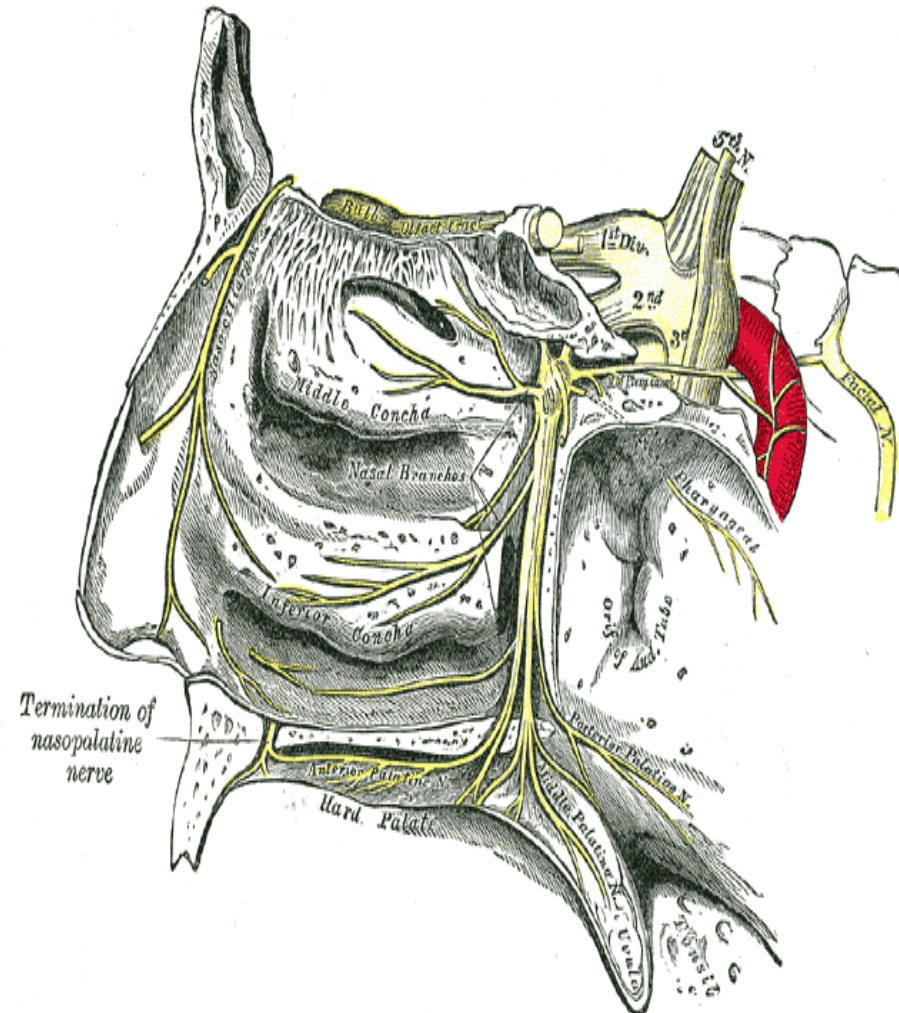
- Passes posteriorly from the pterygopalatine ganglion
- Leaves the fossa through the palatovaginal canal
- Supply the mucosa and glands of the nasopharynx




# Greater and lesser palatine nerves



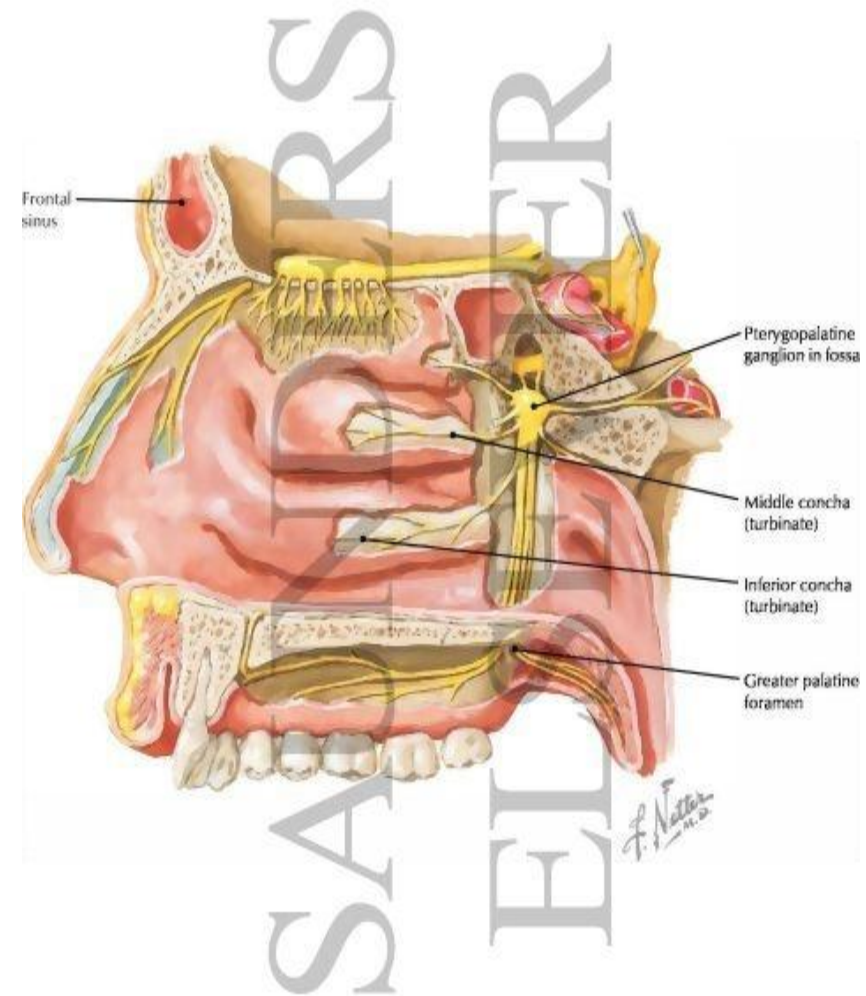
- Pass through the palatine canal
- Enter the oral surface of the palate through the greater and lesser palatine foramina.
- **Lesser palatine (Middle, Post, palatine)** nerve passes posteriorly to supply the soft palate.



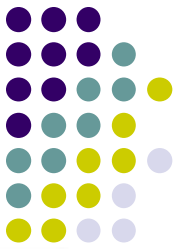# Greater and lesser palatine nerves



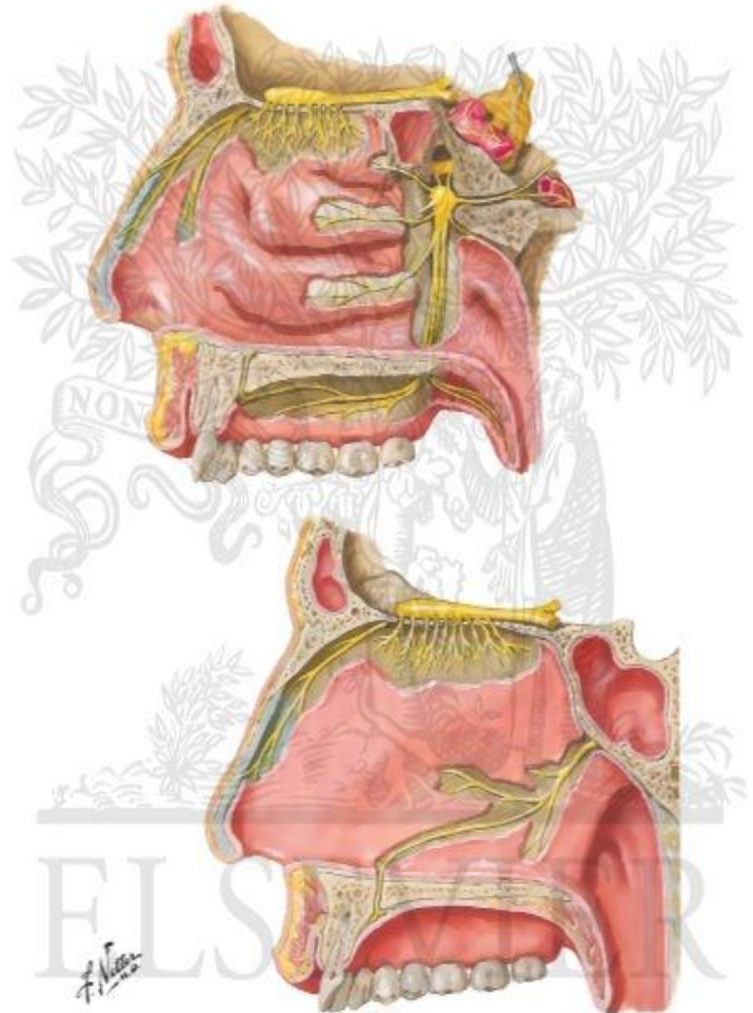
- **The Greater palatine (Ant.palatine)** nerve passes forward on the roof of the oral cavity
- Innervate mucosa and glands of the hard palate and the adjacent gingiva, almost as far forward as the incisor teeth
- Also supply the mucosa over the middle and lower part of the lateral wall of the nasal cavity
- Joins the long sphenopalatine nerve



# Nasal nerves




- Seven in number
- Pass medially through the sphenopalatine foramen to enter the nasal cavity
- **Short sphe-no-palatine** (Post.Sup. Lateral nasal) supply the mucosa of the Post,Sup. quadrant of the nasal cavity.
- The **Nasopalatine nerve (long Sphe-no-palatine)** is the largest of the nasal nerves
- Passes anteriorly grooving down the nasal septum
- Through the incisive canal and fossa in the hard palate
- Supply mucosa, gingiva, and glands adjacent to the incisor teeth.
- Join the greater palatine nerve.






# Maxillary Nerve

---






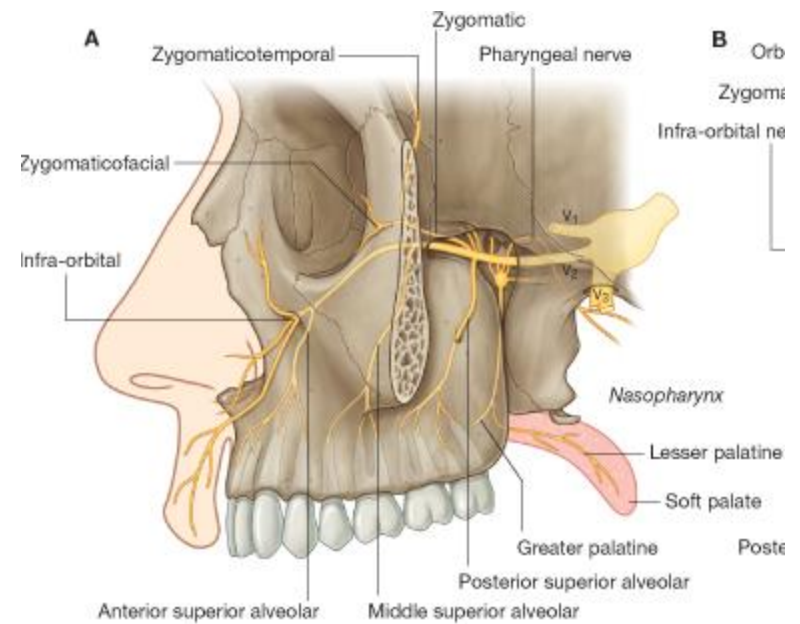
# Maxillary nerve [V2]

- Purely sensory
- Originates from the trigeminal ganglion in the cranial cavity
- Exits the middle cranial fossa, and enters the pterygopalatine fossa through the foramen rotundum
- It terminates as the infra-orbital nerve through the inferior orbital fissure.

# Maxillary nerve



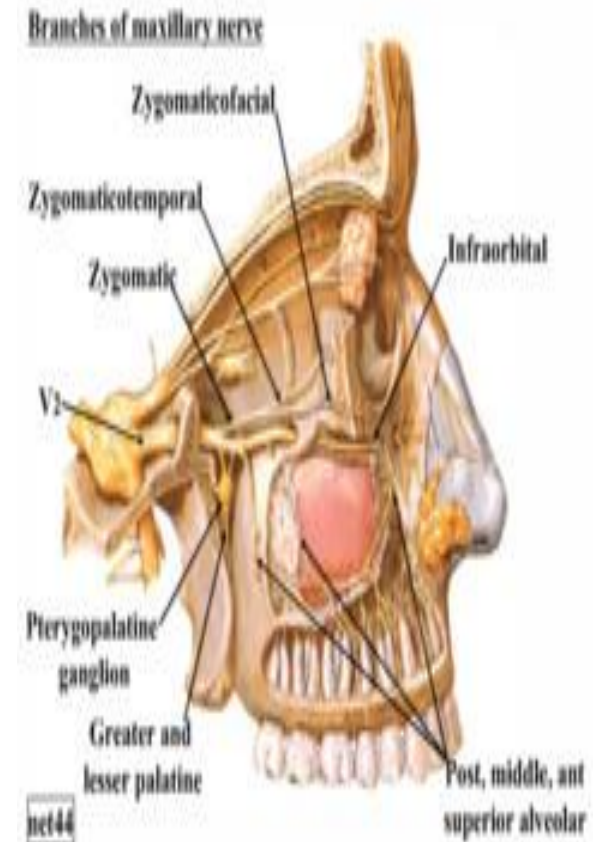
- Branches:
- Meningeal (before it enters the Fossa)
- Two ganglionic branches pass through the pterygopalatine ganglion (Postganglionic parasympathetic fibers and sensory).
- Zygomatic nerve
- Posterior superior alveolar nerve
- Infra-orbital




© Elsevier. Drake et al: Gray's Anatomy for Students - v

# Zygomatic nerve

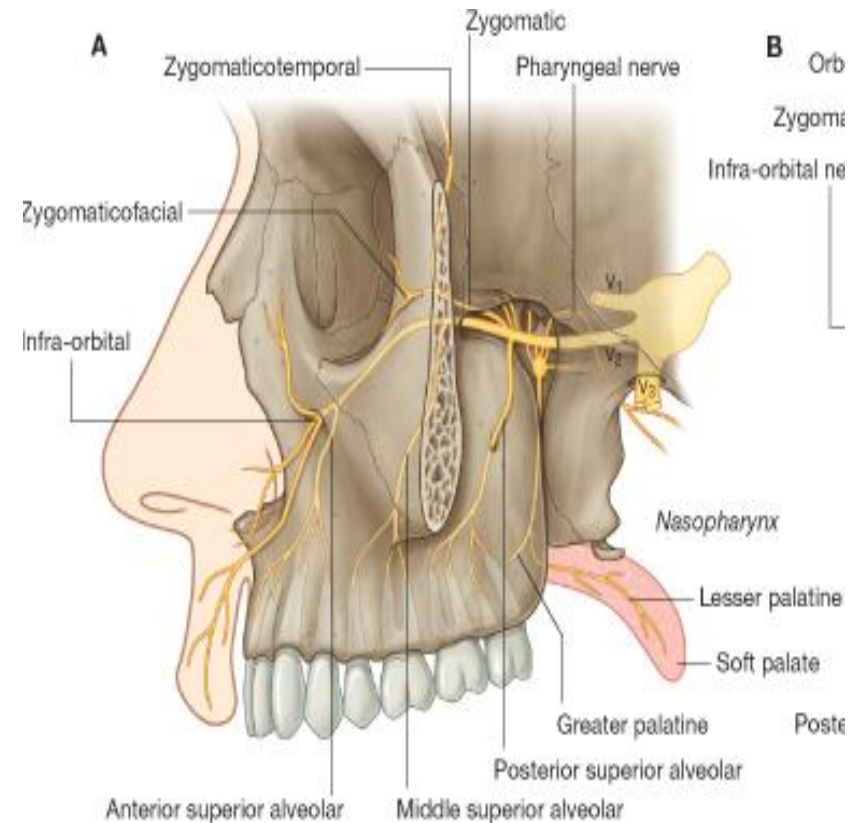
- Originates directly from the maxillary nerve in the pterygopalatine fossa
- Enter the orbit through the inferior orbital fissure
- Divides into zygomaticotemporal and zygomaticofacial branches
- **Zygomaticotemporal branch** enter the temporal fossa and passes superficially to supply skin over the temple
- Carries postganglionic parasympathetic and sympathetic fibers and form a special autonomic nerve to join the lacrimal nerve
- The **Zygomaticofacial branch** opens on the anterolateral surface of the zygomatic bone, and supply the adjacent skin.




# Posterior superior alveolar nerve



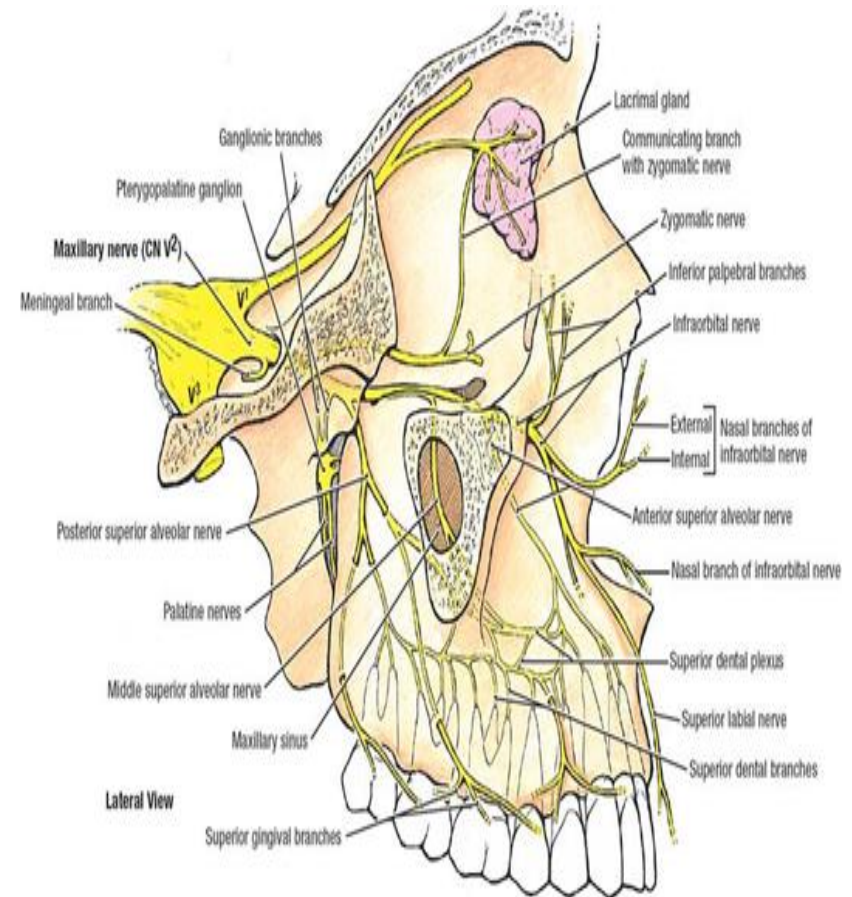
- Passes laterally out of the fossa through the pterygomaxillary fissure
- Enter the posterior surface of the maxilla approximately midway between the last molar tooth and the inferior orbital fissure
- Supplies the molar teeth and adjacent buccal gingivae
- contributes to the supply of the maxillary sinus




# Infra-orbital nerve



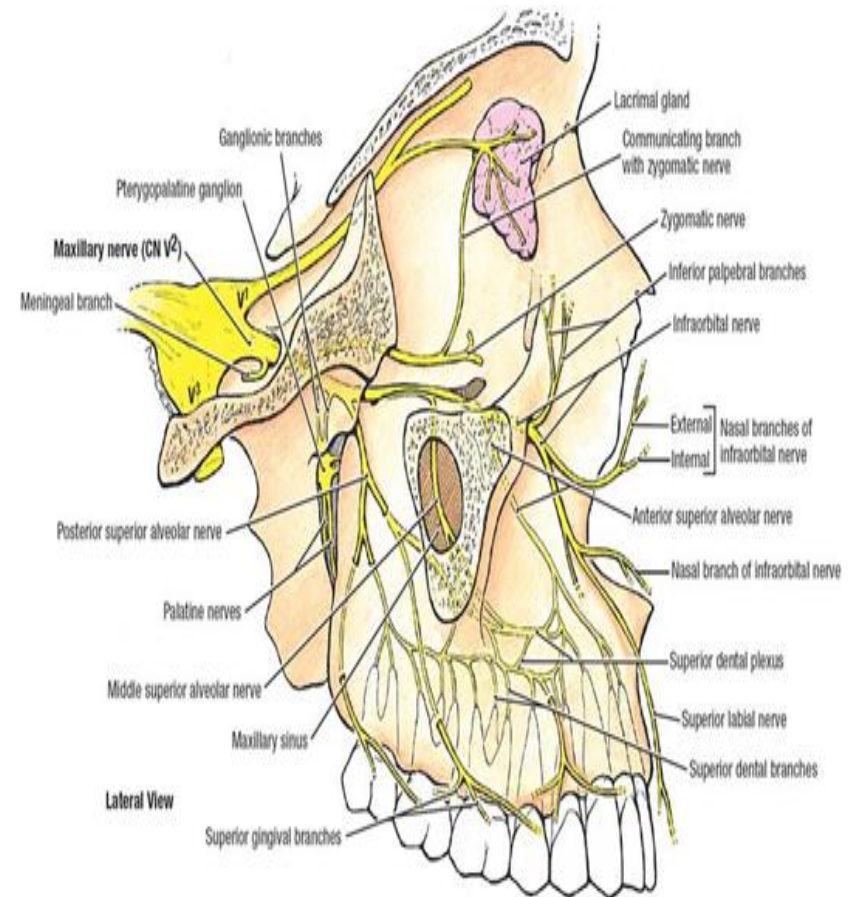
- Anterior continuation of the maxillary nerve
- Leaves the pterygopalatine fossa through the inferior orbital fissure
- First in the **infra-orbital groove** in the floor of the orbit and then continues forward in the **infra-orbital canal**.
- While in the infra-orbital groove and canal, the infra-orbital nerve gives origin to **middle** and **anterior superior alveolar nerves**:
- They Join the **superior alveolar plexus** to supply the upper teeth
- Middle superior alveolar nerve also supplies the maxillary sinus
- Anterior superior alveolar nerve also gives origin to a small nasal branch




# Infra-orbital nerve



- The infra-orbital nerve exits the infra-orbital canal through the **infra-orbital foramen**
- Divides into nasal, palpebral, and superior labial branches
- Nasal branches supply skin over the lateral aspect of the external nose and part of the nasal septum;
- Palpebral branches supply skin of the lower eyelid;
- Superior labial branches supply skin over the cheek and upper lip, and the related oral mucosa.



# Maxillary Nerve and Pterygopalatine ganglion

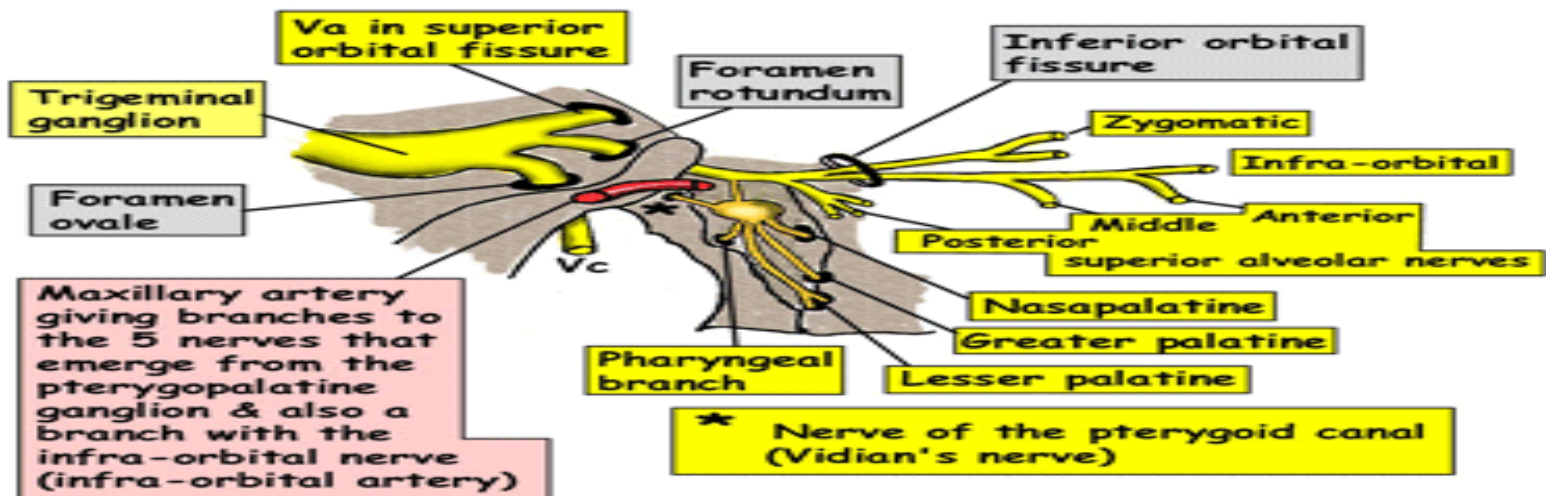


## PTERYGOPALATINE FOSSA 1

Right side of skull cut away to show trigeminal ganglion lying in Meckel's cave and the maxillary division entering the pterygopalatine fossa through foramen rotundum. The nerve of the pterygoid canal is seen entering the pterygopalatine ganglion and connecting to Vb so that sensory fibres can be distributed with the parasympathetic fibres from the ganglion and so that parasympathetics can pass on Vb to be distributed to sinuses and lacrimal gland.

The contents of the pterygopalatine fossa are:


- Terminal branches of the maxillary artery
- Maxillary nerve (Vb) to upper teeth, floor of orbit, face/skin
- Pterygopalatine ganglion for distribution of parasympathetics to nose and palate





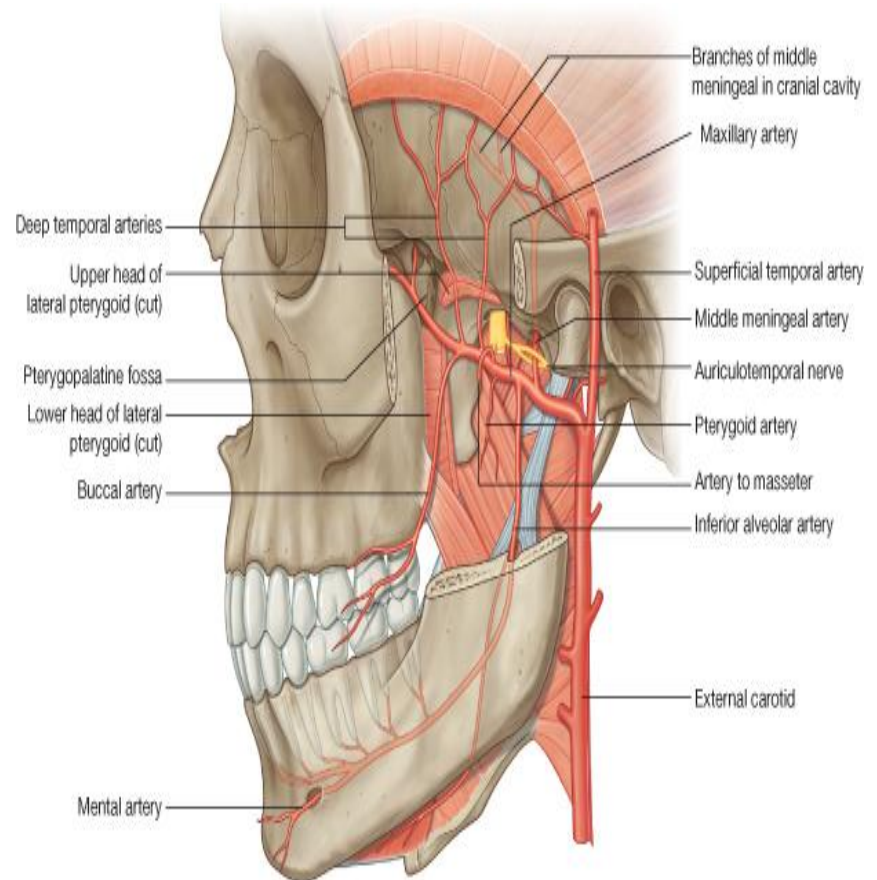
# Maxillary Artery

---




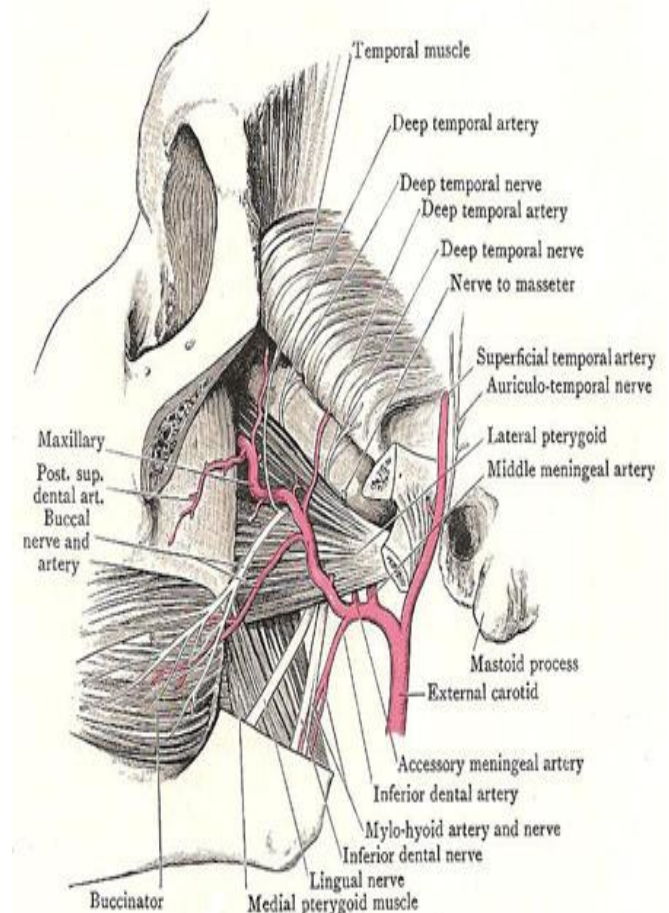
# Maxillary artery

- Major branch of the external carotid artery in the neck
- Originates adjacent to the neck of mandible
- Originates within the substance of the parotid gland
- Passes forward through the infratemporal fossa
- Enters the pterygopalatine fossa through the pterygomaxillary fissure (the third part)



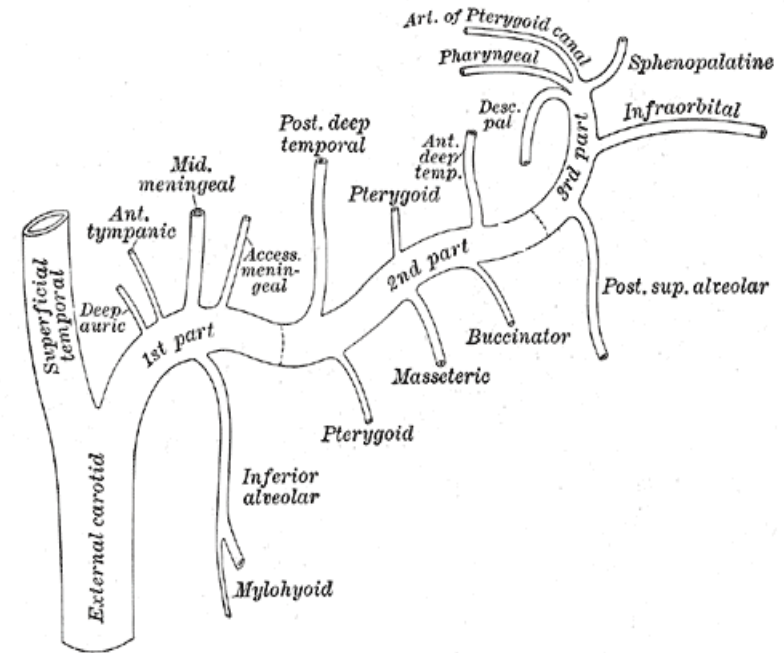
# First part

- The first part of the maxillary artery is the part between the neck of mandible (Lat.) and the sphenomandibular ligament (Med.)
- Also related to the auriculo-temporal nerve (above) and the maxillary vein (below).
- Gives origin to two major branches (the middle meningeal and inferior alveolar arteries)
- Smaller branches (deep auricular, anterior tympanic, and accessory meningeal);




# Second part

- The second part of the maxillary artery the part related to the lateral pterygoid muscle
- Gives origin to deep temporal, masseteric, buccal, and pterygoid branches (muscles of mastication)
- Course with branches of the mandibular nerve



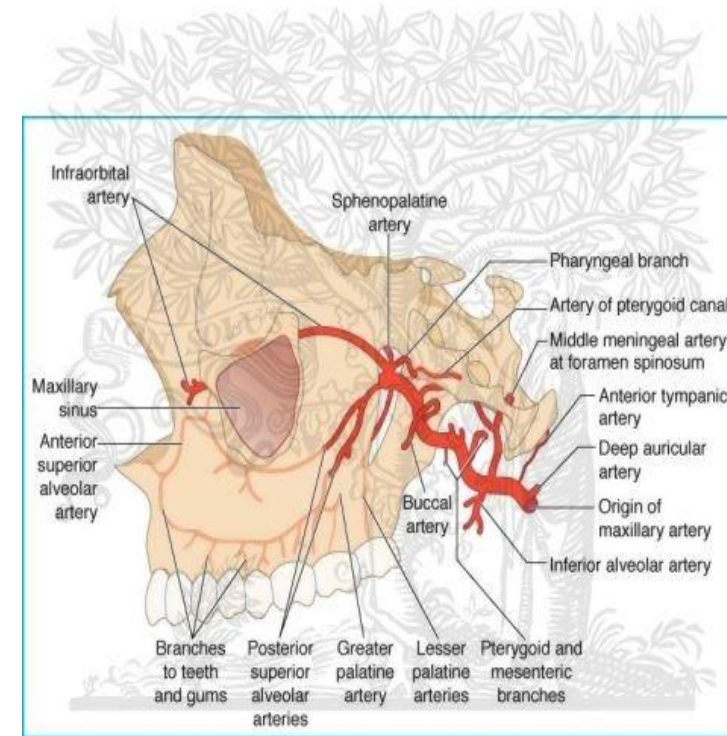
Branches of the maxillary artery  
Gray's Anatomy 1918



# Terminal (3<sup>rd</sup>) part




- In the pterygopalatine fossa
- Anterior to the pterygopalatine ganglion
- Gives origin to branches that accompany branches of the maxillary nerve [V2] and the pterygopalatine ganglion.
- These branches supply much of the nasal cavity, the roof of the oral cavity, and all upper teeth.
- In addition, they contribute to the blood supply of the sinuses, oropharynx, and floor of the orbit.

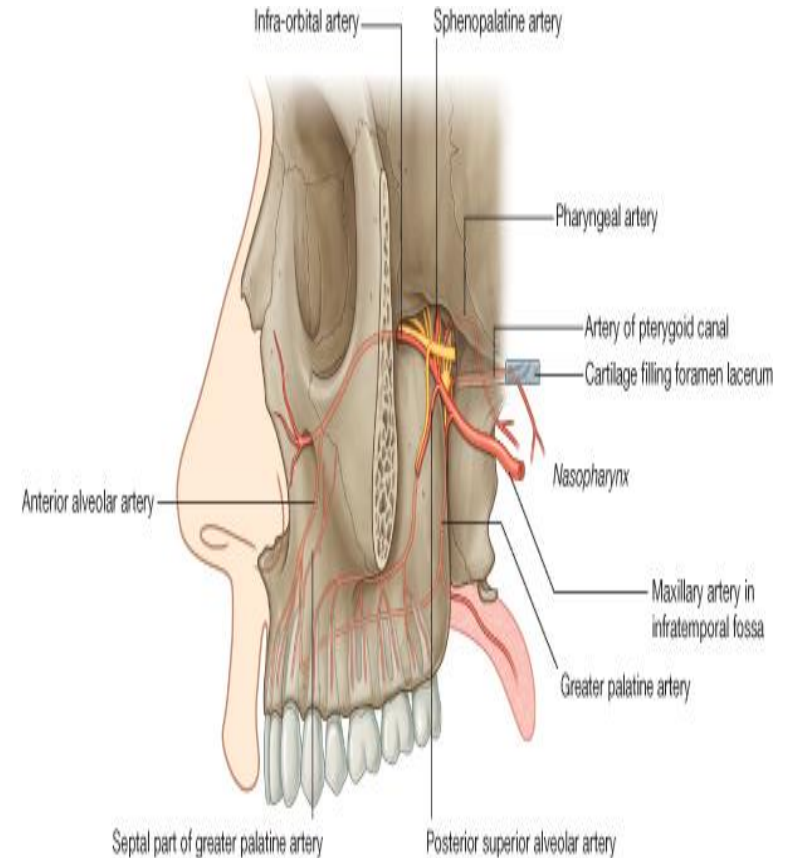


ELSEVIER

# Branches of the 3<sup>rd</sup> part maxillary artery



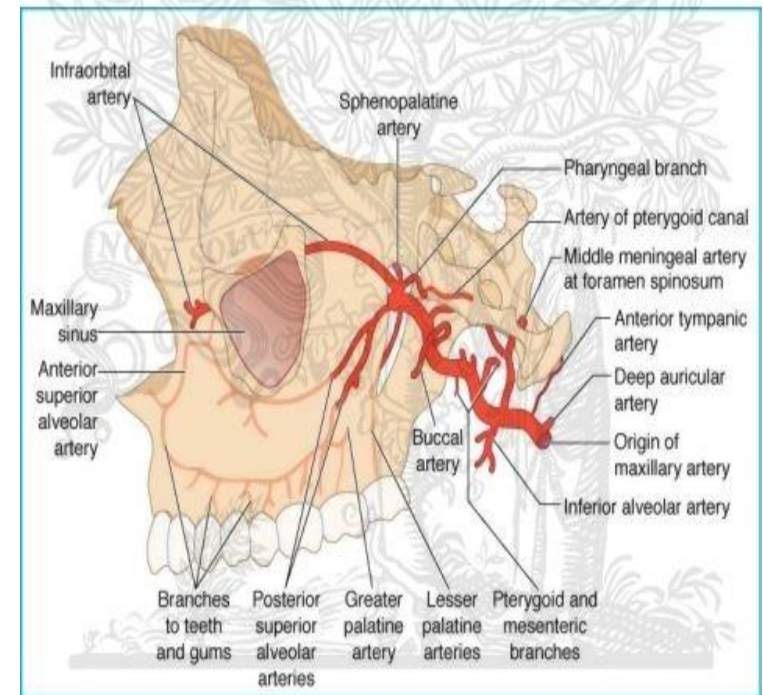
- 1. The posterior superior alveolar,
- 2. Infra-orbital,
- 3. Greater palatine,
- 4. Pharyngeal,
- 5. Sphenopalatine arteries,
- 6. The artery of the pterygoid canal



# Posterior superior alveolar artery




- Originates from the maxillary artery as it passes through the pterygomaxillary fissure
- Meets the posterior superior alveolar nerve,
- Accompanies it through the alveolar foramen on the infratemporal surface of the maxilla
- Supplies the molar and premolar teeth, adjacent gingiva, and the maxillary sinus.



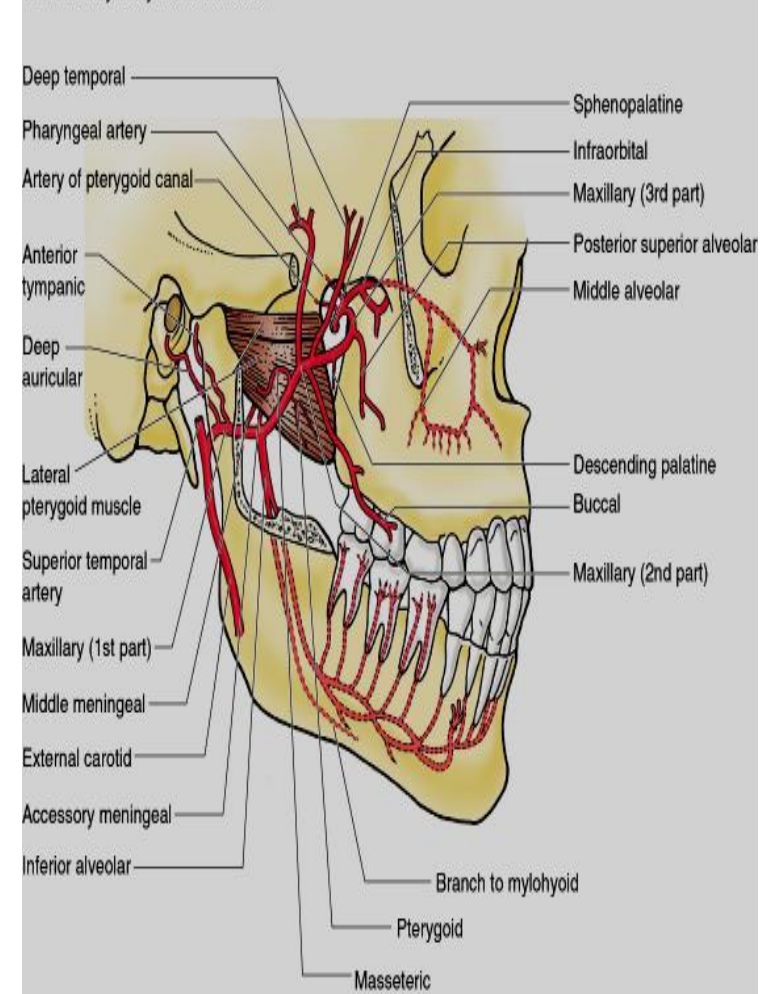
ELSEVIER

# Infra-orbital artery



- Passes forward with the infra-orbital nerve and leaves the pterygopalatine fossa through the inferior orbital fissure
- With the infra-orbital nerve, it lies in the infra-orbital groove and infra-orbital canal
- Emerges through the infra-orbital foramen to supply parts of the face.
- In the orbital canal gives :
  - 1. Branches that contribute to the blood supply of structures near the floor of the orbit-the inferior rectus and inferior oblique muscles, and the lacrimal sac;
  - 2. **Anterior superior alveolar arteries**, which supply the incisor and canine teeth and the maxillary sinus.

7.42. Maxillary artery and its branches.

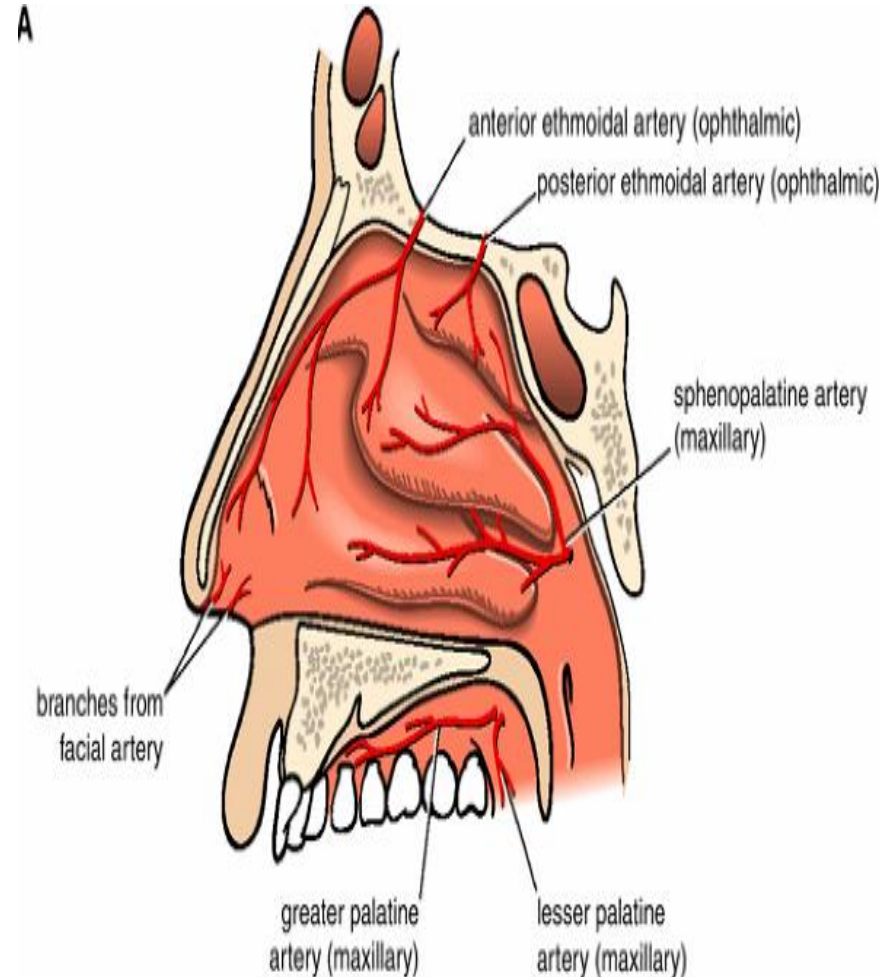





# Greater palatine artery



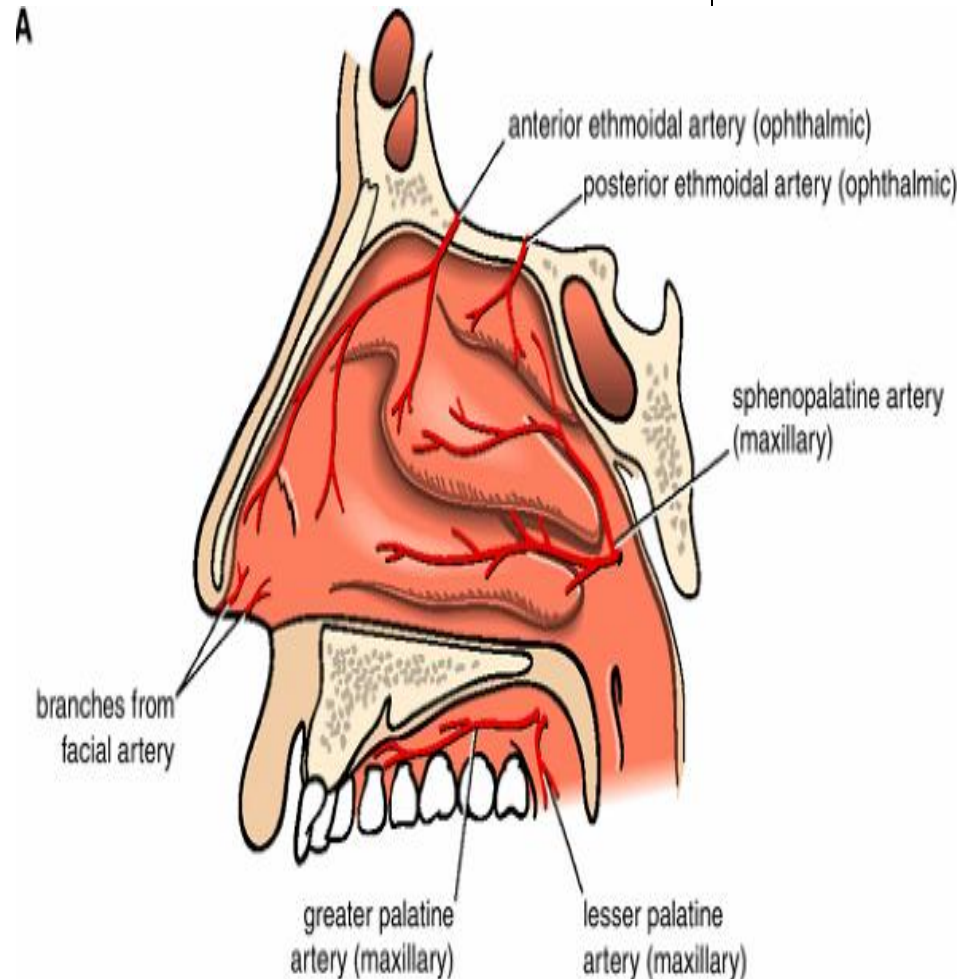
- Travels posteriorly and leaves the pterygopalatine fossa through the palatovaginal canal with the pharyngeal nerve
- Supplies the posterior aspect of the roof of the nasal cavity, the sphenoidal sinus, and the pharyngotympanic tube.




# Sphenopalatine artery



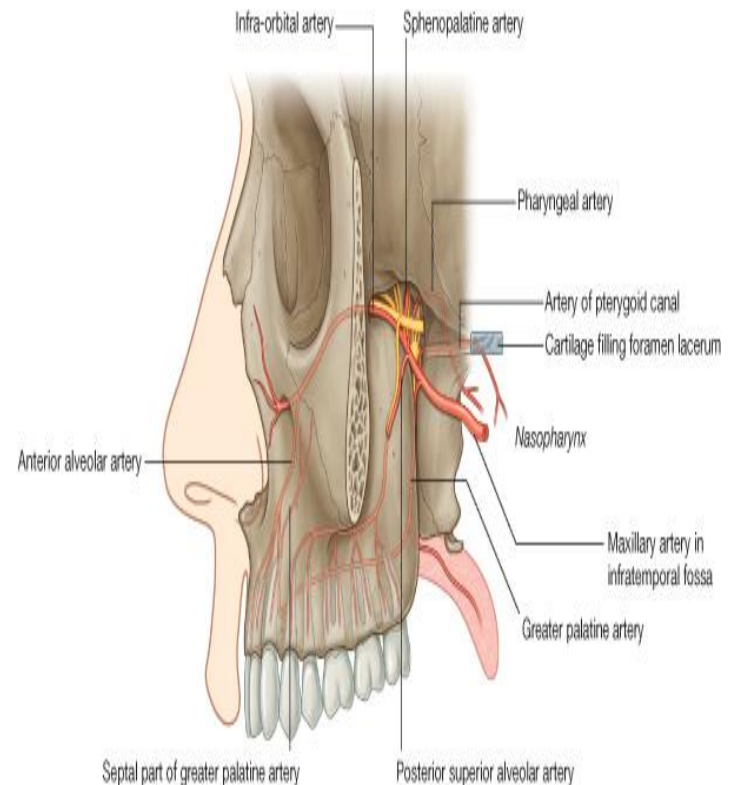
- The terminal branch of the maxillary artery
- Leaves the pterygopalatine fossa medially through the sphenopalatine foramen
- Accompanies the nasal nerves, giving off:
  1. Posterior lateral nasal arteries, which supply the lateral wall of the nasal cavity and contribute to supply of the paranasal sinuses;
  2. Posterior septal branches, which supply the nasal septum-the largest of these branches passes anteriorly down the septum to anastomose with the end of the greater palatine artery.




# Artery of pterygoid canal



- Passes posteriorly into the pterygoid canal and supplies surrounding tissues
- Passing inferiorly through cartilage filling the foramen lacerum,
- Terminates in the mucosa of the nasopharynx.

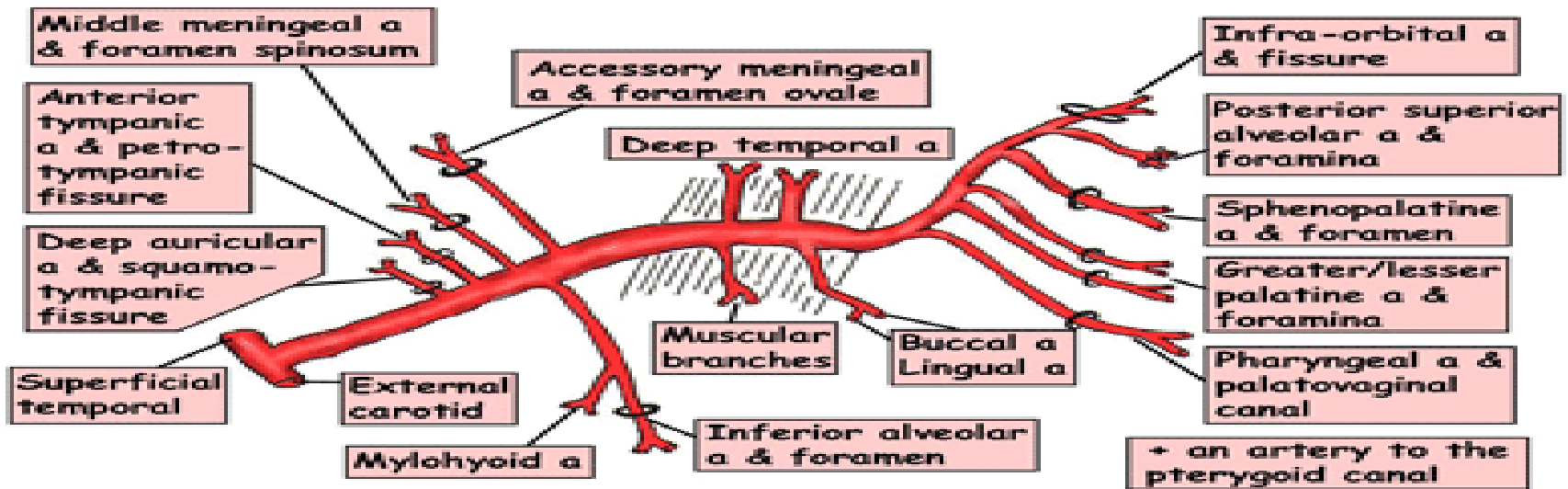


# Maxillary artery



## MAXILLARY ARTERY

In infratemporal fossa, either within or lateral to the superficial head of lateral pterygoid muscle. This muscle is shown below




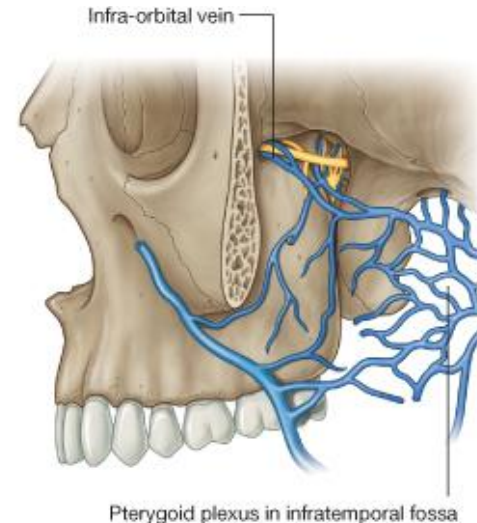
BEFORE LATERAL PTERYGOID 5 BRANCHES INTO BONE

LATERAL OR WITHIN LATERAL PTERYGOID. 4/5 BRANCHES TO SOFT TISSUE

BEYOND LATERAL PTERYGOID 5/6 BRANCHES WITH NERVES

# Veins

- Drain areas supplied by branches of the terminal part of the maxillary artery
- Generally travel with these branches back into the pterygopalatine fossa.
- The veins coalesce in the fossa and then pass laterally through the pterygomaxillary fissure to join the pterygoid plexus of veins in the infratemporal fossa
- The infra-orbital vein, drains the inferior aspect of the orbit,
- May pass directly into the infratemporal fossa, so bypassing the pterygopalatine fossa



# Thank you

