

Pathological Characteristics of Surgically Removed Craniopharyngiomas: Analysis of 131 Cases

G. T. Szeifert, L. Sipos, M. Horváth, M. H. Sarker, O. Major, B. Salomváry, S. Czirják, K. Bálint, F. Slowik, L. Kolonics, and E. Pásztor

National Institute of Neurosurgery, Budapest, Hungary

Summary

Pathological specimens of 131 surgically removed craniopharyngiomas were obtained from the registry of the National Institute of Neurosurgery, Budapest between 1977 and 1991. The cases were reviewed statistically with reference to their gross and microscopic features and clinical characteristics. Macroscopically, 34% of the tumours were cystic, 23% solid and 43% mixed. Histologically, 38% of the cases belonged to the adamantinous group, 26% were squamous epithelial type, 15% were combined, that is expressing the characteristics of both. In 21% of the cases the surgically removed samples did not contain enough material for correct histopathological classification.

There was no recurrence in the group with the squamous epithelial type tumours, while 59% of the adamantinous, and 36% of the combined craniopharyngiomas recurred. The 5-year survival proportion was 73% at the squamous epithelial, 60% in the adamantinous, and 55% at the combined histological types.

Keywords: Craniopharyngioma; histopathology; survival; recurrence.

Introduction

The natural history of craniopharyngiomas is quite controversial. They are histologically benign neoplasms of the sellar region, but even after seemingly total surgical removal frequently recur locally, with a progressively deteriorating clinical course. However, cellular atypia is absent in the tumour and never gives rise to distant metastases, which is the most important pathological criterion of malignancy. They account for approximately 1, 2 to 9% of all intracranial neoplasms in the different series^{3, 7, 11, 15} and are the most common brain tumours of nonglial origin in children⁵.

The macroscopic appearance of the tumour might be cystic, solid and mixed. Histologically, two basic types have been differentiated so far^{1, 4, 6}. One of them

is the epithelial or adult form with nests, papillary structures or trabeculae of squamous epithelial cells embedded in a loose connective tissue stroma. The other is the adamantinous or childhood type, wherein aggregates of stellated cells are surrounded by a layer of single or pseudostratified columnar epithelium resting upon a basement membrane, frequently associated with calcification and keratin nodule formation. The histopathological classification has also clinical importance and prognostic value.

The aim of this study was to investigate the connection between the pathological and clinical characteristics of surgically removed craniopharyngiomas on the basis of 131 cases operated upon at the National Institute of Neurosurgery, Budapest, between 1977 and 1991.

Materials and Methods

Between 1977 and 1991, 131 craniopharyngioma cases were found in the histopathological registry of the National Institute of Neurosurgery, Budapest. A blind study was carried out: the histological sections were evaluated by the first author (Dr. Szeifert) and the clinical details with at least 5 years follow-up were processed by the second author (Dr. Sipos). The histopathological and clinical observations have been separately fed into a computer, and were then compared and analysed by the Smart Software data base (Innovative Software, Inc., 1986) and the Harvard Graphics 2.10 programme (Software Publishing Corp., 1987.). Detailed analysis of clinical signs and symptoms will be published in a subsequent paper.

The biopsy specimens, obtained at surgery, were fixed immediately in 4% formaldehyde and embedded in paraffin. In addition to the routine haematoxylin and eosin staining, immunohistochemical reactions were carried out with and without trypsinisation on 5 µm sections from 33 cases to demonstrate the presence of cytokeratin and vimentin in the tumour cells, using the peroxidase-antiperoxidase

(PAP) technique, as was described previously⁸. The histological slides were evaluated under the light microscope to determine the pathological subtype of the tumour, i.e. squamous epithelial or adamantinous, and for the presence of calcification, keratinization, vimentin and cytokeratin in the tumour cells.

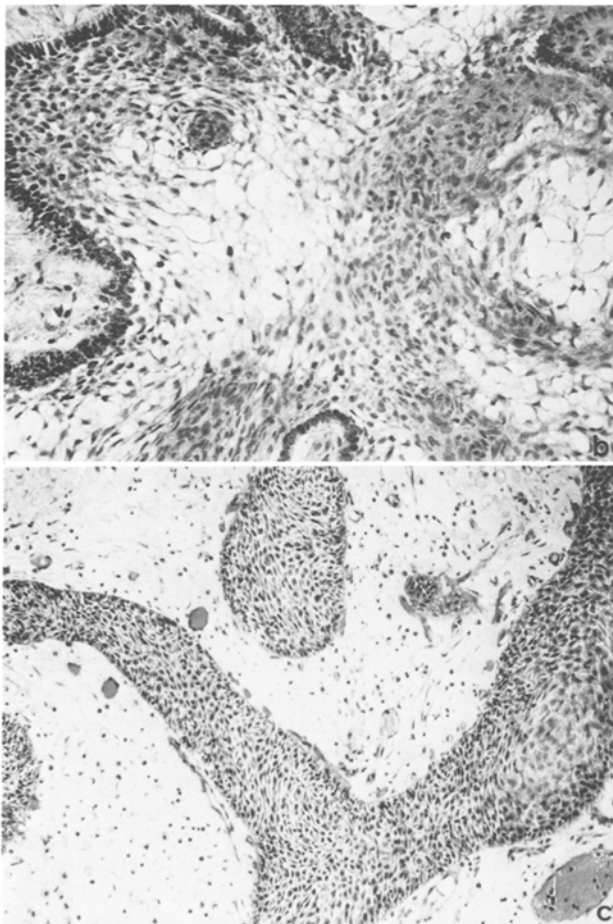
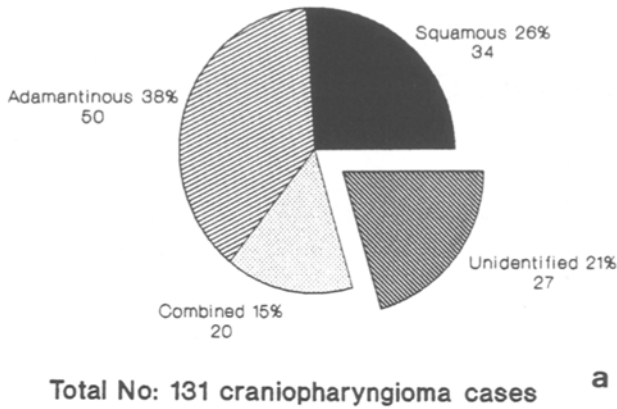


Fig. 1. (a) Distribution of the histological subtypes (in the National Institute of Neurosurgery, 1977–1991). (b) Adamantinous stellate epithelial cells surrounded by pseudostratified columnar cells (H & E, 250 ×). (c) Nests and trabeculae of squamous epithelial cells embedded in connective tissue stroma (H & E, 250 ×)

Results

Histopathology

Histologically three groups were differentiated in this series (Fig. 1 a): 38% of the cases expressed the

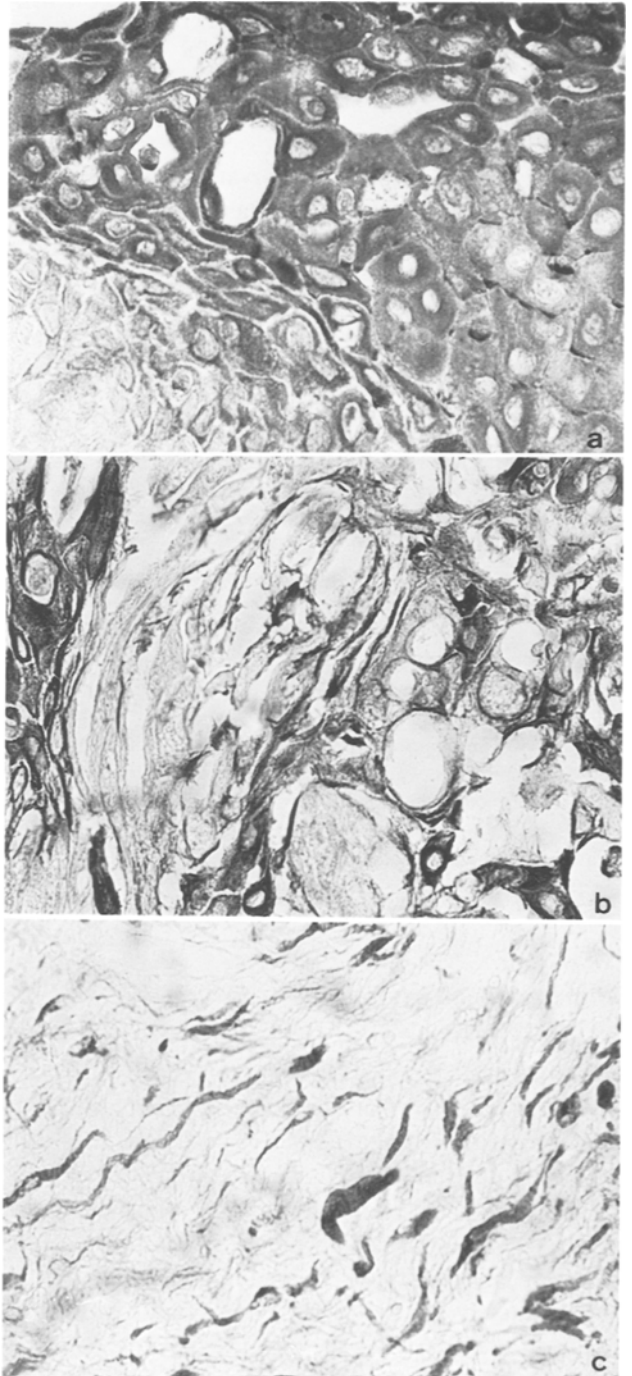


Fig. 2. (a) Cytokeratin positivity in the squamous epithelial cells (PAP-technique, 400 ×). (b) Cytokeratin positivity in the adamantinous tumour cells (PAP-technique, 400). (c) Vimentin demonstration in the stromal connective tissue cells (PAP-technique, 400)

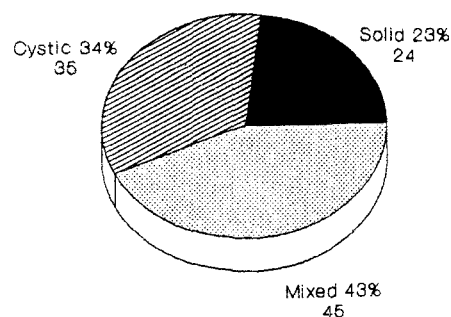
adamantinous characteristics (Fig. 1 b) often associated with focal calcification, keratin nodule formation and degenerative changes in its stroma. The squamous epithelial pattern appeared in 26% of the samples (Fig. 1 c). We have separated a third, so called “combined” histological category at 15% of the cases, in which both squamous epithelial and adamantinous features occurred in the same specimen. In 21% of the cases the surgical biopsy sample did not contain enough material for the correct histopathological classification, therefore these 27 instances were designated as “unidentifiable”, and excluded from the further processing.

Immunohistochemistry

The immunohistochemical reactions revealed cytokeratin positivity in the tumour cells of both the squamous epithelial and adamantinous types (Fig. 2 a, b), justifying their epithelial nature, and the stromal cells expressed vimentin suggesting their mesenchymal origin (Fig. 2 c).

Macroscopic Findings

The macroscopic appearance of the remaining evaluable 104 cases was solid in 23%, cystic in 34% and mixed in 43% (Fig. 3). In the great majority of the adamantinous cases (76%) calcification occurred (Fig. 4 a), and the 3 dimensional CT reconstruction can help to judge the extension and configuration of the lesion (Fig. 4 b). There was no calcification in the squamous epithelial group. A cystic component was detected in the 56% of the squamous epithelial, 50% of the adamantinous and 65% of the combined histological band (Fig. 5).



Total No: 104 cases

Fig. 3. Macroscopic appearance, CT findings distribution of the macroscopic types

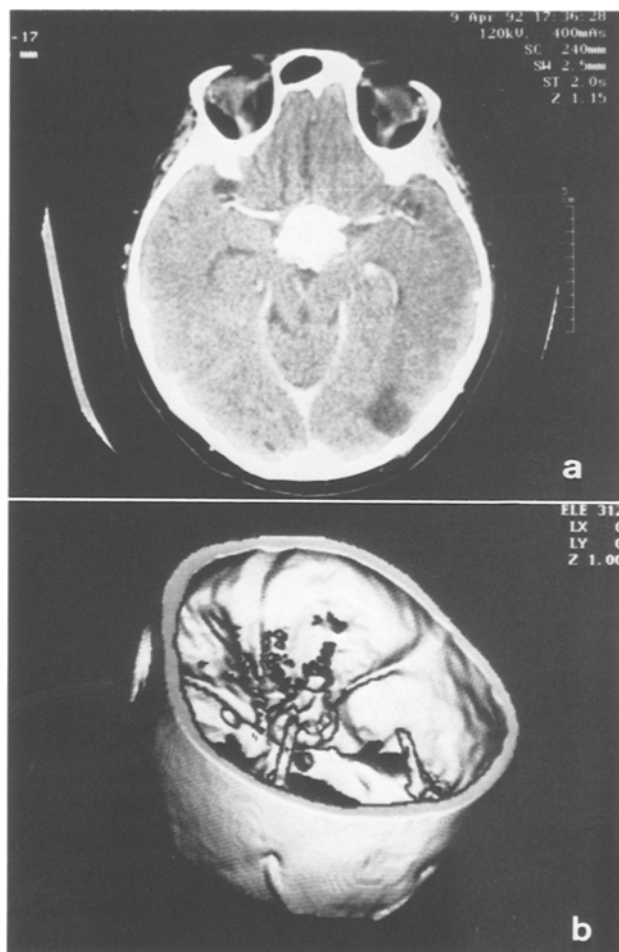


Fig. 4. (a) CT-scan demonstrates calcified tumour in the sellar region. (b) The 3 D CT reconstruction of the calcified lesion

Age Distribution

Generally, 36% of the tumours presented in childhood, while the 64% in adults. The squamous epithelial pattern appeared most frequently around the age of 50 (Fig. 6 a), the adamantinous in childhood (Fig. 6 b), whereas the combined picture equally in children and adults (Fig. 6 c).

Follow-up Dates

Between 1977 and 1986, 81 patients were operated on with craniopharyngiomas in our Institute. Histologically, 11 biopsy samples were unidentifiable, 15 cases were lost to follow-up, therefore 55 patients underwent examinations at follow-up. There was no recurrence in the squamous epithelial group, but on the other hand 59% of the adamantinous and 36% of the combined histological cases recurred (Fig. 7). The

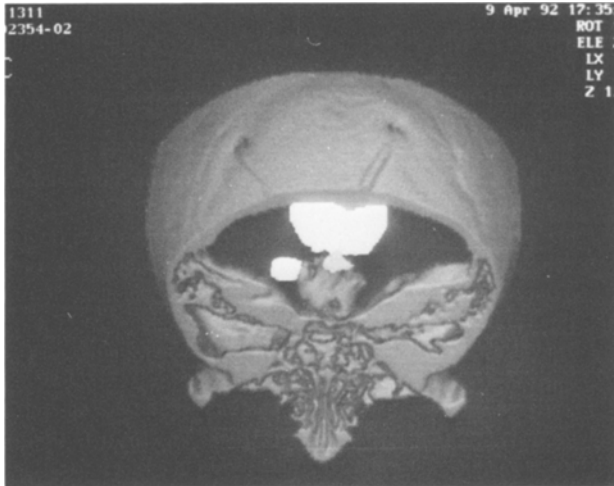

Fig. 5. 3D CT reconstruction of a multicystic case

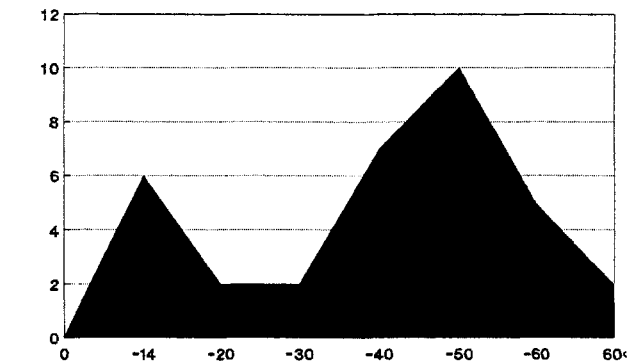
5-year survival was most favourable (73% in the squamous epithelial group, and the least beneficial (55%) in the combined histological population (Fig. 8).

Discussion

Since 1910, when the first craniopharyngioma case was operated on by Dean Lewis — professor of surgery at John Hopkins University — controversy has surrounded this peculiar tumour. Debates arose regarding its developmental origin, natural history, operability, radio-, and chemotherapy¹⁰. The modern neuro-imaging techniques (CT, MRI) passed over rapid development in characterization and pre-operative differentiation from other sellar pathological processes, thus making possible planning of specific intervention².

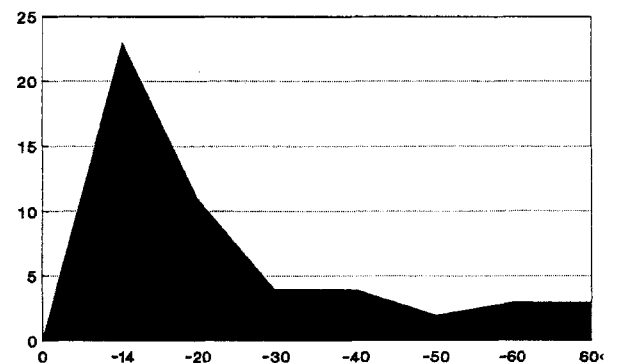
Although pathological characterization has also great importance and prognostic value, the histological classification is still being debated. Kahn *et al.*⁶ separated squamous epithelial and adamantinous types of craniopharyngiomas, whereas Petito *et al.*⁹ have questioned the validity of such a distinction, and described transitional forms between these types. It was supported by the tissue-culture studies of Yoshida *et al.*¹⁴, demonstrating that tumour cells with both secretory and squamous epithelial features exist in the same craniopharyngioma. Contrary to these findings Giangaspero *et al.*⁴, and more recently, Adamson *et al.*¹ have supplied further evidence for the two distinct variants.

The aim of this study was to investigate the correlation between the histopathological types and clinical outcome of craniopharyngiomas. In the presented



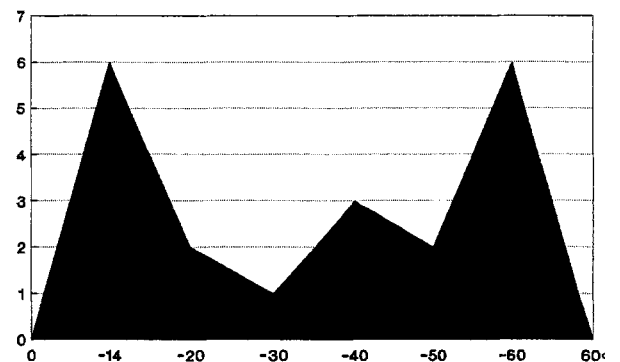
Total No: 34 cases/15 years

a



Total No: 50 cases/15 years

b

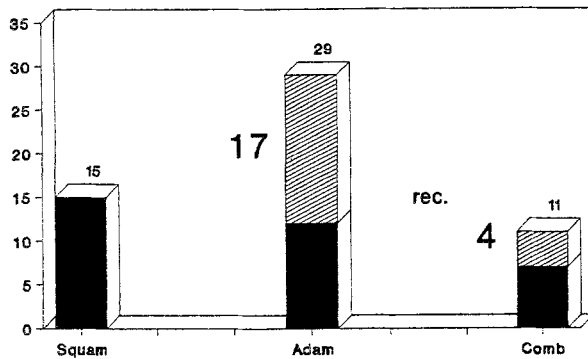


Total No: 20 cases/15 years

c

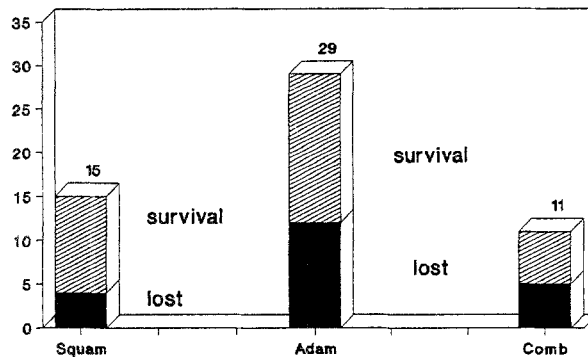
Fig. 6. (a) Age distribution of the squamous epithelial type. (b) Age distribution of the adamantinous type. (c) Age distribution of the combined type

material 3 groups were differentiated: 1) the squamous epithelial type with the best survival rate, and without any recurrence after total surgical removal of the tumour; 2) the adamantinous pattern with a worse survival and the highest recurrence; 3) and the combined histological category expressing the worst clinical outcome with a moderate recurrence tendency.



More than 5-years follow up

Fig. 7. Correlation of histological types and recurrence



More than 5-years follow up

Fig. 8. Correlation of survival and histological types

The presented pathological findings reflect the hypothesis that lesions originating from remnants of Rathke's pouch constitute a spectrum of developmental disorders, ranging from the simplest form – the single cell lined Rathke's cleft cyst – to the most complex pattern, designated as craniopharyngioma¹⁴. Concerning the pathogenesis, our previous mucinohistochemical and electron-microscopical investigations revealed secretory activity in the tumour¹², and more recently immunohistochemical investigations demonstrated positivity for pituitary hormones in scattered tumour cell groups¹³. These findings support, that craniopharyngiomas originate in the remnants of Rathke's pouch.

Considering the results of the study presented here we suggest intra-operative biopsy and histological investigation during surgery of craniopharyngiomas. The

pathological classification of the tumour can influence the outcome of the operation. Noting the high recurrence rate and unfavourable prognosis of the adamantinous type, in our opinion therefore total removal of these tumours is not absolutely necessary in complicated cases.

References

1. Adamson TE, Wiestler OD, Kleihues P, Yaşargil MG (1990) Correlation of clinical and pathological features in surgically treated craniopharyngiomas. *J Neurosurg* 73: 12–17
2. Bognár L, Szeifert GT, Fedorcsák I, Pásztor E (1992) Abscess formation in Rathke's cleft cyst. *Acta Neurochir (Wien)* 117:70–72
3. Burger PC, Vogel FS (1982) *Surgical pathology of nervous system and its coverings*, 2nd Ed. Wiley, New York, pp 511–525
4. Giangaspero F, Osborne DR, Burger PC, Stein RB (1984) Suprasellar papillary squamous epithelioma ("papillary craniopharyngioma"). *Am J Surg Pathol* 8: 57–64
5. Hoffman HJ, De Silva M, Humphreys RP, Drake JM, Smith ML, Blaser SI (1992) Aggressive surgical management of craniopharyngiomas in children. *J Neurosurg* 76: 47–52
6. Kahn EA, Gosch HH, Seeger JF, Hicks SP (1973) Forty-five years experience with the craniopharyngiomas. *Surg Neurol* 1: 5–12
7. Matson DD (1969) *Neurosurgery of infancy and childhood*, 2nd Ed. Thomas, Springfield, Ill, p 545
8. Nemes Z, Thomázy V, Szeifert GT (1983) Demonstration of light chain monotypia in B-cell non-Hodgkin's lymphomas using unfixed freeze-dried and formalin fixed trypsinised paraffin sections. *J Clin Pathol* 36: 883–893
9. Petito CK, De Girolamo U, Earle KM (1976) Craniopharyngiomas. A clinical and pathological review. *Cancer* 37: 1944–1952
10. Raimondi JA (1991) Le craniopharyngiome de l'enfant. *Neurochirurgie* 37 [Suppl 1]: 11
11. Russel DS, Rubinstein LJ (1971) *Pathology of tumours of the nervous system*, 3rd Ed. Williams and Wilkins, Baltimore, p 19
12. Szeifert GT, Julow J, Szabolcsi M, Slowik F, Bálint K, Pásztor E (1991) Secretory component of cystic craniopharyngiomas: a mucino-histochemical and electron-microscopic study. *Surg Neurol* 36: 286–293
13. Szeifert GT, Pásztor E (1993) Could craniopharyngiomas produce pituitary hormones? *Neurol Res* 15: 68–69
14. Yoshida J, Kobayashi T, Kageyama N, Kanzaki M (1977) Symptomatic Rathke's cleft cyst. Morphological study with light and electron microscopy and tissue culture. *J Neurosurg* 47: 451–458
15. Zülch K (1986) *Brain tumors. Their biology and pathology*, 3rd Ed. Springer, Wien New York

Correspondence: G. T. Szeifert, M.D., National Institute of Neurosurgery, Amereikai u. 57, H-1145 Budapest, Hungary.