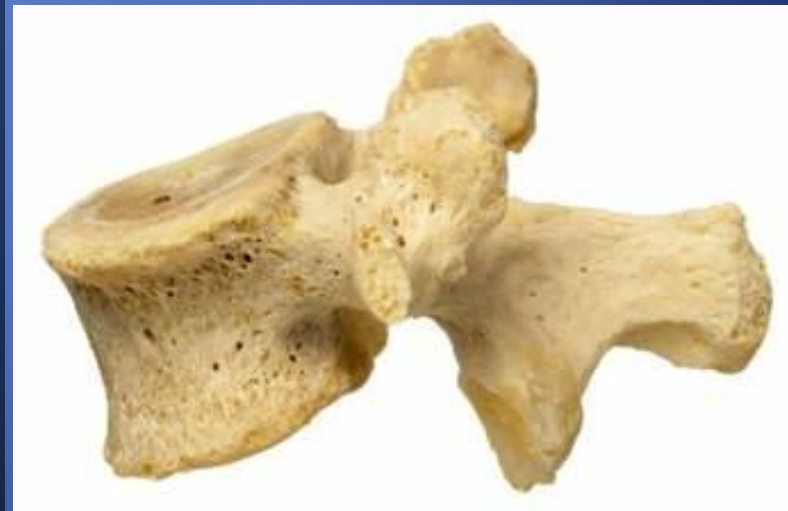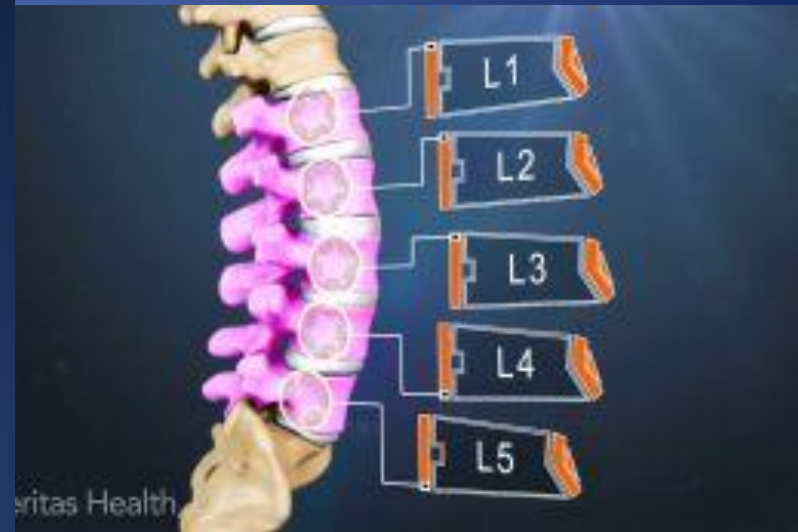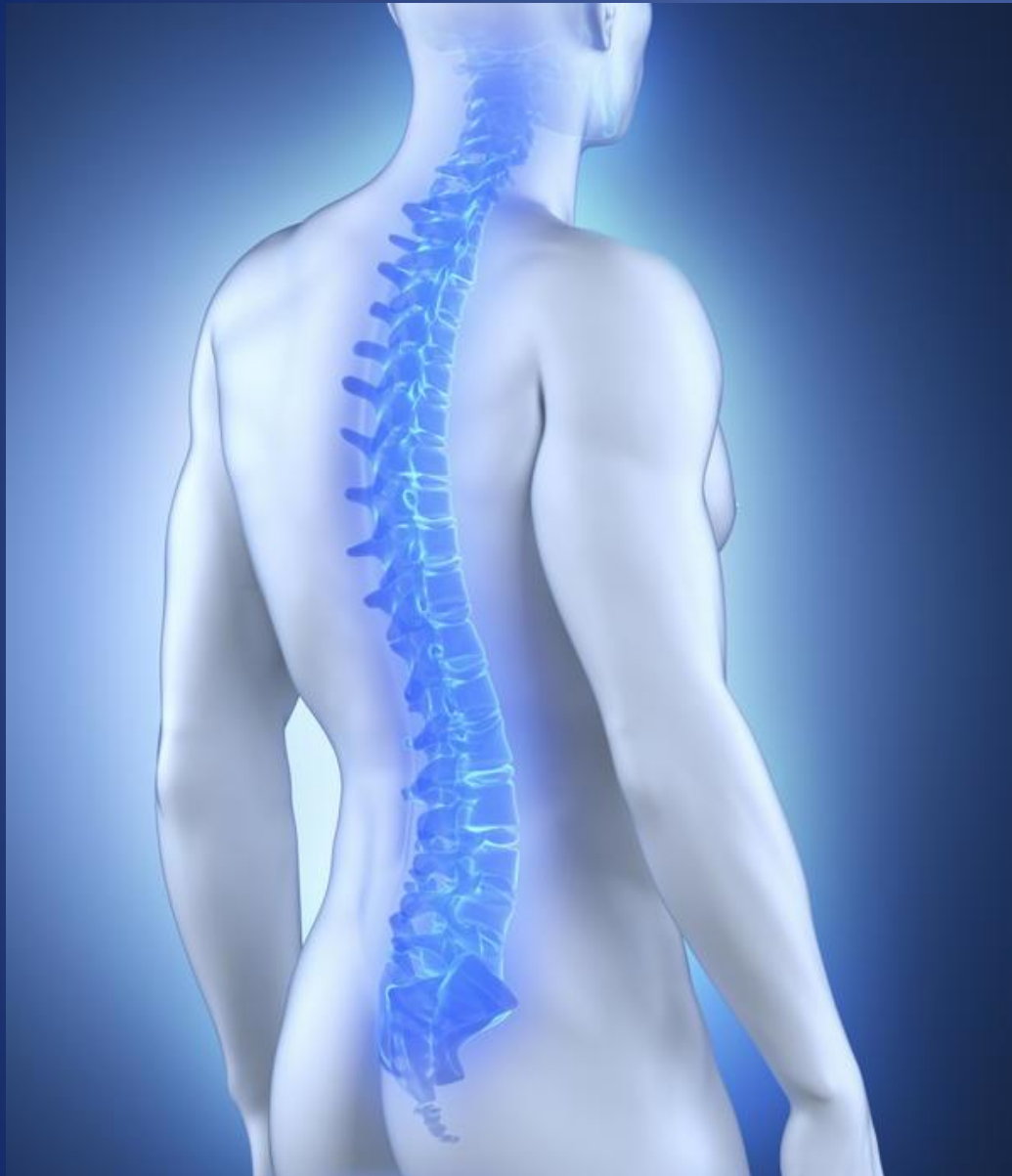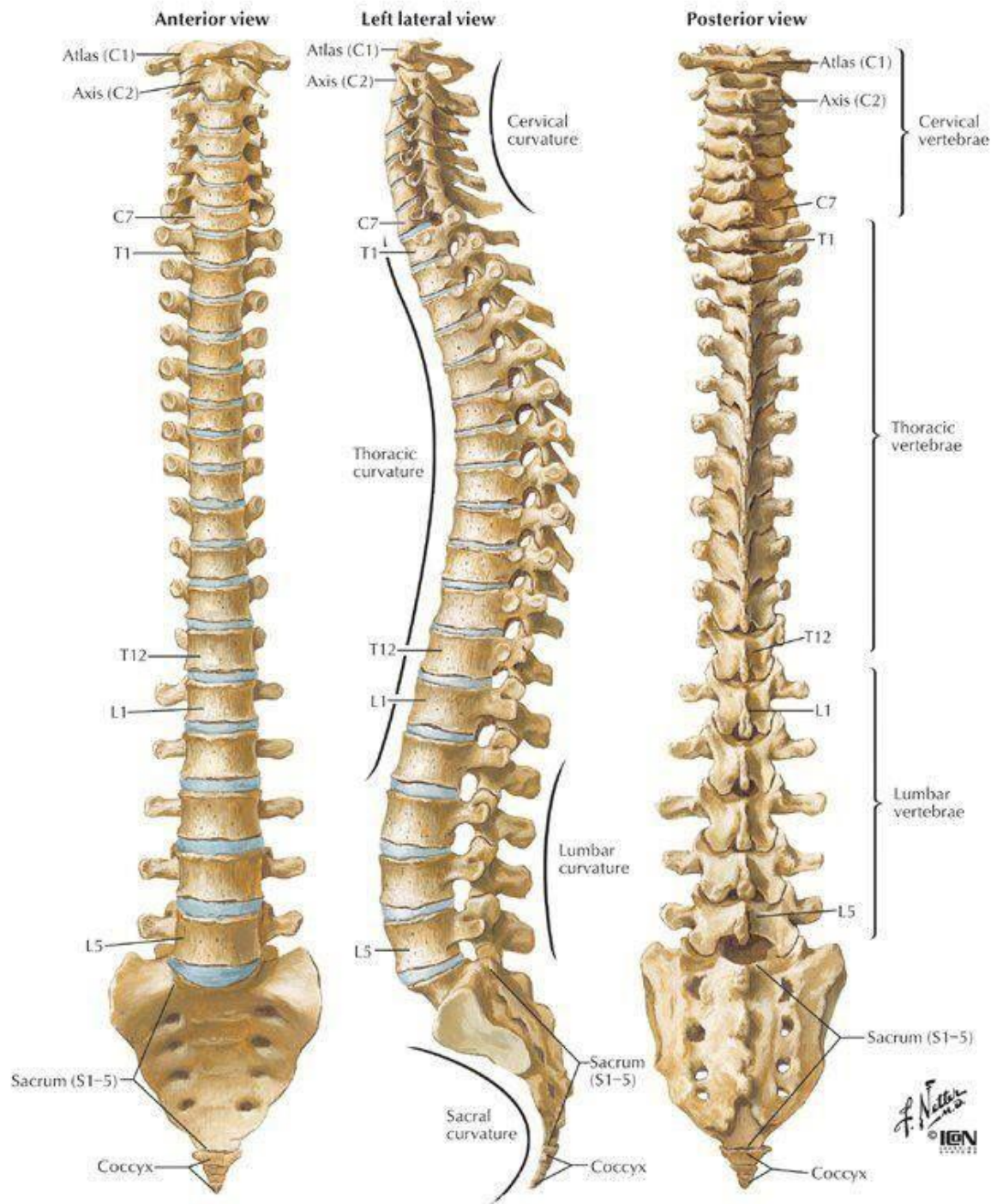


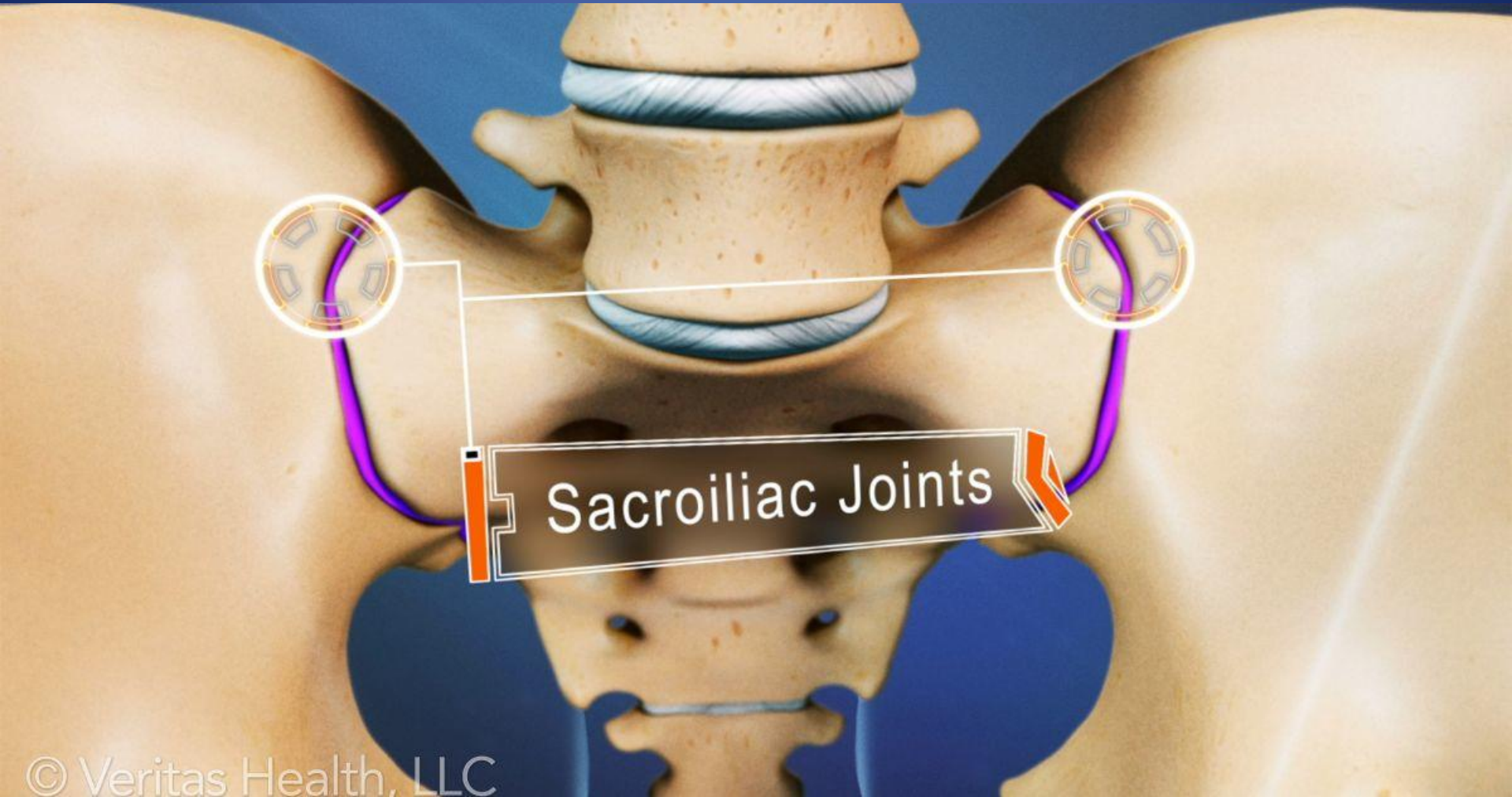
ΕΦΗΡΜΟΣΜΕΝΗ
ΝΕΥΡΟΑΝΑΤΟΜΙΑ Ι

ΟΣΦΥΙΚΗ ΜΟΙΡΑ ΣΣ

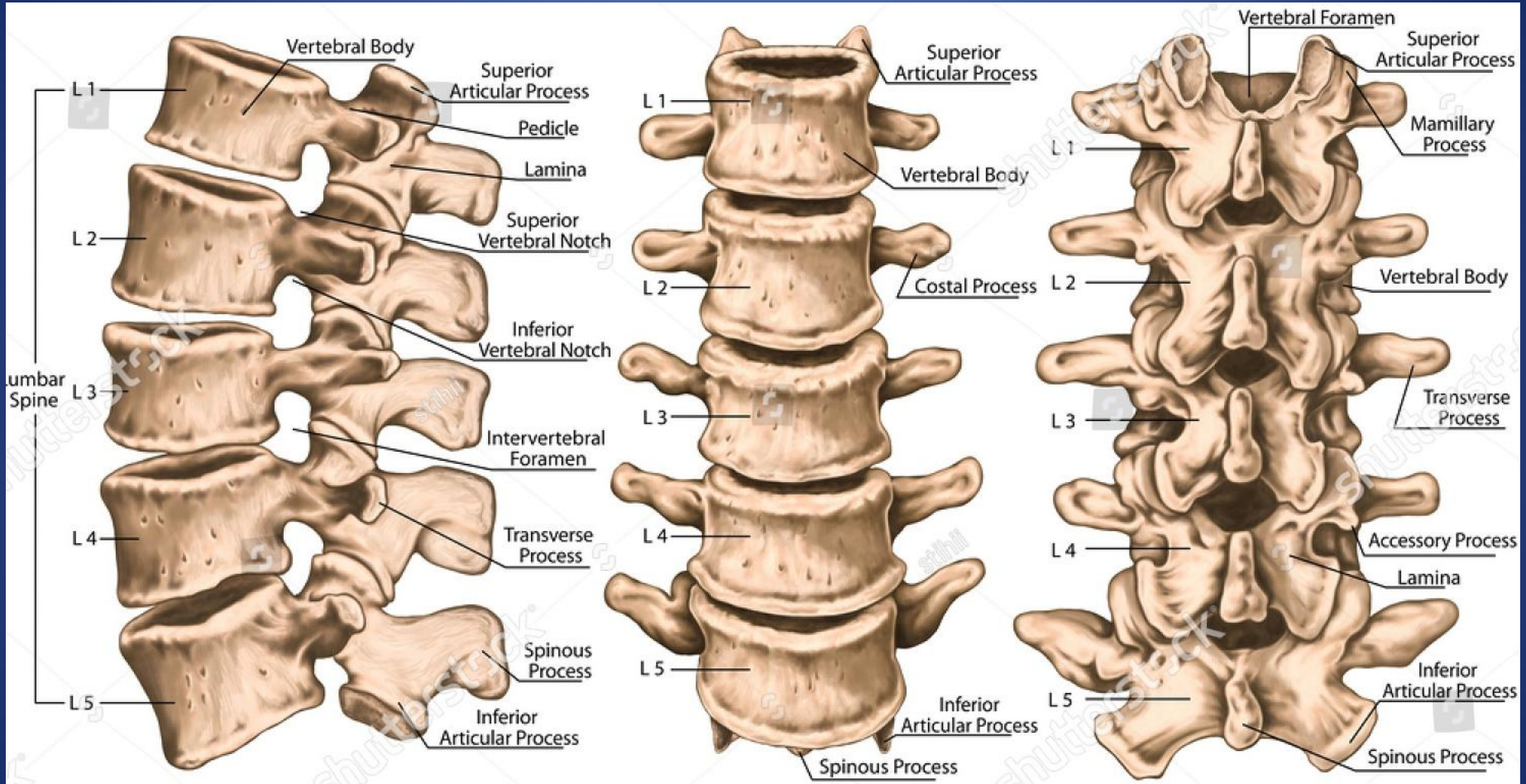
ΙΩΑΝΝΗΣ ΜΑΓΡΑΣ
ΝΕΥΡΟΧΕΙΡΟΥΡΓΟΣ
ΑΝΑΠΛ. ΚΑΘΗΓΗΤΗΣ ΑΠΘ



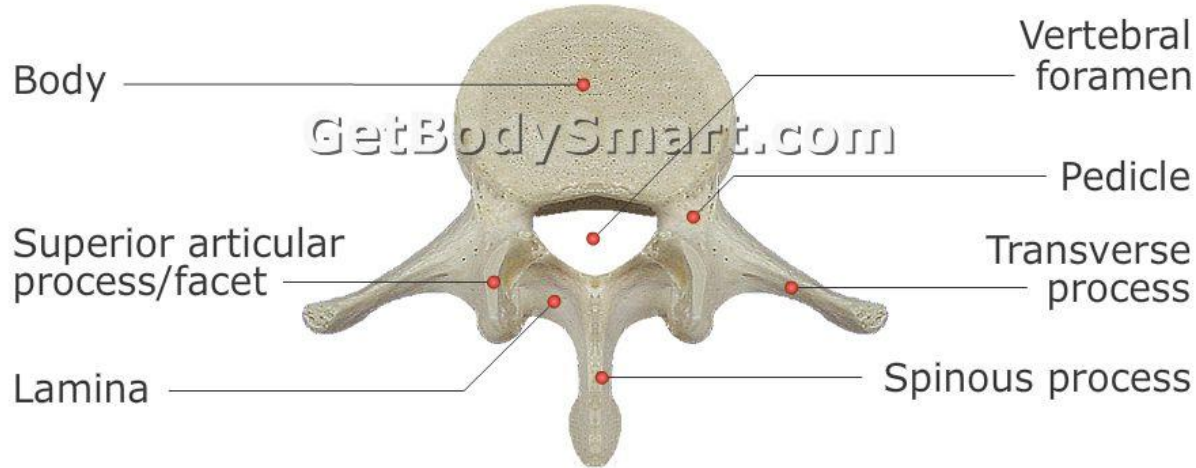




Sacroiliac Joints



Superior View

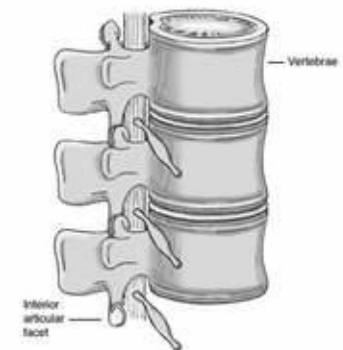
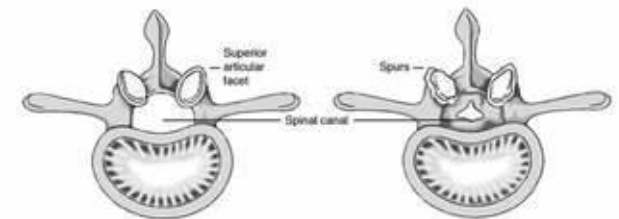
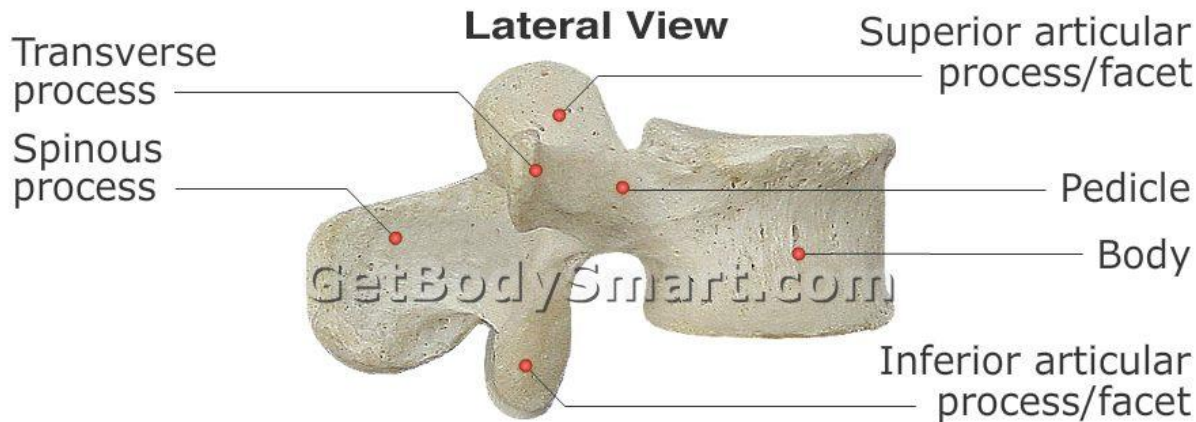


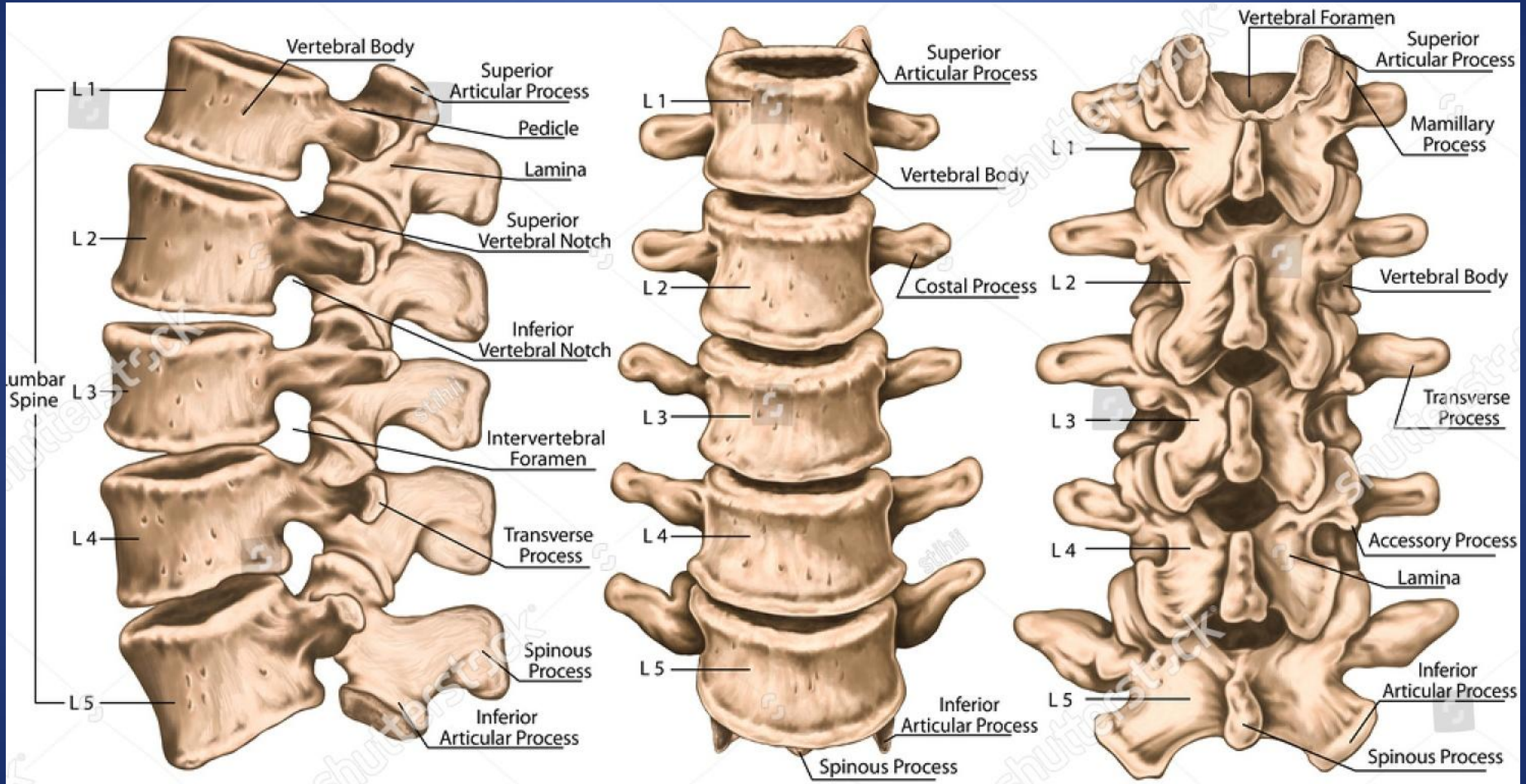
Φυσιολογική διάμετρος >13 mm

Κατώτερα φυσιολογικά όρια 10 and 13 mm

Στένωση <10 mm

Lateral View





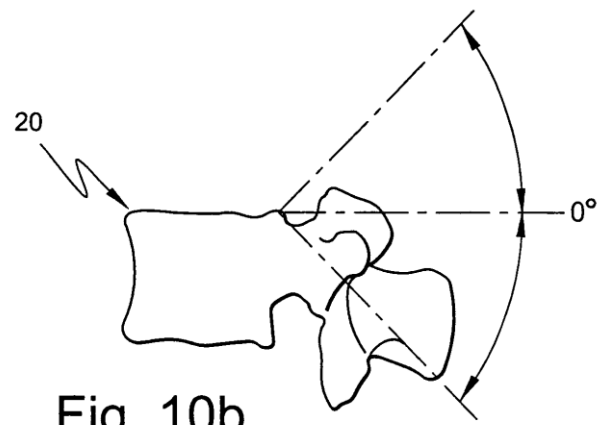


Fig. 10b

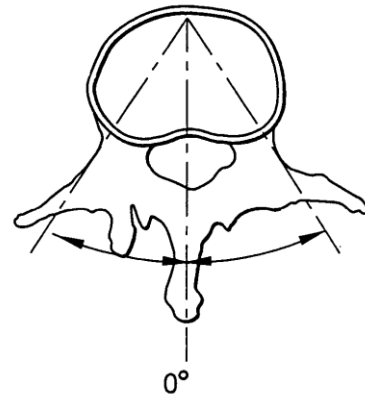


Fig. 10c

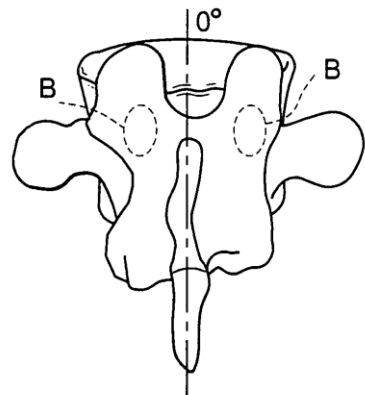
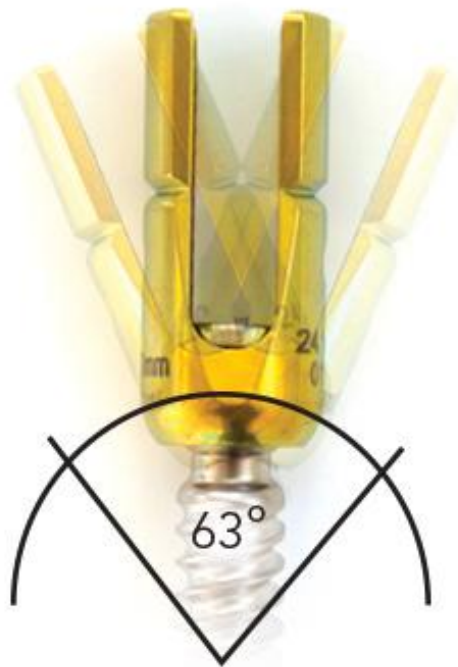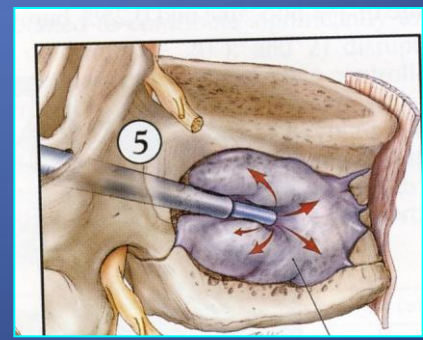
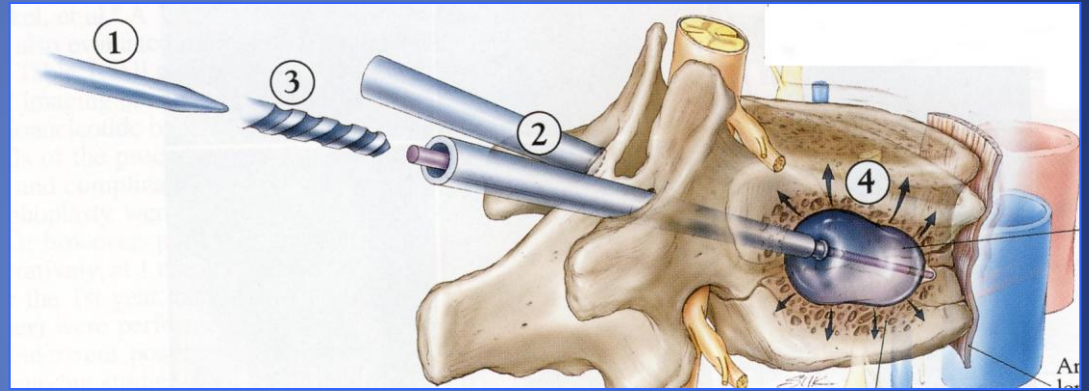
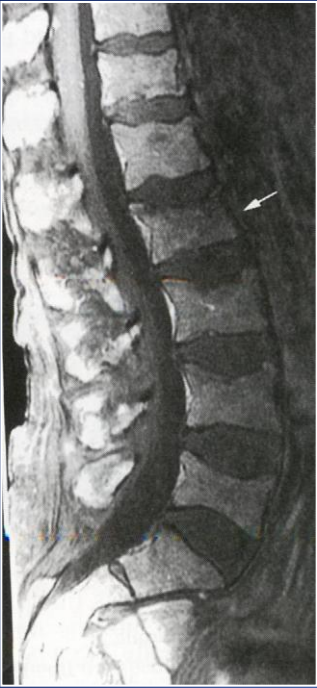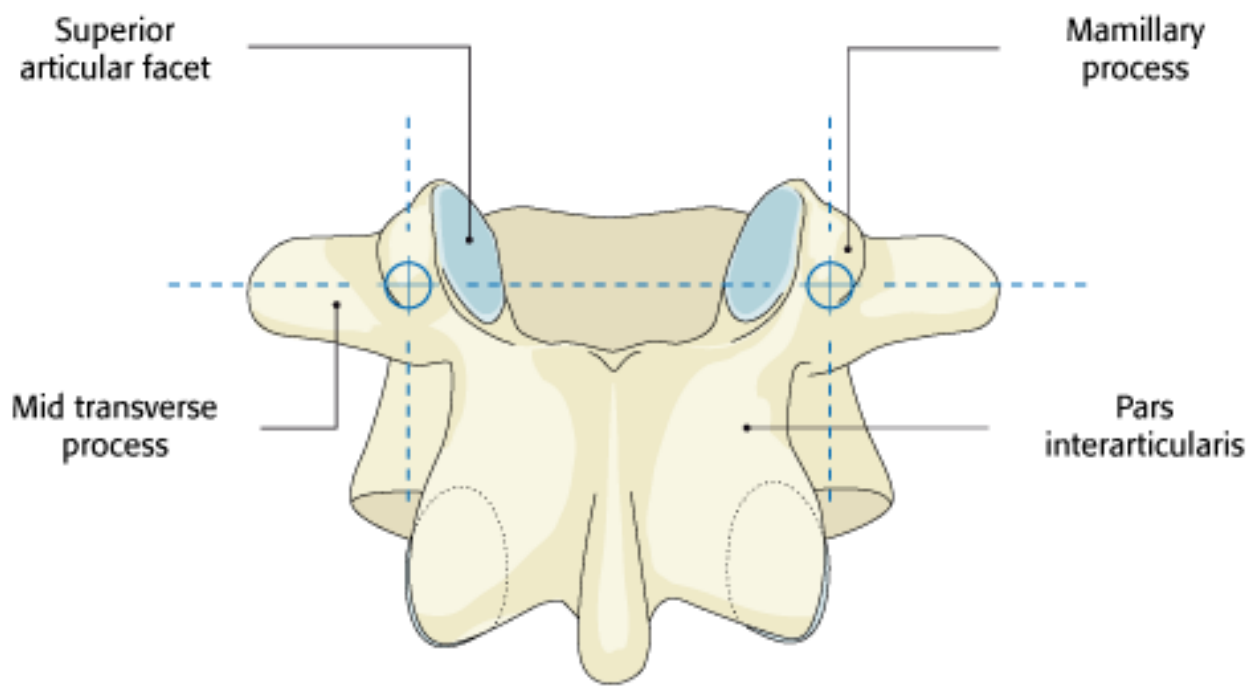


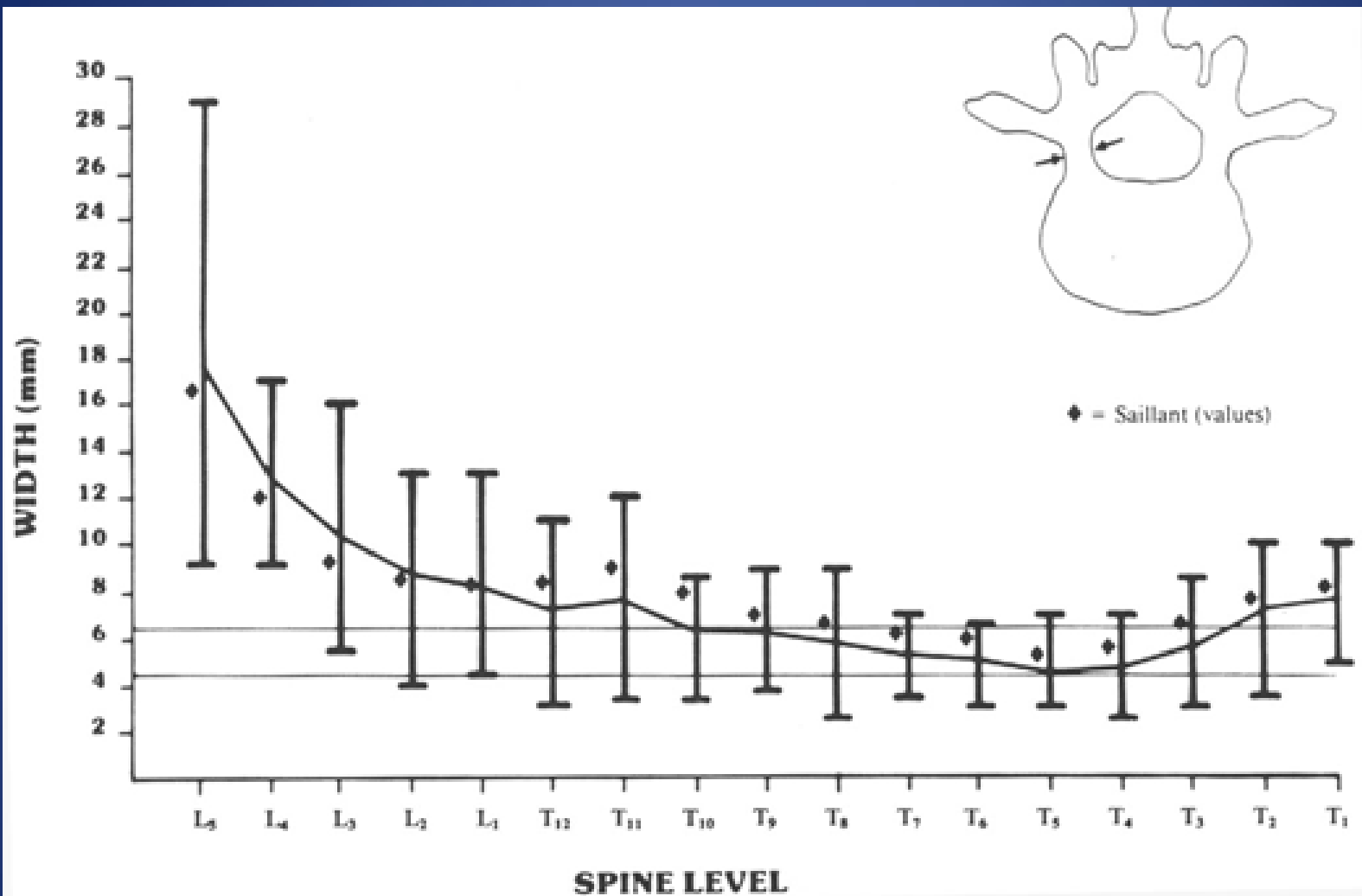
Fig. 10d

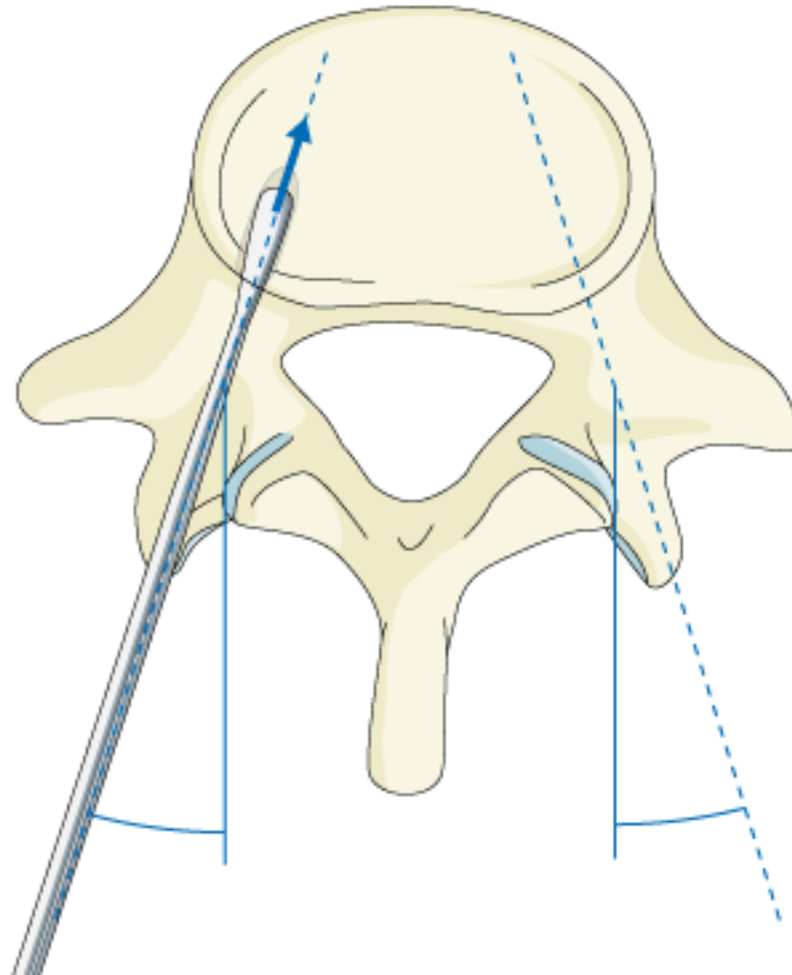


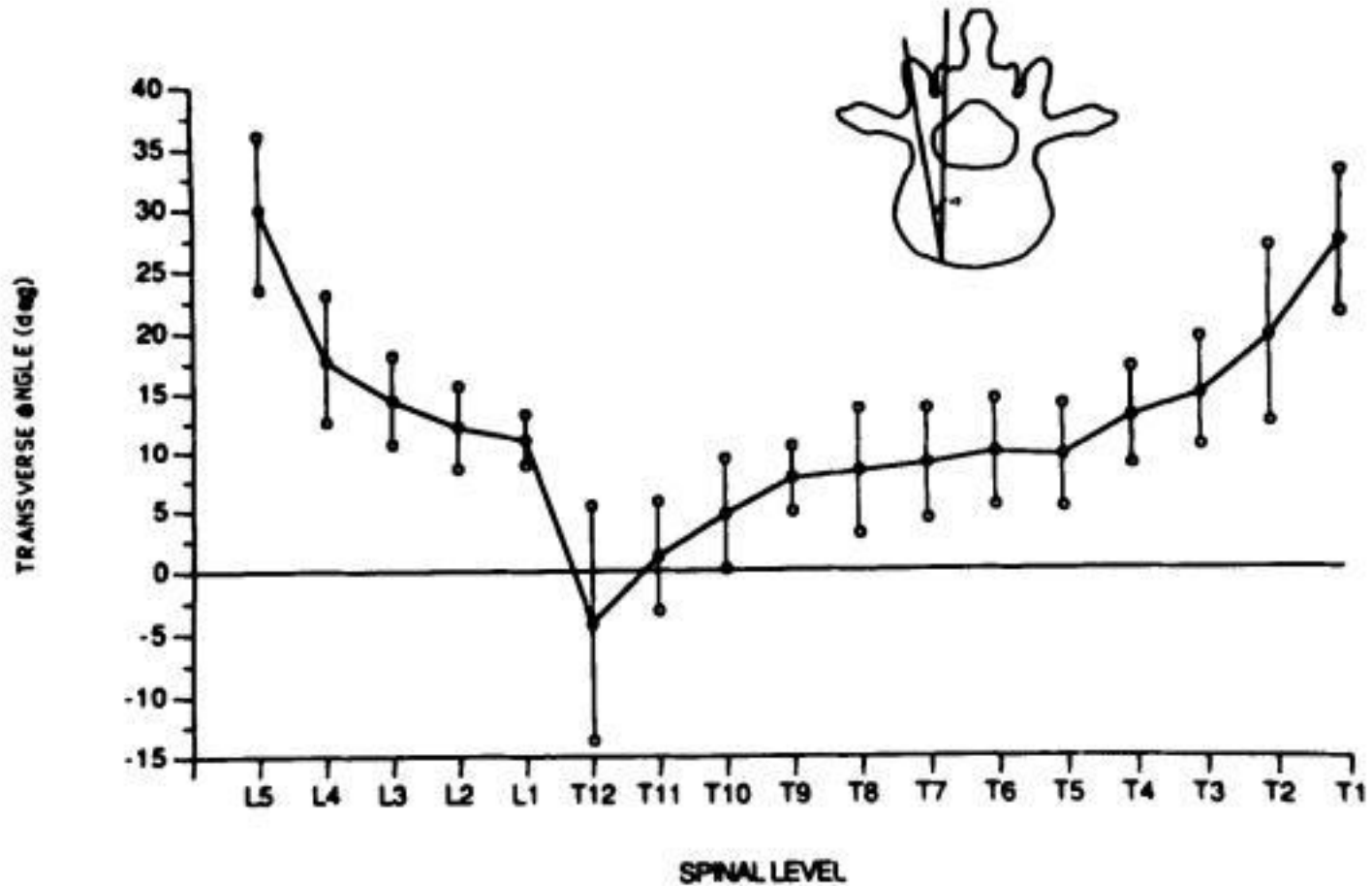
Οστεοπόρωση - κατάγματα





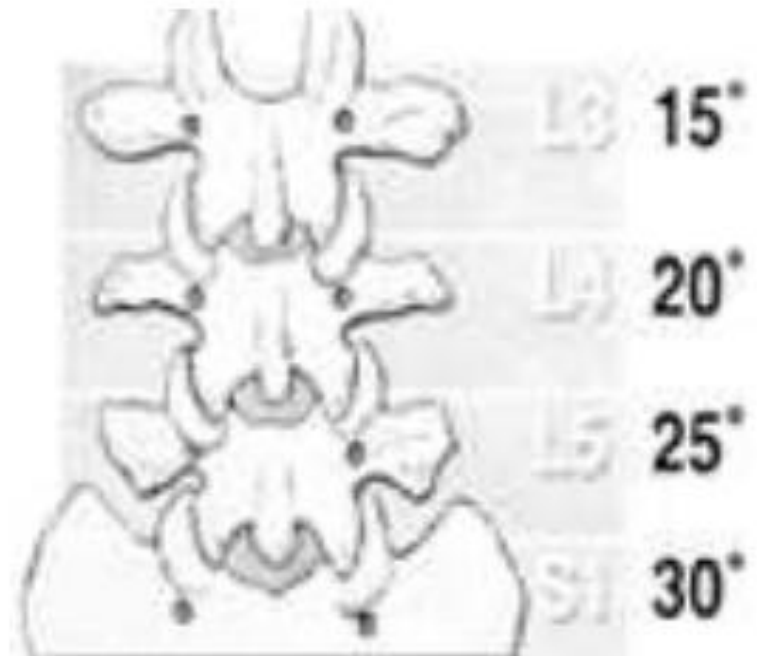


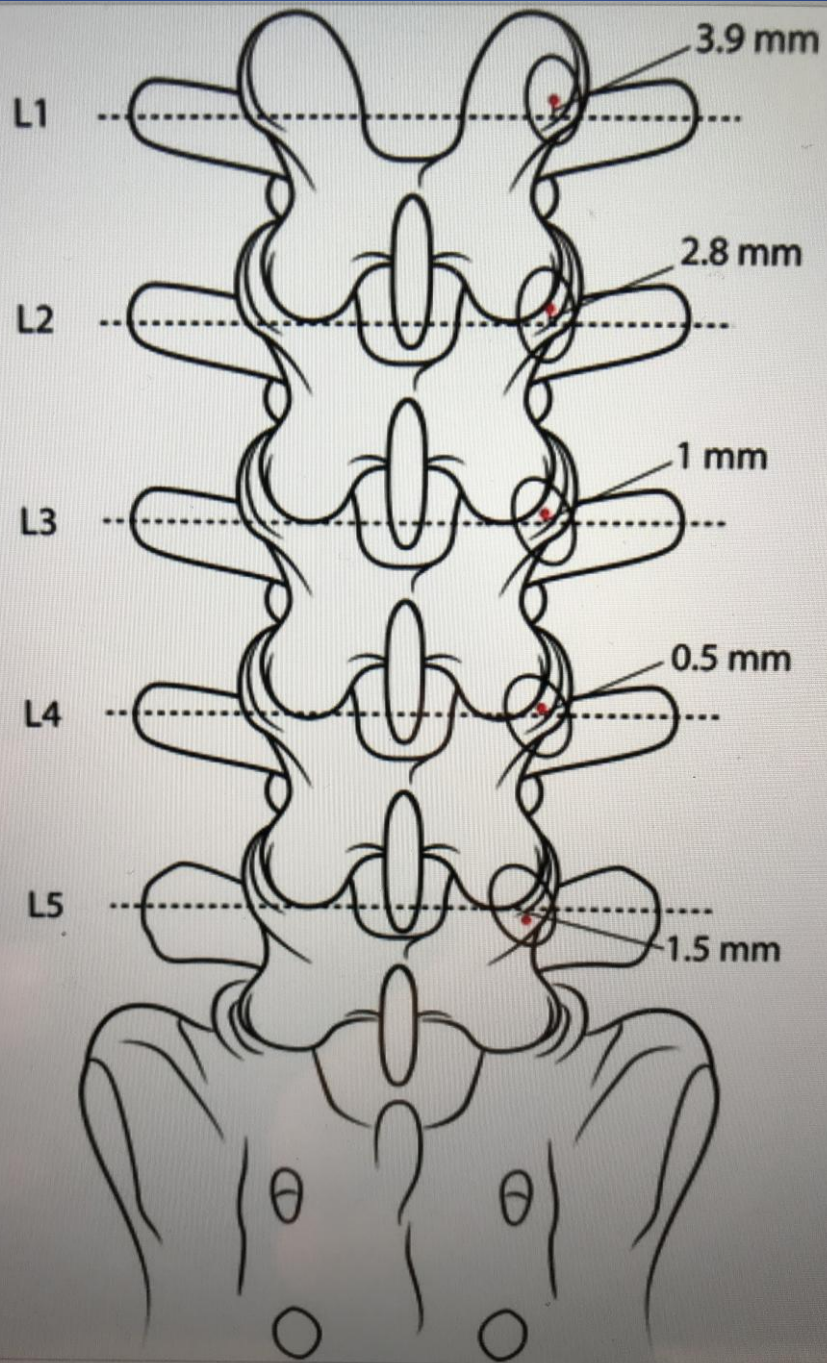


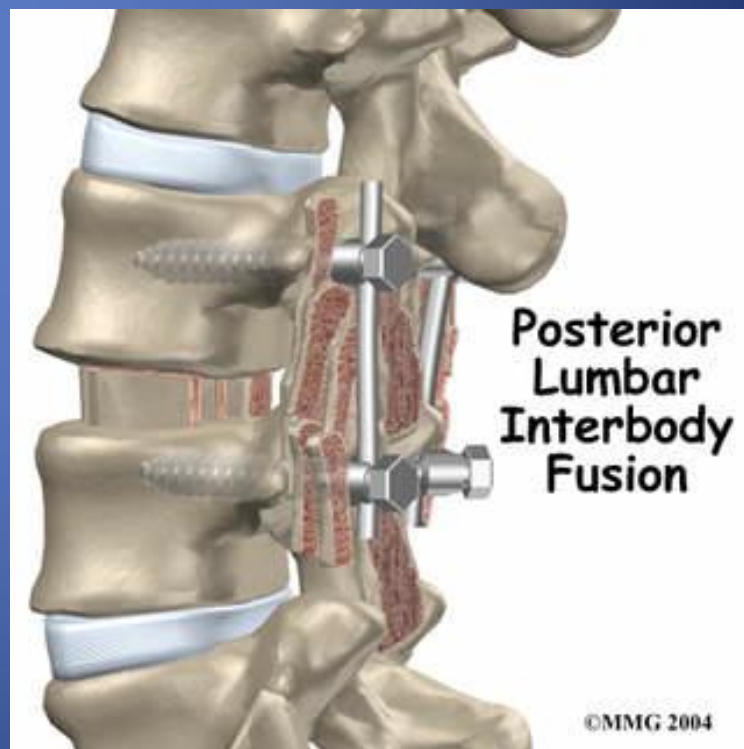
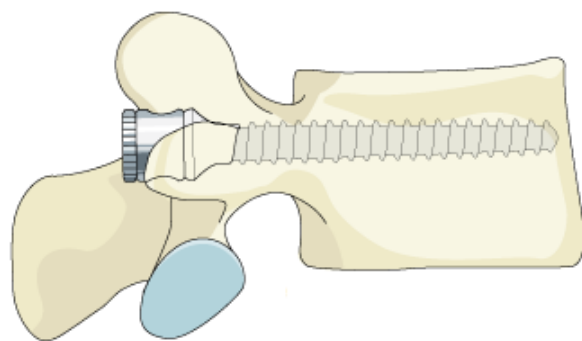


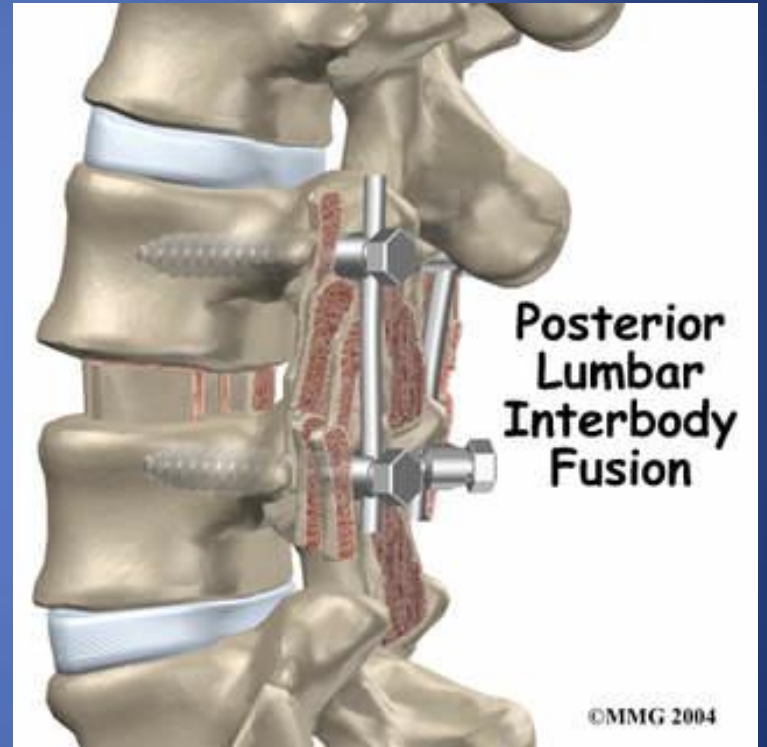
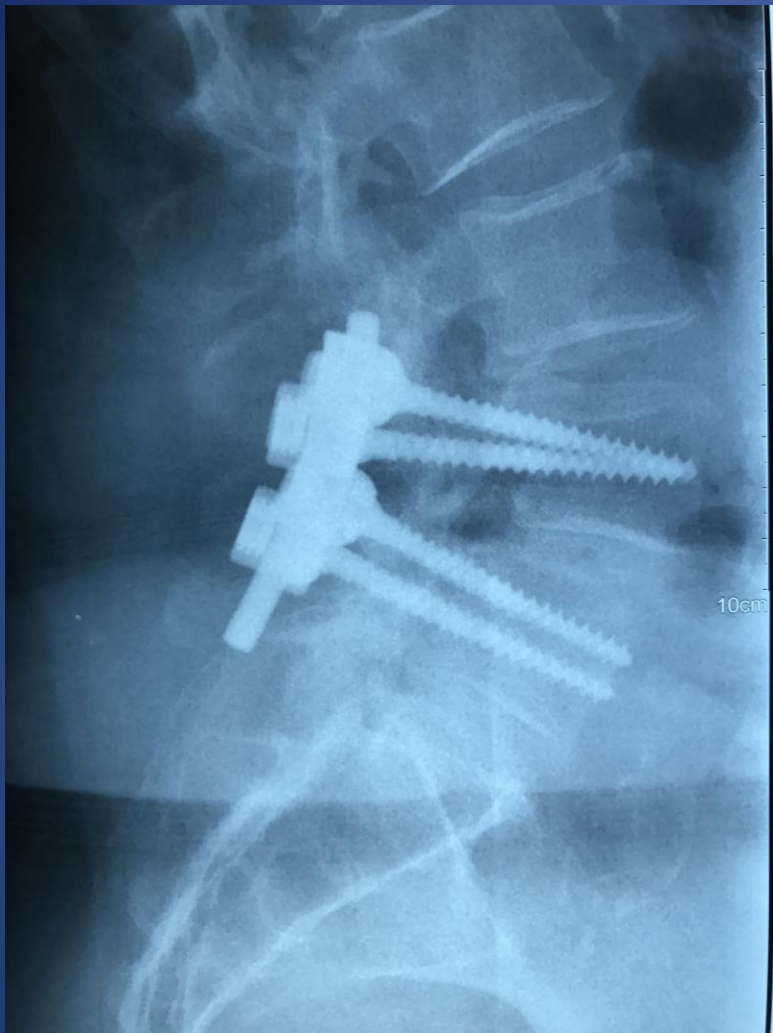
Pedicle Screw Entry Sites and Trajectory

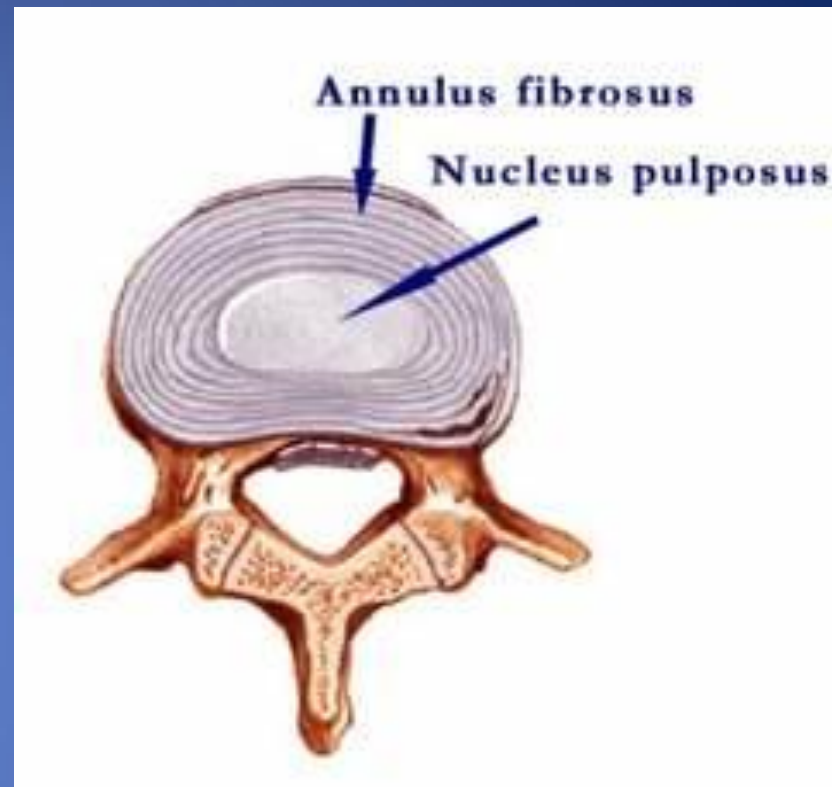
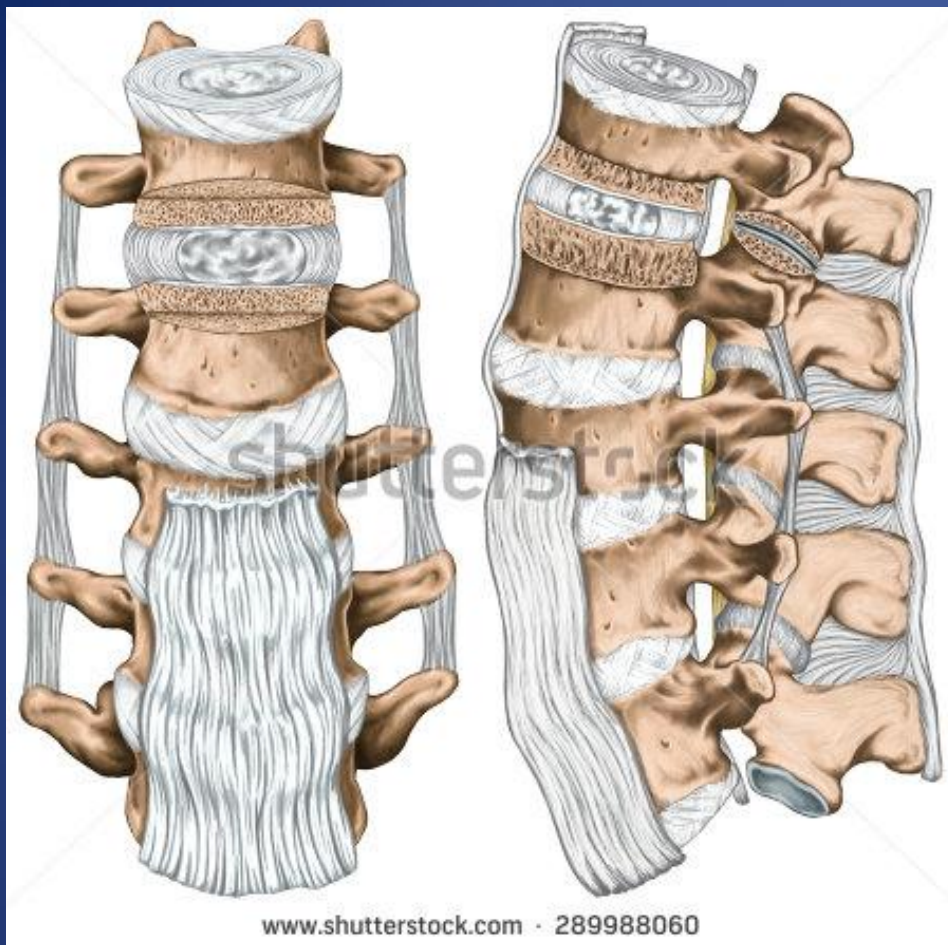Schematic diagram showing that the coronal (medial) angle increase approximately 5 degs per level from L1 to the sacrum.



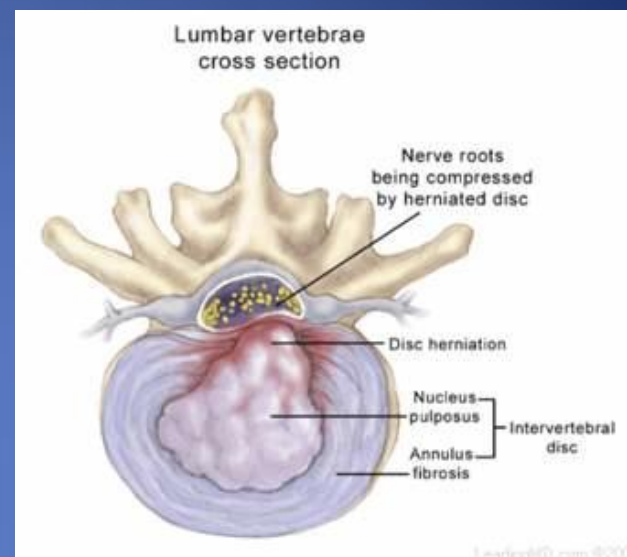
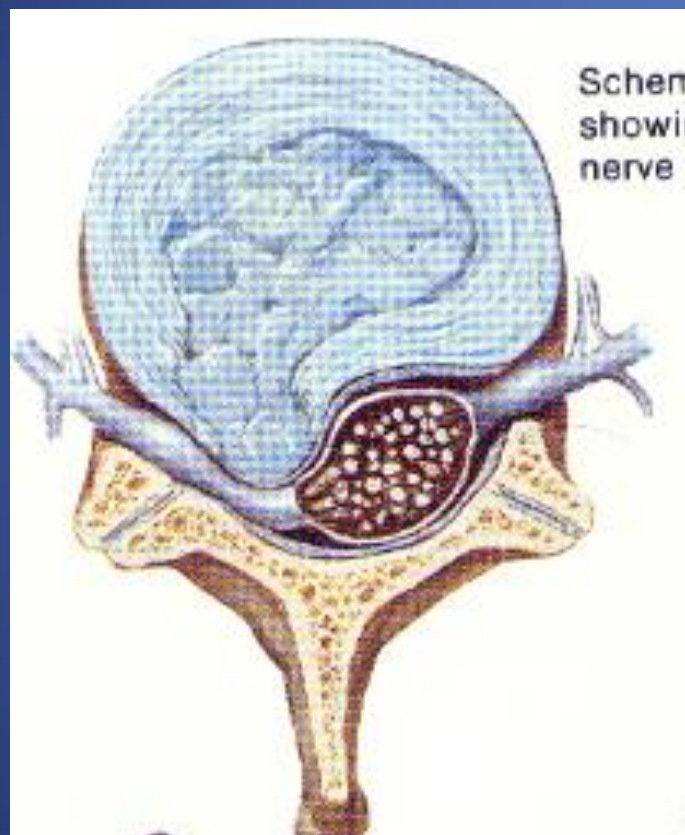









ΟΣΦΥΙΚΗ ΔΙΣΚΟΚΗΛΗ





Intradiscal pressure (kg)

350
325
300
275
250
225
200
175
150
125
100
75
50
25
0

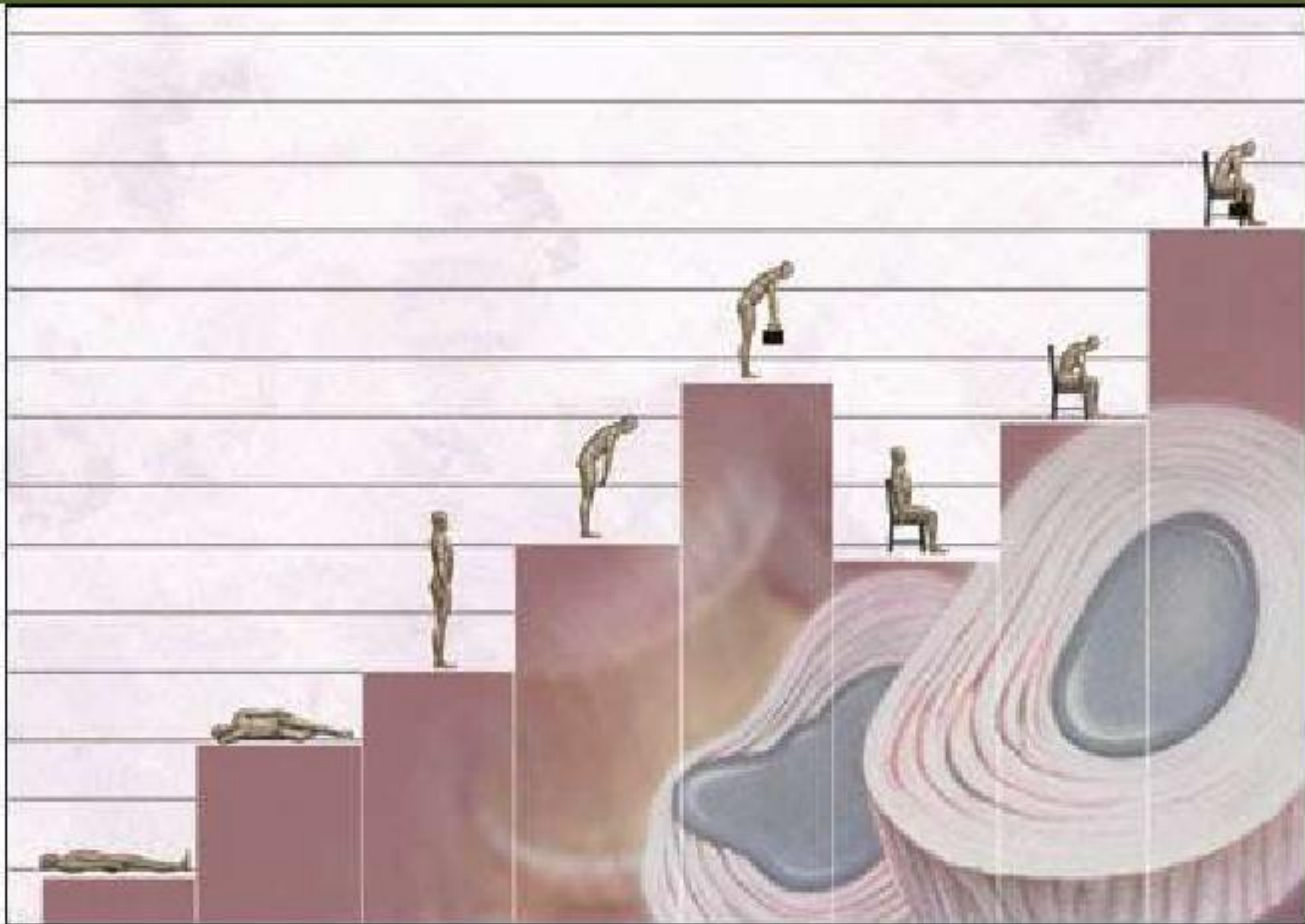
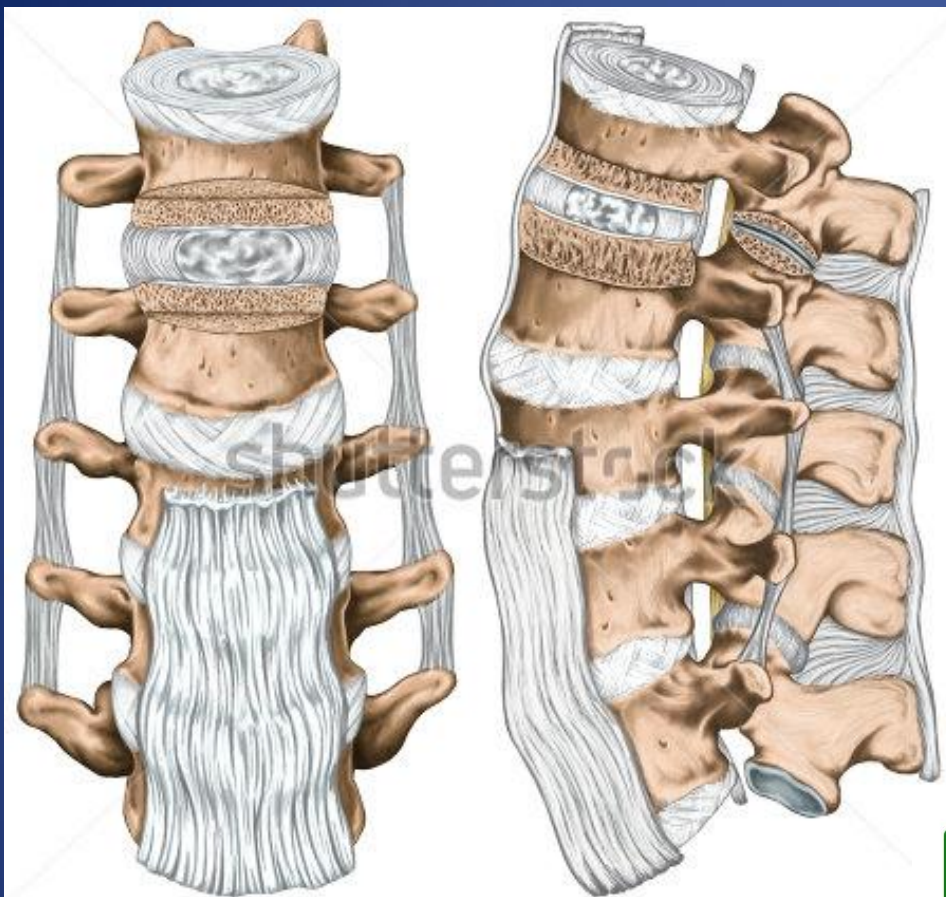



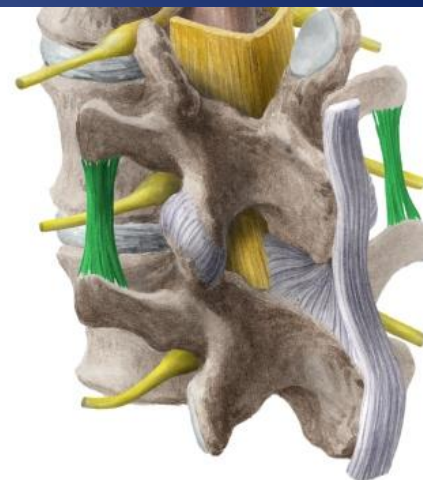
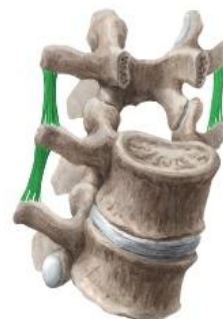Photo Buyamag Inc.



www.shutterstock.com · 289988060

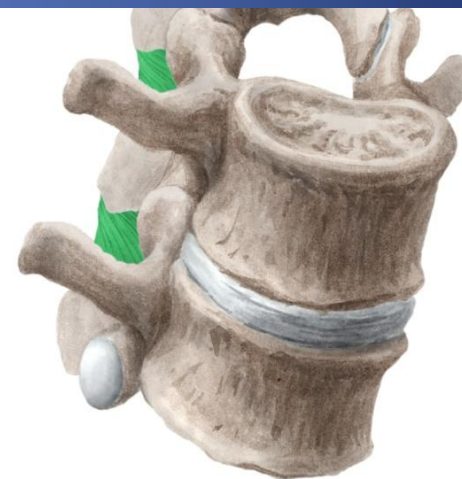
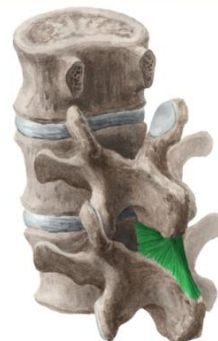Intertransverse ligaments

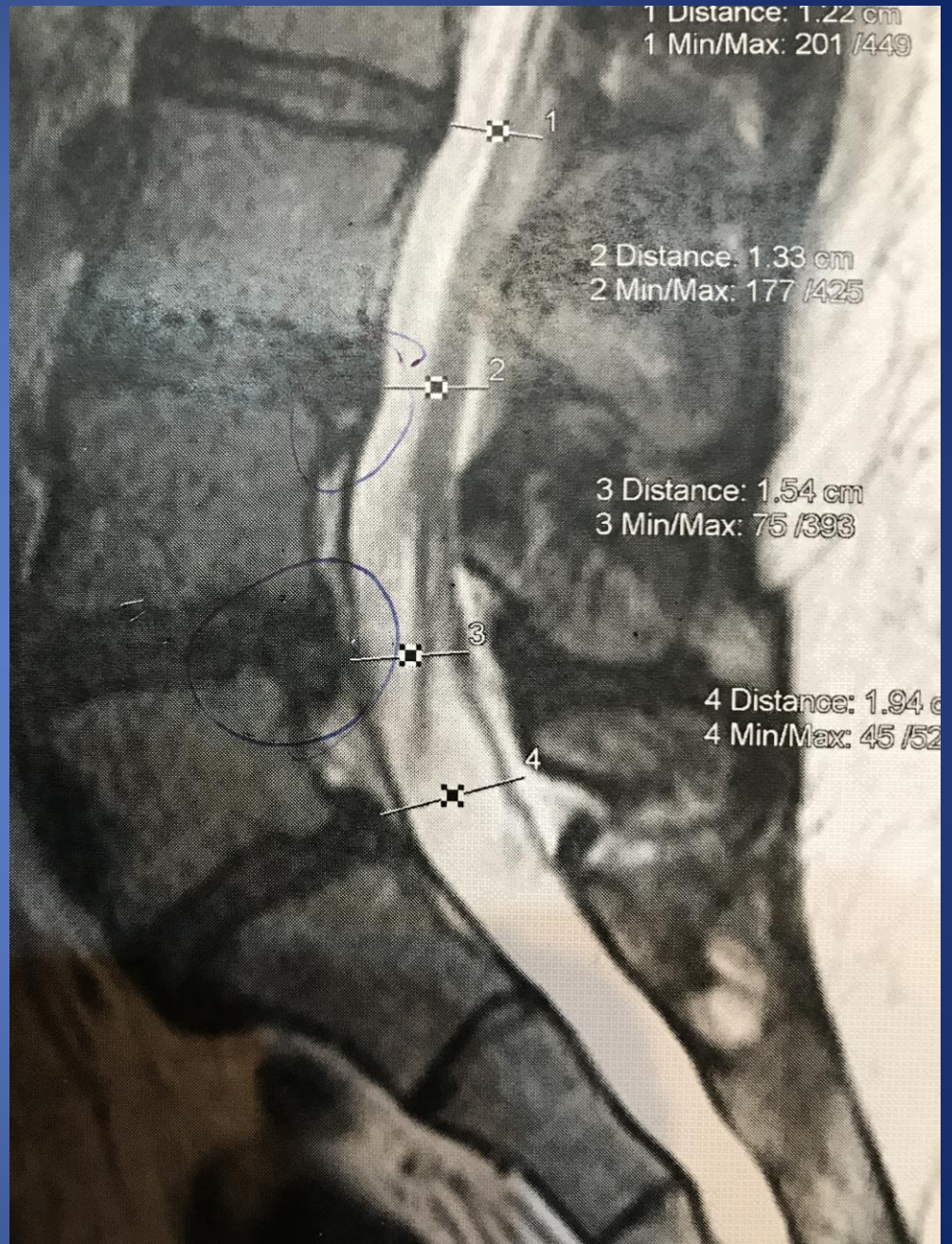
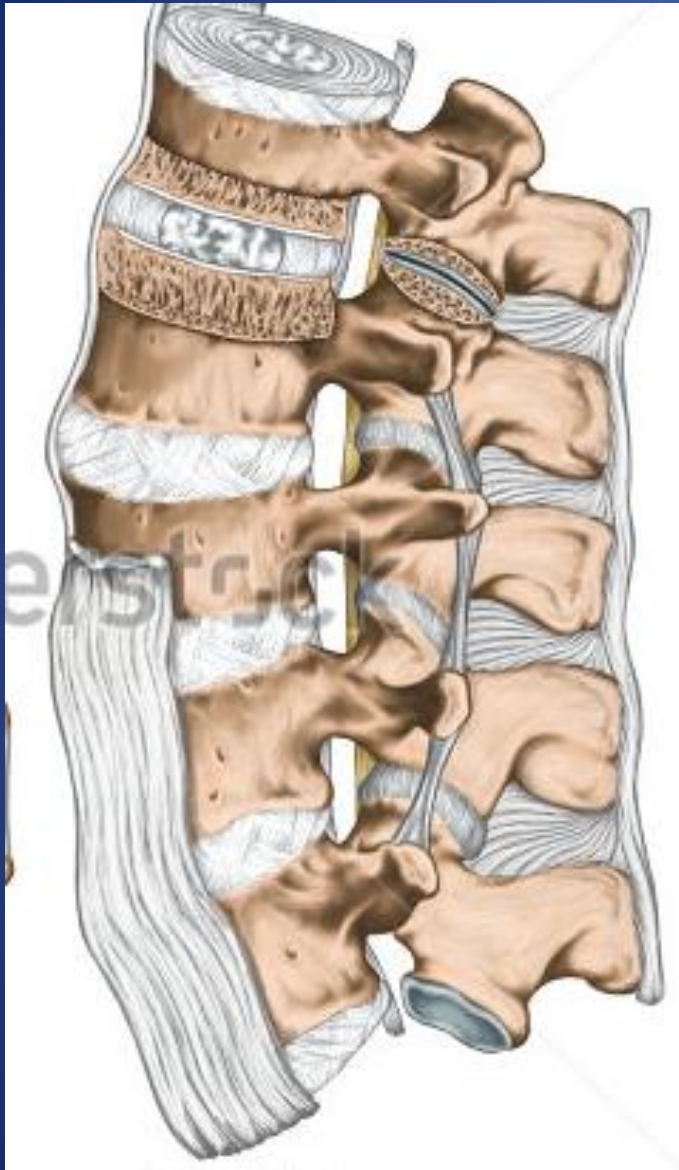
LATIN
Ligamenta intertransversaria



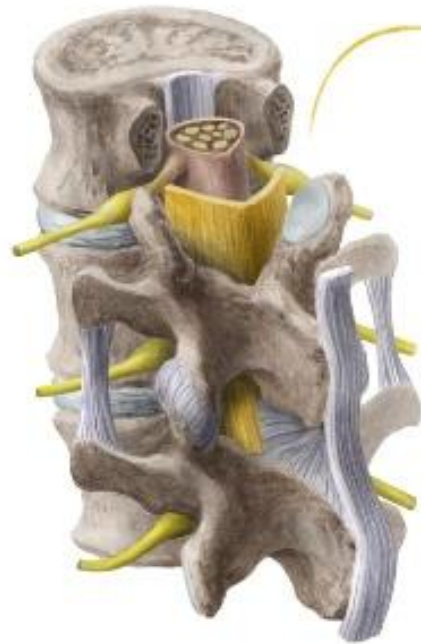Interspinous ligaments

LATIN
Ligamentum interspinale

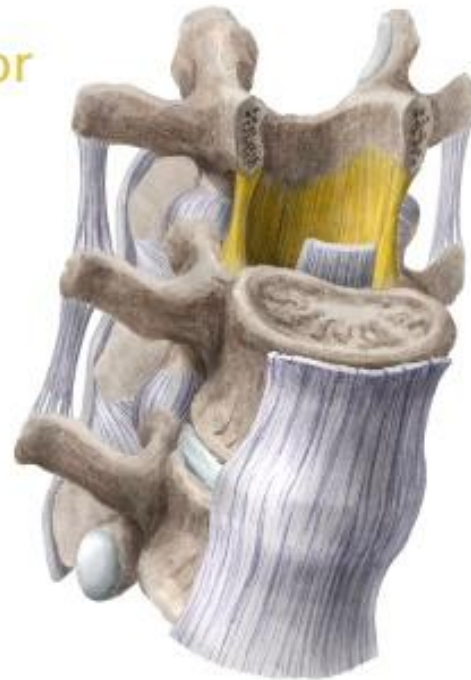



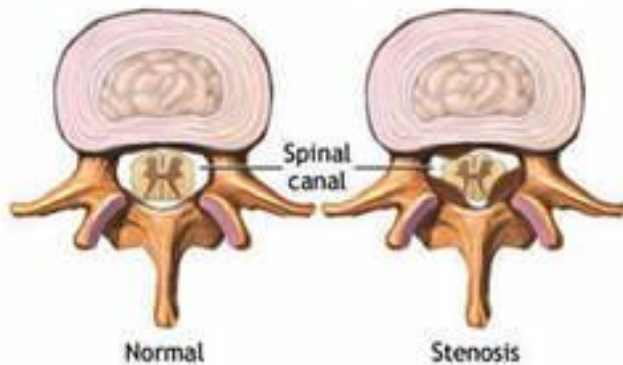
Ligamentum flavum



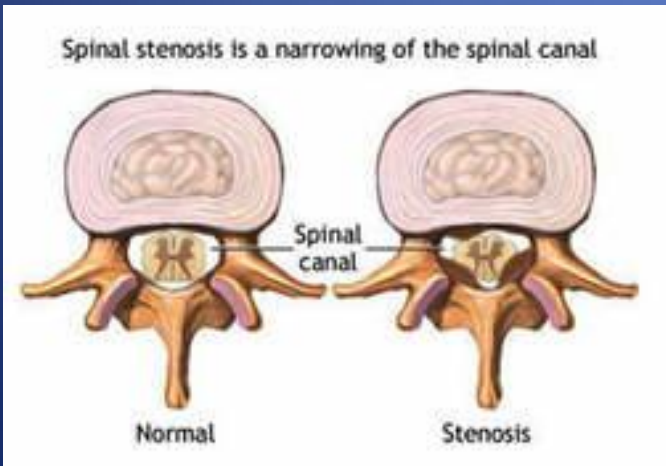
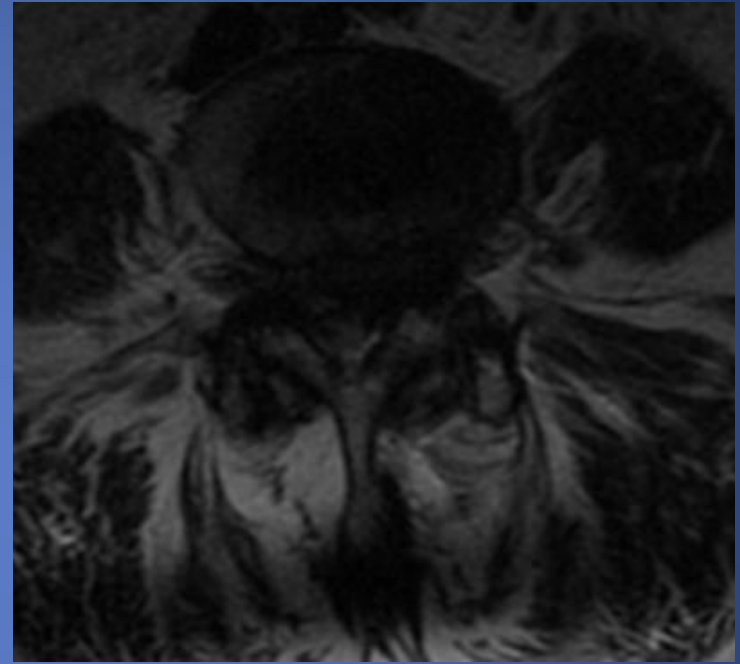
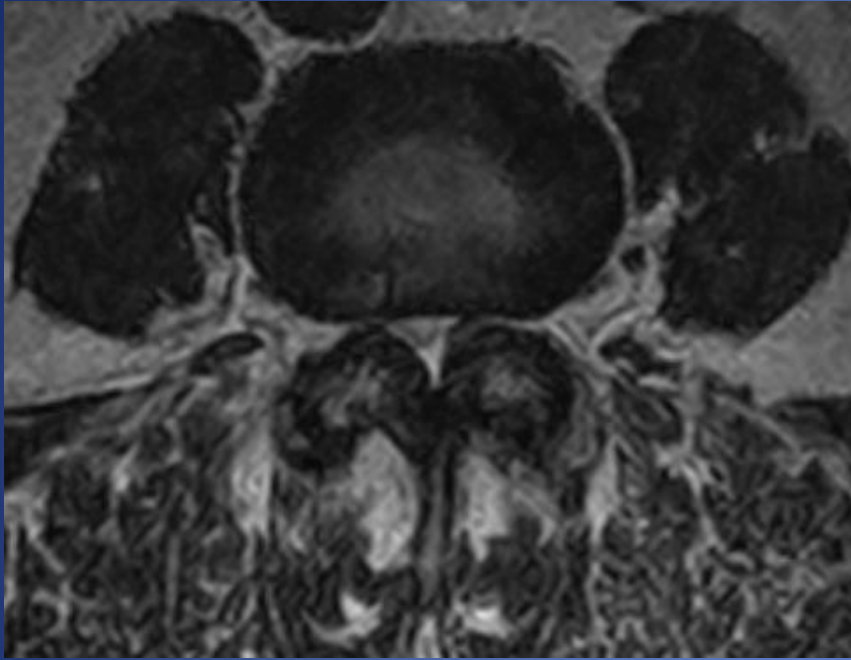
yellow color
arrangement
of elastic
fibers




Spinal stenosis is a narrowing of the spinal canal

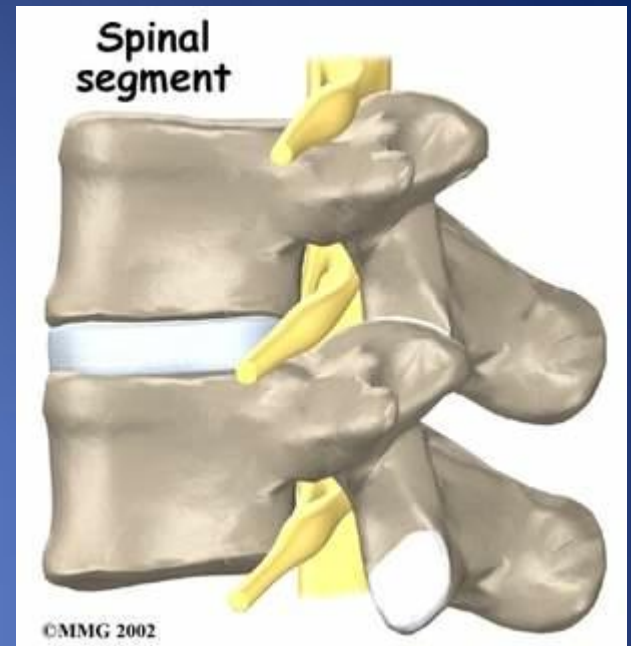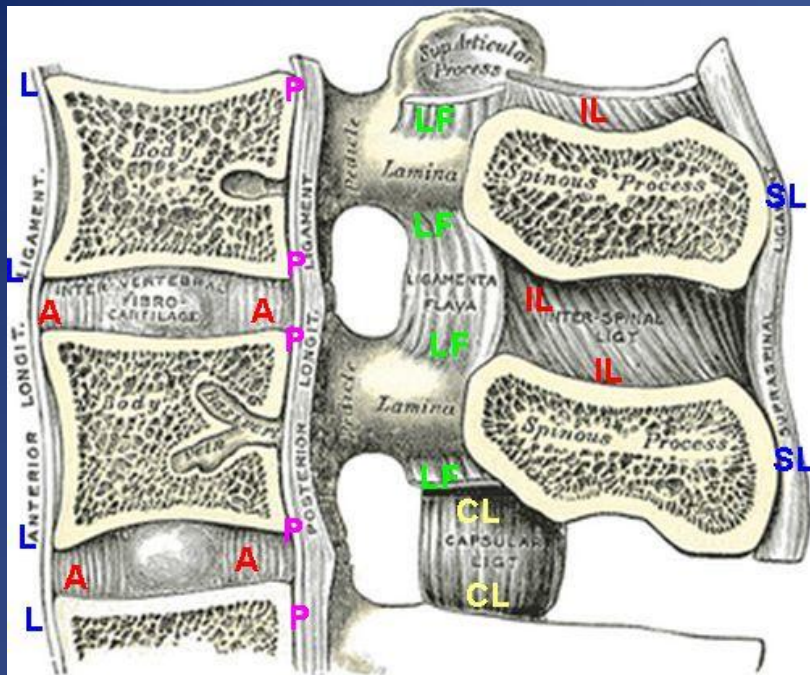


Thickness < 5mm

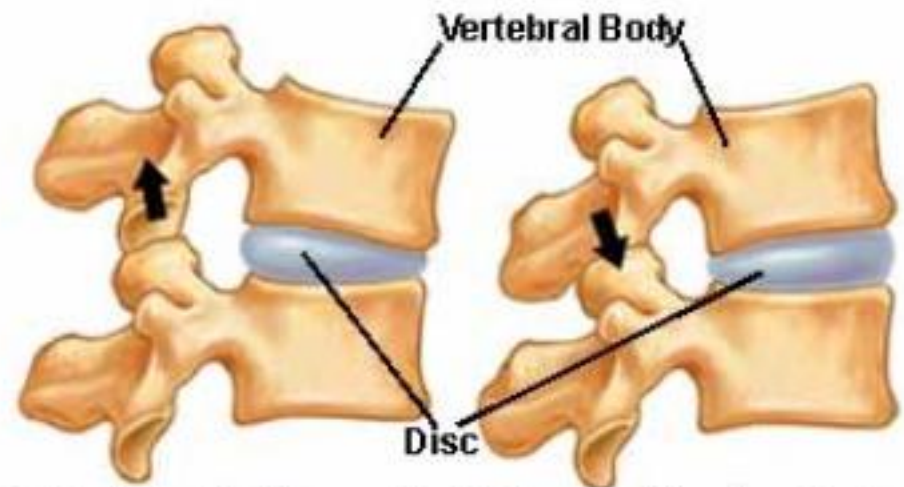


Thickness <5mm





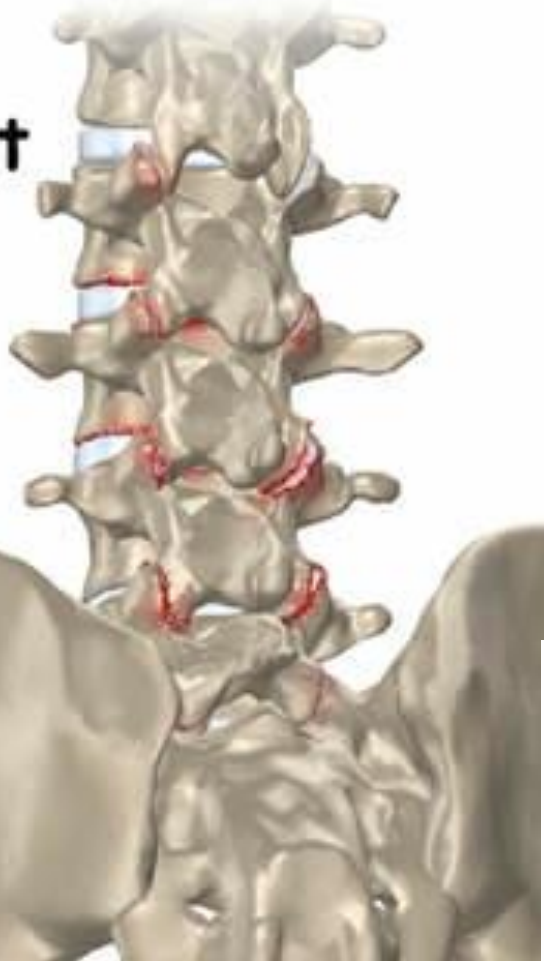Facet Joints in Motion



Flexion (Bending Forward)

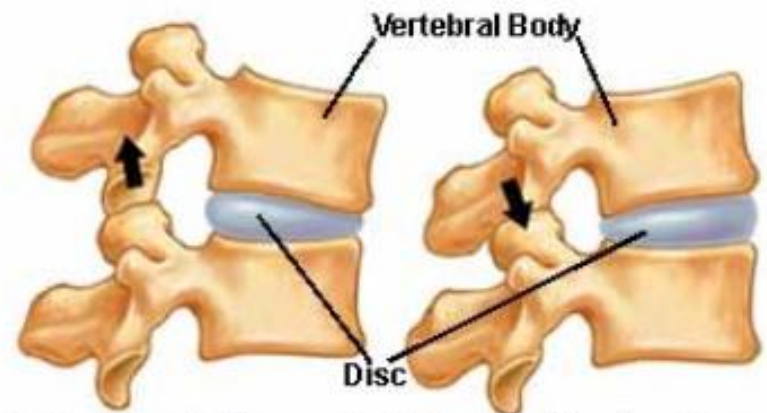
Extension (Bending Backward)

Facet Joint Arthritis



©MMG 2002

Facet Joints in Motion

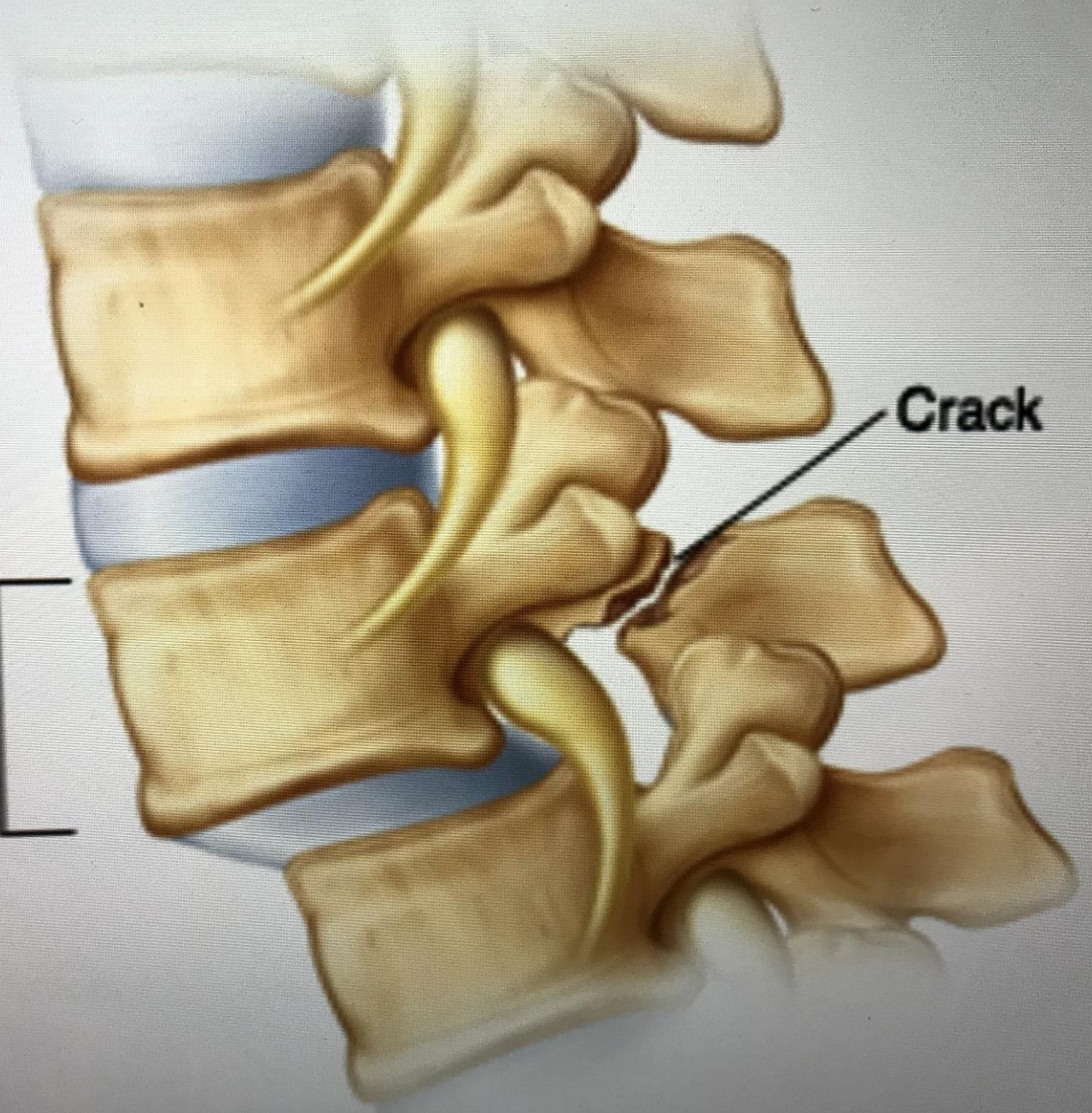


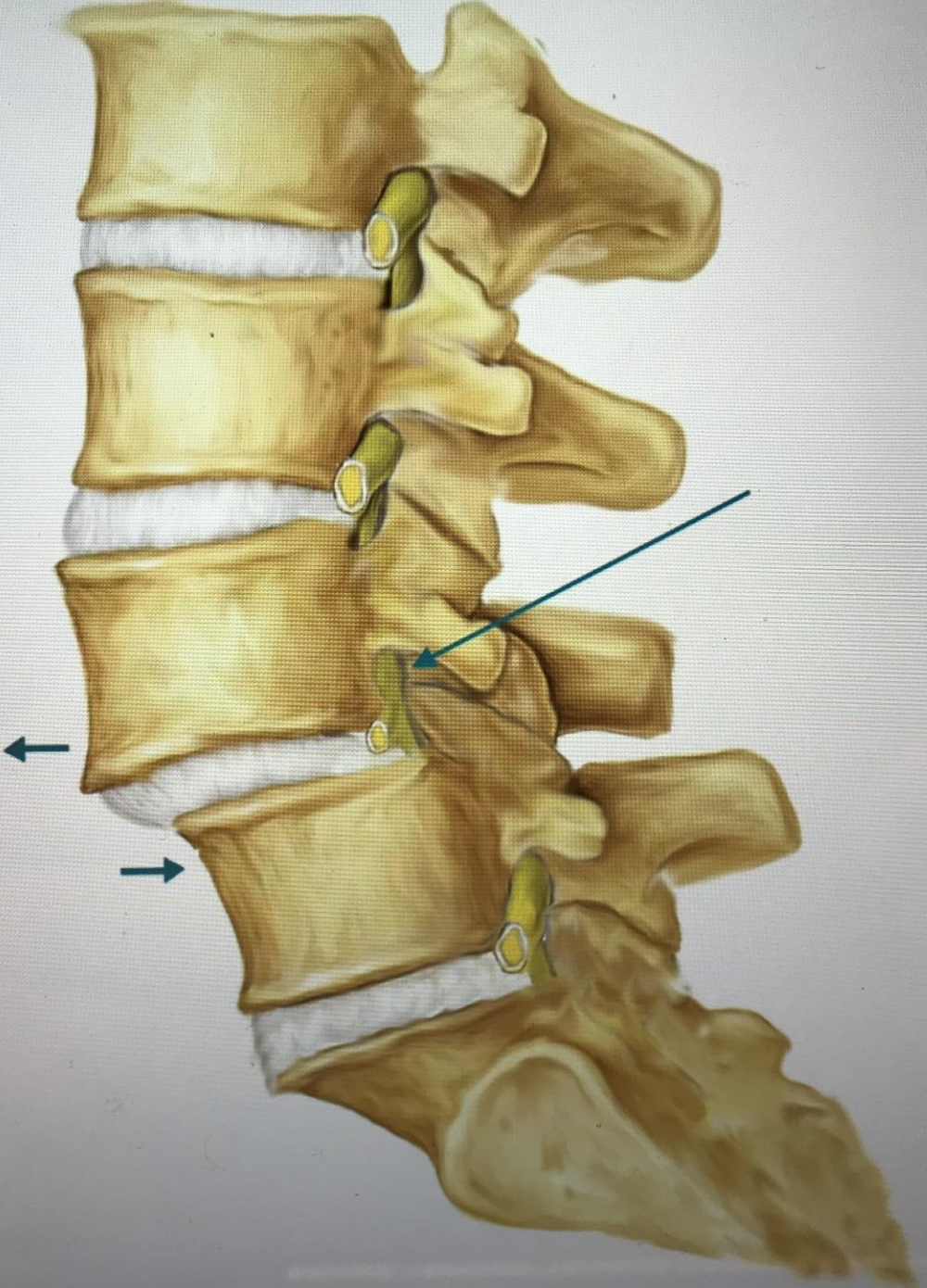
Flexion (Bending Forward) Extension (Bending Backward)

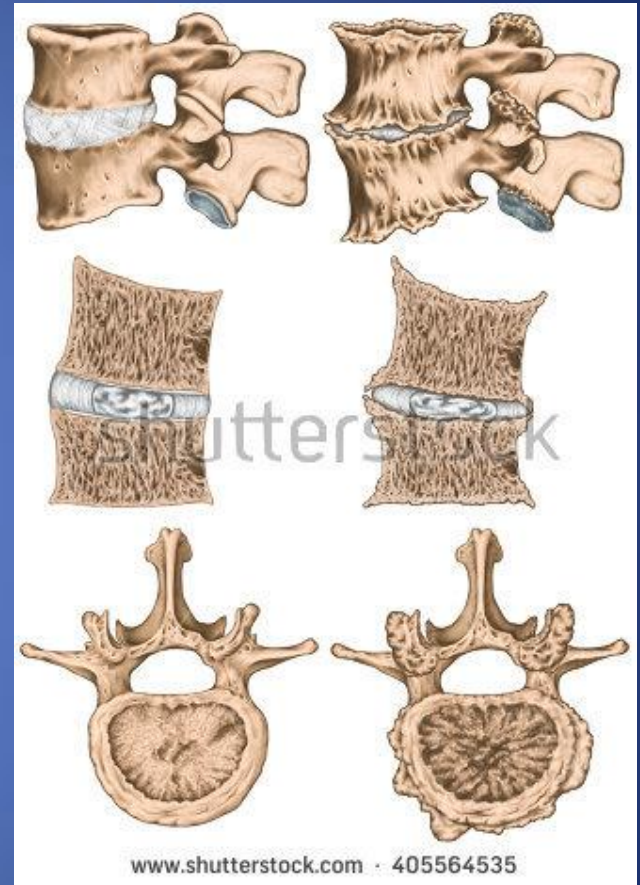
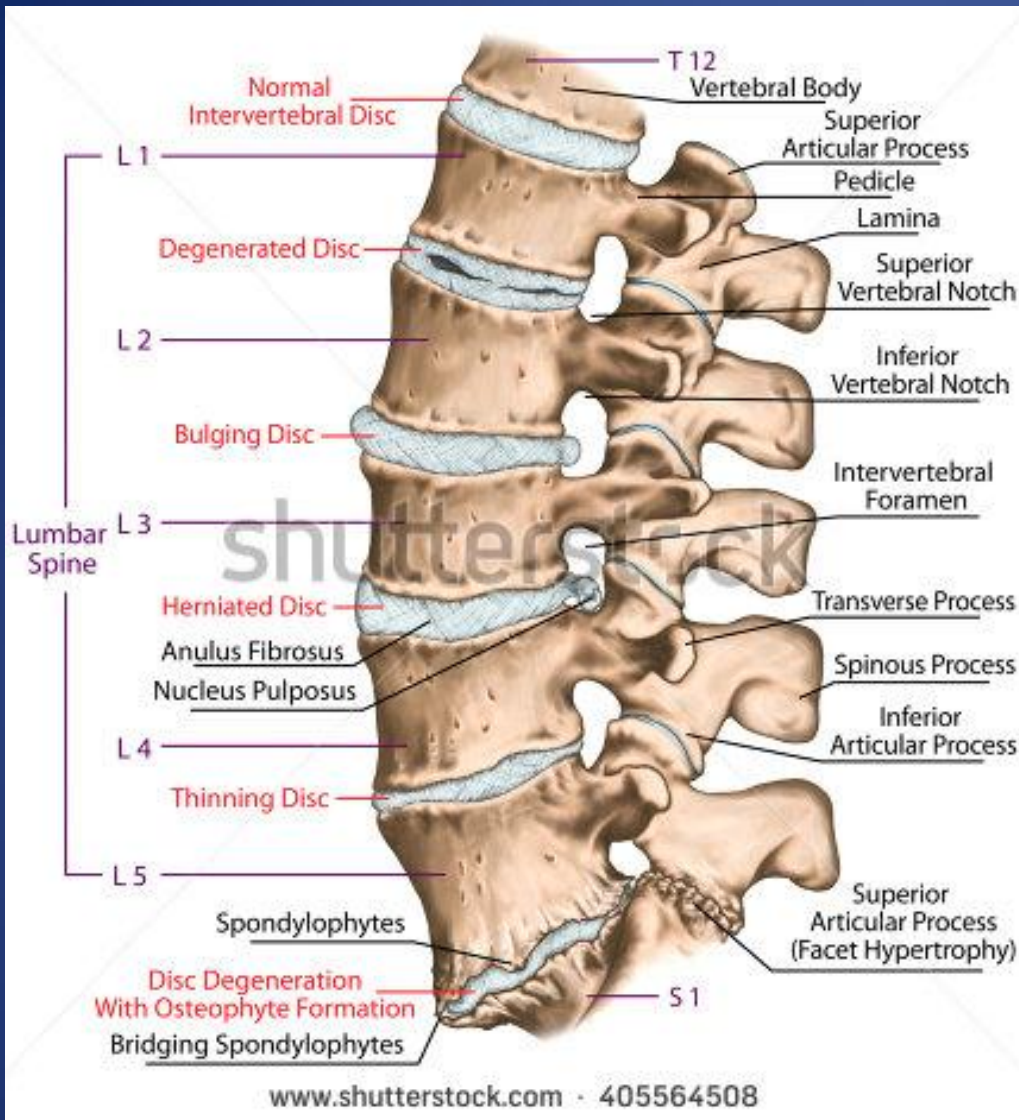
Vertebra
slipping
forward

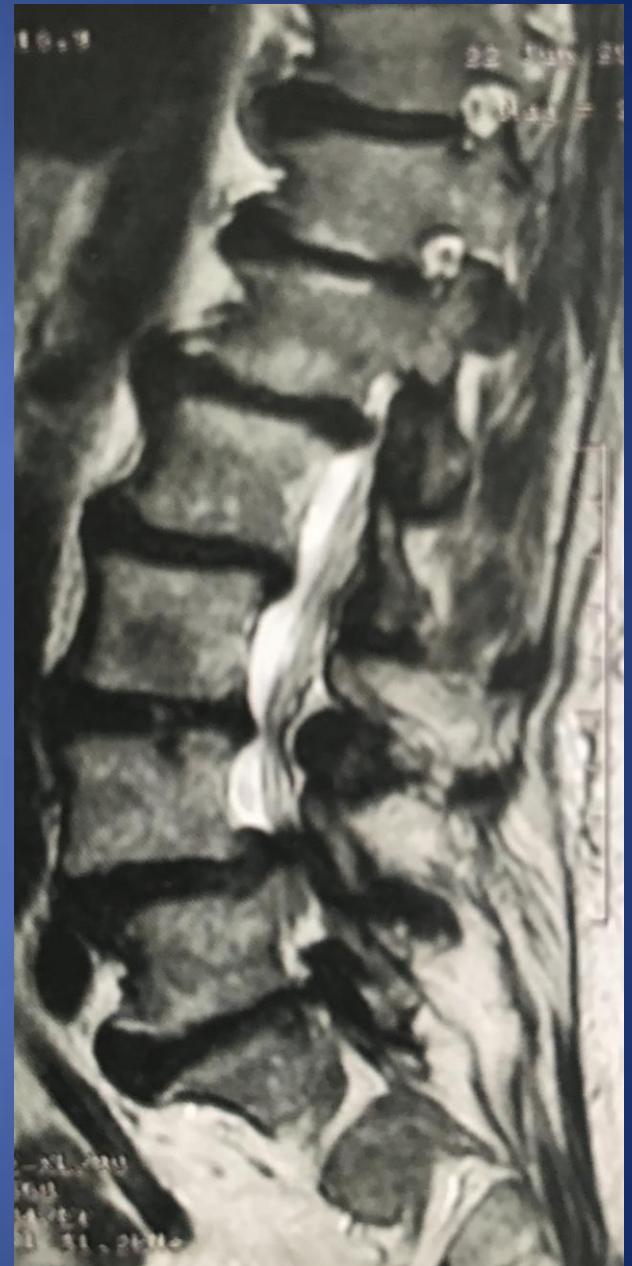
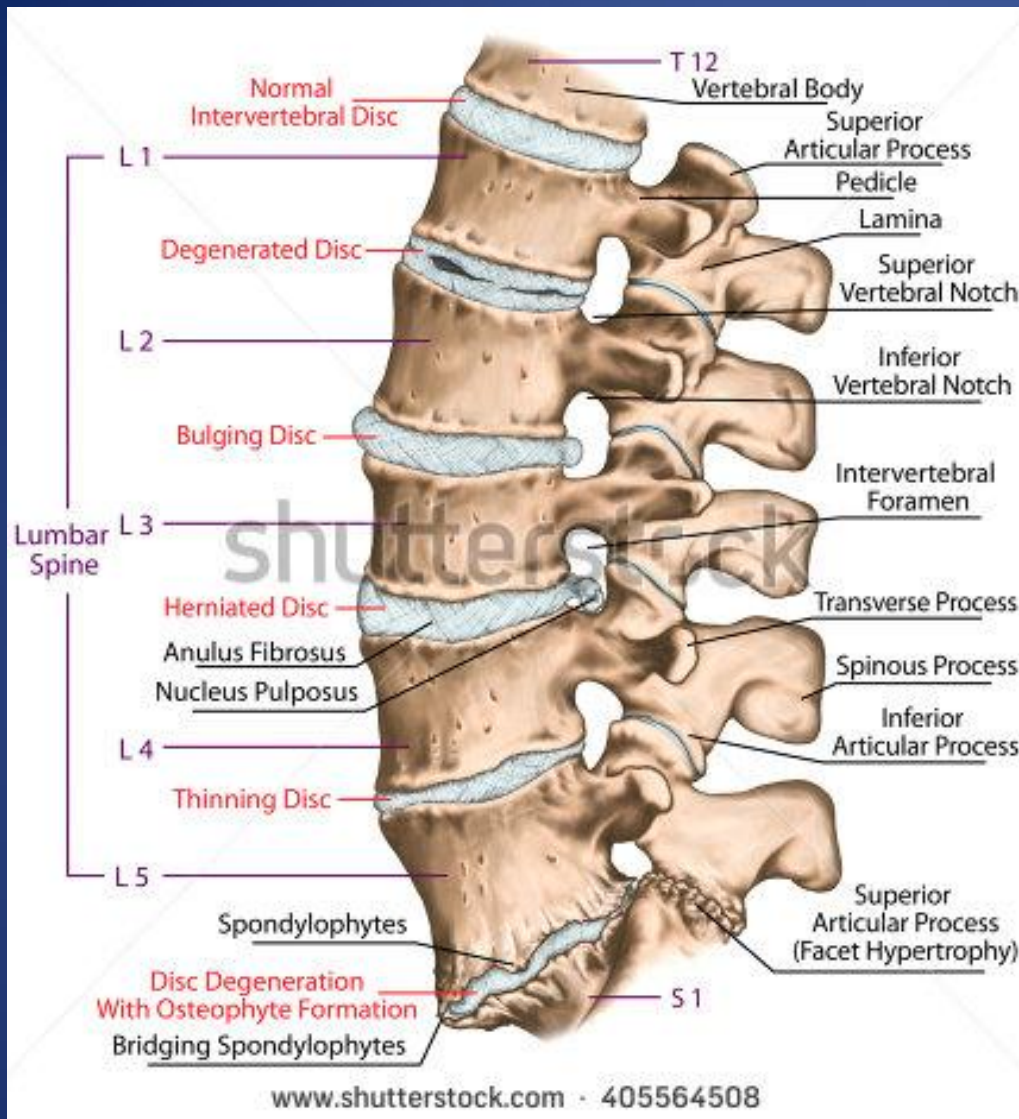
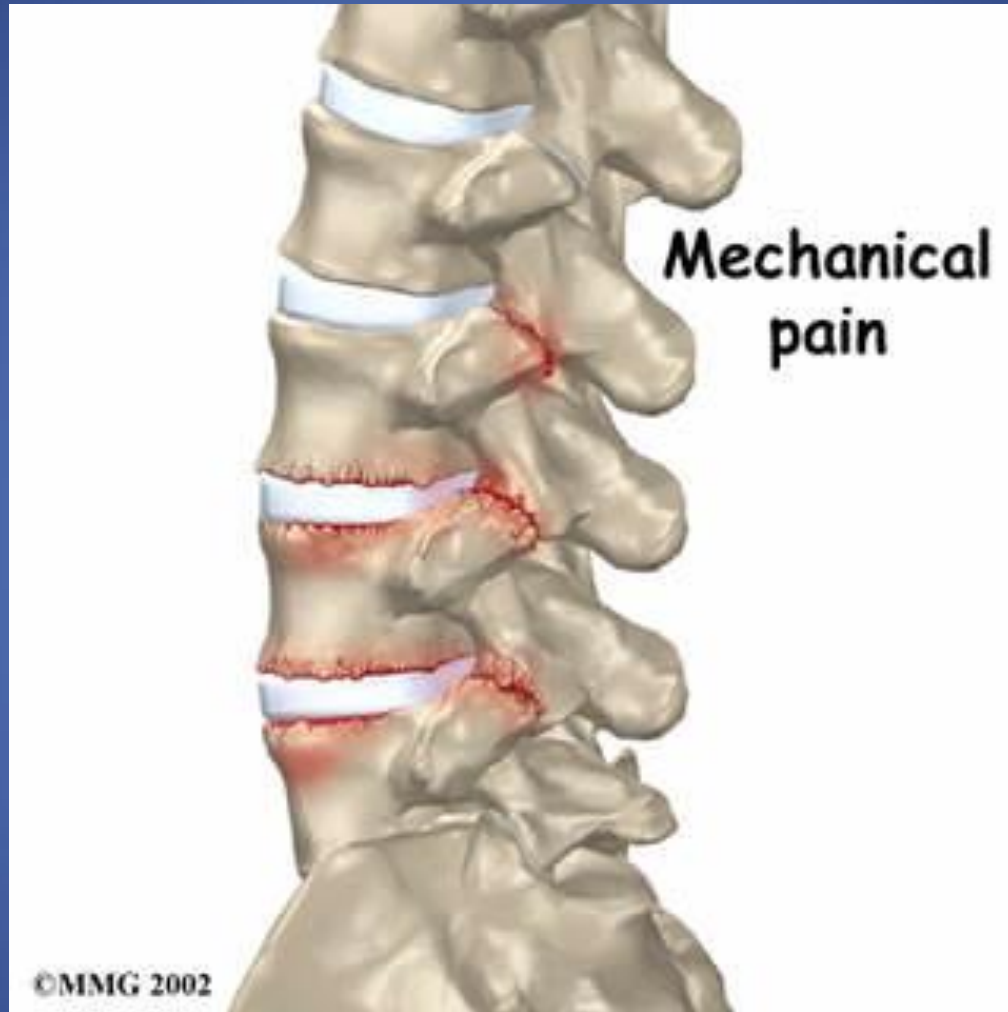Crack



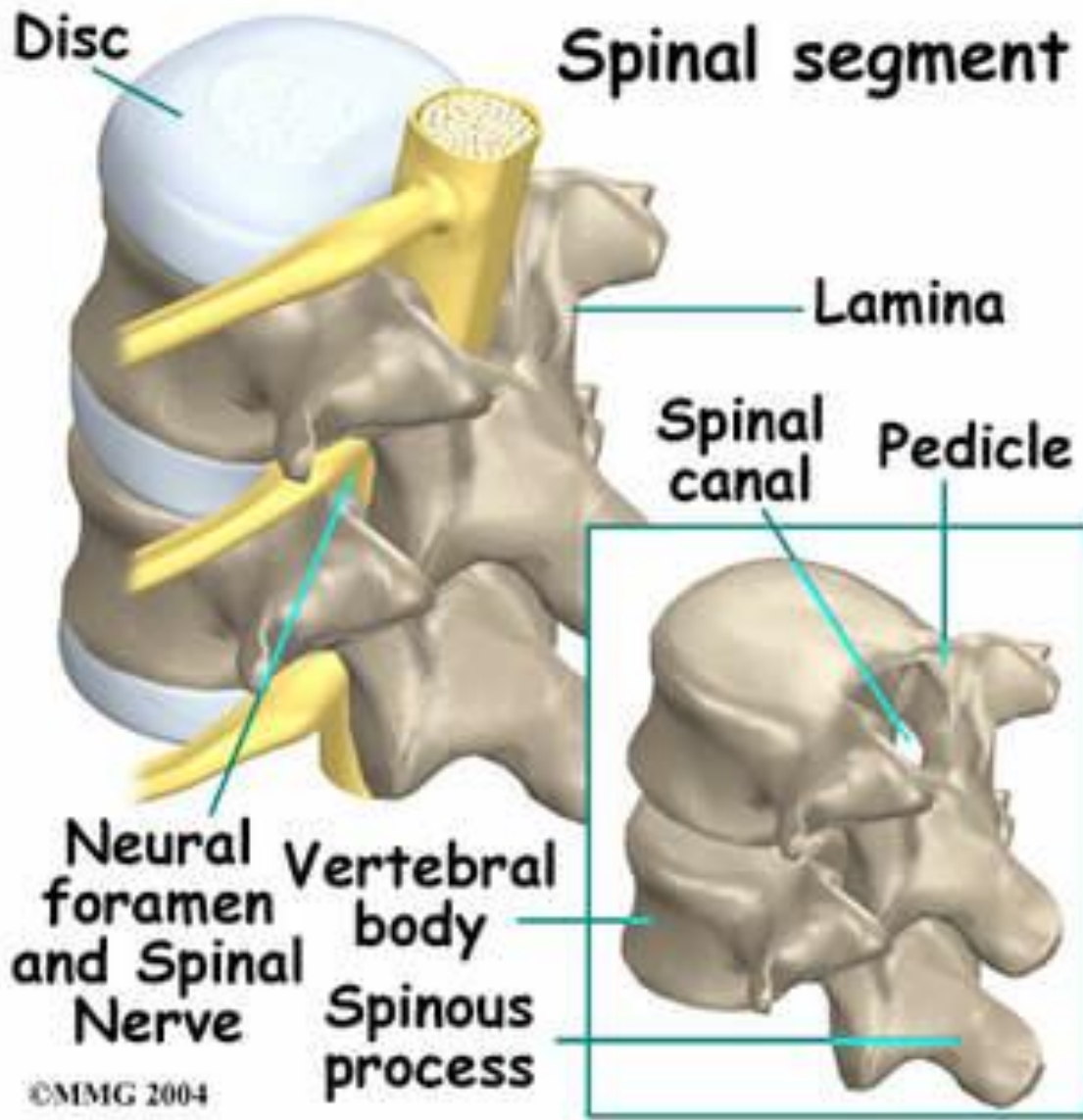




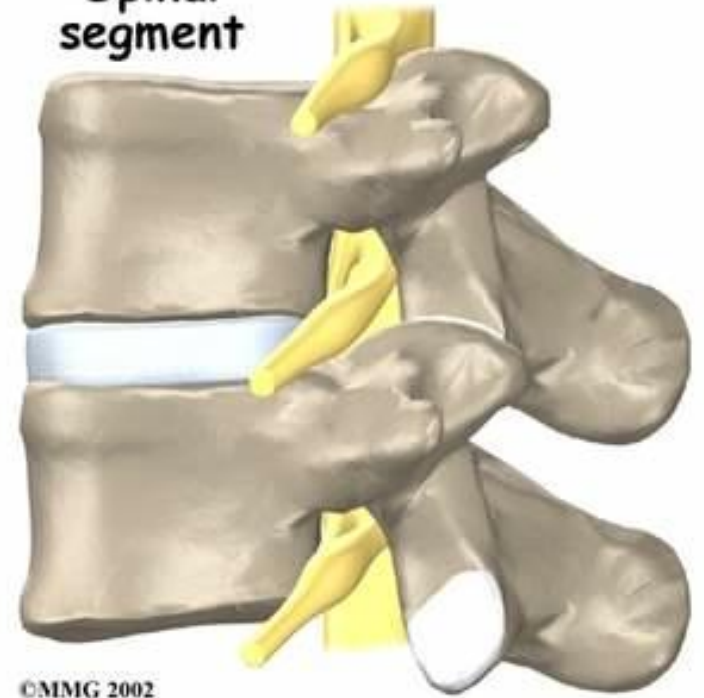




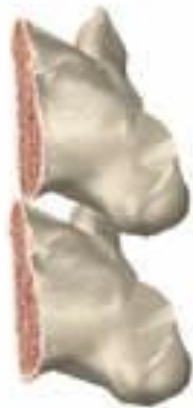Spinal segment



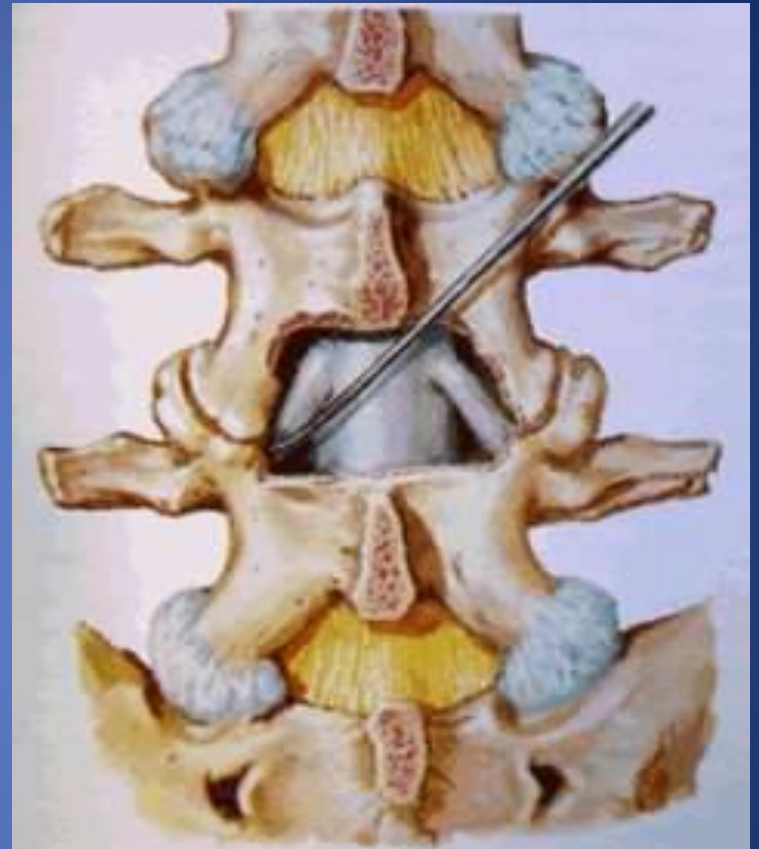Spinal segment



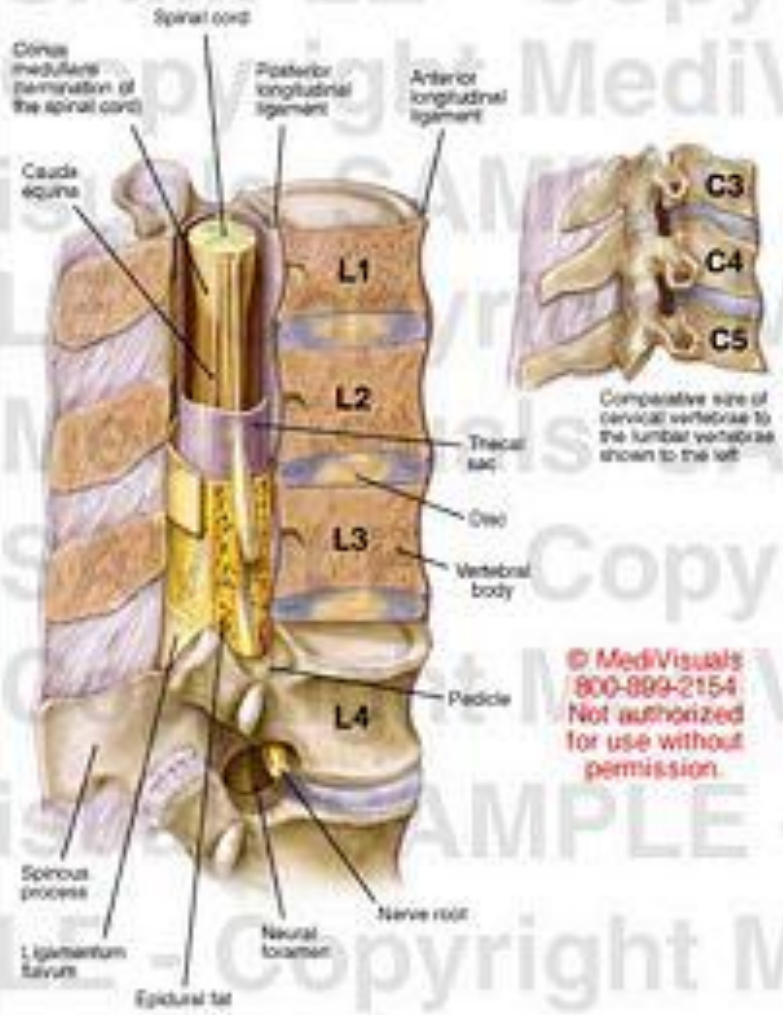
Lamina
removed



©MMG 2002



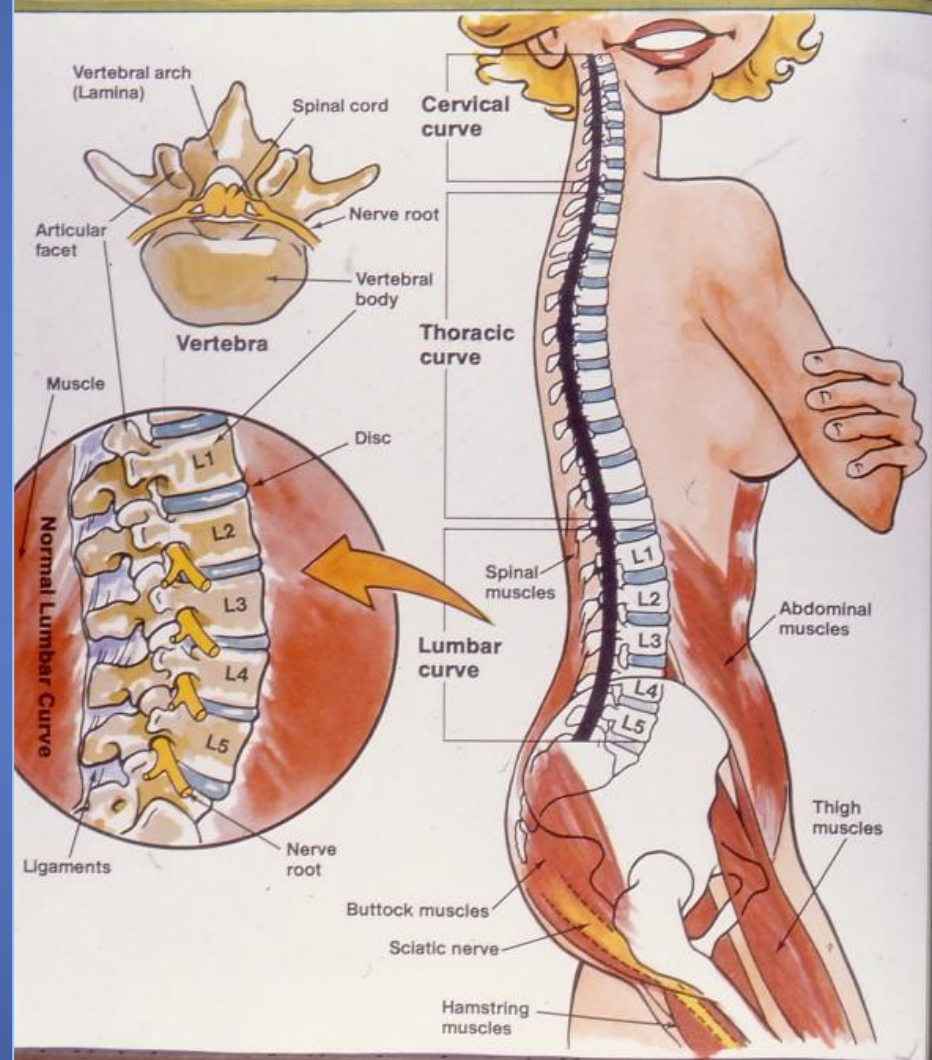
Anatomy of the Lumbar Spinal Column



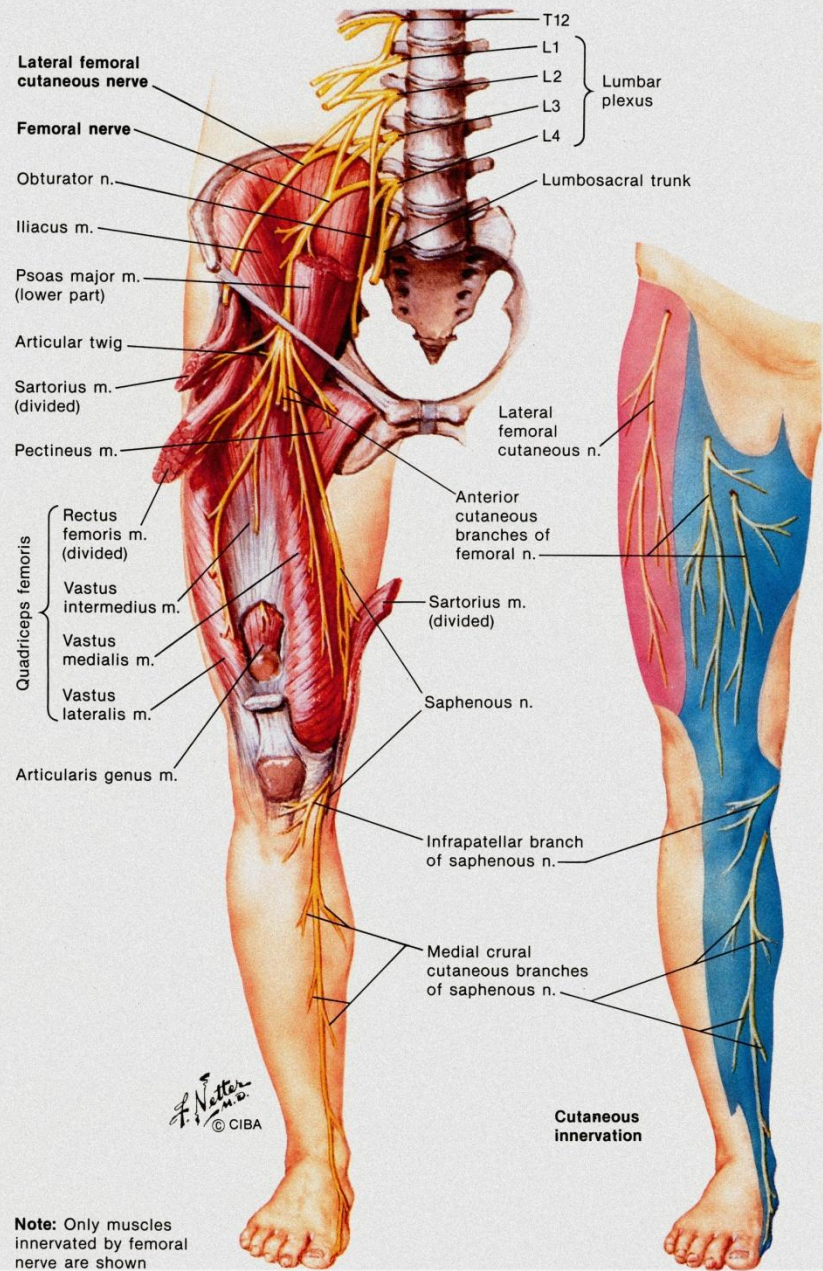
© MediVisuals
800-899-2154
Not authorized
for use without
permission.

Exhibit 202047_010





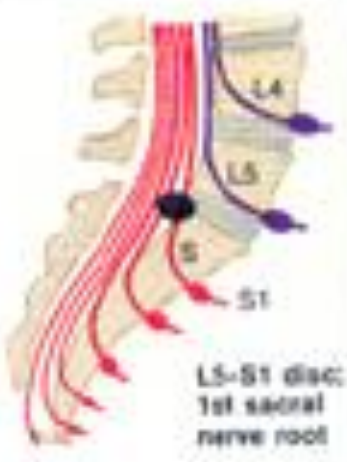





ANATOMY OF THE HEALTHY BACK



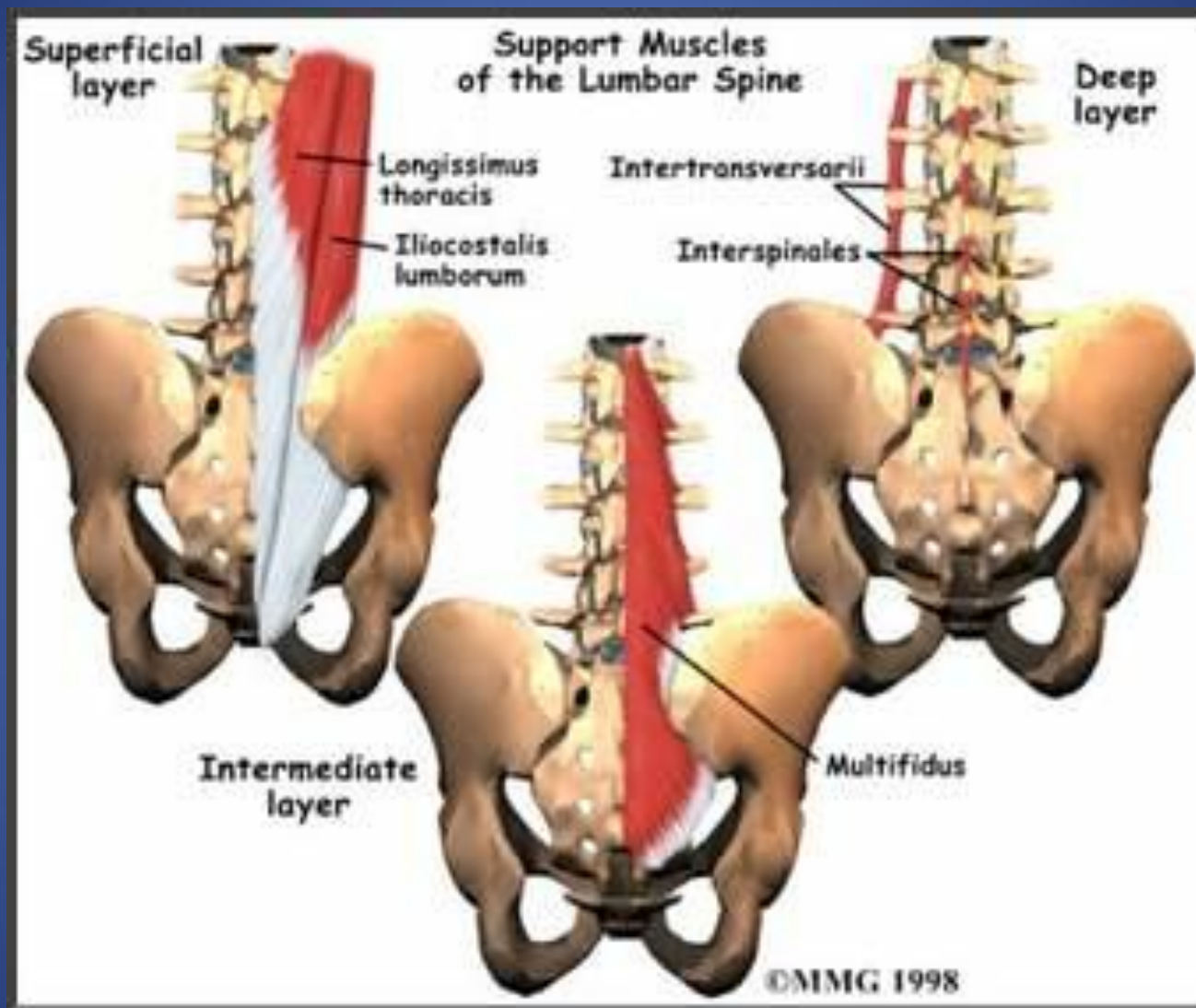
Femoral Nerve (L2, L3, L4) and Lateral Femoral Cutaneous Nerve (L2, L3)



Clinical features of herniated lumbar nucleus pulposus

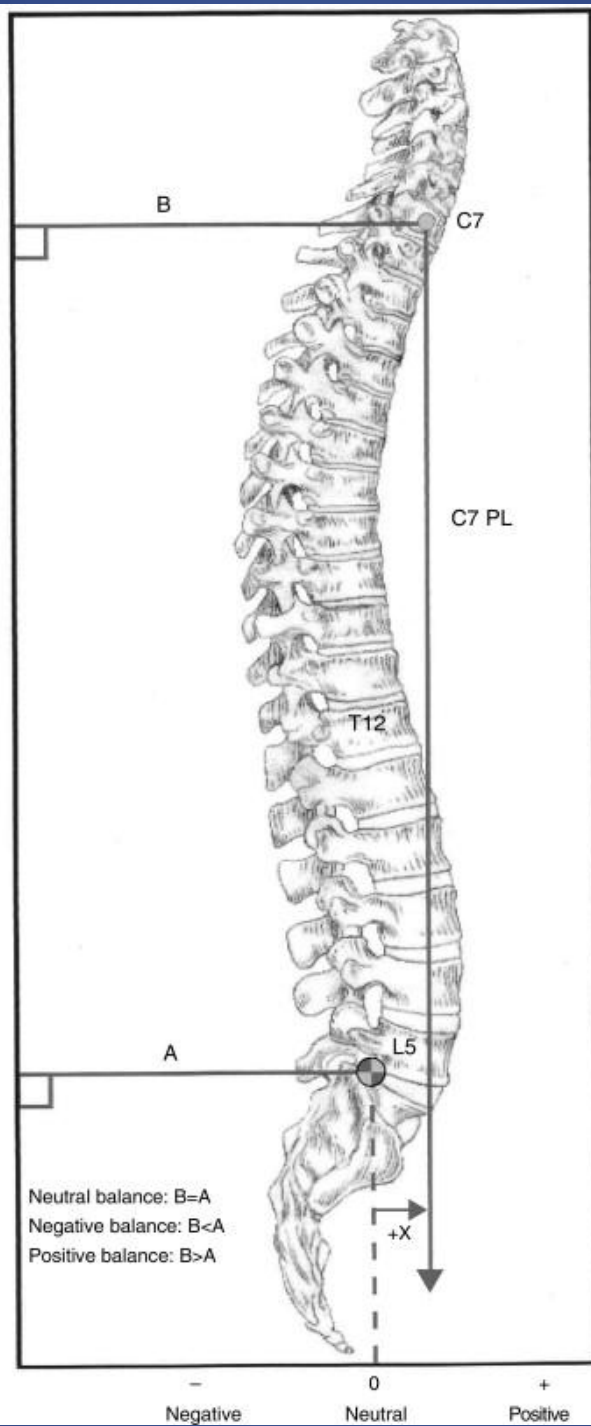
Level of herniation	Pain	Numbness	Weakness	Atrophy	Reflexes
 <p>L4-5 disc; 5th lumbar nerve root</p>	 <p>Over sacro-iliac joint, hip, lateral thigh and leg</p>	 <p>Lateral leg, feet 3 toes</p>	 <p>Dorsiflexion of great toe and foot; difficulty walking on heels; foot drop may occur</p>	Minor	Changes uncommon in knee and ankle jerks, but internal hamstring reflex diminished or absent
 <p>L5-S1 disc; 1st sacral nerve root</p>	 <p>Over sacro-iliac joint, hip, postero-lateral thigh and leg to heel</p>	 <p>Back of calf, lateral heel, foot and toe</p>	 <p>Plantar flexion of foot and great toe may be affected; difficulty walking on toes</p>	 <p>Gastrocnemius and soleus</p>	 <p>Ankle jerk diminished or absent</p>

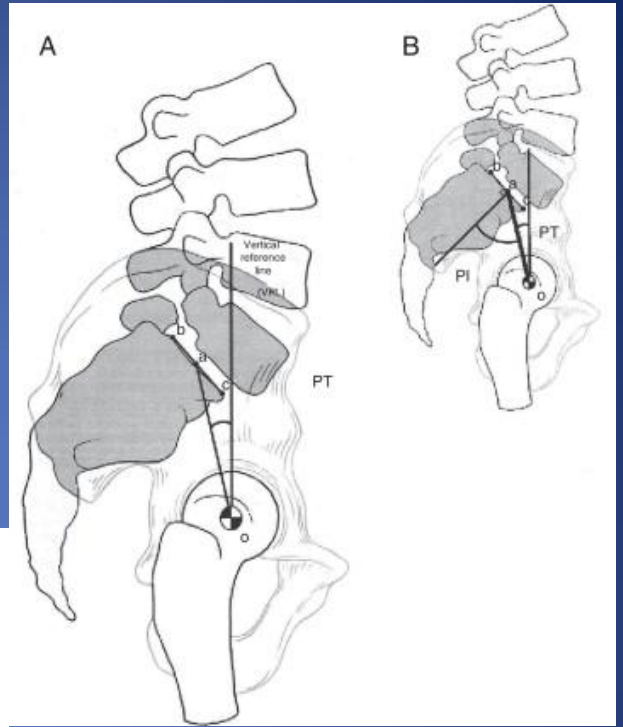
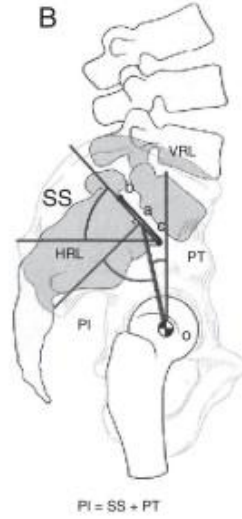
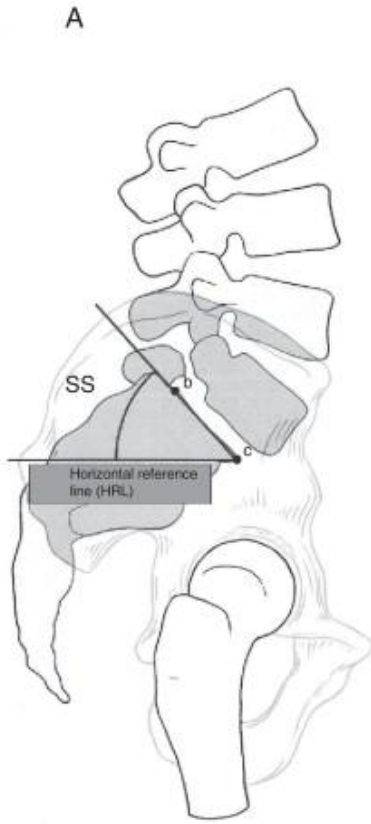
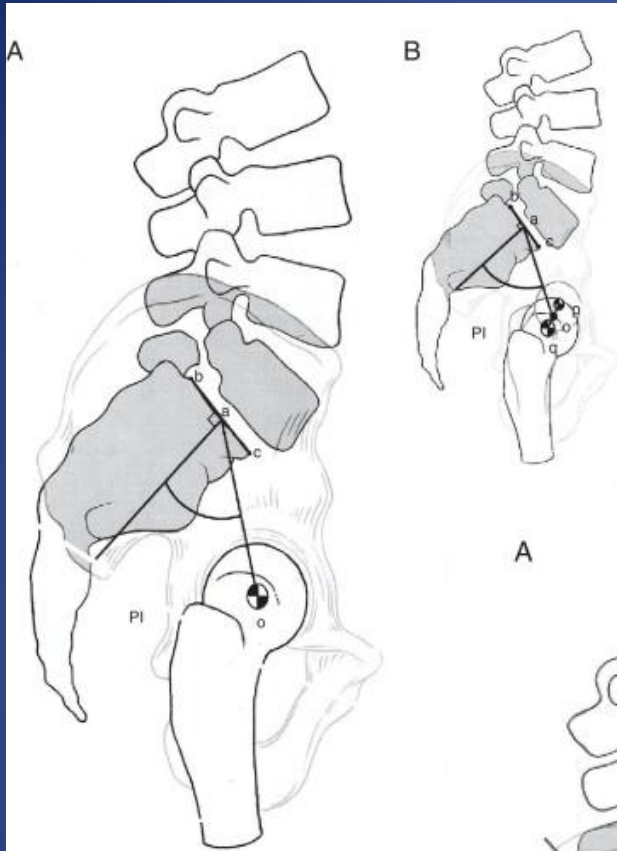
πλατυς
ραχιαίος

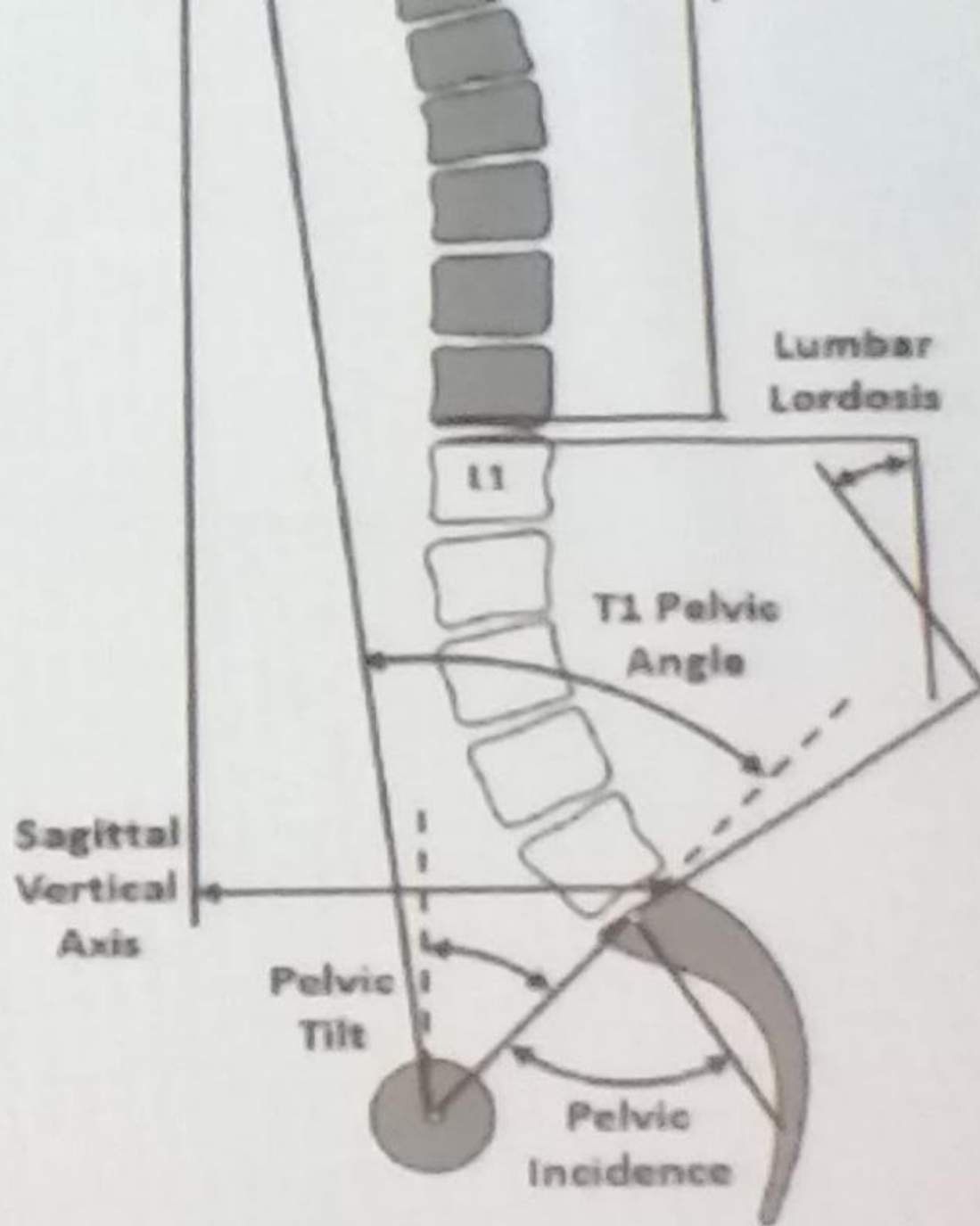


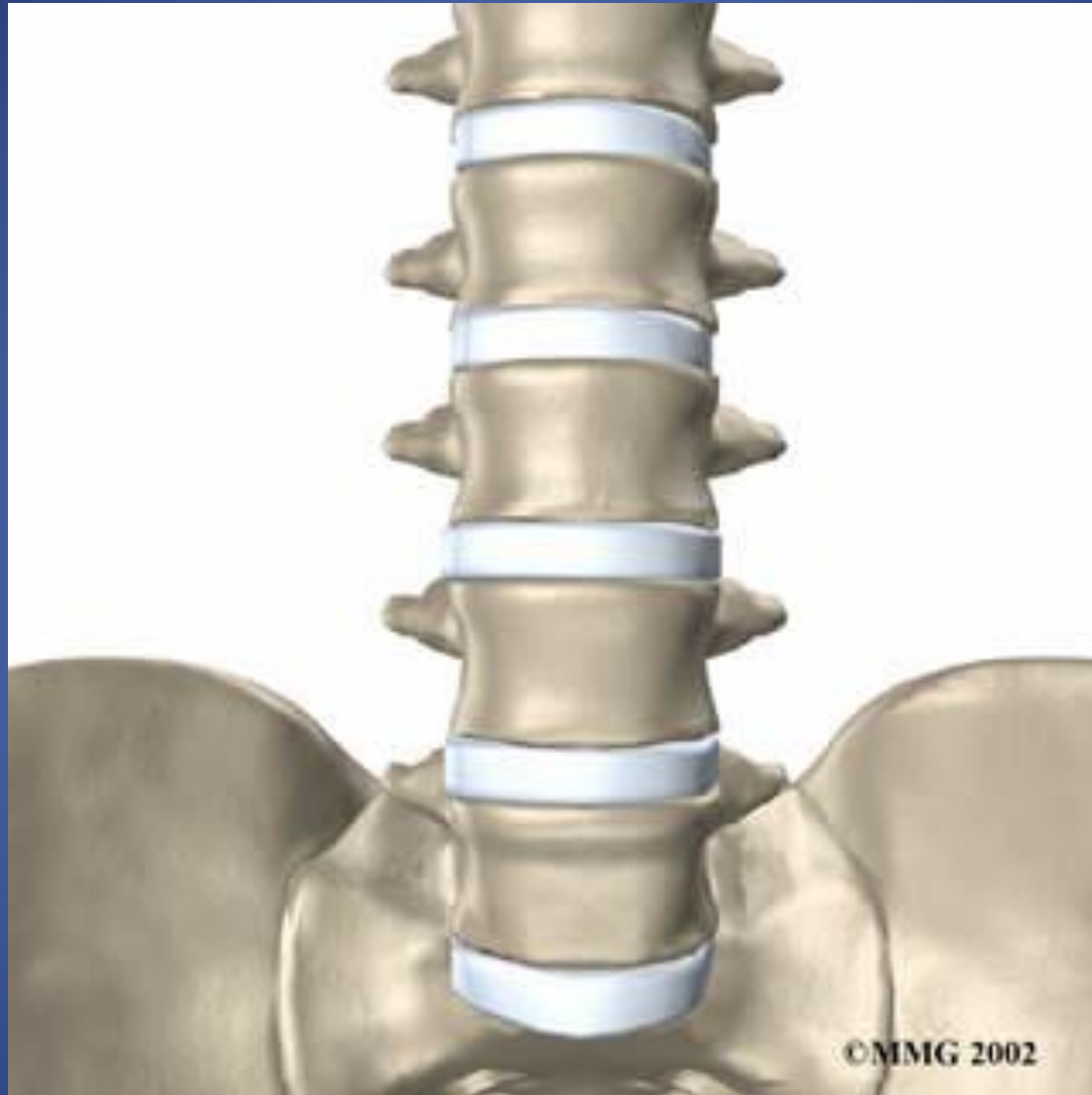
Ιδίως
ραχιαίοι

πολυσχιδής

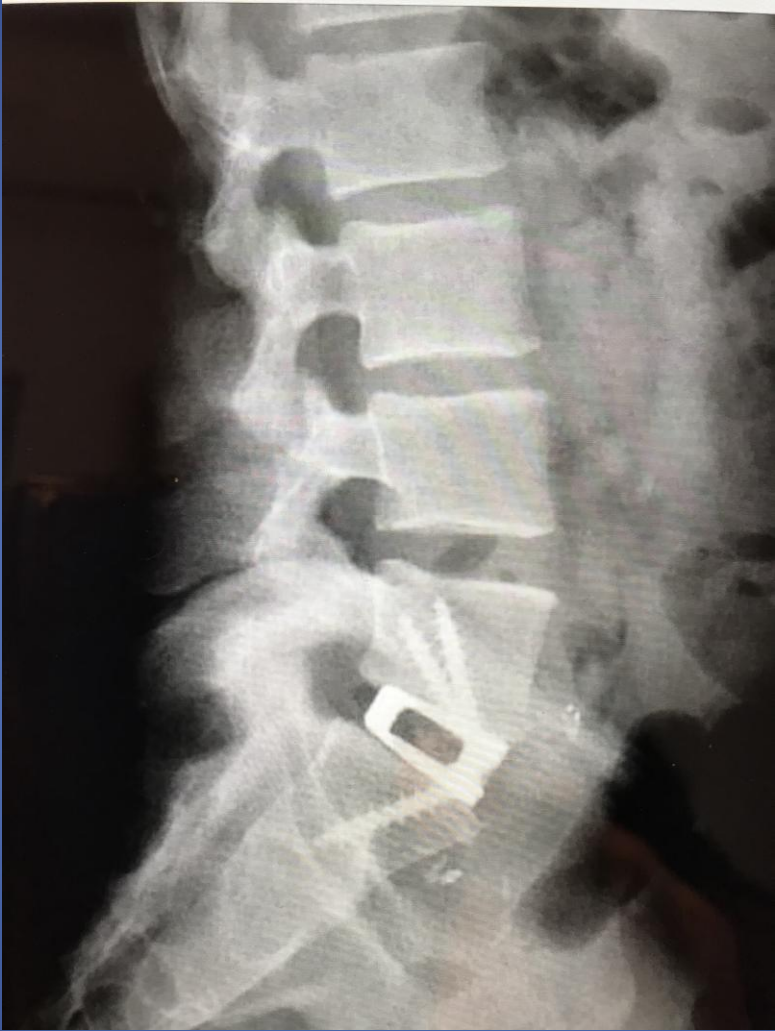


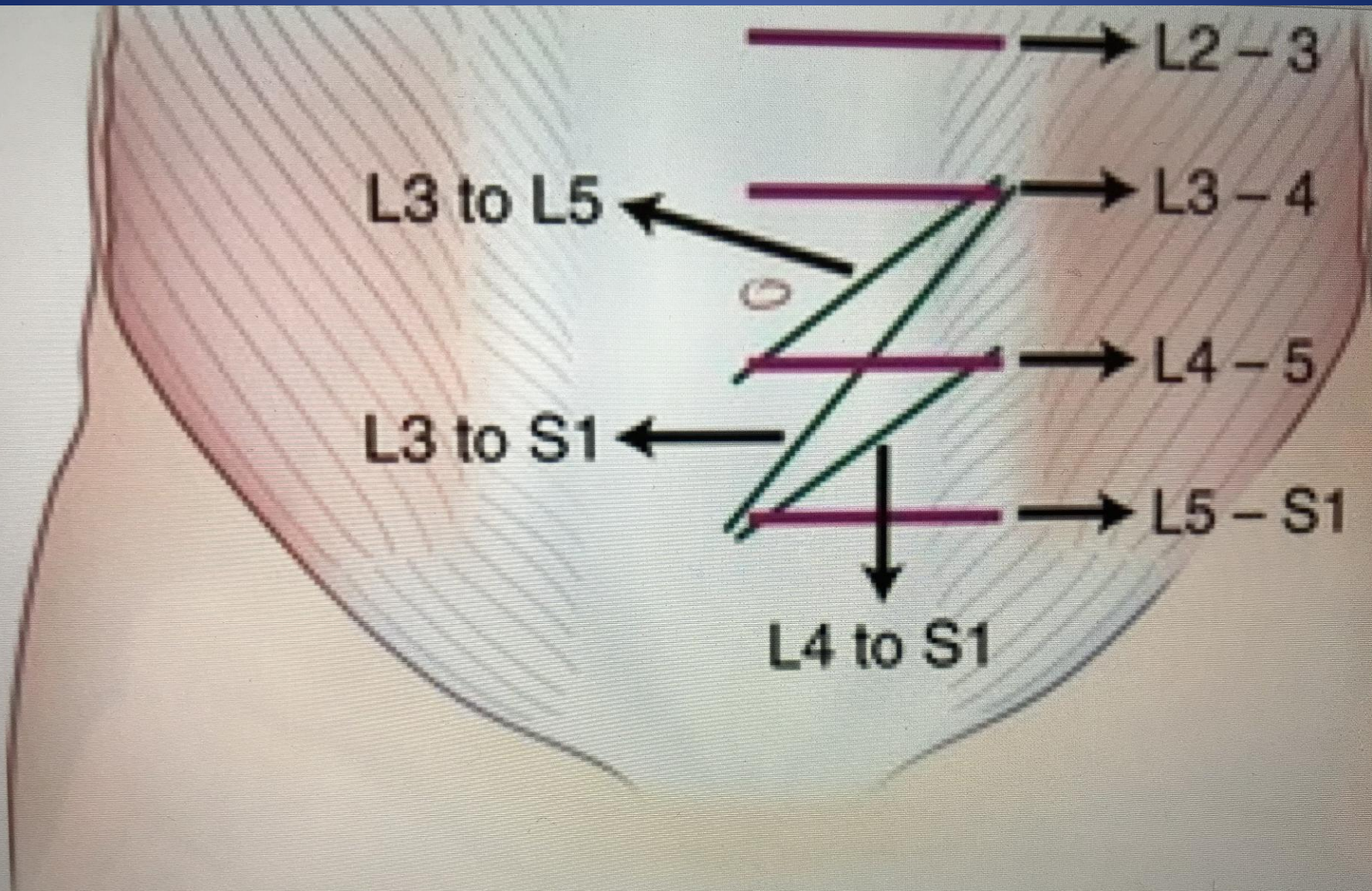


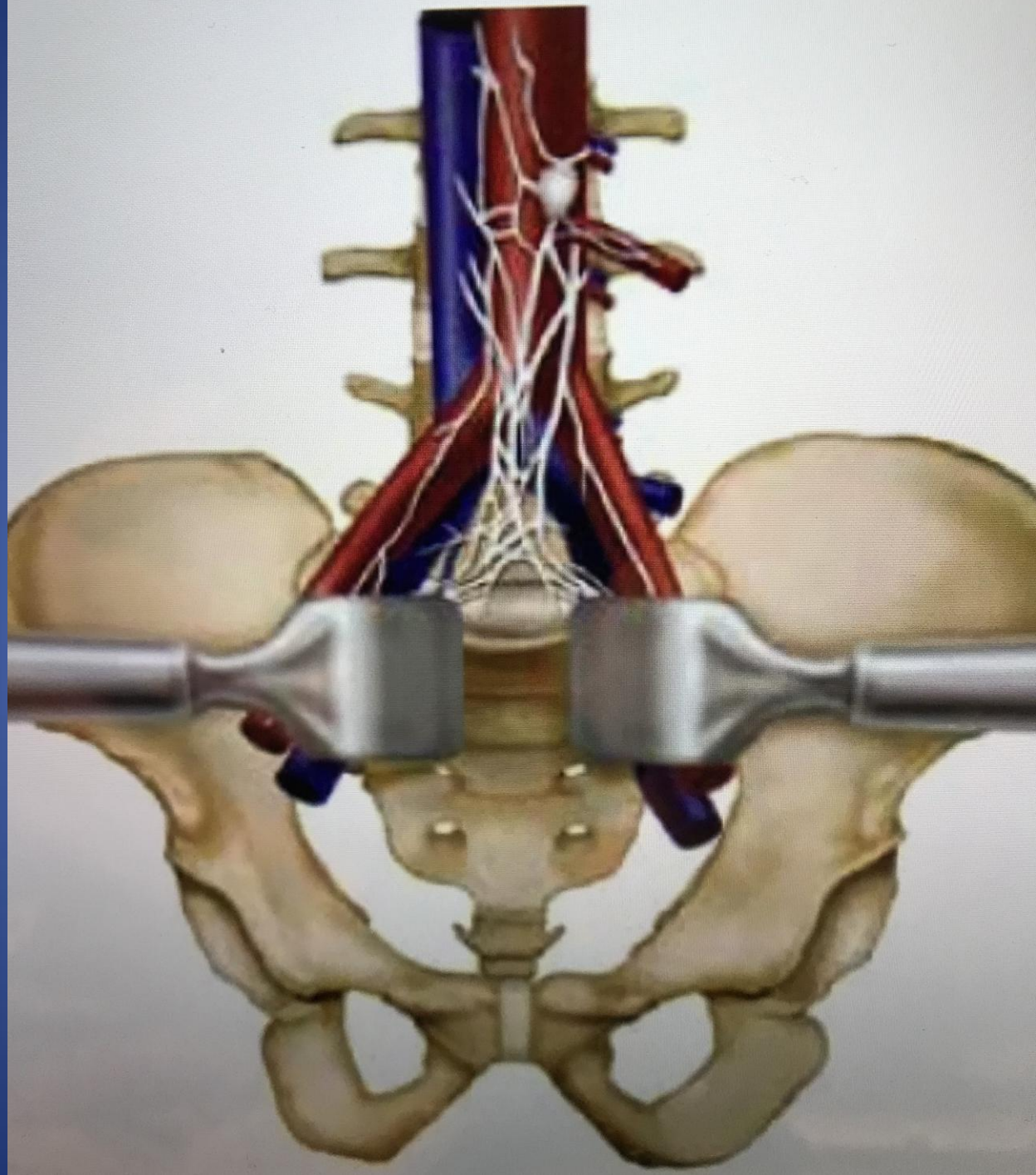




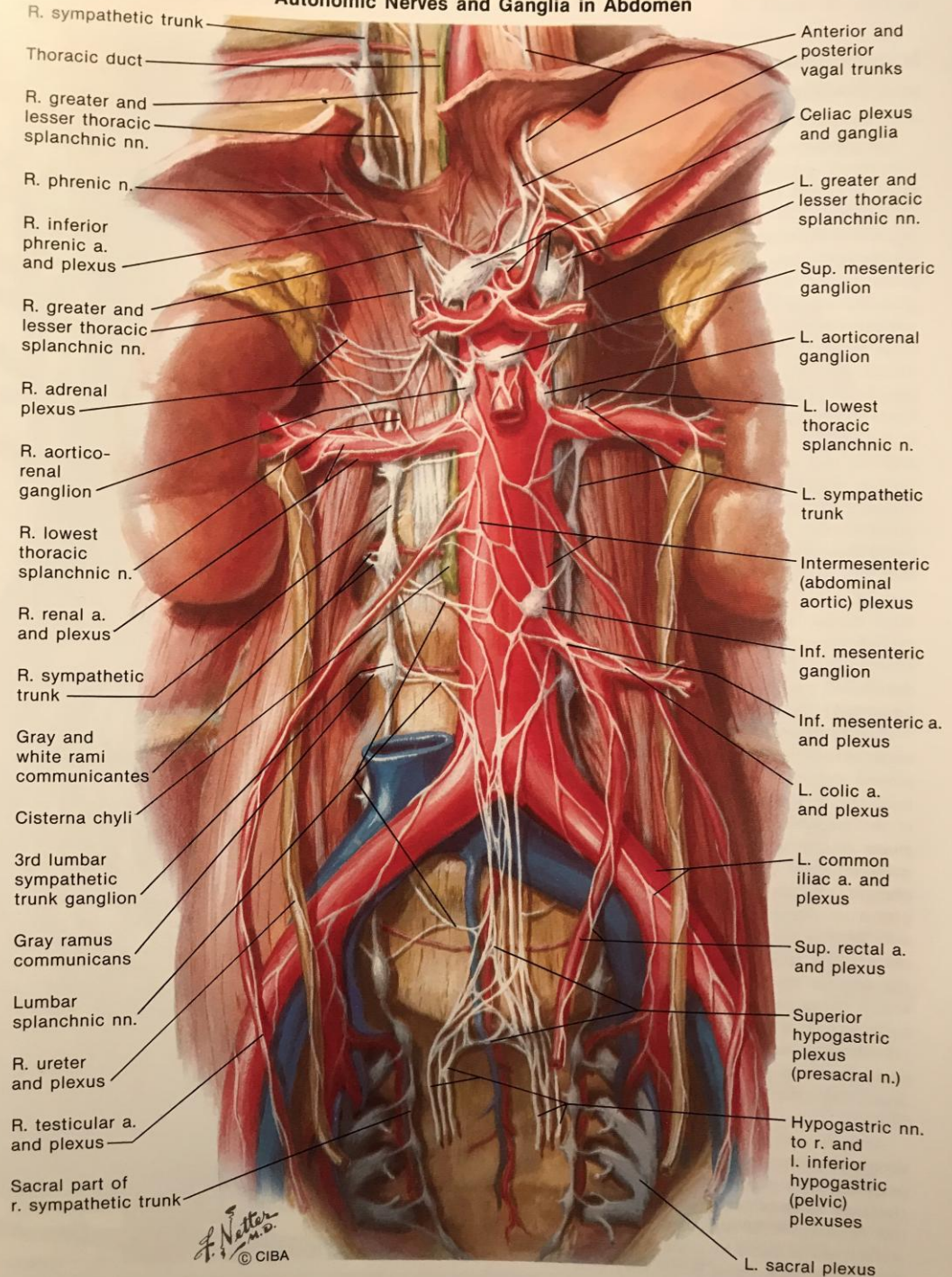
©MMG 2002





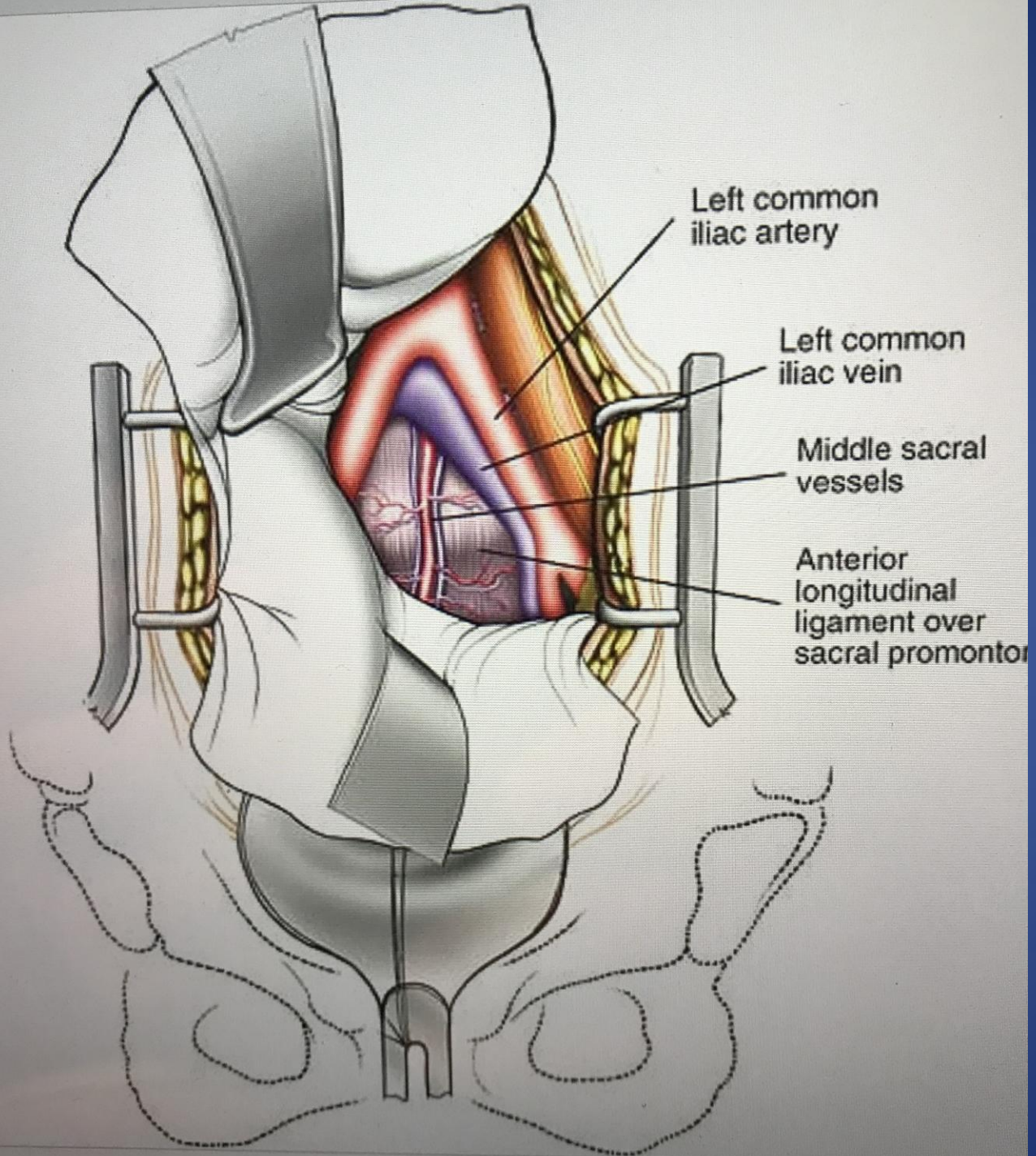


Autonomic Nerves and Ganglia in Abdomen



- R. sympathetic trunk
- Thoracic duct
- R. greater and lesser thoracic splanchnic nn.
- R. phrenic n.
- R. inferior phrenic a. and plexus
- R. greater and lesser thoracic splanchnic nn.
- R. adrenal plexus
- R. aortico-renal ganglion
- R. lowest thoracic splanchnic n.
- R. renal a. and plexus
- R. sympathetic trunk
- Gray and white rami communicantes
- Cisterna chyli
- 3rd lumbar sympathetic trunk ganglion
- Gray ramus communicans
- Lumbar splanchnic nn.
- R. ureter and plexus
- R. testicular a. and plexus
- Sacral part of r. sympathetic trunk

- Anterior and posterior vagal trunks
- Celiac plexus and ganglia
- L. greater and lesser thoracic splanchnic nn.
- Sup. mesenteric ganglion
- L. aortico-renal ganglion
- L. lowest thoracic splanchnic n.
- L. sympathetic trunk
- Intermesenteric (abdominal aortic) plexus
- Inf. mesenteric ganglion
- Inf. mesenteric a. and plexus
- L. colic a. and plexus
- L. common iliac a. and plexus
- Sup. rectal a. and plexus
- Superior hypogastric plexus (presacral n.)
- Hypogastric nn. to r. and l. inferior hypogastric (pelvic) plexuses
- L. sacral plexus



ANATOMY

Psoas Muscle

Peritoneum

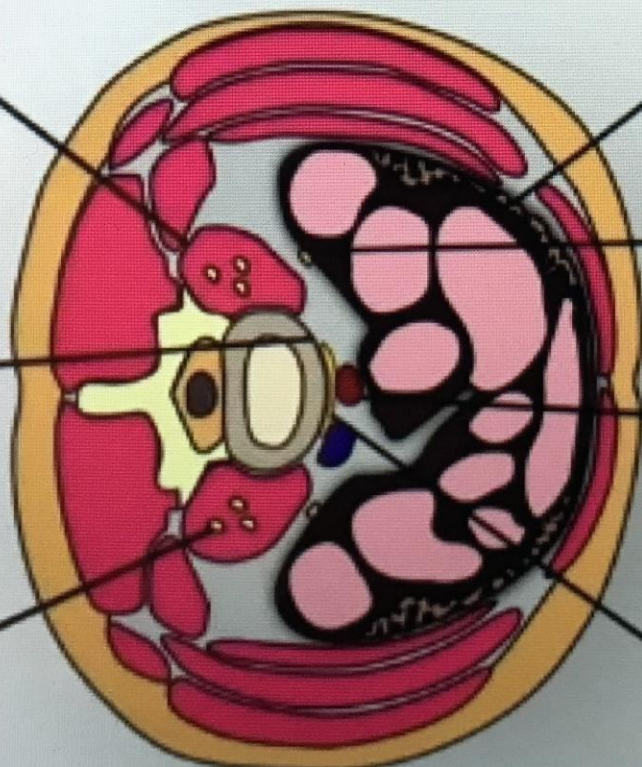
Sympathetic Chain

Ureter and Kidney

Lumbar Plexus

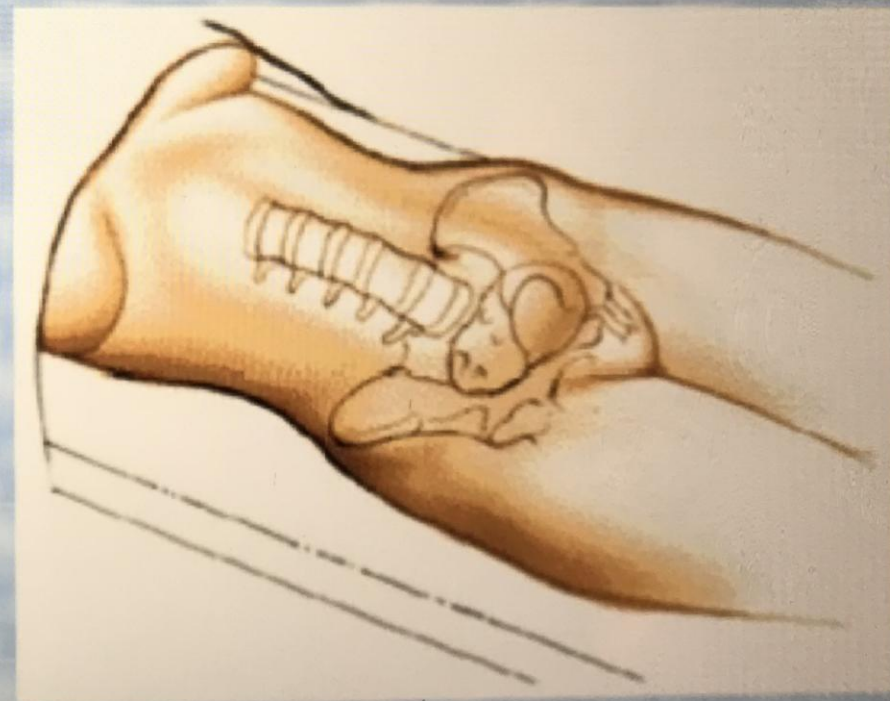
Vasculature

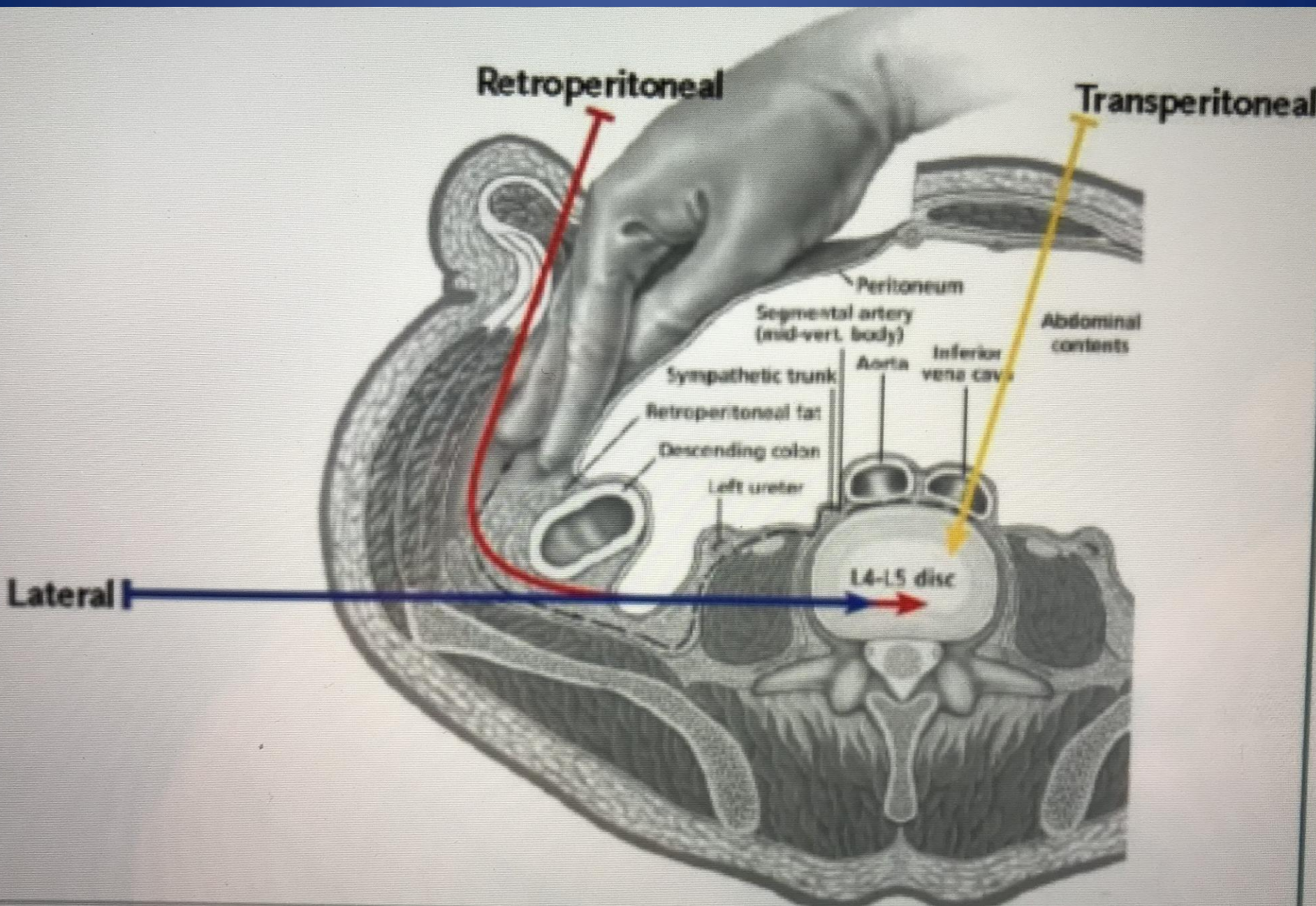
Anterior Longitudinal Ligament



Transperitoneal Approach to Lumbar Spine

- Indication
- L 4 L5 Fusion
- L5 S1 fusion
- Position- supine
- Catheterize
- NG tube
- Bare Area- Abd incision and Iliac crest bone graft





B

