

# IMAGE-GUIDED, ENDOSCOPIC-ASSISTED DRILLING AND EXPOSURE OF THE WHOLE LENGTH OF THE INTERNAL AUDITORY CANAL AND ITS FUNDUS WITH PRESERVATION OF THE INTEGRITY OF THE LABYRINTH USING A RETROSIGMOID APPROACH: A LABORATORY INVESTIGATION

## Promod Pillai, M.D., M.Ch.

Dardinger Microneurosurgical  
Skull Base Laboratory,  
Department of Neurological Surgery,  
The Ohio State University  
Medical Center,  
Columbus, Ohio

## Steffen Sammet, M.D., Ph.D.

Department of Radiology,  
The Ohio State University  
Medical Center,  
Columbus, Ohio

## Mario Ammirati, M.D., M.B.A.

Dardinger Microneurosurgical  
Skull Base Laboratory,  
Department of Neurological Surgery,  
The Ohio State University  
Medical Center,  
Columbus, Ohio

### Reprint requests:

Promod Pillai, M.D., M.Ch.,  
Dardinger Microneurosurgical  
Skull Base Laboratory,  
Department of Neurological Surgery,  
The Ohio State University  
Medical Center,  
N-1014 Doan Hall, 410 W. 10th Avenue,  
Columbus, Ohio 43210.  
Email: promod.pillai@osumc.edu

Received, June 6, 2008.

Accepted, December 3, 2008.

Copyright © 2009 by the  
Congress of Neurological Surgeons

**OBJECTIVE:** Hearing loss after removal of vestibular schwannomas with preservation of the cochlear nerve can result from labyrinthine injury of the posterior semicircular canal and/or common crus during drilling of the posterior wall of the internal auditory meatus. Indeed, there are no anatomic landmarks that intraoperatively identify the position of the posterior semicircular canal or of the common crus. We investigated the usefulness of image guidance and endoscopy for exposure of the internal auditory canal (IAC) and its fundus without labyrinthine injury during a retrosigmoid approach.

**METHODS:** A retrosigmoid approach to the IAC was performed on 10 whole fresh cadaveric heads after acquiring high-resolution computed tomographic scans (120 kV; slice thickness, 1 mm; field of vision, 40 cm; matrix, 512 × 512) with permanent bone-implanted reference markers. Drilling of the posterior wall of the IAC was executed with image guidance. Its most lateral area was visualized using endoscopy.

**RESULTS:** Target registration error for the procedure was 0.28 to 0.82 mm (mean, 0.46 mm; standard deviation, 0.16 mm). The measured length of the IAC along its posterior wall was  $9.7 \pm 1.6$  mm. The angle of drilling (angle between the direction of drill and the posterior petrous surface) was  $43.3 \pm 6.0$  degrees, and the length of the posterior wall of the IAC drilled without violating the integrity of the labyrinth was  $7.2 \pm 0.9$  mm. The surgical maneuvers in the remaining part of the IAC, including the fundus, were performed using an angled endoscope.

**CONCLUSION:** Frameless navigation using high-resolution computed tomographic scans and bone-implanted reference markers can provide a “roadmap” to maximize safe surgical exposure of the IAC without violating the labyrinth and leaving a small segment of the lateral IAC unexposed. Further exposure and surgical manipulation of this segment, including the fundus without additional cerebellar retraction and labyrinthine injury, can be achieved using an endoscope. Use of image guidance and an endoscope can help in exposing the entire posterior aspect of the IAC including its fundus without violating the labyrinth through a retrosigmoid approach. This technique could improve hearing preservation in vestibular schwannoma surgery.

**KEY WORDS:** Endoscope, Image guidance, Internal auditory canal, Labyrinth, Temporal bone, Vestibular schwannoma

*Neurosurgery* 65[ONS Suppl 1]:ons53–ons59, 2009

DOI: 10.1227/01.NEU.0000343521.88537.16

**ABBREVIATIONS:** AAO-HNS, American Academy of Otolaryngology–Head and Neck Surgery; **CT**, computed tomographic; **IAC**, internal auditory canal; **SD**, standard deviation

Hearing preservation has become one of the benchmarks when comparing treatment modalities for patients affected by vestibular schwannomas who have pretreat-

ment functional hearing. Functional hearing loss, even with anatomic preservation of the cochlear nerve, continues to be a problem despite the refinement of surgical techniques and intraoperative monitoring (3, 25). During a retrosigmoid approach to vestibular schwannomas, a variety of iatrogenic damages can contribute to postoperative hearing loss, including injury to the labyrinth while removing the posterior wall of the internal auditory canal (IAC), as well as injury to the cochlear nerve or to the labyrinthine artery while attempting to remove tumor located at the fundus of the IAC (1, 10–12, 18, 20, 24, 25). Because of the great anatomic variability of labyrinthine structures, there are no intraoperative landmarks that indicate their exact locations within the petrous bone (4, 14, 18). Therefore, opening of the IAC via the retrosigmoid route is based solely on preoperative image findings and on the personal experience of the surgeon. Thus, at the present time, there are neither standardized ways to protect the labyrinth nor definite parameters that indicate the specific risks of damage to the labyrinth (10–12, 18, 20, 24, 25).

Theoretically, because of its bony construct and lack of intraoperative shift, the temporal bone is an ideal site in which to utilize image-guided navigation. The use of endoscopes for posterior fossa surgery is steadily obtaining acceptance and has proven to be a viable adjunct to microsurgical approach to the lateral-most portion of the IAC, including its fundus (21, 22, 29, 34, 36). We investigated the usefulness of combining frameless stereotaxy with the endoscope for the complete removal of the posterior wall of the IAC and for exposure of its fundus without violating the integrity of the labyrinth through a retrosigmoid approach.

## MATERIALS AND METHODS

### Specimens and Computed Tomographic Protocol

Ten surgical dissections were performed bilaterally on 5 fresh cadavers. Six titanium microscrews were implanted onto the skull as permanent bone-reference markers. Cadavers were then subjected to high-resolution bony computed tomographic (CT) scans (slice thickness, 0.6 mm; contiguous nonoverlapping slices). The CT scanning was performed at a gantry of 0 degrees, with a scan window diameter of 225 mm and a pixel size of more than  $0.44 \times 0.44$ .

### Image Guidance

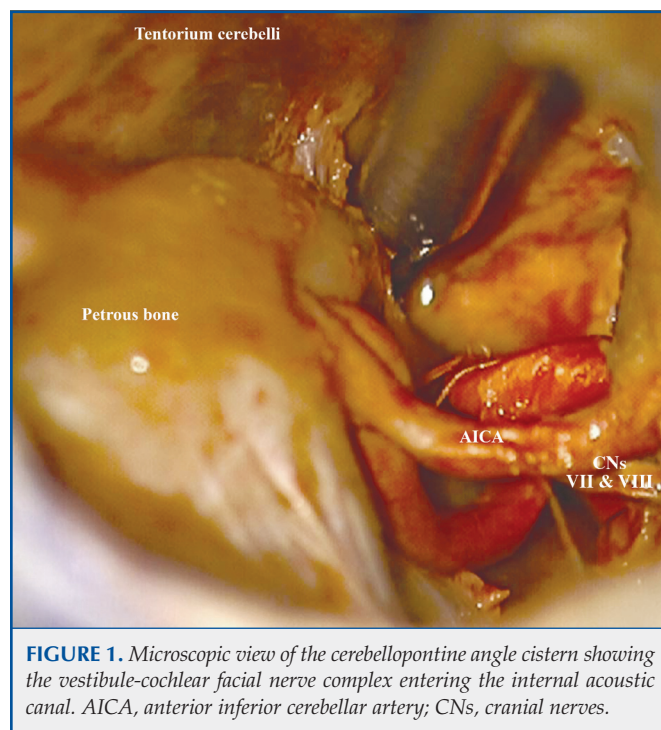
We used a Stryker Navigation System (Kalamazoo, MI) for intraoperative navigation. The Stryker Navigation System consists of planning software (iNtellect Cranial; Stryker), a frame on which 3 optical sensors are mounted, a patient tracker, and a pointer. Details on the operational use of this navigation system can be found in a previous publication (27). The entire length of the IAC and its fundus, as well as various labyrinthine structures, including the semicircular canals, the common crus, and the vestibule, were outlined on the reconstructed images using a semiautomatic segmentation technique. The posterior semicircular canal, the common crus, the vestibule, and the lateral-most point of the fundus were selected on the image sets as the targets for the purpose of measuring their distance from the tip of the selected navigation tool. However, the lateral-most point of the fundus was the only target intended to be reached by drilling the IAC.

### Endoscopes

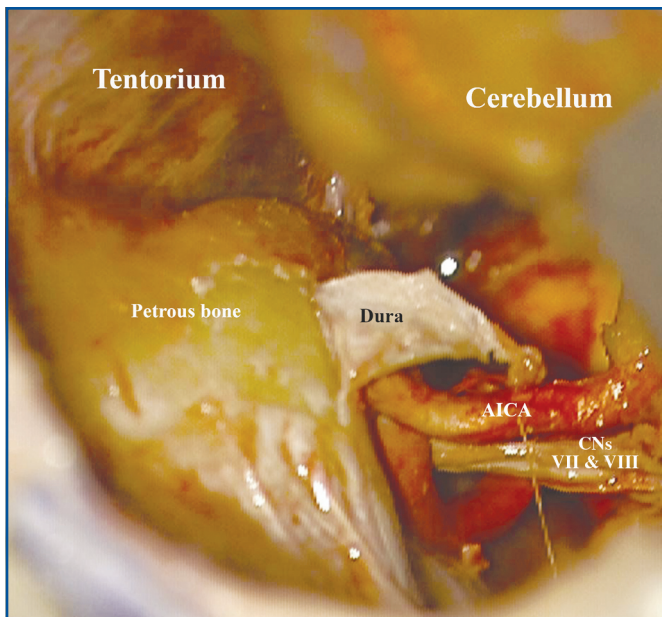
We used rigid endoscopes (Aesculap Co., Tuttlingen, Germany) measuring 2.7 and 4 mm in diameter, 18 cm in length, with 0- and 30-degree lenses. The endoscope was connected to a light source via a fiberoptic cable and to a video camera fitted with 3 charge-coupled device sensors that were connected to a video monitor supporting the high resolution of the charge-coupled device technology. Images and video were captured and recorded using a digital video recorder system.

### Surgical Procedure

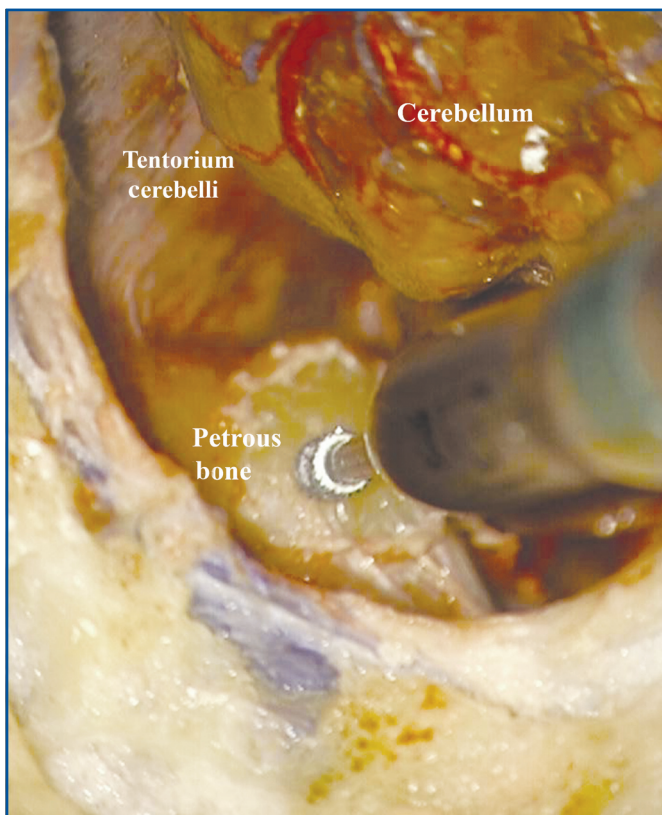
A standard retrosigmoid 3.5-cm craniotomy was made posterior to the sigmoid sinus and inferior to the transverse sinus. The dura was incised in standard manner and a cerebellar retractor was used to retract the cerebellum to simulate operative conditions. Cranial nerves VII and VIII were identified in the posterior fossa as they entered the internal auditory meatus (Fig. 1). The dura over the posterior lip of the internal auditory meatus was removed, after positive identification of the endolymphatic sac and duct (Fig. 2). The length of the IAC was measured using a microprobe. The lateral extent of the IAC was probed to analyze the maximum extent of the fundus, and the maximal length of the fundus was recorded using an angled microprobe. The posterior wall of the IAC was drilled with a high-speed diamond burr under continuous saline irrigation (Fig. 3). As the fundus was being approached, progressively smaller diamond burrs were used. Tool calibration was done for the microdrill (Midas Rex; Medtronic, Inc., Fort Worth, TX) and for the angled microprobe to allow for their intraoperative navigation so that we were able to direct those instruments toward the virtual target (lateral-most point on the fundus) drawn on the image. Intraoperative image guidance was continuously used during the drilling (Fig. 4). The drilling angle, which is defined as the angle between the drill and the posterior petrous surface, was measured in each dissection. During drilling, the amount of the remaining IAC was repeatedly assessed using image guidance and by palpating the fundus



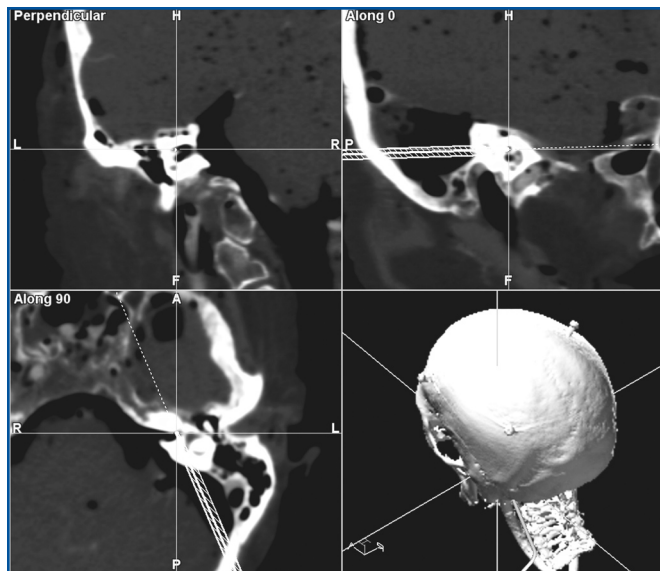
**FIGURE 1.** Microscopic view of the cerebellopontine angle cistern showing the vestibule-cochlear facial nerve complex entering the internal acoustic canal. AICA, anterior inferior cerebellar artery; CNs, cranial nerves.



**FIGURE 2.** Dural incision exposing the retromeatal petrous temporal bone. AICA, anterior inferior cerebellar artery; CNs, cranial nerves.



**FIGURE 3.** Drilling of the internal auditory canal (IAC) using a micro-drill.



**FIGURE 4.** Intraoperative navigation image obtained while exposing the IAC microscopically.

with an angled microprobe. Drilling of the posterior wall of the IAC was stopped when, according to the information provided by the navigation system, no more than 1 mm of bone was covering the labyrinthine structures (Figs. 4 and 5). The length of this drilled portion of the IAC was measured. This is the amount of accessible IAC without violating the integrity of the labyrinth. At this stage, we used a 30-degree angled, 2.7-mm, 18-cm long endoscope (Aesculap Co.) to visualize the fundus (Fig. 6). Using an angled microdissector under direct endoscopic guidance, we subjectively evaluated the ability to perform surgical maneuvers (mimicking those used during intracanalicular tumor removal) on the fundus.

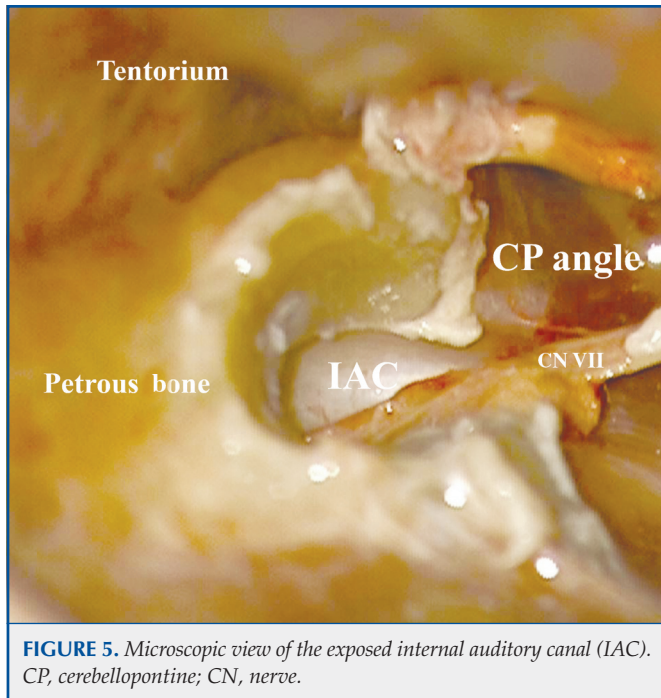
## RESULTS

Target registration errors reported by the neuronavigational software ranged from 0.28 to 0.82 mm (mean, 0.46 mm; standard deviation [SD], 0.16 mm). The measured length of the IAC along its posterior wall ranged from 7 to 11.9 mm (mean, 9.7; SD, 1.4 mm). The length of the posterior wall of the IAC exposed by drilling without injuring the labyrinth ranged from 5.8 to 8.4 mm (mean, 7.4; SD, 0.8 mm). The length of the IAC exposed under endoscopic vision ranged from 1.2 to 3.5 mm (mean, 2.35 mm). The drilling angle (the angle between the direction of the drill and the posterior petrous surface) ranged from 33 to 54 degrees (mean, 43 degrees; SD, 6 degrees). Table 1 shows all the described measurements.

## DISCUSSION

### Goals of Vestibular Schwannoma Surgery in Patients with Preoperative Hearing

The goals of vestibular schwannoma surgery have changed dramatically, from life-saving or life-lengthening to hearing and facial nerve function preservation (26). Whereas a high

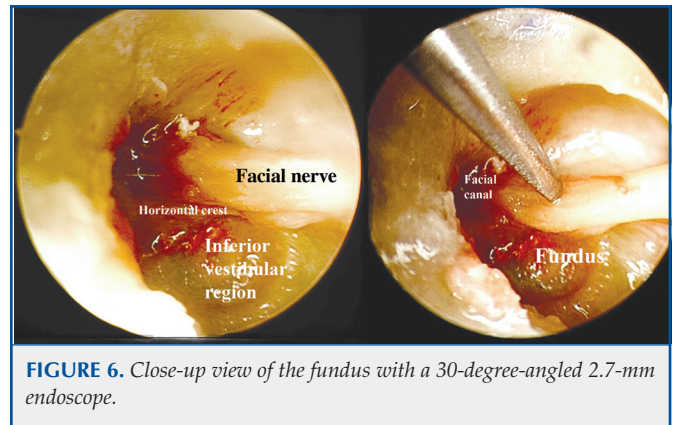


**FIGURE 5.** Microscopic view of the exposed internal auditory canal (IAC). CP, cerebellopontine; CN, nerve.

rate of acceptable facial nerve function is achieved postoperatively (House-Brackmann grade 1–2 outcomes are reported in at least 95% of intracanalicular, 85% of small, 75% of medium, and 40% of large tumors), the same is not true for hearing preservation. The overall serviceable hearing preservation, American Academy of Otolaryngology–Head and Neck Surgery (AAO-HNS) class A or B for tumors smaller than 2 cm in major diameter is 40% to 50% (3).

Indeed, the earlier identification of small tumors challenges the clinician to formulate the most appropriate management strategy for functional preservation for a given individual (2, 3, 26). With other effective, alternative management options available, including radiosurgery or a conservative approach with no intervention at all, functional hearing preservation becomes an important benchmark to evaluate the results of surgery in patients with preoperative functional hearing (2, 13, 26).

The debate regarding which hearing preservation approach to use for surgical management of vestibular schwannoma removal is ongoing. Prerequisites for hearing preservation include preservation of the labyrinthine structures, of the integrity of the cochlear nerve, and of the cochlear vascular (1). Three principal approaches are used to surgically remove vestibular schwannomas: the translabyrinthine, the retrosigmoid, and the middle fossa approaches. Two of the 3 approaches, the middle cranial fossa and retrosigmoid approaches, may anatomically preserve hearing. It is difficult to assess hearing preservation rates reported in the literature because of different hearing selection and reporting criteria chosen by different authors (15). The AAO-HNS grade for hearing is the most accepted grading system for assessing the hearing function in acoustic schwannomas (3, 8).



**FIGURE 6.** Close-up view of the fundus with a 30-degree-angled 2.7-mm endoscope.

Harsha and Backous (13) recently reviewed the English-language literature reporting hearing outcome using either the AAO-HNS or the Gardner-Robinson hearing outcome scales. Of the 1132 articles evaluated, 31 met the criteria and only 14 compared 1 or more outcome measures for more than 1 approach from the same institution. Serviceable hearing (AAO-HNS class A or B/Gardner-Robinson class 1 or 2) was present postoperatively in 618 of 2034 patients (30%) treated with the hearing preservation approach. Results were better with the middle fossa approach (523 of 1017, 51%) than with the retrosigmoid approach (95 of 304, 31%) (13). However, no correlations were made among tumor size, surgical approach, and hearing preservation.

### Retrosigmoid Approach

The retrosigmoid approach has traditionally been the most widely used approach by neurosurgeons because of its versatility. The retrosigmoid approach provides immediate and accurate identification of the tumor, the IAC, and relevant neurovascular structures.

The retrosigmoid approach also provides wide exposure of the posterior fossa, can be used for excision of small and large tumors, and is anatomically suited to preserve hearing. A major drawback of this approach is the difficulty in removing the tumor from the most lateral portions of the IAC without violating the labyrinth or without blind removal of the tumor from the fundus of the IAC. Because of its angle in the petrous bone and to the intervening cerebellum, the fundus is difficult to reach. To expose the intrameatal tumor, the posterior lip of the IAC has to be drilled away, which may cause damage to the posteromedial part of the inner ear structures. The structures at risk are represented by the common crus, the vestibular aqueduct, and the posterior semicircular canal. If the tumor extends laterally in the IAC and one wants to limit the posterior meatal lip drilling because of fear of injury to the bony labyrinth, the residual tumor must be blindly removed from the fundus with possible cochlear nerve injury.

The conundrum is that extensive drilling of the IAC is not possible without labyrinthine injury. Because limited IAC drilling does not expose the lateral-most portion of the tumor,

**TABLE 1. Intraoperative measurements of anatomic dissections<sup>a</sup>**

Procedure	IAC length (mm)	Microscopically exposed IAC (mm)	Endoscopically exposed IAC (mm)	Drilling angle (degrees)	Target registration error
1	9.3	7.1	2.2	45	0.43
2	7.0	5.8	1.2	33	0.61
3	10.2	8.2	2.0	43	0.34
4	10.2	7.2	3.0	43	0.28
5	9.1	6.9	2.2	51	0.46
6	10.1	7.1	3.0	42	0.35
7	10.5	8.2	2.3	54	0.82
8	11.9	8.4	3.5	41	0.50
9	10.8	8.1	2.7	44	0.44
10	8.2	6.7	1.5	37	0.40
Mean	9.7	7.4		43	0.46

<sup>a</sup> IAC, internal auditory canal.

controlled removal of the tumor from the fundus without cochlear nerve injury is not possible with limited drilling. Both factors can ultimately contribute to hearing compromise in a retrosigmoid operation despite anatomic preservation of the cochlear nerve.

### Image-Guided Navigation of the Temporal Bone

Literature pertaining to the application of image guidance during temporal bone surgery is scarce (5–7, 9, 19, 28, 31–33). Samii et al. (28) attempted navigation-guided opening of the IAC via the retrosigmoid route for acoustic neuroma surgery and achieved a mean registration error of  $0.25 \pm 0.03$  mm and a mean anatomic localization error of  $0.67 \pm 0.2$  mm. Miller and Pensak (23) investigated the usefulness of an electromagnetic image-guidance surgical navigation system in localizing the midpoint of the IAC and other structures of the temporal bone with the middle cranial fossa approach and were able to identify the middle of the IAC within 2.31 mm of the actual target.

In our own previous investigation of the global accuracy of CT-based image-guided navigation in approaching the temporal bone, we obtained a mean accuracy of 0.93 mm with 95% of targets reached within 1.41 mm of the actual targets (27). Thus, image-guided navigation can provide a roadmap and give valuable “alerts” to the surgeon while drilling the posterior meatal lip.

### Endoscopes and Cerebellopontine Angle Surgery

The use of endoscopes for surgery of cerebellopontine angle tumors is obtaining acceptance (17, 21, 22, 29, 30, 34–36). Whereas endoscopic inspection for vestibular schwannomas during surgery has obtained widespread acceptance, the advantages of endoscope-controlled removal of these tumors are less clear (29). The endoscope provides improved visualization of narrow corridors and angled trajectories, whereas the operating microscope provides a poor visualization. The use of

endoscopes with angled lenses can provide better visibility of the “blind” area of the fundus of the IAC, increasing the safety of tumor resection (29). Endoscopic inspection can confirm the completeness of tumor resection or assist in locating residual tumor that might have been left at the IAC fundus. It enables the removal of intracanalicular tumors, with direct control of the lateral intracanalicular nerve portions.

### Present Study

#### *Image-Guided Endoscopic-Assisted Drilling of the Posterior Wall of the IAC*

Because the traditional retrosigmoid approach is widely used and is familiar to most neurosurgeons, we reasoned that it would be worthwhile to investigate the integration of image guidance and endoscopic techniques to optimize the surgical exposure of the IAC through a retrosigmoid approach. The most challenging goal in the current management of vestibular schwannomas is the ability to preserve hearing, which is increasingly important because many patients considered for treatment have a degree of intact hearing at the time of presentation. Labyrinthine injury, while attempting to expose the intracanalicular part of the tumor, is a well-established cause of postoperative hearing loss in such patients, and many neurotologists admit that it is often impossible to expose the IAC without violating the labyrinthine integrity (3). The aim of this anatomic study was to investigate, using quantitative data, the utility of CT-based frameless stereotaxy and endoscopy to optimize safe drilling of the IAC and controlled exposure of the fundus without violating the integrity of the labyrinth or injuring the cochlear nerve.

Our study has shown that 70% to 80% of the posterior wall of the IAC can be drilled without injuring the labyrinth and that this drilling can be safely pushed to its limit by using image guidance. Still, the lateral-most portion of the IAC is inaccessible with the microscopic approach without undue cerebellar retraction.

However, it can be safely exposed using a 2.7-mm endoscope with a 30-degree angled lens. The potential usefulness of the endoscope lies in its ability to visualize the IAC beyond the limit of the microscopically drilled posterior wall. Using an angled endoscope, we were able to safely perform surgical maneuvers in and around the IAC fundus. This technique of integrating image guidance and the endoscope may provide a viable clinical paradigm to safely drill the IAC and perform surgical maneuvers in and around the IAC fundus. The usefulness of the endoscope might be enhanced in the future by the development of angled microdrills to be used through the endoscope working channel.

### Angle of Drilling

The drilling angle, angle between the drill and the posterior pyramis wall, is surgically relevant because it is directly linked to the amount of cerebellar retraction. Previous anatomic studies have shown that complete unroofing of the posterior wall of the IAC without labyrinthine entry can be achieved with a drilling angle of 90 degrees (10). However, in clinical practice, a drilling angle of 90 degrees is associated with significant cerebellar retraction and is not practical. It has been estimated that a drilling angle of 60 degrees is safe in clinical situations even though it does not allow complete exposure of the fundus (10). In a recent anatomic study, King and Wackym (16) stated that it was possible to remove a full two-thirds of the posterior canal wall of the IAC without labyrinthine entry using a drilling angle of 30 degrees.

Our study shows that it is possible, by using image guidance, to safely remove three-quarters of the posterior wall of the IAC without labyrinthine entry and by using a safe drilling angle of  $43 \pm 6$  degrees.

### Limitations of the Present Study

Our study is an anatomic study. Clearly, only clinical application of our suggested technique can demonstrate its validity. However, our study forms the foundation and the rationale for the proposed approach to the IAC and its fundus.

## CONCLUSION

Because hearing preservation is the accepted benchmark for comparing the results of various modes of treatment for vestibular schwannomas, it is important to optimize the hearing outcome in the retrosigmoid approach to the IAC.

Frameless navigation using high-resolution CT scanning and bone-implanted reference markers can maximize safe drilling of the IAC without violating the labyrinth, leaving behind a small segment of lateral IAC unexposed. Further exposure of the fundus without substantial cerebellar retraction and labyrinthine injury can be achieved using an endoscope. Use of image guidance and an endoscope during a retrosigmoid approach can aid in performing surgical maneuvers under direct vision of the entire length of the IAC, including its fundus, without violating the labyrinth and injuring the cochlear nerve. This could improve the hearing preservation rate in patients with preoperative functional hearing.

## Disclosure

This study was funded by Dardinger Center Fund for Neurooncology Research at Arthur G. James Cancer Hospital, Ohio State University Medical Center. The authors have no personal financial or institutional interest in any of the drugs, materials, or devices described in this article.

## REFERENCES

1. Ammirati M, Ma J, Cheatham ML, Maxwell D, Bloch J, Becker DP: Drilling the posterior wall of the petrous pyramid: A microneurosurgical anatomical study. *J Neurosurg* 78:452–455, 1993.
2. Backous DD, Pham HT: Guiding patients through the choices for treating vestibular schwannomas: Balancing options and ensuring informed consent. *Otolaryngol Clin North Am* 40:521–540, 2007.
3. Bennett M, Haynes DS: Surgical approaches and complications in the removal of vestibular schwannomas. *Otolaryngol Clin North Am* 40:589–609, 2007.
4. Blevins NH, Jackler RK: Exposure of the lateral extremity of the internal auditory canal through the retrosigmoid approach: A radioanatomic study. *Otolaryngol Head Neck Surg* 111:81–90, 1994.
5. Brinker T, Arango G, Kaminsky J, Samii A, Thorns U, Vorkapic P, Samii M: An experimental approach to image guided skull base surgery employing a microscope-based neuronavigation system. *Acta Neurochir (Wien)* 140:883–889, 1998.
6. Caversaccio M, Langlotz F, Nolte LP, Häusler R: Impact of a self-developed planning and self-constructed navigation system on skull base surgery: 10 years experience. *Acta Otolaryngol* 127:403–407, 2007.
7. Caversaccio M, Romualdez J, Baechler R, Nolte LP, Kompis M, Häusler R: Valuable use of computer-aided surgery in congenital bony aural atresia. *J Laryngol Otol* 117:241–248, 2003.
8. Committee on Hearing and Equilibrium: Committee on Hearing and Equilibrium guidelines for the evaluation of hearing preservation in acoustic neuroma (vestibular schwannoma). *Otolaryngol Head Neck Surg* 113:179–180, 1995.
9. Copeland BJ, Senior BA, Buchman CA, Pillsbury HC 3rd: The accuracy of computer-aided surgery in neurotologic approaches to the temporal bone: A cadaver study. *Otolaryngol Head Neck Surg* 132:421–428, 2005.
10. Day JD, Kellogg JX, Fukushima T, Giannotta SL: Microsurgical anatomy of the inner surface of the petrous bone: Neuroradiological and morphometric analysis as an adjunct to the retrosigmoid transmeatal approach. *Neurosurgery* 34:1003–1008, 1994.
11. Domb GH, Chole RA: Anatomical studies of the posterior petrous apex with regard to hearing preservation in acoustic neuroma removal. *Laryngoscope* 90:1769–1776, 1980.
12. Haberkamp TJ, Meyer GA, Fox M: Surgical exposure of the fundus of the internal auditory canal: Anatomic limits of the middle fossa versus the retrosigmoid transcanal approach. *Laryngoscope* 108:1190–1194, 1998.
13. Harsha WJ, Backous DD: Counseling patients on surgical options for treating acoustic neuroma. *Otolaryngol Clin North Am* 38:643–652, 2005.
14. Kartush JM, Telian SA, Graham MD, Kemink JL: Anatomic basis for labyrinthine preservation during posterior fossa acoustic tumor surgery. *Laryngoscope* 96:1024–1028, 1986.
15. Kaylie DM, Gilbert E, Horgan MA, Delashaw JB, McMenomey SO: Acoustic neuroma surgery outcomes. *Otol Neurotol* 22:686–689, 2001.
16. King WA, Wackym PA: Endoscope-assisted surgery for acoustic neuromas (vestibular schwannomas): Early experience using the rigid Hopkins telescope. *Neurosurgery* 44:1095–1102, 1999.
17. Koval J, Molcan M, Bowdler AD, Sterkers JM: Retrosigmoid transmeatal approach: An anatomic study of an approach used for preservation of hearing in acoustic neuroma surgery and vestibular neurotomy. *Skull Base Surg* 3:16–21, 1993.
18. Krajewski R, Kukwa A: Infratentorial approach to internal acoustic meatus. *Skull Base Surg* 9:81–85, 1999.
19. Kurtsoy A, Menku A, Tucer B, Oktem IS, Akdemir H: Neuronavigation in skull base tumors. *Minim Invasive Neurosurg* 48:7–12, 2005.
20. Laine T, Johnsson LG, Palva T: Surgical anatomy of the internal auditory canal. A temporal bone dissection study. *Acta Otolaryngol* 110:78–84, 1990.
21. Low WK: Enhancing hearing preservation in endoscopic-assisted excision of acoustic neuroma via the retrosigmoid approach. *J Laryngol Otol* 113:973–977, 1999.

22. McKennan KX: Endoscopy of the internal auditory canal during hearing conservation acoustic tumor surgery. *Am J Otol* 14:259–262, 1993.
23. Miller RS, Pensak ML: An anatomic and radiologic evaluation of access to the lateral internal auditory canal via the retrosigmoid approach and description of an internal labyrinthectomy. *Otol Neurotol* 27:697–704, 2006.
24. Miller RS, Hashisaki GT, Kesser BW: Image-guided localization of the internal auditory canal via the middle cranial fossa approach. *Otolaryngol Head Neck Surg* 134:778–782, 2006.
25. Mohr G, Sade B, Dufour JJ, Rappaport JM: Preservation of hearing in patients undergoing microsurgery for vestibular schwannoma: Degree of meatal filling. *J Neurosurg* 102:1–5, 2005.
26. Myrseth E, Pedersen PH, Møller P, Lund-Johansen M: Treatment of vestibular schwannomas. Why, when and how? *Acta Neurochir (Wien)* 149:647–660, 2007.
27. Pillai P, Sammet S, Ammirati M: Application accuracy of computed tomography-based image-guided navigation of the temporal bone. *Neurosurgery* 63 [Suppl 2]:326–333, 2008.
28. Samii A, Brinker T, Kaminsky J, Lanksch WR, Samii M: Navigation-guided opening of the internal auditory canal via the retrosigmoid route for acoustic neuroma surgery: Cadaveric, radiological, and preliminary clinical study. *Neurosurgery* 47:382–388, 2000.
29. Tatagiba M, Matthies C, Samii M: Microendoscopy of the internal auditory canal in vestibular schwannoma surgery. *Neurosurgery* 38:737–740, 1996.
30. Valtonen HJ, Poe DS, Heilman CB, Tarlov EC: Endoscopically assisted prevention of cerebrospinal fluid leak in suboccipital acoustic neuroma surgery. *Am J Otol* 18:381–385, 1997.
31. Van Havenbergh T, Koekelkoren E, De Ridder D, Van De Heyning P, Verlooy J: Image guided surgery for petrous apex lesions. *Acta Neurochir (Wien)* 145:737–742, 2003.
32. Vrionis FD, Foley KT, Robertson JH, Shea JJ 3rd: Use of cranial surface anatomic fiducials for interactive image-guided navigation in the temporal bone: A cadaveric study. *Neurosurgery* 40:755–764, 1997.
33. Vrionis FD, Robertson JH, Foley KT, Gardner G: Image-interactive orientation in the middle cranial fossa approach to the internal auditory canal: An experimental study. *Comput Aided Surg* 2:34–41, 1997.
34. Wackym PA, King WA, Poe DS, Meyer GA, Ojemann RG, Barker FG, Walsh PR, Staecker H: Adjunctive use of endoscopy during acoustic neuroma surgery. *Laryngoscope* 109:1193–1201, 1999.
35. Yuguang L, Chengyuan W, Meng L, Shugan Z, Wandong S, Gang L, Xingang L: Neuroendoscopic anatomy and surgery of the cerebellopontine angle. *J Clin Neurosci* 12:256–260, 2005.

COMMENTS

This study once again highlights that perfect anatomic knowledge and targeted surgical skill are crucial in neurosurgical practice. Even though the study’s design model has already been reported by the same authors, the article can be advocated as a relevant contribution to the literature concerning vestibular schwannoma surgery.

The possibility of relying on an image-guided system to decrease the risk of hearing loss while approaching vestibular schwannomas can be considered one of the greatest achievements of this kind of cranial base surgery. Furthermore, the authors point out the great improvement that can be provided in the surgical management of such pathology by the adoption of permanent bone implanted markers as reference points for the neuronavigation system. However, this cannot yet be immediately applied to clinical in vivo practice. Therefore, it is advisable to accomplish this goal so that further efforts can be carried out to move this

study from the laboratory to the operating room, thereby definitively contributing to the effectiveness and safety of this kind of surgery.

**Luigi M. Cavallo**  
**Paolo Cappabianca**  
*Naples, Italy*

Pillai et al. report an anatomic study using a navigation system and endoscope during exposure of the internal auditory canal (IAC) in the retrosigmoid approach. The aim is to increase hearing preservation when using the retrosigmoid approach in patients with vestibular schwannomas who have functional hearing before treatment. Hearing loss in such procedures is not only attributable to the cochlear injury but also to labyrinthine injury produced during drilling of the posterior wall of the auditory meatus. Image guidance may allow additional safe access to the lateral IAC. The endoscope-assisted technique may further help to remove the schwannoma from the unexposed part and the fundus of the IAC, while preserving the cochlear nerve.

**Giorgio Frank**  
*Bologna, Italy*

This is another excellent article from this group that addresses anatomic principles and, in this case, the posterior fossa and the IAC. The authors displayed thoroughness in their study of the integration of multiple technologies: microscopy, endoscopy, and image guidance. Although this article has defined the anatomic principles well, clinical applications will be needed to validate the findings of this study. Specifically, does an endoscope truly help with the visualization provided by a microscope at the level of the IAC? A minor nuance that the reader may wish to consider is that an improvement in accuracy can often be obtained with the use of internal anatomic fiducials for re-registration. This may help resolve the 2-mm-or-so error that is often associated with external fiducials. In this confined space, even 2 mm can be substantial. Again, the authors have done a very nice job in quantitating the anatomic visualization.

**Daniel M. Prevedello**  
**Paul A. Gardner**  
**Amin B. Kassam**  
*Pittsburgh, Pennsylvania*

In this article, the authors used image guidance to restrict the drilling of the posterior wall of the IAC to avoid injury to the labyrinth, restricting the angle of drilling to avoid excessive cerebellar retraction. They used endoscopic vision to see the lateral aspect of the fundus of the IAC. This is what I currently do in practice, although I do not routinely use image guidance to restrict drilling of the bone. Rather, I measure the distance on preoperative computed tomographic scans from the lip of the IAC to the vestibule and the posterior semicircular canal and use this as a guide to limit the drilling. I also use the endoscope to visualize the lateral aspect of the tumor near the fundus, to ensure complete removal. By using these techniques, there is no reason to use the middle fossa approach, which, in most surgeons’ experience, carries a higher risk to the facial nerve, in addition to the potential risks of temporal lobe retraction.

**Laligam N. Sekhar**  
*Seattle, Washington*

