



Published in final edited form as:

*Neuromodulation*. 2014 June ; 17(4): 312–319. doi:10.1111/ner.12141.

## Surgical Neuroanatomy and Programming in Deep Brain Stimulation for Obsessive Compulsive Disorder

Takashi Morishita, M.D., Ph.D.<sup>1</sup>, Sarah M. Fayad, M.D.<sup>2</sup>, Wayne K. Goodman, M.D.<sup>3</sup>, Kelly D. Foote, M.D.<sup>1</sup>, Dennis Chen, B.S.<sup>2</sup>, David A. Peace, M.S., CMI<sup>1</sup>, Albert L. Rhoton Jr.<sup>1</sup>, and Michael S. Okun, M.D.<sup>1,2</sup>

<sup>1</sup>Department of Neurosurgery, University of Florida College of Medicine/Shands Hospital, Center for Movement Disorders and Neurorestoration, McKnight Brain Institute, Gainesville, FL

---

Corresponding Author: Takashi Morishita, M.D., Ph.D., Department of Neurosurgery, Mcknight Brain Institute Room L2-100, 1149 South Newell Drive, Gainesville, FL 32611, 352-273-9000, 352-392-8413 FAX, takashi.morishita@neurosurgery.ufl.edu.

**Authorship Statement:** Drs. Morishita and Okun deigned and conducted the study, including patient recruitment, data collection and data analysis. Drs. Morishita and Fayad prepared the manuscript draft with important intellectual input from Drs. Okun, Rhoton, Goodman and Foote. Mr. Peace provided his illustration into this manuscript. Mr. Chen contributed to collect the data. All authors approved the final manuscript.

### Author disclosures

1. Takashi Morishita, M.D., Ph.D.

Disclosures: Dr. Morishita has received grant support from Nakatomi foundation, St. Luke's Life Science Institute of Japan, and Japan Society for Promotion of Science in Japan.

2. Sarah M. Fayad, M.D.

Disclosures: Dr. Fayad does not have disclosure to make.

3. Wayne K. Goodman, M.D.

Disclosures: Dr. Goodman does not have disclosure to make.

4. Kelly D. Foote, M.D.

Disclosures: Dr. Foote has received Medtronic fellowship training and research grants and has participated in CME activities on movement disorders sponsored by the University of South Florida CME office.

5. Dennis Chen, B.S.

Disclosures: Mr. Chen does not have disclosure to make.

6. David A. Peace, M.S., CMI

Disclosures: Mr. Peace does not have disclosure to make.

7. Albert L. Rhoton, Jr., M.D.

Disclosures: Dr. Rhoton does not have disclosure to make.

8. Michael S Okun, M.D.

Disclosures: Dr. Okun serves as a consultant for the National Parkinson Foundation, and has received research grants from NIH, NPF, the Michael J. Fox Foundation, the Parkinson Alliance, Smallwood Foundation, the Bachmann-Strauss Foundation, the Tourette Syndrome Association, and the UF Foundation. Dr. Okun has previously received honoraria, but in the past >36 months has received no support from industry. Dr. Okun has received royalties for publications with Demos, Manson, Amazon, and Cambridge (movement disorders books). Dr. Okun is an associate editor for New England Journal of Medicine Journal Watch Neurology. Dr. Okun has participated in CME activities on movement disorders in the last 36 months sponsored by PeerView, Prime, and by Vanderbilt University. The institution and not Dr. Okun receives grants from Medtronic and ANS/St. Jude, and the PI has no financial interest in these grants. Dr. Okun has participated as a site PI and/or co-I for several NIH, foundation, and industry sponsored trials over the years but has not received honoraria.

<sup>2</sup>Department of Neurology, University of Florida College of Medicine/Shands Hospital, Center for Movement Disorders and Neurorestoration, McKnight Brain Institute, Gainesville, FL

<sup>3</sup>Department of Psychiatry, Mount Sinai School of Medicine, New York, NY

## Abstract

**Objectives**—Deep brain stimulation (DBS) has been established as a safe, effective therapy for movement disorders (Parkinson’s disease, essential tremor, etc.), and its application is expanding to the treatment of other intractable neuropsychiatric disorders including Depression and Obsessive-Compulsive Disorder (OCD). Several published studies have supported the efficacy of DBS for severely debilitating OCD. However, questions remain regarding the optimal anatomical target and the lack of a bedside programming paradigm for OCD DBS. Management of OCD DBS can be highly variable and is typically guided by each center’s individual expertise. In this paper, we review the various approaches to targeting and programming for OCD DBS. We also review the clinical experience for each proposed target, and discuss the relevant neuroanatomy.

**Methods**—A PubMed review was performed searching for literature on OCD DBS and included all articles published before March 2012. We included all available studies with a clear description of the anatomical targets, programming details, and the outcomes.

**Results**—Six different DBS approaches were identified. High frequency stimulation with high voltage was applied in most cases, and predictive factors for favorable outcomes were discussed in the literature.

**Conclusion**—DBS remains an experimental treatment for medication refractory OCD. Target selection and programming paradigms are not yet standardized, though, an improved understanding of the relationship between the DBS lead and the surrounding neuroanatomical structures will aid in the selection of targets and the approach to programming. We propose to form a registry to track OCD DBS cases for future clinical study design.

## Keywords

Deep Brain Stimulation; Obsessive Compulsive Disorder; Ventral Capsule/Ventral striatum; Subthalamic nucleus; Inferior thalamic peduncle

## Introduction

Obsessive Compulsive Disorder (OCD) is a potentially disabling neuropsychiatric illness with a lifetime prevalence of 2.3%.<sup>1</sup> In recent years, attention has been given to a novel treatment approach, deep brain stimulation (DBS), for those with chronic and severe treatment-refractory OCD. While DBS has been established as a safe and effective treatment for movement disorders such as Parkinson’s disease and essential tremor,<sup>2</sup> its use in treating neuropsychiatric disorders is still experimental. The first report of DBS in patients with OCD was described by Nuttin and colleagues,<sup>3</sup> who selected their target, the anterior limb of the internal capsule, based on the anatomical target used in the ablative technique, the anterior capsulotomy. Following this initial study, the use of DBS in patients with treatment-refractory OCD was examined in four controlled studies.<sup>4-7</sup> In addition to a multitude of various neuroanatomical targets, the number of possible bedside programming combinations

is so large, that patient's cannot in practicality, be tested on all settings. We will review the published approaches to neuroanatomical target selection, and discuss the hypotheses of aberrant neurocircuitry in OCD. We aim to use the anatomical information as a springboard to propose potential DBS programming paradigms for OCD.

Various hypotheses have been proposed to explain the pathophysiology of OCD. Many of these theories are based on phenomenology and include dysfunctions in cognitive flexibility,<sup>8</sup> reversal learning,<sup>9</sup> reward processing<sup>10, 11</sup> and error recognition, emotion and motivation.<sup>12</sup> However, other theories, based on imaging studies and surgical experience, seek to describe the role of aberrant neuroanatomical circuitry in OCD. Perhaps the most widely accepted of these theories describes the role of the cortico-striato-thalamo-cortical (CSTC) circuit. Alexander and colleagues proposed thalamo-cortical loops with different functions.<sup>13, 14</sup> Several authors have since expanded on this in describing the potential pathophysiology in OCD.<sup>15–19</sup> Despite the variations in hypotheses, there appears to be a consensus that the orbitofrontal cortex, thalamus, caudate nucleus, and the anterior cingulate cortex appear to play central roles. Several authors posit that the basal ganglia circuits may be involved in the pathophysiology of OCD,<sup>19, 20</sup> while others have implicated the cortico-thalamic loops and Papez circuit as having important roles.<sup>21</sup>

Neuroimaging studies using computed tomography (CT) scans,<sup>22–24</sup> magnetic resonance imaging (MRI) scans,<sup>25–28</sup> magnetic resonance spectroscopy (MRS),<sup>29–32</sup> functional MRI (fMRI),<sup>10, 33–36</sup> single-photon emission computed tomography (SPECT)<sup>37–41</sup> and positron emission tomography (PET)<sup>42, 43</sup> have been performed in an effort to develop circuit hypotheses and while the results have been somewhat inconsistent, there does seem to be an association of the orbitofrontal cortex (OFC), the thalamus and the caudate nucleus with OCD pathophysiology.

Currently, neurosurgical procedures for the treatment of OCD aim to modulate a pathway in the aberrant circuit, rather than addressing a single area that could be responsible for etiology.<sup>21</sup> In the past decade, there have been six different anatomical targets used in deep brain stimulation for the treatment of OCD. These include the anterior limb of the internal capsule (ALIC), ventral capsule/ventral striatum (VC/VS), nucleus accumbens (NAcc), ventral striatum, and subthalamic nucleus (STN), and inferior thalamic peduncle (ITP). We review the theory underlying these various targets and will discuss methods for DBS programming based on the area in which the DBS electrodes are placed.

## Methods

A PubMed review was performed searching for literature on OCD DBS and included all articles published before March 2012. We used keywords including “obsessive compulsive disorder”, “deep brain stimulation”, “anterior limb”, “internal capsule”, “subthalamic nucleus”, “inferior thalamic peduncle”, and “psychosurgery”. We included all available studies with a clear description of the anatomical targets, programming details, and the outcomes (n=20), and the results are summarized in Table 1.<sup>4–7, 44–59</sup>

## Results

### Neuroanatomical Considerations

**ALIC, VC/VS**—The ALIC is comprised of several components including frontopontine fibers, thalamic peduncles, and possibly the medial forebrain bundle (MFB).<sup>60</sup> The frontopontine fibers project from frontal cortex to the pons, and thalamocortical fibers (anterior and inferior thalamic peduncles) connects the medial and mediodorsal (MD) nuclei of the thalamus to the frontal cortex. In the ALIC region, the frontopontine fibers are located lateral to the anterior thalamic peduncle. The target for DBS to treat OCD which was reported by Nuttin and colleagues was identical to the area targeted in gamma capsulotomy.<sup>3, 61</sup> In a subsequent report, the same group reported that they implanted the DBS electrode in the ALIC and/or the adjacent ventral striatal region.<sup>59</sup>

Greenberg and colleagues targeted the ventral capsule/ventral striatum (VC/VS).<sup>53</sup> This VC/VS stimulation procedure was also utilized concomitantly for co-existing Tourette's syndrome (TS) cases with OCD, however the efficacy has been inconsistent.<sup>48, 56, 58, 62</sup> Greenberg reported that favorable outcomes in OCD increased as the target migrated toward a more posterior target.<sup>52</sup> It is important to be aware that this "modified" VC/VS trajectory utilized in recent series may result in stimulating not only the NAcc and ALIC, but also adjacent structures, including the diagonal band of Broca, stria terminalis, and nucleus basalis. Denys and colleagues utilized the VC/VS trajectory with the smaller lead configuration, and the efficacy was carefully evaluated in a double-blind crossover study.<sup>7</sup> This group utilized the identical target to the capsulotomy, and in these cases the tip of the electrodes were located at the dorsal border of the NAcc.<sup>7</sup>

**NAcc**—The NAcc has two different areas (shell and core), and these two regions are assumed to have different functions.<sup>63, 64</sup> The shell region in the human brain has been assumed to be located in the caudal (posterior) area of the NAcc.<sup>65</sup> A human study revealed that the shell region has more dense  $\mu$  receptors, and possibly this may be the explanation that there are associated drug rewards.<sup>65</sup> The NAcc stimulation is based on the theory that the OCD may be due to reward processing and behavioral addiction.<sup>7</sup> However, the spread of the electric current to the ventral capsule cannot be excluded as a potential mechanism to the effect on the OCD symptoms in these cases. It remains unclear whether it is more advantageous to target the shell or the core of the NAcc. Franzini and colleagues argued that stimulation of the core region was more effective than the shell stimulation based on the anatomical location of the DBS leads.<sup>51</sup> However, Strum and colleagues found favorable improvements when the shell region of the NAcc was targeted.<sup>66</sup> Another study reported on two cases in which the ventral striatum including the NAcc and the ventral part of the caudate nucleus were stimulated.<sup>46, 47</sup> Interestingly, it was discovered that caudate nucleus stimulation addressed depressive symptoms but not symptoms of OCD.<sup>46, 47</sup>

There has been argument regarding the use of unilateral stimulation in patients with neuropsychiatric disorders.<sup>6, 66–68</sup> There have been two reports from Germany concerning unilateral NAcc procedures passing through the dorsal area of the NAcc and ventral capsule.<sup>6, 66</sup> The electrode was implanted unilaterally on the right side in both studies. In addition, the tip of the electrode seemed to be located in the nucleus basalis, posterior to

NAcc and ventral to the AC.<sup>69</sup> This unilateral procedure seems to be largely based on the first experience with a patient who benefitted from right unilateral stimulation, but not from left unilateral stimulation. Lippitz and colleagues found that the volume of the capsulotomy lesion in the right hemisphere influenced clinical outcomes.<sup>61</sup> These authors observed that when the lesion was located at the level of AC-PC plane, the outcomes were more favorable; however, the location of the lesion in the left hemisphere did not affect the outcomes. Other observations have not been able to establish laterality for OCD DBS, and the laterality issue remains inconclusive with most groups performing bilateral operations.

Most of the aforementioned procedures are quite similar in that they cover the NAcc and the ventral capsular region (Figure 1). However, it is possible that outcomes could be improved with more meticulous and accurate target selection.

**STN**—The STN is made up of limbic, associative and motor territories.<sup>70</sup> It receives input from the orbitofrontal-striato-pallido-thalamo-cortical circuit.<sup>71</sup> There have been four DBS studies that have targeted the STN for treatment of OCD.<sup>4, 49, 50, 57</sup> This approach was initially reported by Mallet et al. who treated two patients with Parkinson's Disease (PD) and OCD.<sup>57</sup> Mallet and colleagues targeted the limbic area of the STN, and interestingly stimulation in this region resulted in an improvement in obsessive behavior, and also in the symptoms of PD. The target was 2 mm anterior, and 1 mm medial to the STN target that was previously reported in PD cases.<sup>72</sup> Subsequently, Fontaine and colleagues reported another case of OCD also with PD who underwent STN DBS with substantial improvement 12 months following surgery.<sup>50</sup> Based on these initial favorable results, Mallet and colleagues performed a crossover, randomized multicenter study, with favorable outcomes.<sup>4</sup>

**Inferior thalamic peduncle (ITP)**—The ITP contains fibers connecting the mediodorsal (MD) thalamic nucleus with the orbitofrontal, insular and temporal cortices as well as the amygdaloid complex. Jimenez and colleagues reported that inferior thalamic peduncle (ITP) could be a potential target in DBS for OCD. It is hypothesized that this approach will disrupt the thalamo-orbitofrontal system. Jimenez's reported outcomes of ITP stimulation for OCD were considered positive, though the case series was small.<sup>54, 55</sup> Jimenez-Ponce and colleagues reported favorable results from one case and also five responders in an open case series,<sup>54, 55</sup> however, a controlled trial for DBS in the ITP to address OCD has not been performed. A better and more controlled study protocol will be needed to assess the true efficacy of ITP DBS.

## Programming Considerations

**General Concepts**—A logical first step in optimizing DBS programming is to define the lead location and to establish the lead configuration (the size of the contacts and the distance between them). Lead configuration can differ according to the specific target selected. While DBS leads with larger distances between contacts and larger contact sizes (ex. Medtronic model 3387 IES) were more likely to be used for earlier studies of VC/VS stimulation,<sup>52, 53</sup> those with relatively smaller configuration (i.e. Medtronic model 3389) have been used for STN and in more recent VC/VS cases.<sup>4, 50</sup> The bedside programmer should be aware of the lead type and configuration when planning treatment. Postoperative imaging can be useful in

this context. The electrode configurations utilized in each published study is summarized in Table 1.

The basic concept utilized in DBS programming was first documented in Nuttin's early study,<sup>59</sup> and in several other subsequent studies.<sup>52,53</sup> According to Nuttin, the first step was to identify the threshold levels (how much voltage was required to induce a side effect or a benefit) for mood changes at each combination, at each of the active contacts. The frequency and pulse width were then purposely kept steady while the programmer changed the amplitude (voltage) at each of the contacts. The investigators then would choose the contacts or contact with the lowest intensity for achieving a beneficial effect without a side effect; or alternatively one with only a transient side effect.

This concept has been also used widely in movement disorders,<sup>73</sup> and could be theoretically applied for all DBS targets. However, there is one potential flaw to using this strategy. Favorable responses may not always be encountered in the acute phase of stimulation, and some patients may experience transient mood changes (such as worsened anxiety). In a recent study using an active and sham stimulation programming design, approximately two thirds of the contacts did not have acute beneficial effects with VC/VS stimulation.<sup>74</sup> On the other hand, Nuttin et al. reported that the OCD symptoms were likely to improve in the first week of the stimulation, and to be aggravated a few days after the stimulation was discontinued.<sup>59</sup> As shown in Table 1, majority of the OCD DBS studies followed patients at least six months, therefore, it might be reasonable to follow-up the patient every month for stimulation adjustment at least for the first six months, though more data will be needed. There is an urgent need for some expert consensus on the best approach to acute and long-term programming of OCD DBS devices.

High frequency DBS (typically >100 Hz) may inhibit neural elements. Interestingly, in tremor, low frequency (< 60 Hz) stimulation usually drives essential tremor while high frequency stimulation suppresses it.<sup>75,76</sup> However, the effects of electrical stimulation are much more complex than can be explained by simply stating they are excitatory or inhibitory; they also involve astrocytes, a propagating calcium wave, neurotransmitter release, and changes in blood flow.<sup>77</sup> The effects seem to heavily depend on the site of stimulation, and also the neural elements affected. For example, high frequency stimulation of the motor fibers in the internal capsule may induce a tonic contraction, rather than paresis.<sup>78</sup> Although all of the OCD DBS studies applied high frequency stimulation, the parameters across studies were highly variable (Table 1). In the following sections, we will focus on the site of stimulation and programming for OCD DBS.

**ALIC, NAcc, and VC/VS**—The ALIC, and VC/VS are relatively large DBS targets, and as a result larger DBS electrodes such as the Medtronic (Minneapolis, MN) model 3387 IES (diameter = 1.27 mm, each contact length = 3mm, inter-electrode spacing = 4 mm) and model 3887 (diameter = 1.3 mm, each contact length = 3mm, inter-electrode spacing = 4 mm) have been used in an attempt to cover the relatively wider target areas.<sup>3, 52, 53, 59</sup> Recently, relatively smaller electrodes with closer inter-contact distances have been implanted to stimulate the NAcc and the ventral capsule specifically.<sup>6, 7, 66</sup> Additionally, the target for gamma capsulotomy has provided guidance for DBS placement and

programming as it has been noted that the more ventral portion of the ALIC seemed to be associated with greater benefit.<sup>53, 61</sup> Based on the literature and on experience, many experts concluded that the location of active contact seems an important factor in outcome.<sup>47, 52</sup>

In the VC/VS stimulation procedure when employed with the 3387 IES leads, the most ventral contact (0) usually is placed in a configuration to stimulate the ventromedial region of the NAcc, and the middle contacts (1 and 2) are placed to stimulate the ventral portion of the ALIC, which is a similar target to the ventral capsulotomy region. With the modified VC/VS trajectory which is located posterior to the original VC/VS trajectory, the most ventral contact is located close to the border between the NAcc and nucleus basalis.

The active contacts for OCD DBS have a strong tendency to be selected symmetrically in most studies, as is shown in the Table 1, and we would posit that this method would be best if both contacts were located in exactly the same place, which is not common in all indications for DBS. In bilateral DBS cases, bilateral independent programming is important as there is no guarantee that the leads are placed in exactly the same location in each hemisphere. The data in DBS support that the notion that clinicians should program each electrode independently in order to optimize outcome. In bilateral Parkinson's disease and in bilateral tremor cases, the same parameters are not typically used on both brain hemispheres.<sup>73</sup> Since the lead location may be slightly different between the left and right sides, we would advocate independent programming of the devices to obtain maximal benefit.

The frequency applied to most cases of OCD DBS has been high frequency (100–145 Hz), with no reports of the use of low frequency. Several groups reported the efficacy of unilateral VC/VS stimulation with a fixed frequency and pulse width,<sup>6</sup> but the effects of different parameters remain inconclusive until more data can be obtained and reported.

Voltage levels are a potentially important factor, particularly with reference to mood changes. A recent study showed that higher voltage levels were associated with mood aggravation, and the lower voltage levels could be associated with positive mood changes, though this is a broad generalization.<sup>74</sup> Pulse widths greater than 210  $\mu$ sec have been associated with more physiological responses such as nausea, cold sensation, fear and panic.<sup>74</sup> Only one patient was identified in a chronic study of OCD in the literature with a higher pulse width (450  $\mu$ sec) and high voltage (10.5 volts),<sup>59</sup> and no beneficial effect was observed in that patient. There are cases reported where very high pulse widths and current densities have been used to treat patients with OCD as shown in Table 1. There is some concern that high voltage stimulation may result in the tissue damage though there is a lack of data on this point, and clinical outcomes to date have been positive. More research and perhaps post-mortem data may be helpful in clarifying this issue.

Intraoperative test stimulation of the ALIC region can induce mirthful laughter.<sup>59, 74, 79, 80</sup> Smile induced by electrical stimulation was observed contralateral to the side to the stimulation, with rapid spread ipsilaterally. This phenomenon is not considered to be a simple motor response as it is frequently accompanied by a euphoric sensation. It is reported

that this phenomenon may be a predictive factor of favorable outcomes in OCD DBS.<sup>79</sup> In bilateral DBS cases, this phenomenon may be useful for clinicians to program each electrode independently. If a favorable response is not observed during the first clinical visit, it is sometimes helpful to try the contact that resulted in an intraoperative smile response. Caution should be exercised when programming this contact or any contact eliciting euphoria, as hypomania may result.

In VC/VS stimulation, temporary stimulation-related adverse events including muscle tightness associated with dysarthria, olfactory hallucinations, and gustatory sensations have all been reported.<sup>53, 80</sup> Olfactory and gustatory responses have been reported to be associated with the activation of the most ventral (deep) contacts,<sup>74</sup> and this observation may be explained by the stimulation of the medial olfactory stria. In addition, temporary mood changes such as hypomania, anxiety, and fear have been reported, and these adverse events have been also associated with the activation of the ventral contacts,<sup>74, 81</sup> and are thought to be related to current spread to the hypothalamus, autonomic circuitry and possibly the amygdalo-fugal pathways.<sup>74</sup> Huff and colleagues reported difficulties in concentration in their patients who underwent unilateral VC/VS surgery, and stimulation of the nucleus basalis may be one hypothesis for this side effect<sup>6</sup>.

Some stimulation-related adverse events will be temporary and not require a change to the stimulation parameters.<sup>53</sup> The differences in observed phenomena may be explained by the differences in lead locations, fiber bundle locations, and anatomical variations even if the same targeting method was utilized. The most worrisome side effect from programming this target has been delayed hypomania or frank mania. Patients and caregivers should be counseled about potential symptoms that may emerge and given information on what to do if this side effect emerges.

**STN**—Completely optimized STN stimulation parameters seem to require relatively lower charge densities when compared to other OCD targets. Recent studies have reported that adjustment of the voltage is typically performed with a fixed frequency (130 Hz) and pulse width (60 µsec).<sup>4, 49</sup> Examination of these studies revealed that selection of the active contacts with immediate clinical benefits was best determined based on the anatomical position as defined by a postoperative imaging study.<sup>4, 49</sup>

Various stimulation-related AE's have been reported in STN DBS for OCD and include anxiety, obsessions, manic symptoms, depressive symptoms, and suicidal ideation.<sup>4</sup> Chabardes and colleagues reported that mood changes, especially hypomania, were commonly observed in the acute phase of stimulation, and that mood changes seemed to wane over time.<sup>49</sup> Motor contractions were reported in a recent study following chronic STN stimulation and were explained by the authors as most likely related to the location to the internal capsule.<sup>49</sup> In Parkinson's disease, the STN is a small target with dense connectivity, and this has been hypothesized to contribute to cognitive impairment, especially when compared with the GPi target, which is a larger target that may be more forgiving with current spread,<sup>82–84</sup> however this point has not been studied in OCD DBS. In addition, mirthful laughter due to STN DBS has been reported in PD cases.<sup>85</sup> This



phenomenon occurs less frequently than the VC/VS target. The smile response has not been documented or studied in detail for STN DBS.

**ITP**—Although the ITP is a relatively small target, high voltage has typically been required to address OCD symptoms. The ITP lies adjacent to the fornix and the hypothalamus, and stimulation of this region may induce AE's. Jimenez-Ponce et. al. applied bipolar stimulation as a strategy to concentrate the electric current within a small area, and to avoid current spread and side effects.<sup>55</sup> Regarding ITP DBS, Jimenez-Ponce and colleagues reported transient confusion when the dorsal (upper) contacts were activated, and reported that anxiety was accompanied by autonomic symptoms when the ventral (lower) contacts were stimulated.<sup>54, 55</sup> There are currently few publications available to guide ITP DBS.

## Conclusion

DBS remains an experimental treatment for medication refractory OCD due to the mixed outcomes and the lack of standardized patient selection methods. Though there are several trials available, they are all small research trials, and more information will be needed to move this therapy beyond a FDA Humanitarian Device Exemption (HDE). Target selection and programming paradigms are not yet standardized, though, an improved understanding of the relationship between the DBS lead and the surrounding neuroanatomical structures will aid in the selection of targets and the approach to programming. Recent studies have illuminated DBS programming pearls and pitfalls, and many of these issues have been strongly tied to the anatomical location of the DBS lead. Ongoing studies investigating the neurocircuitry of OCD, along with an improved and evolved understanding of the mechanisms of action of DBS, will be important to direct future work in this area. However, since OCD DBS is still not considered a standard of care, the ethics concerning this experimental procedure should be addressed by employing strict informed consent and a risks versus benefits analysis. Additionally, patients should be carefully vetted by trained and experienced DBS multidisciplinary teams.

The formation of a registry to track OCD DBS cases will be critical, because of the small number of cases reported worldwide, and the need to monitor safety and improve outcomes. Key variables to be recorded would likely include 1) clinical characteristics such as OCD subtypes and response to all past treatments, 2) intraoperative findings (e.g. microelectrode recording data, smile response etc.), 3) the coordinates and the detailed anatomical area where the active DBS contact(s) is/are located; along with detailed post-operative imaging, 4) detailed postoperative DBS setting data, 5) clinical outcomes utilizing validated measures, and 6) tracking of adverse events. This registry approach may potentially help to direct investigators and programmers in refining DBS as a potential treatment for medication refractory OCD.

## Acknowledgments

This study was supported by R21MH064161 and in part by the University of Florida Grant M01 RR000082 National Center for Research Resources/National Institutes of Health. This work was also partly supported by a Grant-in Aid for Clinical Research from St. Luke's Life Science Institute of Japan and Japan Society for Promotion of Science.

## References

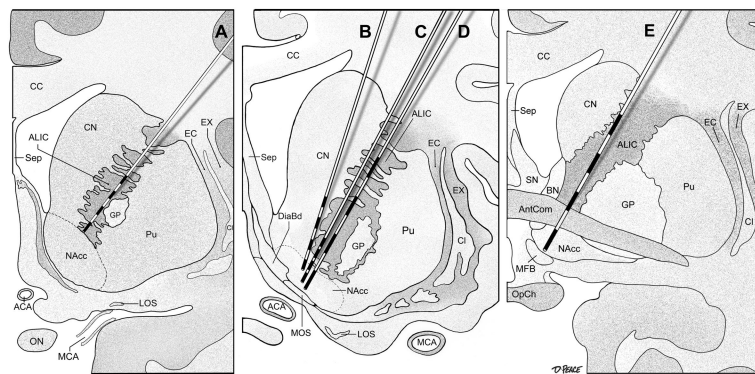
1. Ruscio AM, Stein DJ, Chiu WT, Kessler RC. The epidemiology of obsessive-compulsive disorder in the National Comorbidity Survey Replication. *Mol Psychiatry*. Jan; 2010 15(1):53–63. [PubMed: 18725912]
2. Gross RE, Lozano AM. Advances in neurostimulation for movement disorders. *Neurol Res*. Apr; 2000 22(3):247–258. [PubMed: 10769817]
3. Nuttin B, Cosyns P, Demeulemeester H, Gybels J, Meyerson B. Electrical stimulation in anterior limbs of internal capsules in patients with obsessive-compulsive disorder. *Lancet*. Oct 30.1999 354(9189):1526. [PubMed: 10551504]
4. Mallet L, Polosan M, Jaafari N, et al. Subthalamic nucleus stimulation in severe obsessive-compulsive disorder. *N Engl J Med*. Nov 13; 2008 359(20):2121–2134. [PubMed: 19005196]
5. Goodman WK, Foote KD, Greenberg BD, et al. Deep brain stimulation for intractable obsessive compulsive disorder: pilot study using a blinded, staggered-onset design. *Biol Psychiatry*. Mar 15; 2010 67(6):535–542. [PubMed: 20116047]
6. Huff W, Lenartz D, Schormann M, et al. Unilateral deep brain stimulation of the nucleus accumbens in patients with treatment-resistant obsessive-compulsive disorder: Outcomes after one year. *Clin Neurol Neurosurg*. Feb; 2010 112(2):137–143. [PubMed: 20006424]
7. Denys D, Mantione M, Figeo M, et al. Deep brain stimulation of the nucleus accumbens for treatment-refractory obsessive-compulsive disorder. *Arch Gen Psychiatry*. Oct; 2010 67(10):1061–1068. [PubMed: 20921122]
8. Bradbury C, Cassin SE, Rector NA. Obsessive beliefs and neurocognitive flexibility in obsessive-compulsive disorder. *Psychiatry Res*. May 15; 2011 187(1–2):160–165. [PubMed: 21112643]
9. Chamberlain SR, Menzies L, Hampshire A, et al. Orbitofrontal dysfunction in patients with obsessive-compulsive disorder and their unaffected relatives. *Science*. Jul 18; 2008 321(5887):421–422. [PubMed: 18635808]
10. Figeo M, Vink M, de Geus F, et al. Dysfunctional reward circuitry in obsessive-compulsive disorder. *Biol Psychiatry*. May 1; 2011 69(9):867–874. [PubMed: 21272861]
11. Huey ED, Zahn R, Krueger F, et al. A psychological and neuroanatomical model of obsessive-compulsive disorder. *J Neuropsychiatry Clin Neurosci*. Fall;2008 20(4):390–408. [PubMed: 19196924]
12. Aouizerate B, Guehl D, Cuny E, et al. Pathophysiology of obsessive-compulsive disorder: a necessary link between phenomenology, neuropsychology, imagery and physiology. *Prog Neurobiol*. Feb; 2004 72(3):195–221. [PubMed: 15130710]
13. Alexander GE, DeLong MR, Strick PL. Parallel organization of functionally segregated circuits linking basal ganglia and cortex. *Annu Rev Neurosci*. 1986; 9:357–381. [PubMed: 3085570]
14. Alexander GE, Crutcher MD, DeLong MR. Basal ganglia-thalamocortical circuits: parallel substrates for motor, oculomotor, “prefrontal” and “limbic” functions. *Prog Brain Res*. 1990; 85:119–146. [PubMed: 2094891]
15. Baxter LR Jr. Basal ganglia systems in ritualistic social displays: reptiles and humans; function and illness. *Physiol Behav*. Aug; 2003 79(3):451–460. [PubMed: 12954439]
16. Insel TR. Toward a neuroanatomy of obsessive-compulsive disorder. *Arch Gen Psychiatry*. Sep; 1992 49(9):739–744. [PubMed: 1514879]
17. Modell JG, Mountz JM, Curtis GC, Greden JF. Neurophysiologic dysfunction in basal ganglia/limbic striatal and thalamocortical circuits as a pathogenetic mechanism of obsessive-compulsive disorder. *J Neuropsychiatry Clin Neurosci*. Winter;1989 1(1):27–36. [PubMed: 2535426]
18. Saxena S, Brody AL, Schwartz JM, Baxter LR. Neuroimaging and frontal-subcortical circuitry in obsessive-compulsive disorder. *Br J Psychiatry Suppl*. 1998; (35):26–37. [PubMed: 9829024]
19. Rauch SL. Neuroimaging and neurocircuitry models pertaining to the neurosurgical treatment of psychiatric disorders. *Neurosurg Clin N Am*. Apr; 2003 14(2):213–223. vii–viii. [PubMed: 12856489]
20. Saxena S, Rauch SL. Functional neuroimaging and the neuroanatomy of obsessive-compulsive disorder. *Psychiatr Clin North Am*. Sep; 2000 23(3):563–586. [PubMed: 10986728]

21. Kopell BH, Greenberg B, Rezai AR. Deep brain stimulation for psychiatric disorders. *J Clin Neurophysiol.* Jan-Feb;2004 21(1):51–67. [PubMed: 15097294]
22. Behar D, Rapoport JL, Berg CJ, et al. Computerized tomography and neuropsychological test measures in adolescents with obsessive-compulsive disorder. *Am J Psychiatry.* Mar; 1984 141(3): 363–369. [PubMed: 6703099]
23. Insel TR, Donnelly EF, Lalakea ML, Alterman IS, Murphy DL. Neurological and neuropsychological studies of patients with obsessive-compulsive disorder. *Biol Psychiatry.* Jul; 1983 18(7):741–751. [PubMed: 6615935]
24. Luxenberg JS, Swedo SE, Flament MF, Friedland RP, Rapoport J, Rapoport SI. Neuroanatomical abnormalities in obsessive-compulsive disorder detected with quantitative X-ray computed tomography. *Am J Psychiatry.* Sep; 1988 145(9):1089–1093. [PubMed: 3414851]
25. Cannistraro PA, Makris N, Howard JD, et al. A diffusion tensor imaging study of white matter in obsessive-compulsive disorder. *Depress Anxiety.* 2007; 24(6):440–446. [PubMed: 17096398]
26. Rotge JY, Dilharreguy B, Aouizerate B, et al. Inverse relationship between thalamic and orbitofrontal volumes in obsessive-compulsive disorder. *Prog Neuropsychopharmacol Biol Psychiatry.* Jun 15; 2009 33(4):682–687. [PubMed: 19306905]
27. Rotge JY, Langbour N, Guehl D, et al. Gray matter alterations in obsessive-compulsive disorder: an anatomic likelihood estimation meta-analysis. *Neuropsychopharmacology.* Feb; 2010 35(3): 686–691. [PubMed: 19890260]
28. Szeszko PR, Ardekani BA, Ashtari M, et al. White matter abnormalities in obsessive-compulsive disorder: a diffusion tensor imaging study. *Arch Gen Psychiatry.* Jul; 2005 62(7):782–790. [PubMed: 15997020]
29. Bartha R, Stein MB, Williamson PC, et al. A short echo 1H spectroscopy and volumetric MRI study of the corpus striatum in patients with obsessive-compulsive disorder and comparison subjects. *Am J Psychiatry.* Nov; 1998 155(11):1584–1591. [PubMed: 9812122]
30. Ebert D, Speck O, Konig A, Berger M, Hennig J, Hohagen F. 1H-magnetic resonance spectroscopy in obsessive-compulsive disorder: evidence for neuronal loss in the cingulate gyrus and the right striatum. *Psychiatry Res.* Jul 4; 1997 74(3):173–176. [PubMed: 9255862]
31. Fitzgerald KD, Moore GJ, Paulson LA, Stewart CM, Rosenberg DR. Proton spectroscopic imaging of the thalamus in treatment-naïve pediatric obsessive-compulsive disorder. *Biol Psychiatry.* Feb 1; 2000 47(3):174–182. [PubMed: 10682215]
32. Smith EA, Russell A, Lorch E, et al. Increased medial thalamic choline found in pediatric patients with obsessive-compulsive disorder versus major depression or healthy control subjects: a magnetic resonance spectroscopy study. *Biol Psychiatry.* Dec 15; 2003 54(12):1399–1405. [PubMed: 14675804]
33. Adler CM, McDonough-Ryan P, Sax KW, Holland SK, Arndt S, Strakowski SM. fMRI of neuronal activation with symptom provocation in unmedicated patients with obsessive compulsive disorder. *J Psychiatr Res.* Jul-Oct;2000 34(4–5):317–324. [PubMed: 11104844]
34. Breiter HC, Rauch SL, Kwong KK, et al. Functional magnetic resonance imaging of symptom provocation in obsessive-compulsive disorder. *Arch Gen Psychiatry.* Jul; 1996 53(7):595–606. [PubMed: 8660126]
35. Martinot JL, Allilaire JF, Mazoyer BM, et al. Obsessive-compulsive disorder: a clinical, neuropsychological and positron emission tomography study. *Acta Psychiatr Scand.* Sep; 1990 82(3):233–242. [PubMed: 2248050]
36. Nakao T, Nakagawa A, Yoshiura T, et al. Brain activation of patients with obsessive-compulsive disorder during neuropsychological and symptom provocation tasks before and after symptom improvement: a functional magnetic resonance imaging study. *Biol Psychiatry.* Apr 15; 2005 57(8):901–910. [PubMed: 15820711]
37. Alptekin K, Degirmenci B, Kivircik B, et al. Tc-99m HMPAO brain perfusion SPECT in drug-free obsessive-compulsive patients without depression. *Psychiatry Res.* Jul 1; 2001 107(1):51–56. [PubMed: 11472864]
38. Lacerda AL, Dalgarrondo P, Caetano D, Camargo EE, Etchebehere EC, Soares JC. Elevated thalamic and prefrontal regional cerebral blood flow in obsessive-compulsive disorder: a SPECT study. *Psychiatry Res.* Jun 30; 2003 123(2):125–134. [PubMed: 12850251]

39. Lucey JV, Costa DC, Adshad G, et al. Brain blood flow in anxiety disorders. OCD, panic disorder with agoraphobia, and post-traumatic stress disorder on 99mTcHMPAO single photon emission tomography (SPET). *Br J Psychiatry*. Oct.1997 171:346–350. [PubMed: 9373423]
40. Machlin SR, Harris GJ, Pearlson GD, Hoehn-Saric R, Jeffery P, Camargo EE. Elevated medial-frontal cerebral blood flow in obsessive-compulsive patients: a SPECT study. *Am J Psychiatry*. Sep; 1991 148(9):1240–1242. [PubMed: 1883006]
41. Rubin RT, Villanueva-Meyer J, Ananth J, Trajmar PG, Mena I. Regional xenon 133 cerebral blood flow and cerebral technetium 99m HMPAO uptake in unmedicated patients with obsessive-compulsive disorder and matched normal control subjects. Determination by high-resolution single-photon emission computed tomography. *Arch Gen Psychiatry*. Sep; 1992 49(9):695–702. [PubMed: 1514874]
42. Rauch SL, Jenike MA, Alpert NM, et al. Regional cerebral blood flow measured during symptom provocation in obsessive-compulsive disorder using oxygen 15-labeled carbon dioxide and positron emission tomography. *Arch Gen Psychiatry*. Jan; 1994 51(1):62–70. [PubMed: 8279930]
43. Sawle GV, Hymas NF, Lees AJ, Frackowiak RS. Obsessional slowness. Functional studies with positron emission tomography. *Brain*. Oct; 1991 114( Pt 5):2191–2202. [PubMed: 1933241]
44. Abelson JL, Curtis GC, Sagher O, et al. Deep brain stimulation for refractory obsessive-compulsive disorder. *Biol Psychiatry*. Mar 1; 2005 57(5):510–516. [PubMed: 15737666]
45. Anderson D, Ahmed A. Treatment of patients with intractable obsessive-compulsive disorder with anterior capsular stimulation. Case report. *J Neurosurg*. May; 2003 98(5):1104–1108. [PubMed: 12744372]
46. Aouizerate B, Cuny E, Martin-Guehl C, et al. Deep brain stimulation of the ventral caudate nucleus in the treatment of obsessive-compulsive disorder and major depression. Case report. *J Neurosurg*. Oct; 2004 101(4):682–686. [PubMed: 15481726]
47. Aouizerate B, Cuny E, Bardinet E, et al. Distinct striatal targets in treating obsessive-compulsive disorder and major depression. *J Neurosurg*. Oct; 2009 111(4):775–779. [PubMed: 19284243]
48. Burdick A, Foote KD, Goodman W, et al. Lack of benefit of accumbens/capsular deep brain stimulation in a patient with both tics and obsessive-compulsive disorder. *Neurocase*. Aug; 2010 16(4):321–330. [PubMed: 20178034]
49. Chabardes S, Polosan M, Krack P, et al. Deep Brain Stimulation for Obsessive Compulsive Disorder: Subthalamic Nucleus Target. *World Neurosurg*. Mar 30.2012
50. Fontaine D, Mattei V, Borg M, et al. Effect of subthalamic nucleus stimulation on obsessive-compulsive disorder in a patient with Parkinson disease. Case report. *J Neurosurg*. Jun; 2004 100(6):1084–1086. [PubMed: 15200126]
51. Franzini A, Messina G, Gambini O, et al. Deep-brain stimulation of the nucleus accumbens in obsessive compulsive disorder: clinical, surgical and electrophysiological considerations in two consecutive patients. *Neurol Sci*. Jun; 2010 31(3):353–359. [PubMed: 20127500]
52. Greenberg BD, Gabriels LA, Malone DA Jr, et al. Deep brain stimulation of the ventral internal capsule/ventral striatum for obsessive-compulsive disorder: worldwide experience. *Mol Psychiatry*. Jan; 2010 15(1):64–79. [PubMed: 18490925]
53. Greenberg BD, Malone DA, Friehs GM, et al. Three-year outcomes in deep brain stimulation for highly resistant obsessive-compulsive disorder. *Neuropsychopharmacology*. Nov; 2006 31(11):2384–2393. [PubMed: 16855529]
54. Jimenez F, Velasco F, Salin-Pascual R, et al. Neuromodulation of the inferior thalamic peduncle for major depression and obsessive compulsive disorder. *Acta Neurochir Suppl*. 2007; 97(Pt 2):393–398. [PubMed: 17691327]
55. Jimenez-Ponce F, Velasco-Campos F, Castro-Farfan G, et al. Preliminary study in patients with obsessive-compulsive disorder treated with electrical stimulation in the inferior thalamic peduncle. *Neurosurgery*. Dec; 2009 65(6 Suppl):203–209. discussion 209. [PubMed: 19934996]
56. Kuhn J, Lenartz D, Mai JK, et al. Deep brain stimulation of the nucleus accumbens and the internal capsule in therapeutically refractory Tourette-syndrome. *J Neurol*. Jul; 2007 254(7):963–965. [PubMed: 17410328]
57. Mallet L, Mesnage V, Houeto JL, et al. Compulsions, Parkinson's disease, and stimulation. *Lancet*. Oct 26; 2002 360(9342):1302–1304. [PubMed: 12414208]

58. Neuner I, Podoll K, Lenartz D, Sturm V, Schneider F. Deep brain stimulation in the nucleus accumbens for intractable Tourette's syndrome: follow-up report of 36 months. *Biol Psychiatry*. Feb 15; 2009 65(4):e5–6. [PubMed: 19006786]
59. Nuttin BJ, Gabriels LA, Cosyns PR, et al. Long-term electrical capsular stimulation in patients with obsessive-compulsive disorder. *Neurosurgery*. Jun; 2003 52(6):1263–1272. discussion 1272–1264. [PubMed: 12762871]
60. Lehman JF, Greenberg BD, McIntyre CC, Rasmussen SA, Haber SN. Rules ventral prefrontal cortical axons use to reach their targets: implications for diffusion tensor imaging tractography and deep brain stimulation for psychiatric illness. *J Neurosci*. Jul 13; 2011 31(28):10392–10402. [PubMed: 21753016]
61. Lippitz BE, Mindus P, Meyerson BA, Kihlstrom L, Lindquist C. Lesion topography and outcome after thermocapsulotomy or gamma knife capsulotomy for obsessive-compulsive disorder: relevance of the right hemisphere. *Neurosurgery*. Mar; 1999 44(3):452–458. discussion 458–460. [PubMed: 10069581]
62. Flaherty AW, Williams ZM, Amirnovin R, et al. Deep brain stimulation of the anterior internal capsule for the treatment of Tourette syndrome: technical case report. *Neurosurgery*. Oct.2005 57(4 Suppl):E403. discussion E403. [PubMed: 16234657]
63. Heimer L. Basal forebrain in the context of schizophrenia. *Brain Res Brain Res Rev*. Mar; 2000 31(2–3):205–235. [PubMed: 10719150]
64. Prensa L, Richard S, Parent A. Chemical anatomy of the human ventral striatum and adjacent basal forebrain structures. *J Comp Neurol*. Jun 2; 2003 460(3):345–367. [PubMed: 12692854]
65. Voom P, Brady LS, Berendse HW, Richfield EK. Densitometrical analysis of opioid receptor ligand binding in the human striatum--I. Distribution of mu opioid receptor defines shell and core of the ventral striatum. *Neuroscience*. Dec; 1996 75(3):777–792. [PubMed: 8951872]
66. Sturm V, Lenartz D, Koulousakis A, et al. The nucleus accumbens: a target for deep brain stimulation in obsessive-compulsive- and anxiety-disorders. *J Chem Neuroanat*. Dec; 2003 26(4):293–299. [PubMed: 14729131]
67. Kuhn J, Bartsch C, Lenartz D, et al. Clinical effectiveness of unilateral deep brain stimulation in Tourette syndrome. *Transl Psychiatry*. 2011; 1:e52. [PubMed: 22833207]
68. Zabek M, Sobstyl M, Koziara H, Dzierzecki S. Deep brain stimulation of the right nucleus accumbens in a patient with Tourette syndrome. Case report. *Neurol Neurochir Pol*. Nov-Dec; 2008 42(6):554–559. [PubMed: 19235110]
69. Mavridis I, Anagnostopoulou S. Stereotactic targeting of the nucleus accumbens. *Clin Neurol Neurosurg*. May; 2011 113(4):342–343. [PubMed: 21159420]
70. Mallet L, Schupbach M, N'Diaye K, et al. Stimulation of subterritories of the subthalamic nucleus reveals its role in the integration of the emotional and motor aspects of behavior. *Proc Natl Acad Sci U S A*. Jun 19; 2007 104(25):10661–10666. [PubMed: 17556546]
71. Karachi C, Yelnik J, Tande D, Tremblay L, Hirsch EC, Francois C. The pallidusubthalamic projection: an anatomical substrate for nonmotor functions of the subthalamic nucleus in primates. *Mov Disord*. Feb; 2005 20(2):172–180. [PubMed: 15382210]
72. Benabid AL, Koudsie A, Benazzouz A, Le Bas JF, Pollak P. Imaging of subthalamic nucleus and ventralis intermedius of the thalamus. *Mov Disord*. 2002; 17( Suppl 3):S123–129. [PubMed: 11948766]
73. Volkmann JHJ, Kopper F, Deuschl G. Introduction to the programming of deep brain stimulators. *Mov Disord*. 2002; 17( Suppl 3):S181–187. [PubMed: 11948775]
74. Okun MS, Mann G, Foote KD, et al. Deep brain stimulation in the internal capsule and nucleus accumbens region: responses observed during active and sham programming. *J Neurol Neurosurg Psychiatry*. Mar; 2007 78(3):310–314. [PubMed: 17012341]
75. Benabid AL, Pollak P, Gervason C, et al. Long-term suppression of tremor by chronic stimulation of the ventral intermediate thalamic nucleus. *Lancet*. Feb 16; 1991 337(8738):403–406. [PubMed: 1671433]
76. Kuncel AM, Cooper SE, Wolgamuth BR, Grill WM. Amplitude- and frequency-dependent changes in neuronal regularity parallel changes in tremor With thalamic deep brain stimulation. *IEEE Trans Neural Syst Rehabil Eng*. Jun; 2007 15(2):190–197. [PubMed: 17601188]

77. Tawfik VL, Chang SY, Hitti FL, et al. Deep brain stimulation results in local glutamate and adenosine release: investigation into the role of astrocytes. *Neurosurgery*. Aug; 2010 67(2):367–375. [PubMed: 20644423]
78. Lozano AM, Mahant N. Deep brain stimulation surgery for Parkinson's disease: mechanisms and consequences. *Parkinsonism Relat Disord*. May; 2004 10( Suppl 1):S49–57. [PubMed: 15109587]
79. Haq IU, Foote KD, Goodman WG, et al. Smile and laughter induction and intraoperative predictors of response to deep brain stimulation for obsessive-compulsive disorder. *Neuroimage*. Jan; 2011 54( Suppl 1):S247–255. [PubMed: 20226259]
80. Okun MS, Bowers D, Springer U, et al. What's in a "smile?" Intra-operative observations of contralateral smiles induced by deep brain stimulation. *Neurocase*. Aug; 2004 10(4):271–279. [PubMed: 15788264]
81. Shapira NA, Okun MS, Wint D, et al. Panic and fear induced by deep brain stimulation. *J Neurol Neurosurg Psychiatry*. Mar; 2006 77(3):410–412. [PubMed: 16484657]
82. Follett KA, Weaver FM, Stern M, et al. Pallidal versus subthalamic deep-brain stimulation for Parkinson's disease. *N Engl J Med*. Jun 3; 2010 362(22):2077–2091. [PubMed: 20519680]
83. Morishita T, Foote KD, Burdick AP, et al. Identification and management of deep brain stimulation intra- and postoperative urgencies and emergencies. *Parkinsonism Relat Disord*. Mar; 2010 16(3):153–162. [PubMed: 19896407]
84. Okun MS, Fernandez HH, Wu SS, et al. Cognition and mood in Parkinson's disease in subthalamic nucleus versus globus pallidus interna deep brain stimulation: the COMPARE trial. *Ann Neurol*. May; 2009 65(5):586–595. [PubMed: 19288469]
85. Krack P, Kumar R, Ardouin C, et al. Mirthful laughter induced by subthalamic nucleus stimulation. *Mov Disord*. Sep; 2001 16(5):867–875. [PubMed: 11746616]



**Figure 1. Anterior view of coronal sections of deep nuclear areas of the left hemisphere showing five different approaches for OCD DBS**

Left. Electrode placement in ALIC (A) for deep brain stimulation. Middle. Electrode placement targeting NAcc through ALIC utilizing three, different trajectories (B, C, and D). Right. Modified VC/VS trajectory (E)

A: The ALIC trajectory (Anderson and Ahmed (2003) and Abelson et al. (2005)). B: Medial trajectory through the caudate nucleus to the nucleus accumbens (NAcc) utilizing Medtronic model 3387 electrode (each contact length = 1.5 mm, inter-electrode spacing = 1.5 mm) by Aouizerate et al. (2004, 2007). C: VC/VS stimulation trajectory through the ALIC to the NAcc using a shorter length of stimulating electrode (Medtronic model 3389: each contact length = 1.5 mm, inter-electrode spacing = 0.5 mm) by Denys et al. (2010). D: VC/VS trajectory through ALIC to the NAcc using a longer length of stimulating electrode (Medtronic model 3387 IES/3887: each contact length = 3 mm, inter-electrode spacing = 4 mm) by Greenberg et al. (2006). E. VC/VS trajectory through ALIC to the NAcc using a longer length of stimulating electrode (Medtronic model 3387 IES/3887: each contact length = 3 mm, inter-electrode spacing = 4 mm) by Greenberg et al. (2010).

ACA = anterior cerebral artery, ALIC = anterior limb of the internal capsule, AN = anterior nucleus of the thalamus, AntCom = anterior commissure, BN = bed nucleus, CC = corpus callosum, CL = claustrum, CN = caudate nucleus, DiaBd = diagonal band of Broca, EC = external capsule, EX = extreme capsule, GP = globus pallidus, LOS = lateral olfactory stria, MCA = middle cerebral artery, MFB = medial forebrain bundle, MD = mediodorsal nucleus of the thalamus, MOS = medial olfactory stria, NA = amygdala, NAcc = nucleus accumbens, OpCh = Optic Chiasm, Pu = putamen, Sep = septum pellucidum, SN = septal nucleus, STN = subthalamic nucleus

Table 1

Stimulation parameters and outcomes

Author (year)	N	F/U (mo)	Electrodes	Parameters		Frequency (L/R)	Pulse Width (L/R)	Amplitude (L/R)**	% Changes in Y-BOCS to baseline
				Active Contacts					
				Left	Right				
ALIC									
Anderson and Ahmed (2003)	1	10	MDT 3387	NA	NA	100/100	210/210	2/2	79.4
Abelson et al. (2005)	1	4	MDT 3387	NA	NA	NA	NA	NA	No improvement
	1	11.5		0,1,2,3(-)/3(+)	0,1,2,3(-)/3(+)	130/130	210/210	7/7	36
	1	23		0(-)/C(+)	0(-)/C(+)	NA	NA	NA	73
	1	13		NA	NA	NA	NA	NA	No improvement
VC/NS									
Nuttin et al. (2003)*	6	NA	MDT 3887 or MDT 3487A	0,1,2,3(-)/C(+)	0,1,2,3(-)/C(+)	100/100	210/210	5.5/5.5	31.7 (on vs. off)
				1(-)/0,2(+)	1(-)/0,2(+)	100/100	210/210	9/9	
				0,1,2,3(-)/C(+)	0,1,2,3(-)/C(+)	100/100	210/210	4/4	
				1(-)/2(+)	1(-)/2(+)	100/100	450/450	10.5/10.5	
Greenberg et al. (2006)	10	36	MDT 3387 IES	0(-) in 8/10 patients 1(-) in 7/10 patients 2(-) in 3/10 patients Bipolar (3 as an anode) in 6/10 patients Monopolar in 4/10 patients		100-130	90-210	8-17 mA	34 4 patients had > 35 % improvement.
Kuhn et al. (2007)	1	30	MDT 3387	0,1,2,3(-)/C(+)	0,1,2,3(-)/C(+)	130/130	90/90	7/7	52
Neuner et al. (2009)	1	36	NA	0,1(-)/C(+)	0,1(-)/C(+)	145/145	90/90	4.8-6	56
Denys et al. (2010)	16	21	MDT 3389	NA	NA	130/130	90/90	3.5 to 5.0	51.9
Franzini et al. (2010)	1	24	MDT 3389	1,2(-)/C(+)	1,2(-)/C(+)	130/130	90/90	5/5	42.1
	1	27		1,2(-)/C(+)	1,2(-)/C(+)	130/130	90/90	5.5/5/5	33.3



Author (year)	N	F/U (mo)	Electrodes	Parameters			% Changes in Y-BOCS to baseline		
				Active Contacts		Amplitude (L/R)**			
				Left	Right				
Frequency (L/R)		Pulse Width (L/R)							
Greenberg et al. (2010)	26	3–36	MDT 3387 IES MDT 388	Usually the ventral contacts (0 and/or 1) were active.		100–130/100–130	90–450/90–450	2–8/2–8	16 of 26 (61.5%) patients had 35% improvement at last f/u
Goodman et al. (2010)	1	12	MDT 3387 IES	0(-)/C(+)	1(-)/C(+)	135/135	210/210	4/5	46.7
	1	12		2(-)/C(+)	2(-)/C(+)	135/135	210/210	3.5/3.5	
	1	12		0,1(-)/C(+)	0,1(-)/C(+)	130/130	150/150	7.5/8.5	
	1	12		1(-)/C(+)	1(-)/C(+)	135/135	180/180	6.5/6.5	
	1	12		1(-)/C(+)	0,1(-)/C(+)	135/135	210/210	2.5/2.5	
	1	12		1(-)/C(+)	1(-)/C(+)	135/135	90/90	3.5/3.5	
Burdick et al. (2010)	1	30	MDT 3387 IES	1(-)/2(+)	1(-)/2(+)	135/135	90/90	6.5/6.5	No improvement
<b>Ventral Striatum</b>									
Aouizerate et al. (2004 and 2009)	1	15	MDT 3387	0,1,2,3(-)/C(+)	0,1,2,3(-)/C(+)	130/130	120/120	4/4	>35 failed to sufficiently alleviate OCD
	1	15		0,1,2,3(-)/C(+)	0,1,2,3(-)/C(+)	130/130	120/120	4/4	
<b>Unilateral NAcc</b>									
Huff et al. (2010)	1	12	MDT 3387	-	0,1,2(-)/C(+)	-/145	NA/90	NA/5.5	27
	1	12		-	0,1,2(-)/C(+)	-/145	NA/90	NA/6.5	38
	1	12		-	0,1,2(-)/C(+)	-/145	NA/90	NA/6.5	36
	1	12		-	0,1,2(-)/C(+)	-/145	NA/90	NA/6.5	15
	1	12		-	1,2,3(-)/C(+)	-/145	NA/90	NA//6.5	26
	1	12		-	1,2,3(-)/C(+)	-/145	NA/90	NA/4.5	24
	1	12		-	1,2,3(-)/C(+)	-/145	NA/90	NA/4.5	30
	1	12		-	0,1,2(-)/C(+)	-/145	NA/90	NA/4.5	34
	1	12		-	0,1,2(-)/C(+)	-/145	NA/90	NA/5.0	30
	1	12		-	0,1,2(-)/C(+)	-/145	NA/90	NA/5.0	22
<b>STN</b>									

Author (year)	N	F/U (mo)	Electrodes	Parameters				% Changes in Y-BOCS to baseline	
				Active Contacts		Frequency (L/R)	Pulse Width (L/R)		Amplitude (L/R)**
				Left	Right				
Mallet et al. (2002)	1	6	NA	NA	NA	185/185	60/60	3.1/3.1	81
	1	6	NA	NA	NA	130/130	90/90	3.2/3.2	64
Fontaine et al. (2004)	1	12	MDT 3389	NA	NA	185/185	60/60	1.3/3.5	75.9
Mallet et al. (2008)	16	3	MDT 3389	NA	NA	130/130	60/60	2.0±0.8	32.1 (on vs. sham)
Chabardes et al. (2012)	1	6	NA	Monopolar	Monopolar	130/130	60/60	NA	75
	1	6	NA	Monopolar	Monopolar	130/130	60/60	NA	71
	1	6	NA	Monopolar	Monopolar	130/130	60/60	NA	78
	1	6	NA	Monopolar	Monopolar	130/130	60/60	NA	34
<b>ITP</b>									
Jimenez et al. (2007)	1	18	NA	NA	NA	130/130	450/450	5.0/5.0	42.9–62.5 (fluctuated)
Jimenez-Ponce et al. (2009)	5	12	MDT 3387	Bipolar stimulation was used.		130/130	450/450	5.0/5.0	49.1

The studies were classified based on the trajectory of the DBS lead documented in the each literature. Parameters were documented from the chronic state.

\* Two patients were non-responder. Four patients were evaluated with crossover manner.

\*\* Amplitudes are voltage in all studies except one study.

ALIC = anterior limb of internal capsule; C = case; F/U = follow-up; ITP = inferior thalamic peduncle; MDT = Medtronic; NA=not applicable; NAcc = nucleus accumbens; NS = not specified; OCD = obsessive compulsive disorder; STN = subthalamic nucleus; Y-BOCS = Yale-Brown obsessive compulsive scale; VC/VS = ventral capsule/ventral striatum