

# Peripheral Nerve of Upper Limb

By : Dr Sumer Yadav  
Plastic and reconstructive surgery

# Brachial Plexus

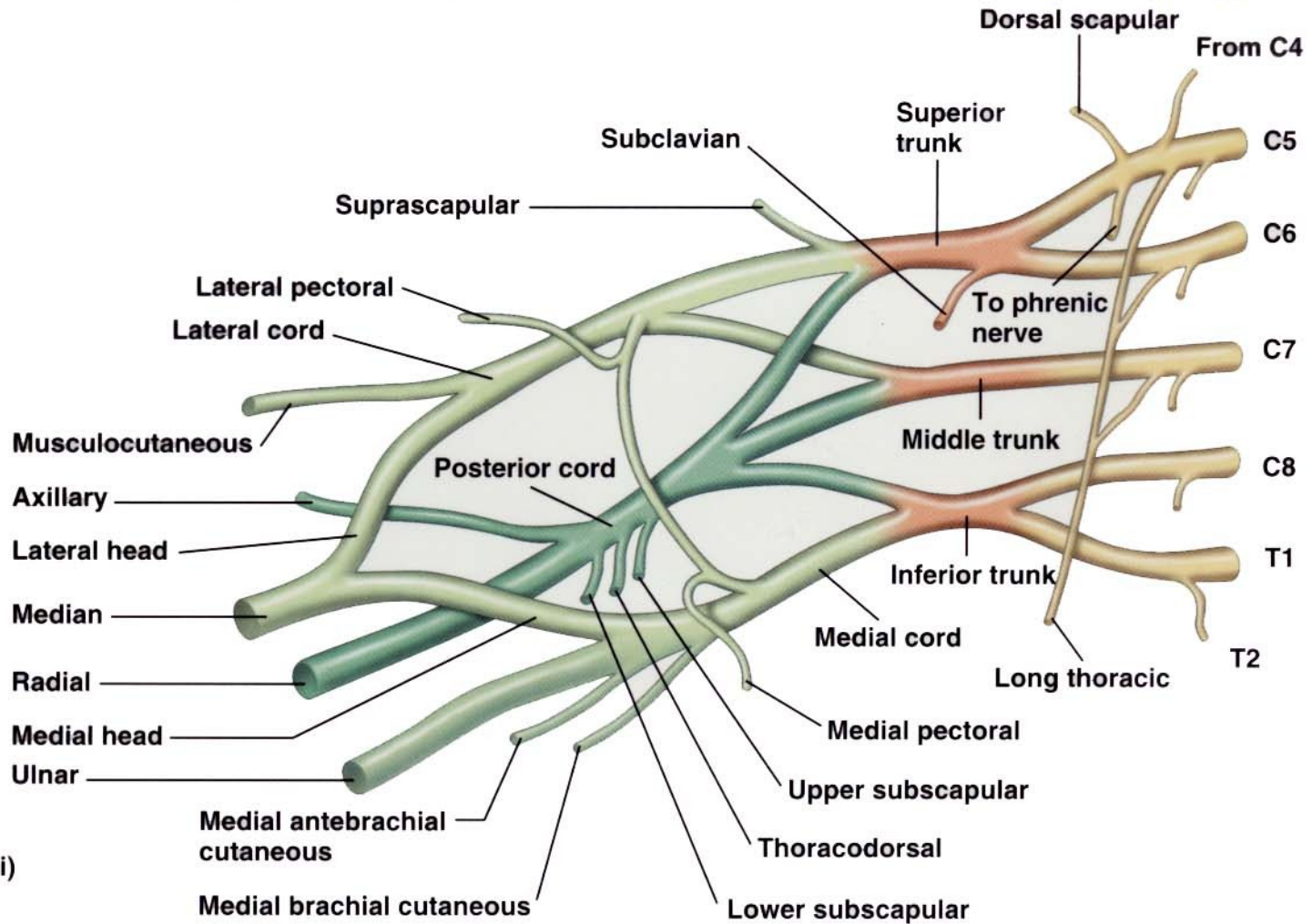
- Networking of spinal nerves, formed by ventral (anterior rami) of cervical spinal nerves C5-C8 and thoracic spinal nerves T1.
- Brachial plexus is responsible for cutaneous (sensory) and muscular (motor) innervation of the entire upper limb.

# Brachial Plexus

- 5 main nerves arise from brachial plexus:
  1. Axillary nerve
  2. Musculocutaneous nerve
  3. Radial nerve
  4. Median nerve
  5. Ulnar nerve



# Brachial Plexus



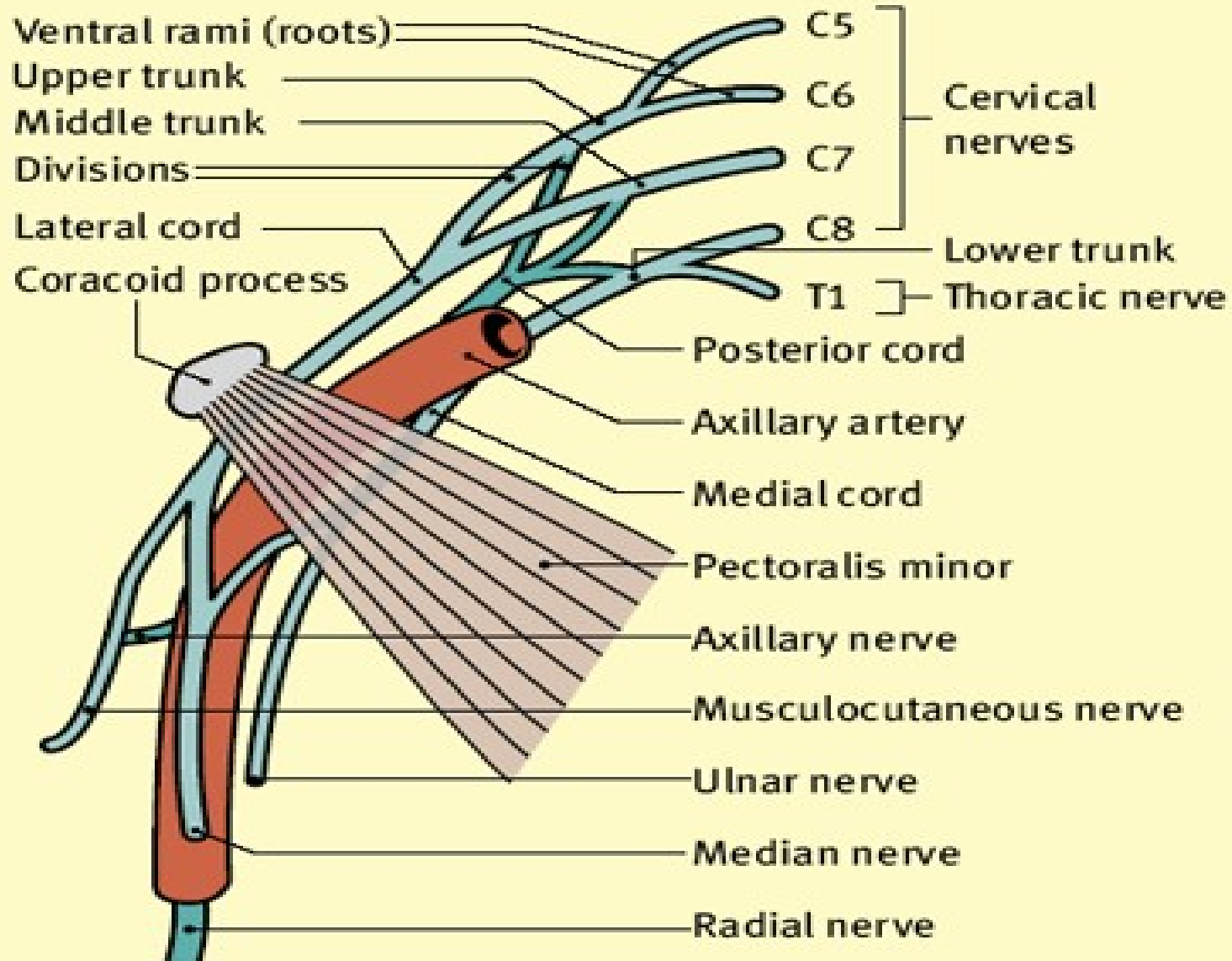
- Roots (anterior rami)
- Trunks
- Anterior divisions
- Posterior divisions

(a) Origin of brachial plexus

# Axillary Nerve

- From root C<sub>5</sub>-C<sub>6</sub>
- Arise from posterior cord of brachial plexus at the level of axilla.

# Relationship of the brachial plexus to the axillary artery



Posterior divisions and their branches dark green



# Branches of Axillary Nerves

- Lies posterior to the axillary artery and anterior to the subscapularis muscles.
- Then axillary nerves will divide into anterior branch (upper branch) and posterior branch (lower branch).
- Anterior branch innervate anterior border of deltoid muscles (anterior and lateral fiber)
- Posterior branch supply teres minor and posterior part of the deltoid (posterior fiber). Then it will branch of to formed superior lateral cutaneous nerve of arm (superior lateral brachial cutaneous).

# Innervations of Axillary Nerve

- **Muscular innervations**

- anterior branch – anterior and lateral fiber of deltoid muscles
- posterior branch – teres minor and posterior fiber of deltoid

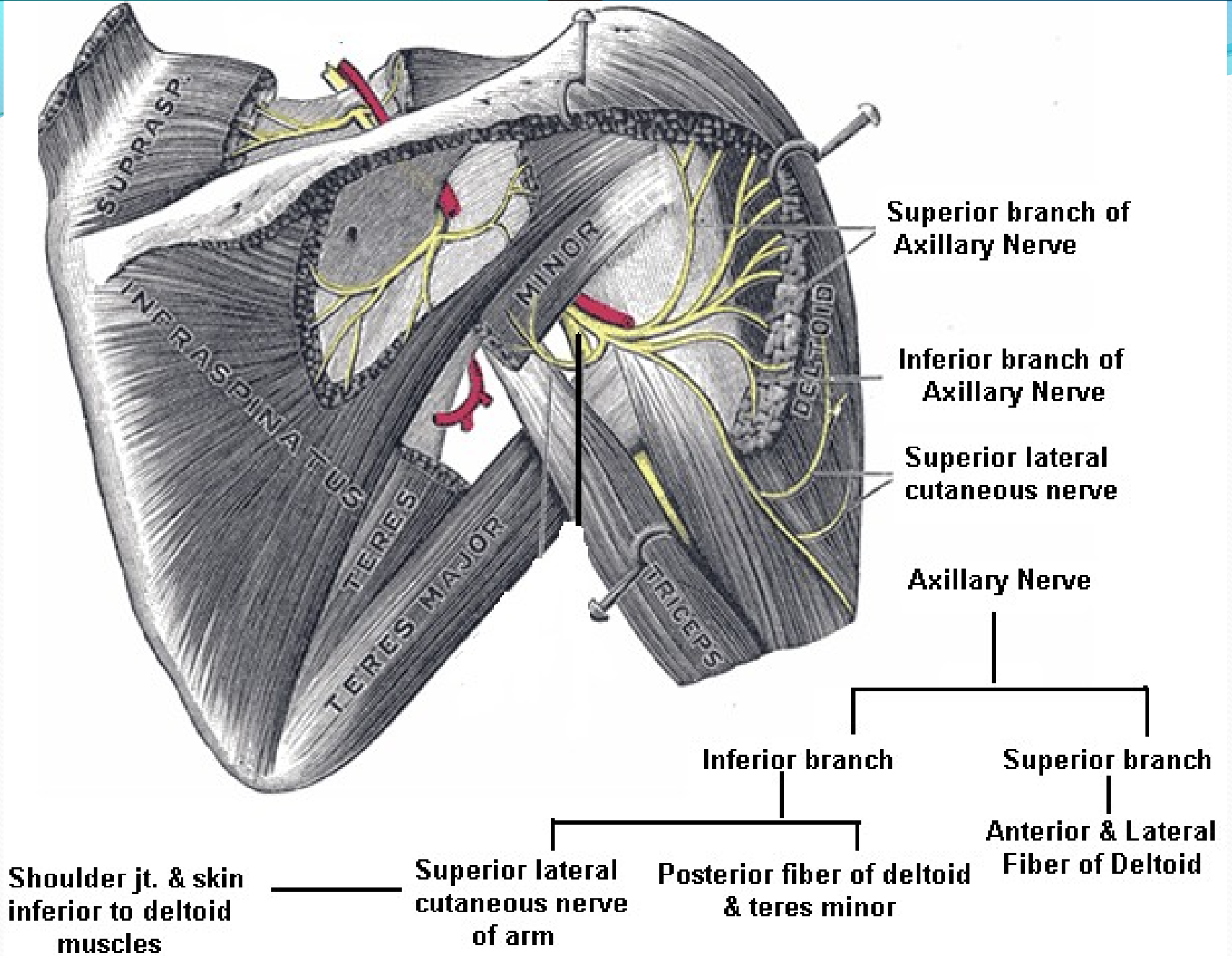
- **Cutaneous innervation**

- superior lateral brachial cutaneous nerve
- carry information from the shoulder joint
- skin covering inferior region of deltoid muscles.

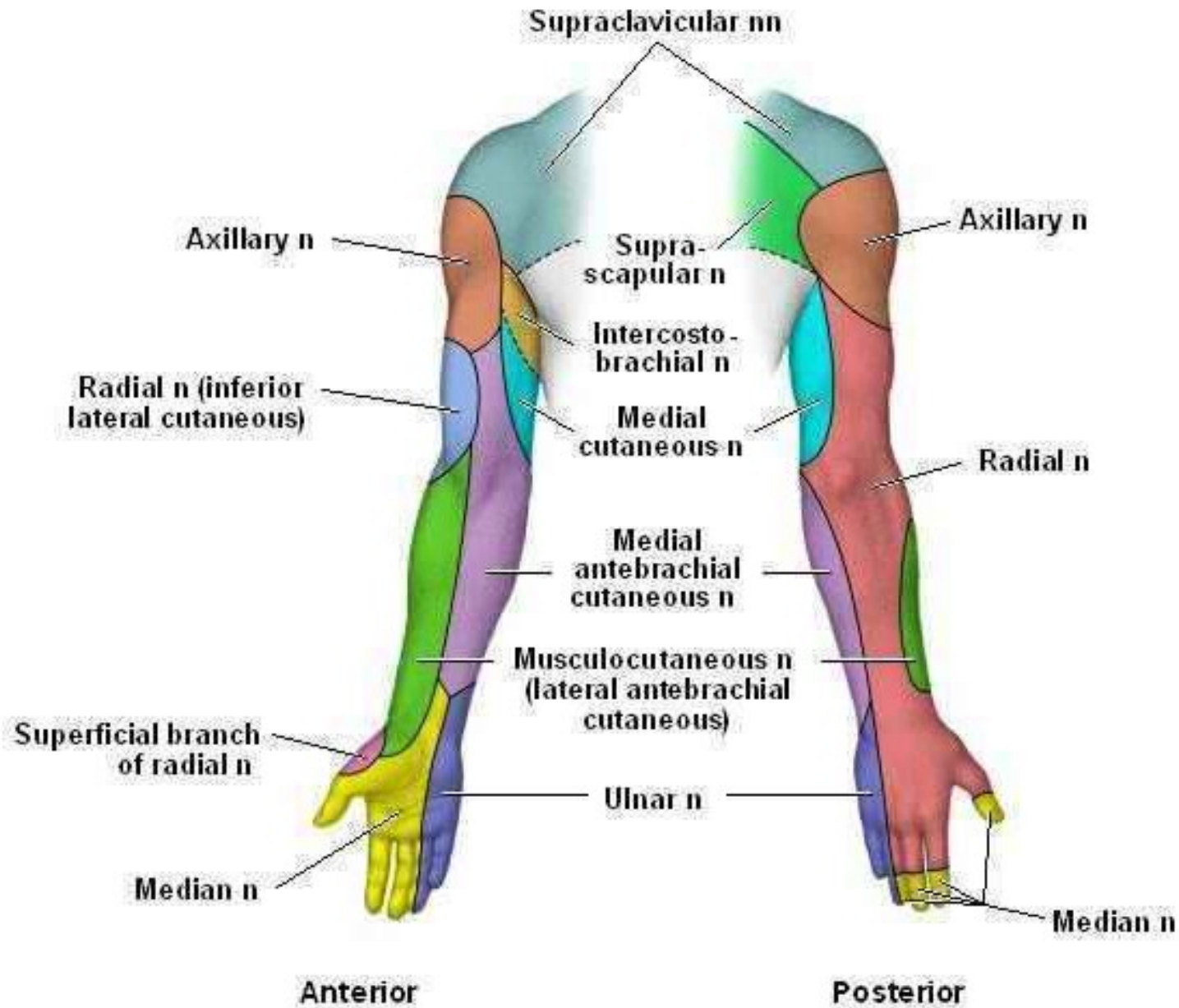


# Cont..

- Frequently injured due to shoulder dislocation because of the close to the proximity of this joint
- Paralysis of the deltoid and teres minor results
- Inability to abduct the arm beyond that possible by the action of the supraspinatus.



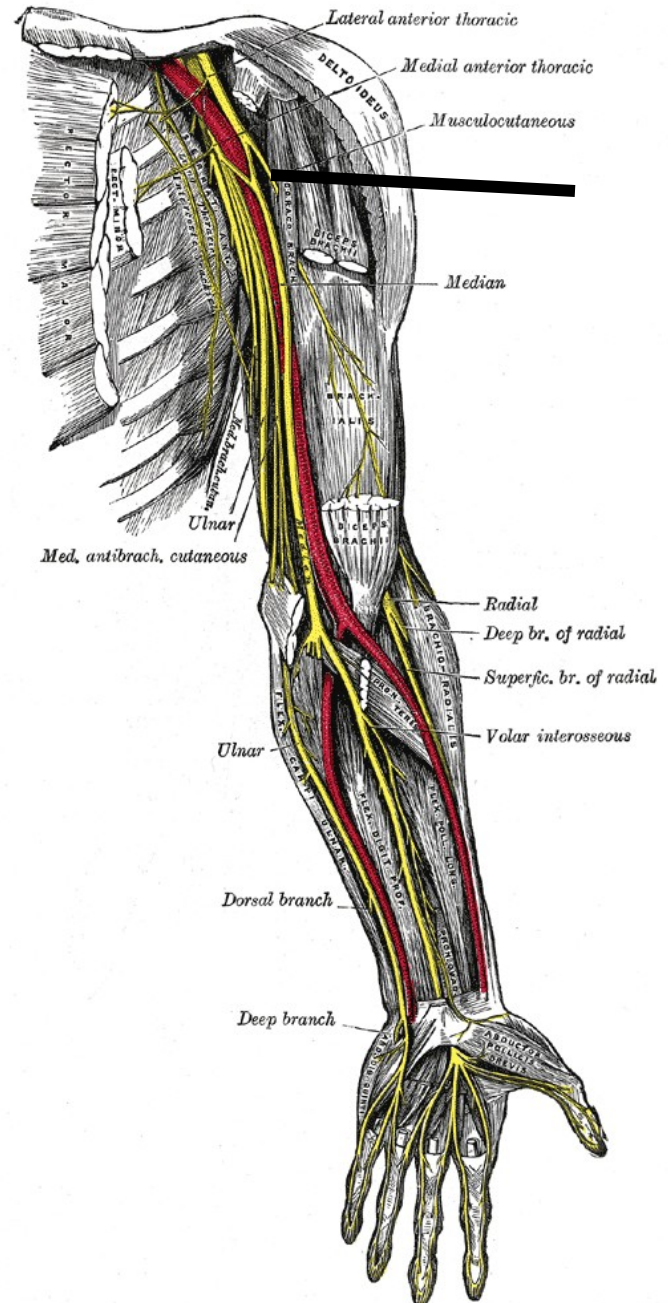
**Posterior View of the Shoulder**





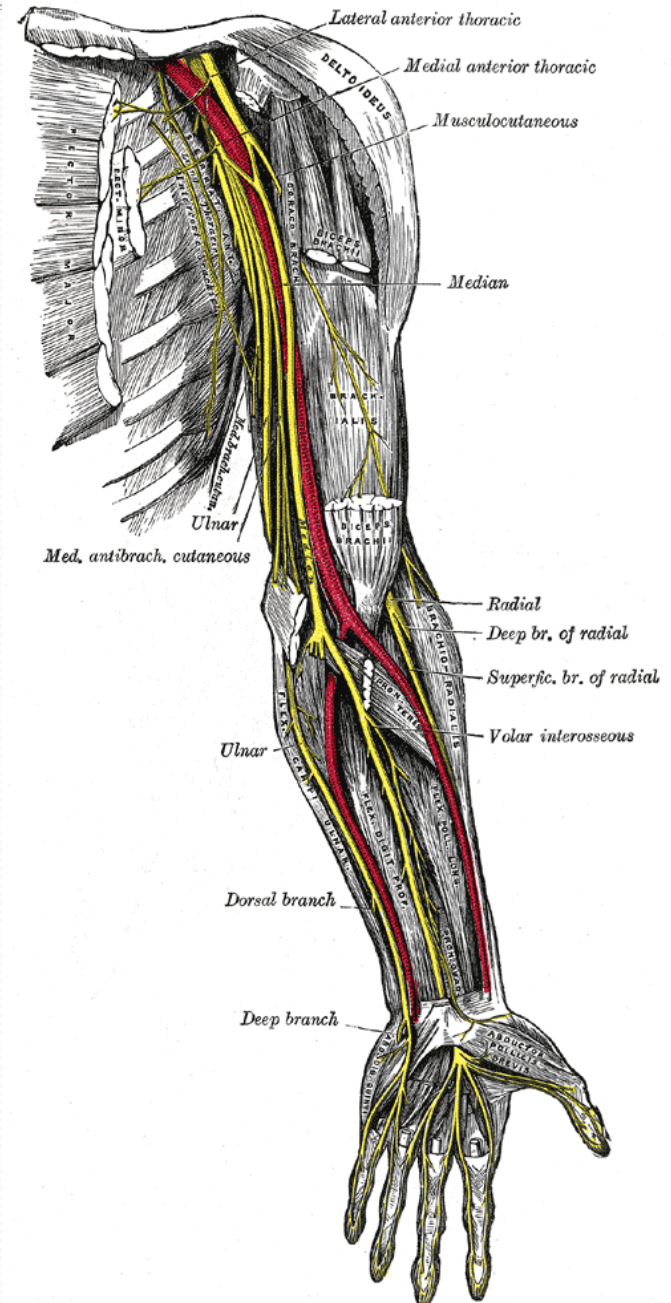
# Musculocutaneous Nerve

- Arise from lateral cord of brachial plexus
- Opposite to the lower border of pectoralis minor
- Arise from root C5, C6 and C7.



# Musculocutaneous Nerve

- Penetrate coracobrachialis and pass obliquely between biceps brachii and the brachialis to the lateral side of the arm.
- Then continue in the forearm as the lateral antebrachial cutaneous nerve.





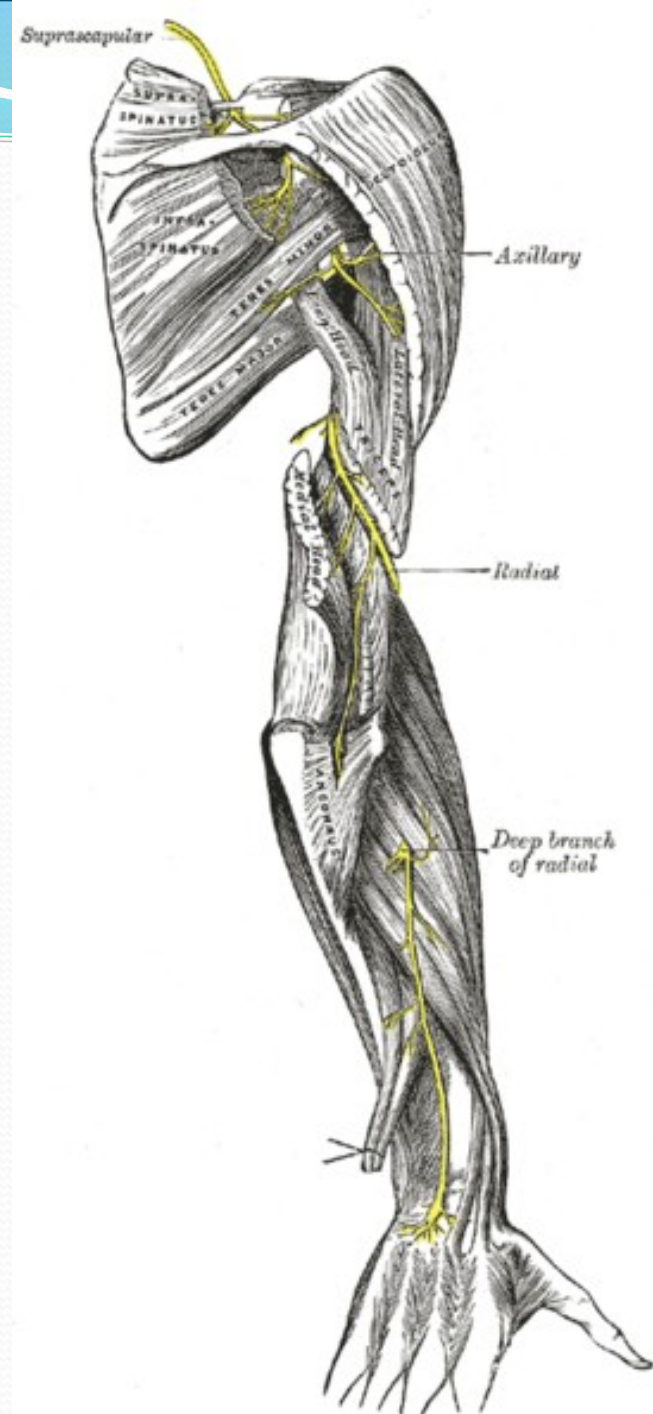
# Innervation of Musculocutaneous Nerve

- Muscular innervation
  - Supply coracobrachialis, biceps brachii and brachialis
- Cutaneous innervation.
  - **Lateral antebrachial cutaneous** nerve divide into anterior and posterior branch.
  - Anterior branch – skin of anterolateral surface of forearm as far as ball of the thumb
  - Posterior branch – skin of posterolateral surface of forearm.



# Radial Nerve

- Arise from posterior cord of brachial plexus
- Arise from root C5, C6, C7, C8 & T1.



# Radial Nerve

- It goes descending obliquely through the arm, first in the posterior compartment of the arm, and later in the anterior compartment of the arm, and continues in the posterior compartment of the forearm.
- The radial nerve enter the arm behind the axillary artery and then travel posteriorly on the medial side of the arm.



# Radial Nerve

- Then radial nerve will innervate triceps brachii.
- Radial nerve then enter the radial groove.
- Radial nerve emerge from radial groove and enter the anterior compartment of the arm.
- It continue the journey between brachialis and brachioradialis.
- When the radial nerve reaches the distal part of the humerus, it passes anterior to the lateral epicondyle and continue to the forearm.



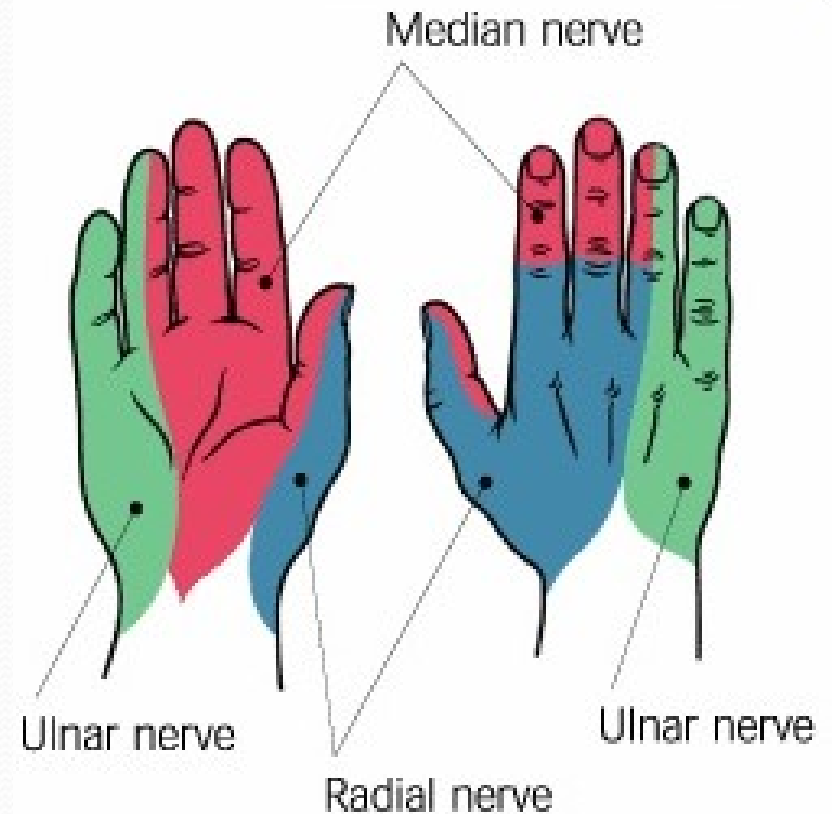
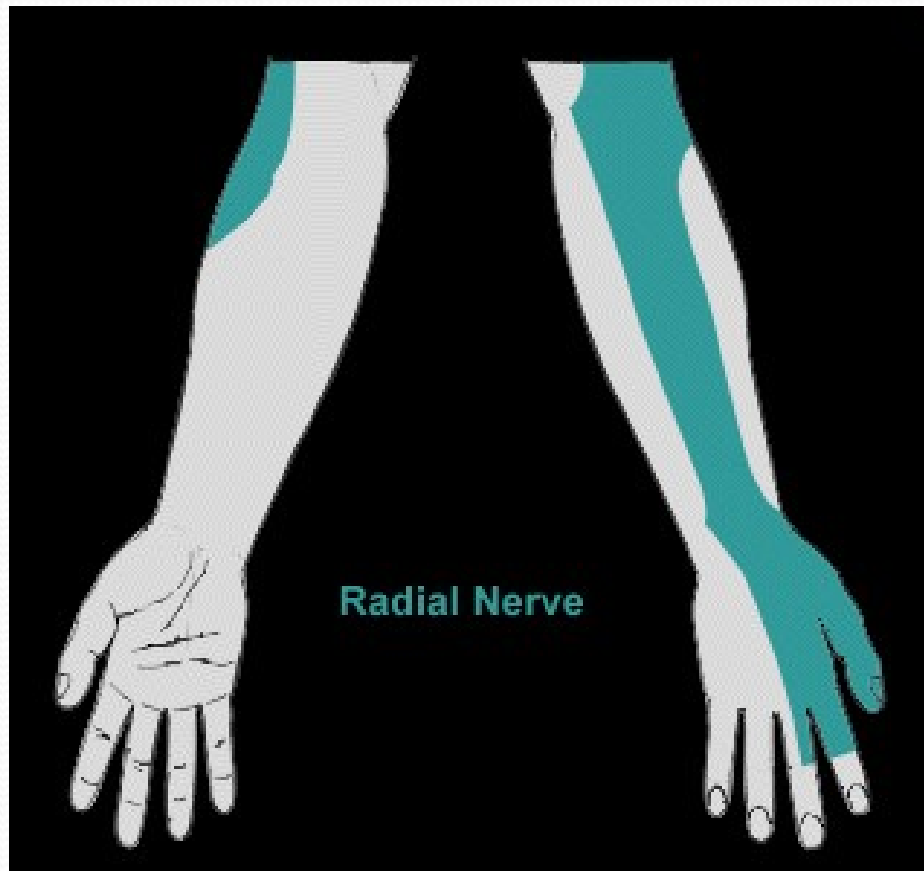
# Radial Nerve

- In the forearm, it will branch of to superficial branch (mainly sensory) and deep branch (mainly motor).
- **Cutaneous innervation** is provided by nerve that arise from radial nerve.
  - Posterior brachial cutaneous nerve
  - Inferior lateral brachial cutaneous nerve
  - Posterior antebrachial cutaneous nerve
  - Superficial branch of radial nerve

# Radial Nerve

- Posterior cutaneous nerve of arm (posterior brachial cutaneous) - provides sensory innervations for much of the skin on the back of the arm.
- Inferior lateral cutaneous nerve of arm (inferior lateral brachial cutaneous) - provides sensory and vasomotor innervation to the lower, lateral aspect of the arm.
- Posterior cutaneous nerve of forearm (posterior antebrachial cutaneous).-skin of the posterior of the forearm
- Superficial branch – back of the hand

# Radial Nerve Dermatomes





# Radial Nerve

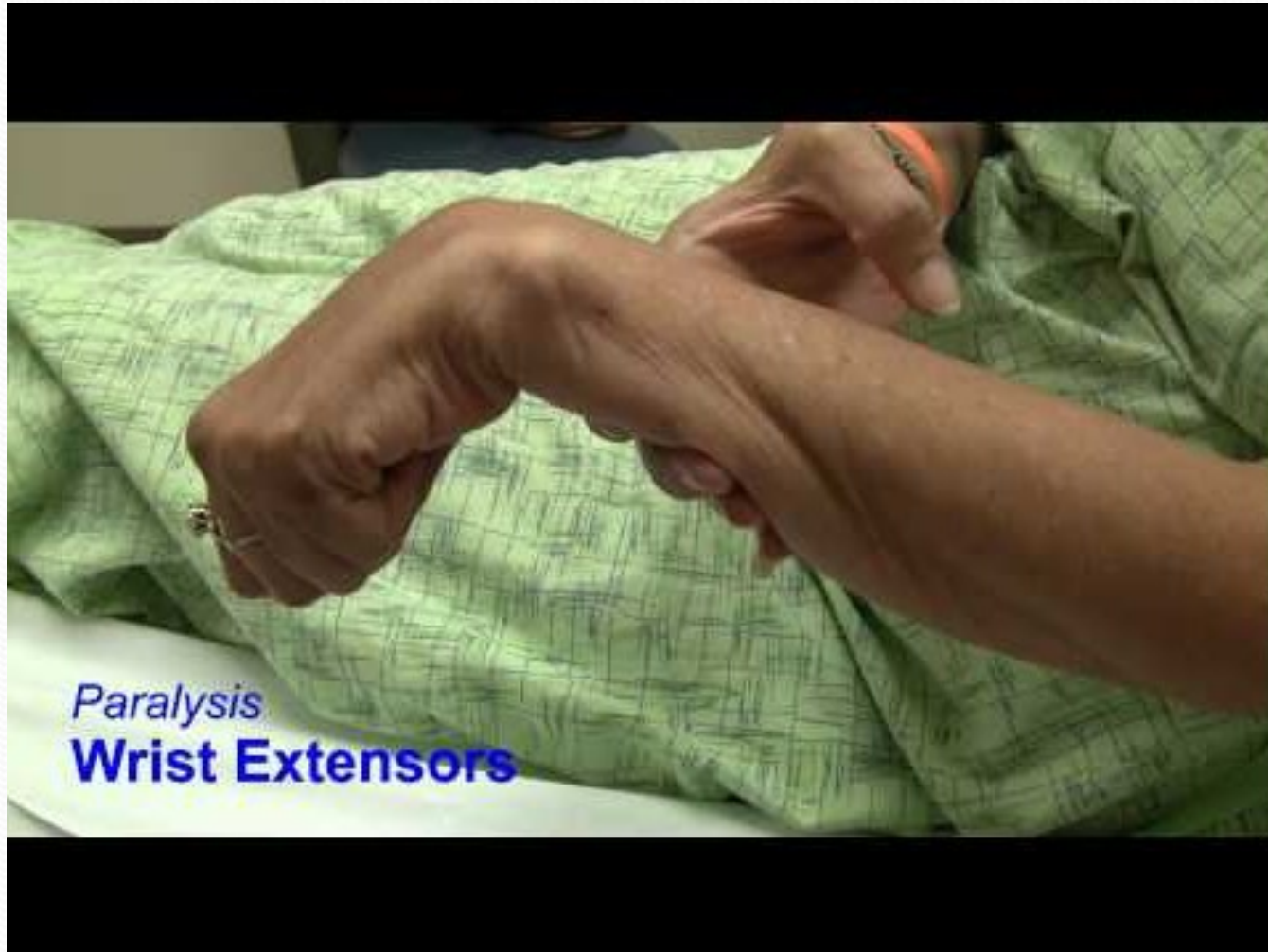- **Motor innervations**
- Triceps brachii, anconeus, brachioradialis, supinator and mostly posterior compartment extrinsic hand muscles.

## Cont...

- The radial nerve is often injured in its course close to the humerus, either from fracture or pressure from direct blow to the humerus (incorrect use of a crutch)
- Triceps usually escapes because derivation of the nerve giving off high in arm, but total paralysis of the extensor of the wrist and digits leads to the **dropped wrist deformities**.



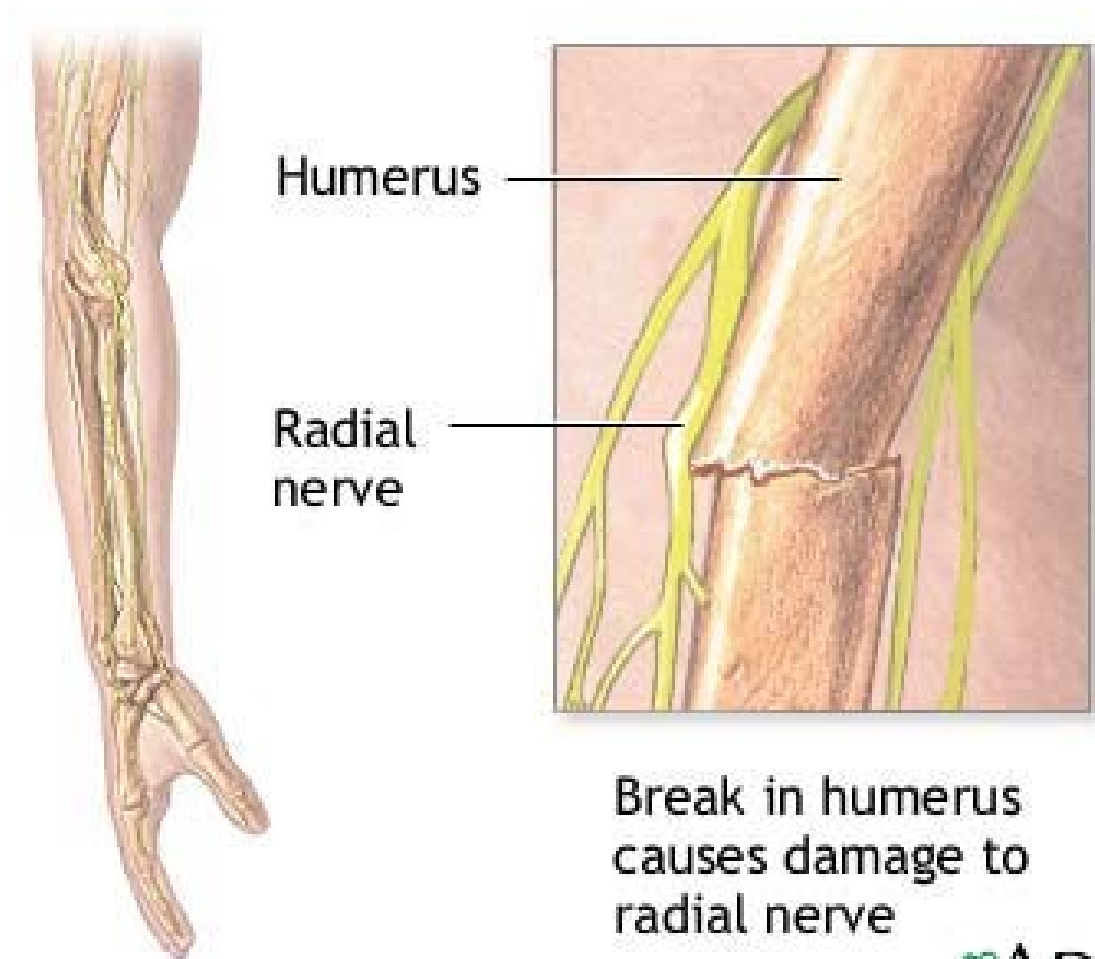
# Wrist Dropped



*Paralysis*  
**Wrist Extensors**



# Fracture of the humerus



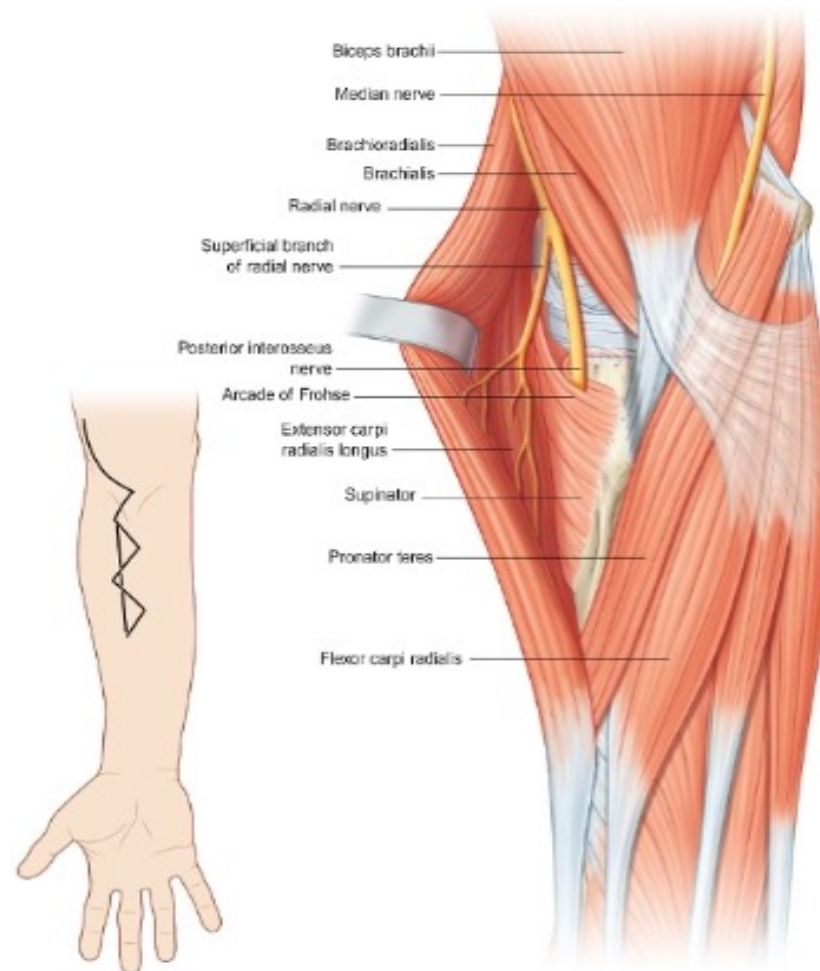
# Posterior interosseous nerve compression in the proximal forearm

- The PIN arises from the bifurcation of the radial nerve in the proximal forearm. The PIN is a motor-only nerve that innervates the extensor muscles and abductor pollicis longus distal to the elbow. The PIN does not innervate the ECRL, brachioradialis, or anconeus muscles; these muscles instead receive their innervation from the radial nerve proximally. Immediately distal to the bifurcation, the PIN travels through the radial tunnel, a 5-cm space defined by the capsule of the radiocapitellar joint dorsally, the ECRL and extensor carpi radialis brevis (ECRB) muscles laterally, the biceps tendon and brachialis muscles medially, and the brachioradialis volarly.
- Within the area of the radial tunnel there are five potential sites of compression: (1) fibrous bands to the radiocapitellar joint between the brachialis and brachioradialis; (2) the recurrent radial vessels, or so-called leash of Henry; (3) the proximal edge of the ECRB; (4) the proximal edge of the supinator, or so-called arcade of Fröhse; and (5) the distal edge of the supinator. The arcade of Fröhse is felt to be the most common site of PIN compression. Compression of the PIN gives rise to two different compression syndromes, PIN and radial tunnel syndromes. The management of these two syndromes is identical.



Anterior approach to the posterior interosseous nerve. This provides good exposure of the radial tunnel when the point of compression cannot be localized to the arcade of Frohse. The zigzag

incision provides a wider exposure, but may be less cosmetically acceptable to the patient ●





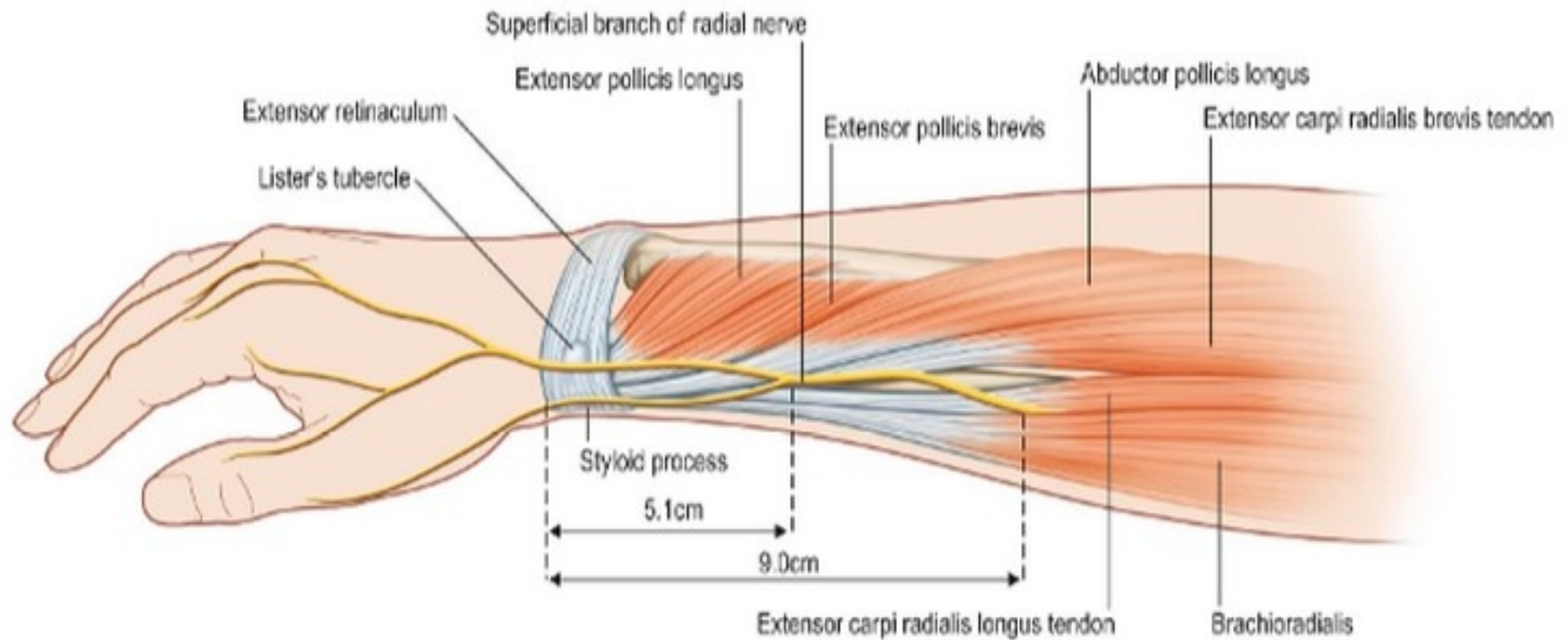
# Posterior interosseous nerve compression in the proximal forearm

- **Posterior interosseous nerve syndrome**
- Patients with PIN syndrome present with loss of finger and thumb extension, most often due to compression of the PIN at the arcade of Fröhse.<sup>135</sup> Wrist extension is preserved, albeit with radial deviation, as innervation to the ECRL is unaffected.
- **Radial tunnel syndrome**
- Like PIN syndrome, radial tunnel syndrome results from compression of the PIN. In contrast to patients with PIN syndrome, radial tunnel syndrome patients complain of lateral proximal forearm pain with no discernible motor weakness.

# Superficial radial nerve compression (Wartenberg's syndrome)

- The fascia between the brachioradialis and ECRL is divided and the superficial radial nerve freed from its bed.

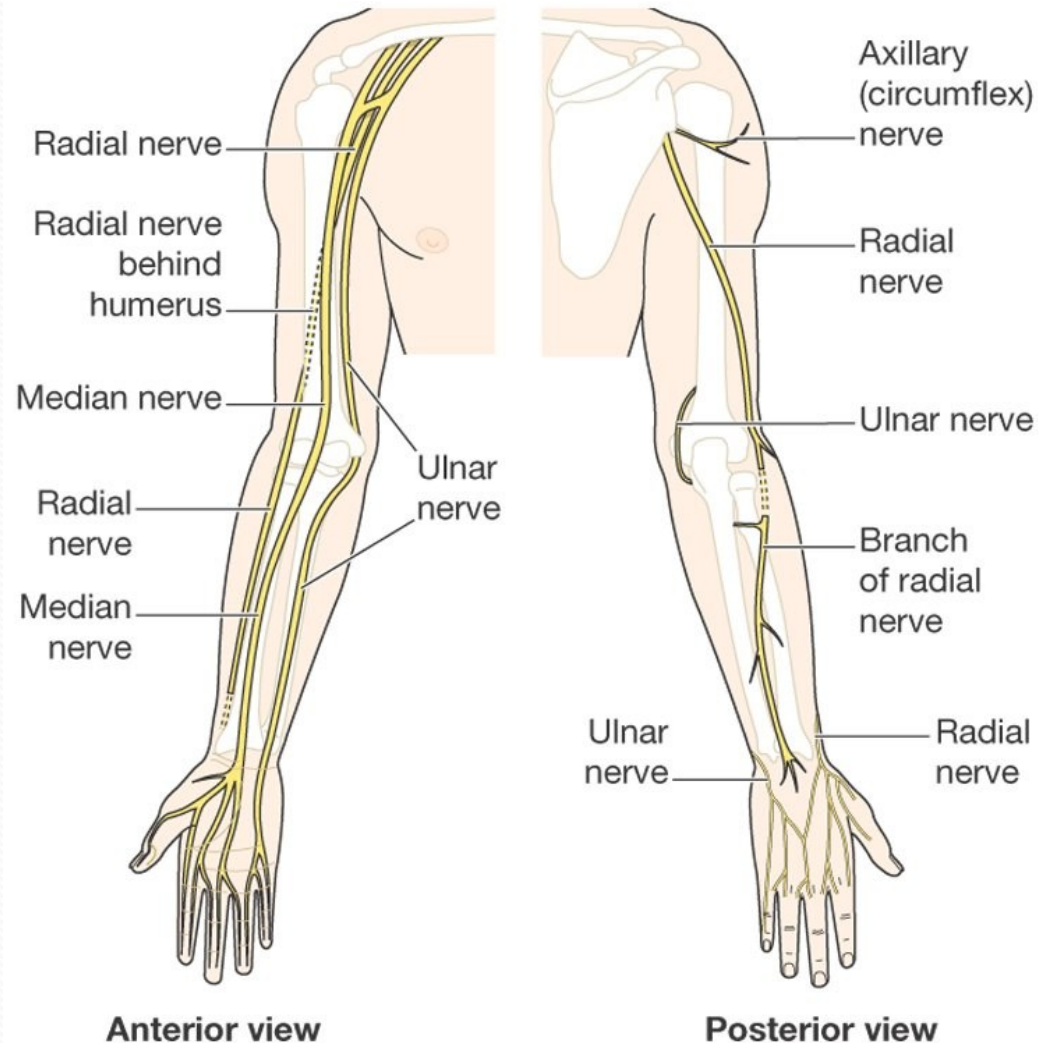
# Anatomy of the superficial sensory branch of the radial nerve.





# Ulnar Nerve

- Arise from medial cord of brachial plexus
- Root C8 and T1 (mostly C7)
- Descend on the posteromedial of the humerus.
- Then it goes posterior to the medial epicondyle.



# Ulnar Nerve

- Enter anterior compartment muscles of forearm and supplies flexor carpi ulnaris and medial half flexor digitorum profundus.
- Then ulnar nerve enter palm of the hand and branch off to the **superficial branch** and **deep branch**.
- Deep branch innervate hypothenar muscles, intermediate hand muscles and thenar hand muscles (adductor pollicis, flexor pollicis brevis (rare))

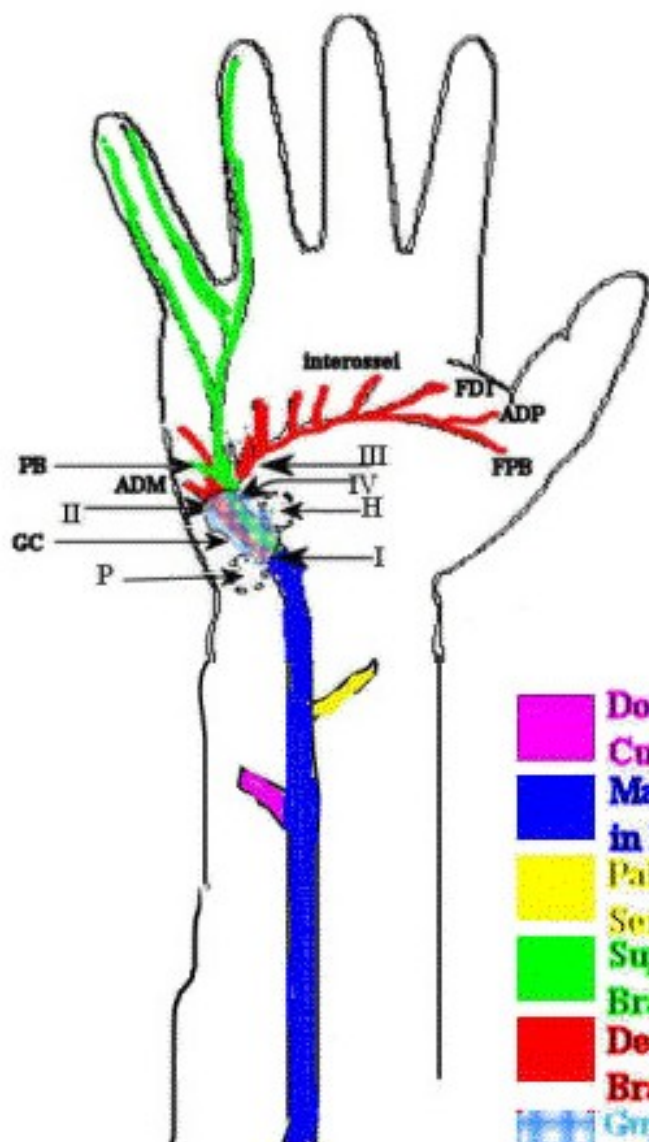


# Ulnar Nerve

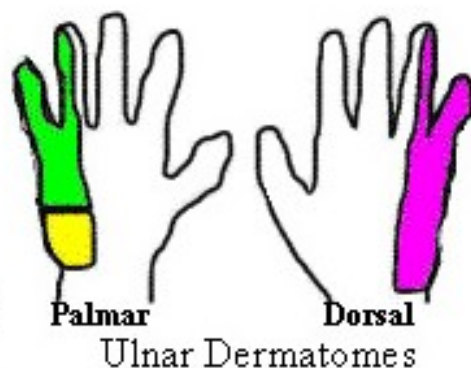
- Superficial branches of Ulnar nerve will innervate palmaris brevis and skin anterior and posterior of the hand (medial aspect of the hand/ one and half digits)



# Ulnar Nerve: Forearm, Guyon's Canal, and Hand



- Dorsal Ulnar Cutaneous nerve
- Main Trunk of Ulnar in Distal Forearm
- Palmar Cutaneous Sensory Nerve
- Superficial Terminal Branch of Ulnar
- Deep Terminal Branch of Ulnar
- Guyon's Canal



## Common Ulnar Impingement Sites: Guyon's Canal Region

- I. At the very entrance of Guyon's canal or just within it, potential impacting all terminal branches (red and green).
- II. Right after the nerve comes out of the canal, impacting the deep terminal motor branch (red). No sensory loss.
- III. The deep motor branch after the branch to the hypothenar muscles has taken off. Motor loss except in hypothenar area. No sensory loss.
- IV. The superficial terminal branch (green). All sensory except for a small branch (PB) to the palmaris brevis muscle. Sensory loss on the fifth and the ulnar half of the 4th digit.

### Abbreviations

M. - Muscle

PB-Branch to Palmaris Brevis M.

ADM-Adductor Digiti Minimi M., also represents other hypothenar muscle including flexor and Opponens digiti minimi

FDI-First Dorsal Interosseus M.

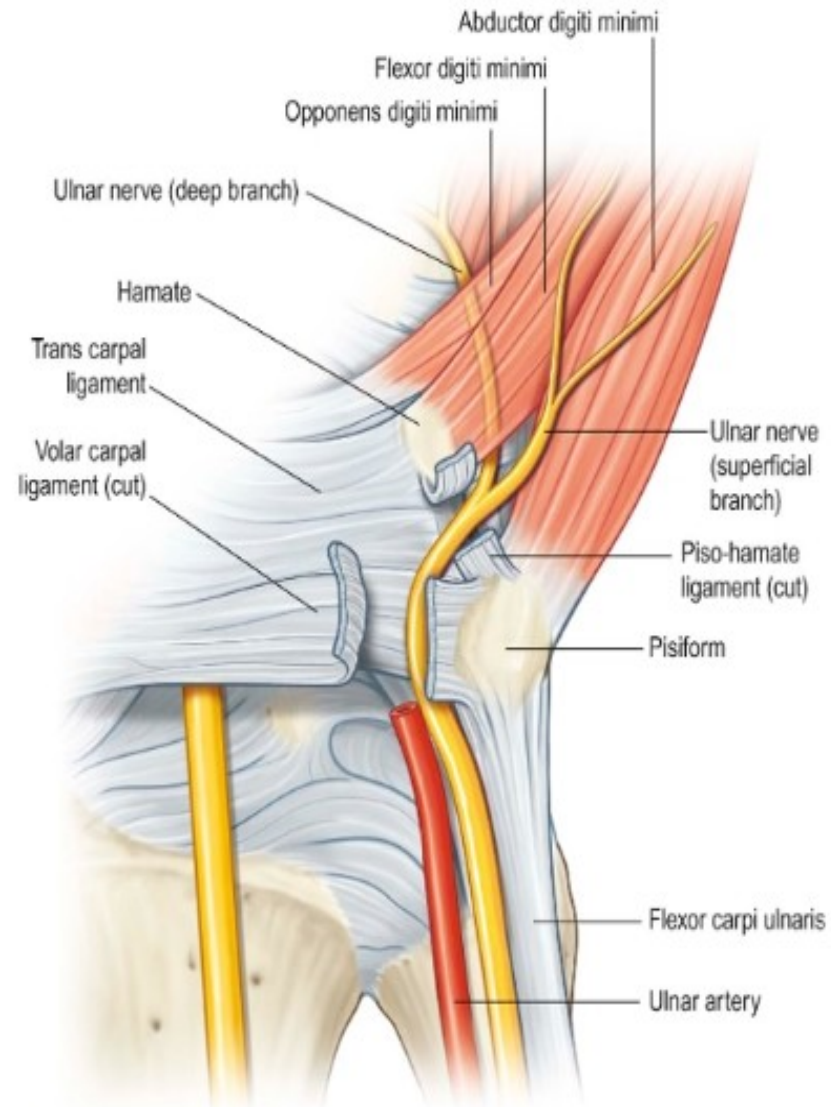
ADP-Adductor Pollicis M.

FPB-Flexor Pollicis Brevis M.

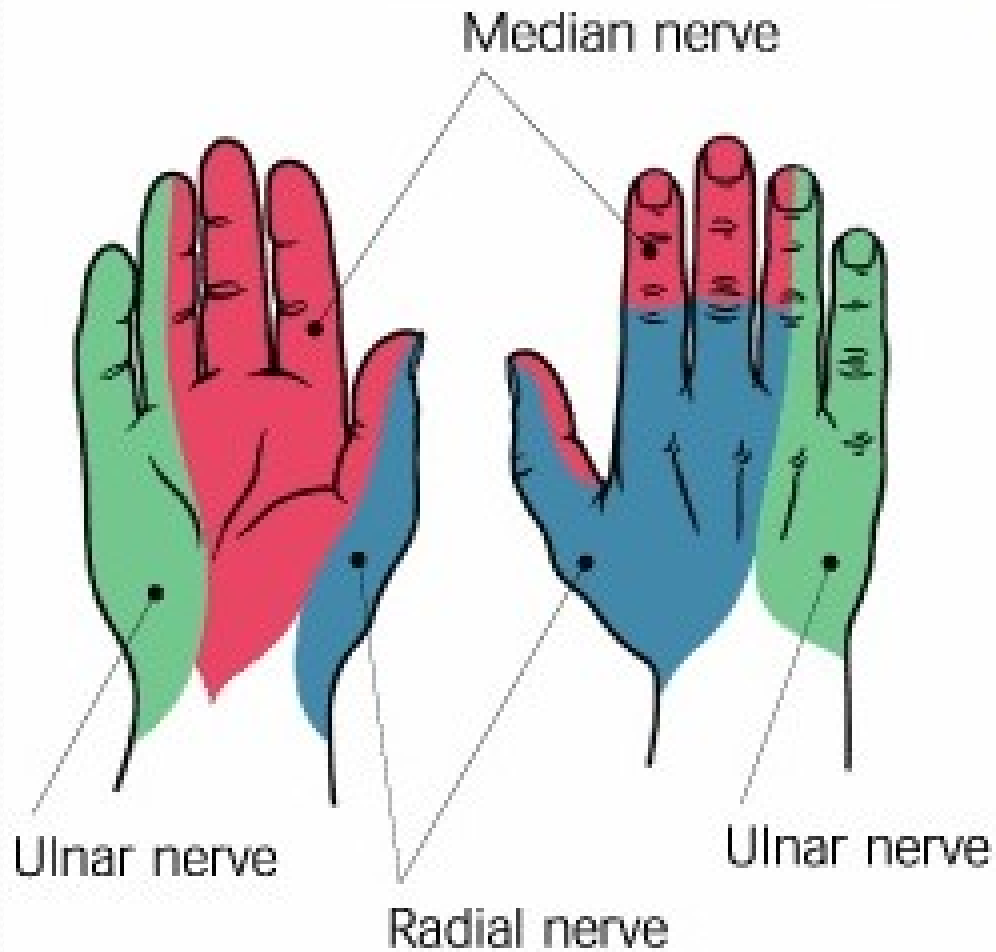
GC-Guyon's Canal; P Pisiform bone; H hamate bone

Interossei-Interosseous muscle of the hand. Other ulnar Intrinsic hand muscles are also similarly innervated

# Guyon's canal



# Hand Dermatomes





# Cont...

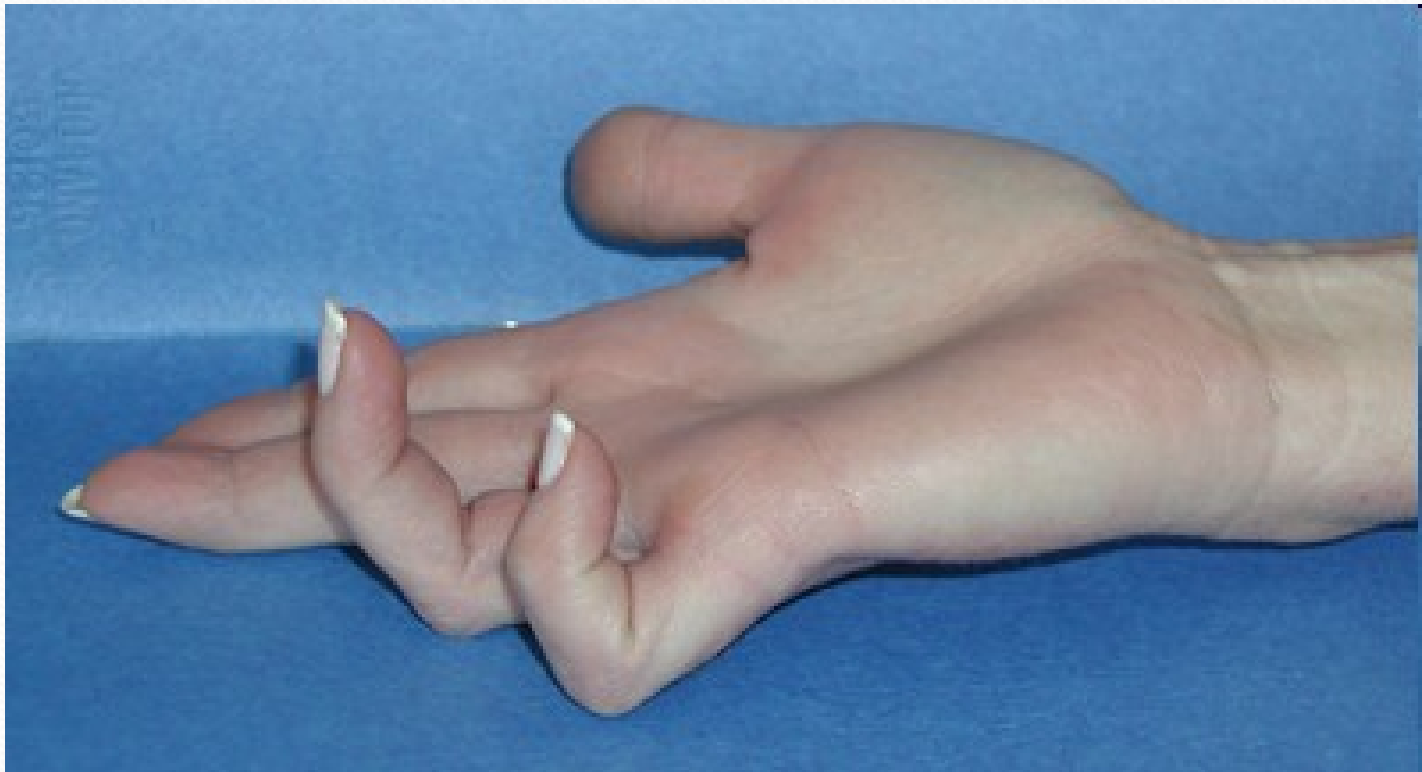- Ulnar nerve may be damaged in the groove behind the medial epicondyle either by trauma or entrapment.
- Leads to partial or completely lost of muscular and sensory innervations.
- The results of the ulnar nerve lesion leads to the typical '**claw hand**' deformities.
- Due to lost of the power in the intrinsic hand muscles and unopposed actions of antagonistic muscles group.
- Wasting of hypothenar eminence.
- There are 'guttering between metacarpals, inability to abduct the fingers or adduct the thumb.
- Sensory lost

**TABLE 24.2** Clinical signs of ulnar nerve palsy

Duchenne's sign (claw or intrinsic-minus deformity)	Hyperextension of proximal phalanx with flexion of middle and distal phalanges caused by paralysis of lumbricals and interossei muscles
Masse's sign	Flattening of the dorsal transverse metacarpal arch caused by hypothenar paralysis and loss of fifth metacarpal supination
Wartenberg's sign	Ulnar deviation and weak adduction of the small finger caused by unopposed pull of extensor digiti minimi
Froment's sign	Hyperflexion of thumb distal phalanx and supination of index during attempted key pinch caused by atrophy of adductor pollicis and first dorsal interosseous muscles
Jeanne's sign	Hyperextension deformity of thumb metacarpophalangeal joint caused by compensatory instability

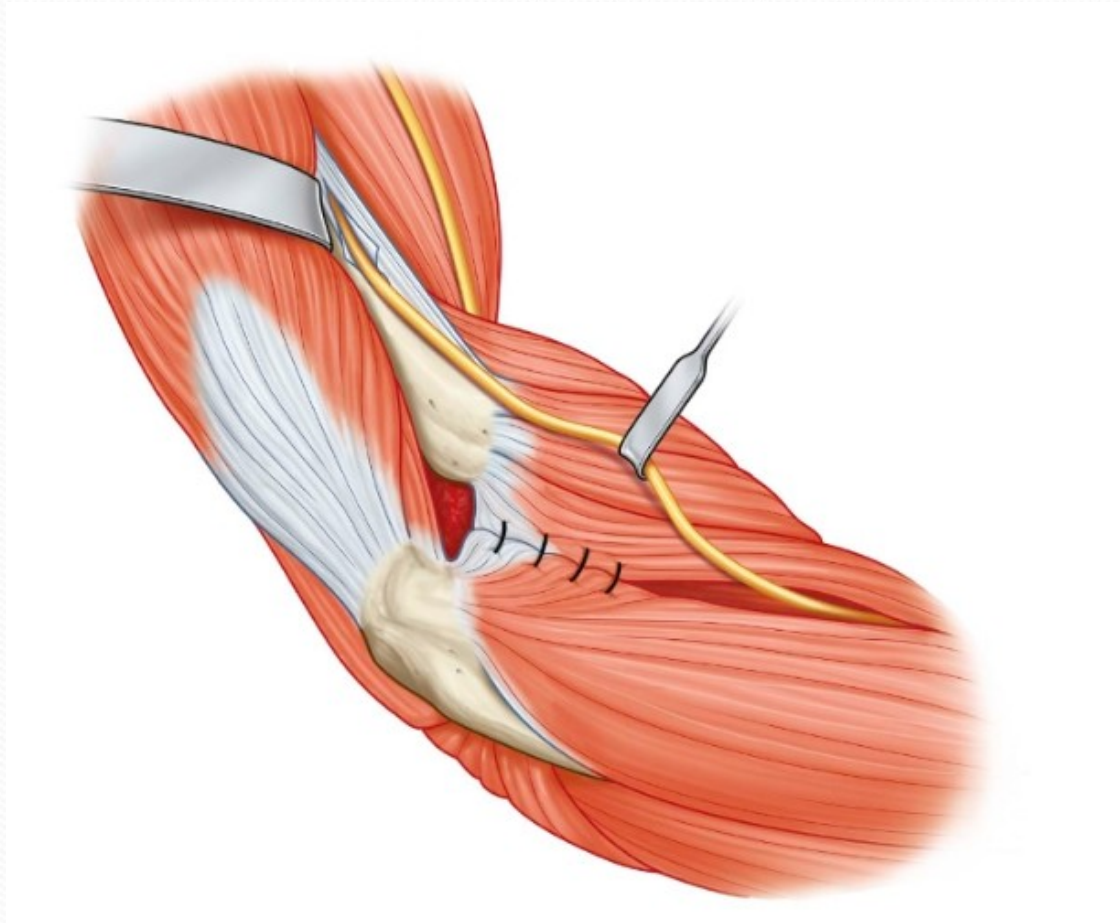


# Claw Hand Deformities

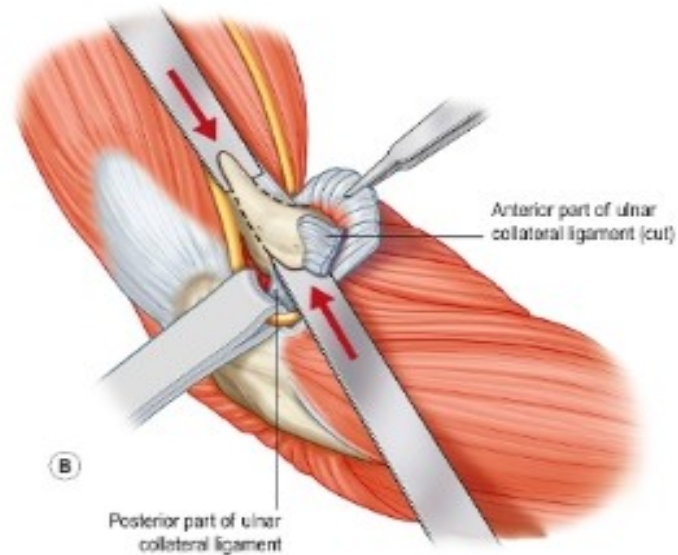
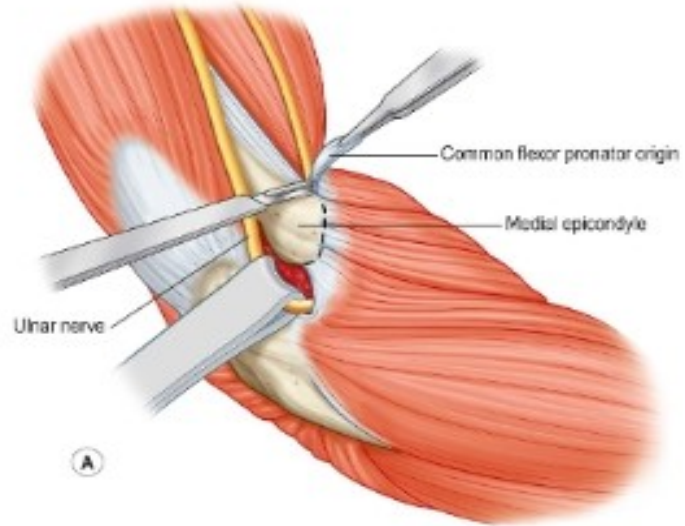




# Subcutaneous transposition technique



# Medial epicondylectomy technique





# Median Nerve

- Arise from lateral root of lateral cord (C<sub>5,6,7</sub>) and medial root and medial cord (C<sub>8</sub>,T<sub>1</sub>) of brachial plexus.
- Passes down the midline of the arm in close association with the brachial artery.
- Passes in front of elbow joint (cubital fossa) then down to supply the muscles of the anterior of forearm.
- Then it continue into the hand through carpal tunnel where it supply intrinsic hand muscles and

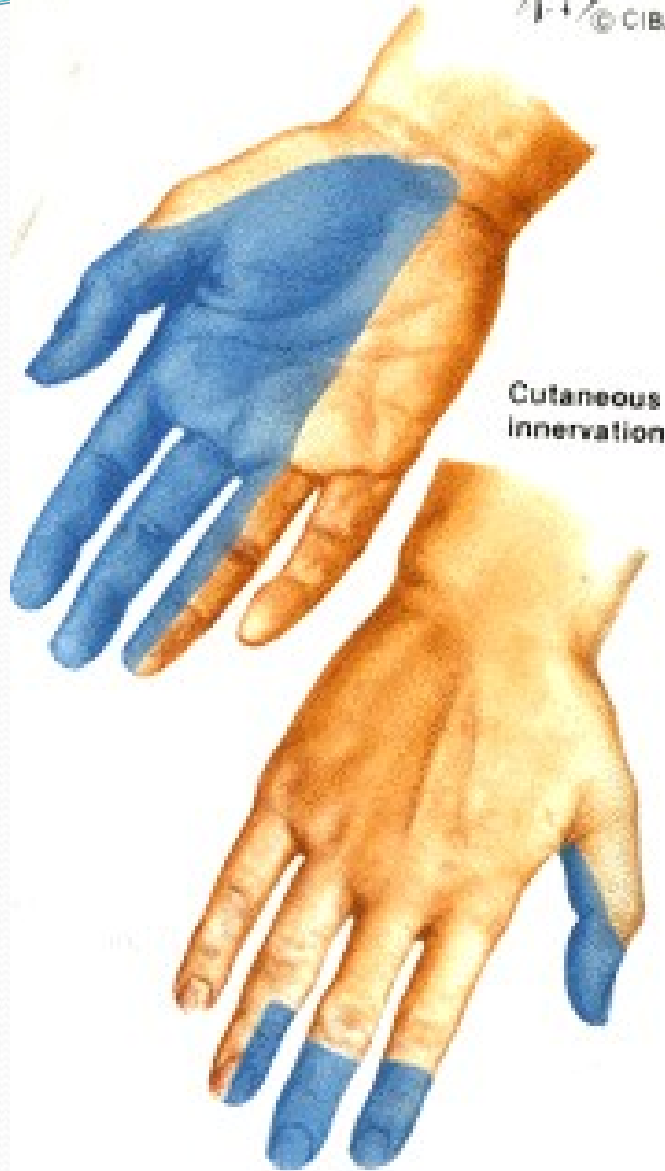

- At the cubital fossa the anterior interosseous nerve arises from the median nerve
- Descend through the forearm and end at the wrist by giving the articular branch to the radiocarpal and intercarpal joint.
- It supplies flexor pollicis longus, lateral half flexor digitorum profundus and pronator quadratus

# Median Nerve

- Motor – all anterior (flexor) compartment of forearm (except flexor carpi ulnaris and ulnar half of the flexor digitorum profundus ), pronator teres & quadratus, intrinsic hand muscles (LOAF; 1,2 lumbricals, OP, FPB, APB)
- Sensory – skin of the palmar aspect of the thumb and the lateral 2 ½ fingers and the distal ends of the same fingers and skin of distal phalanx on same finger

F. Netter M.D.  
© CIBA



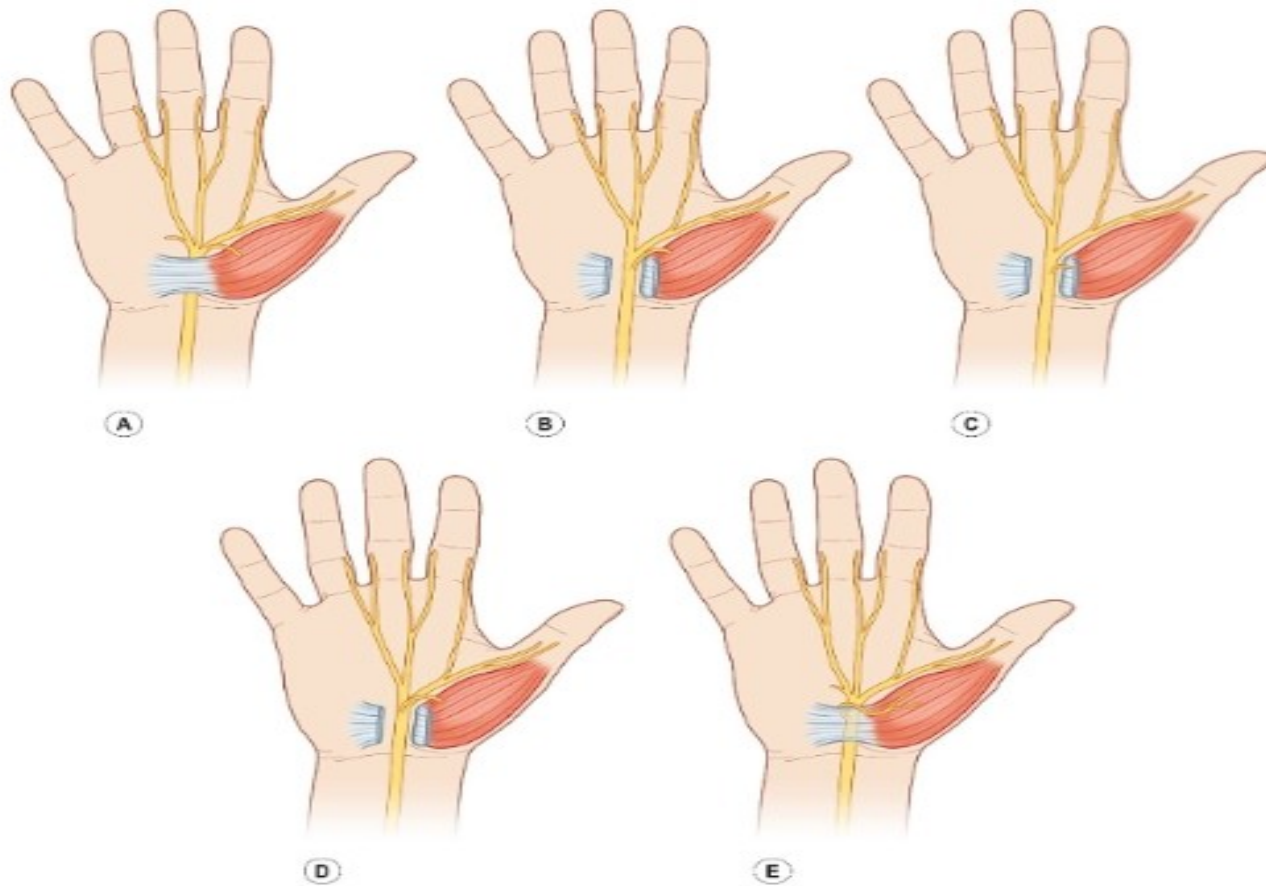
# Median nerve dermatomes



# Cont...

- Median nerve can be injured by deep cut with resultant lost of flexion at all IP joint except the distal ones in the ring and little finger.
- MCP still can be flexed at this fingers ( lumbricals)
- In the hand thumb is extend and adducted, lost of ability to abduct and oppose.
- Compression at the carpal tunnel give rise the carpal tunnel syndrome (CTS)

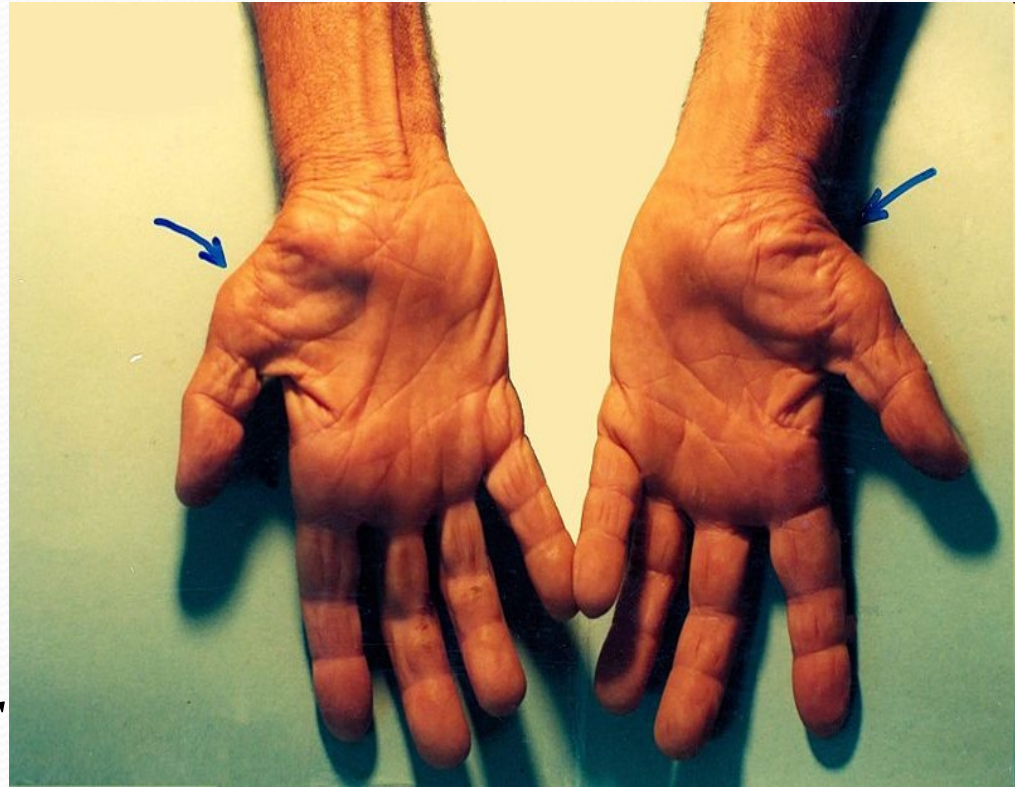
Variations in median nerve anatomy in the carpal tunnel. **(A)** The most common branching pattern of the motor branch is extraligamentous. **(B)** Subligamentous branching pattern of the motor branch. **(C)** Transligamentous course of the recurrent motor branch. **(D)** The motor branch can rarely arise from the ulnar border of the median nerve. **(E)** The motor branch can also lie superficial to the transverse carpal ligament.





# Carpal Tunnel Syndrome

- Compression median nerve at the carpal tunnel
- Patient will experience numbness, tingling, or burning sensation at the thumb, index, middle and radial half of the ring finger.
- If untreated – weakness or atrophy of the thenar muscles.





# Carpal Tunnel Syndrome

- The six criteria included: (1) nocturnal numbness; (2) numbness and tingling in the median nerve distribution; (3) weakness and/or atrophy of the thenar muscles; (4) Tinel sign; (5) Phalen's test; and (6) loss of two-point discrimination.

# American Academy of Orthopaedic Surgeons clinical practice guidelines

- Nonsurgical treatment is an option for early CTS. Surgery is an option when there is evidence of median nerve denervation.
- A second nonsurgical treatment or surgery is recommended when initial nonsurgical treatment fails after 2–7 weeks
- Local steroid injection or splinting is recommended prior to treatment with surgery
- Oral steroids and ultrasound are also options for treatment

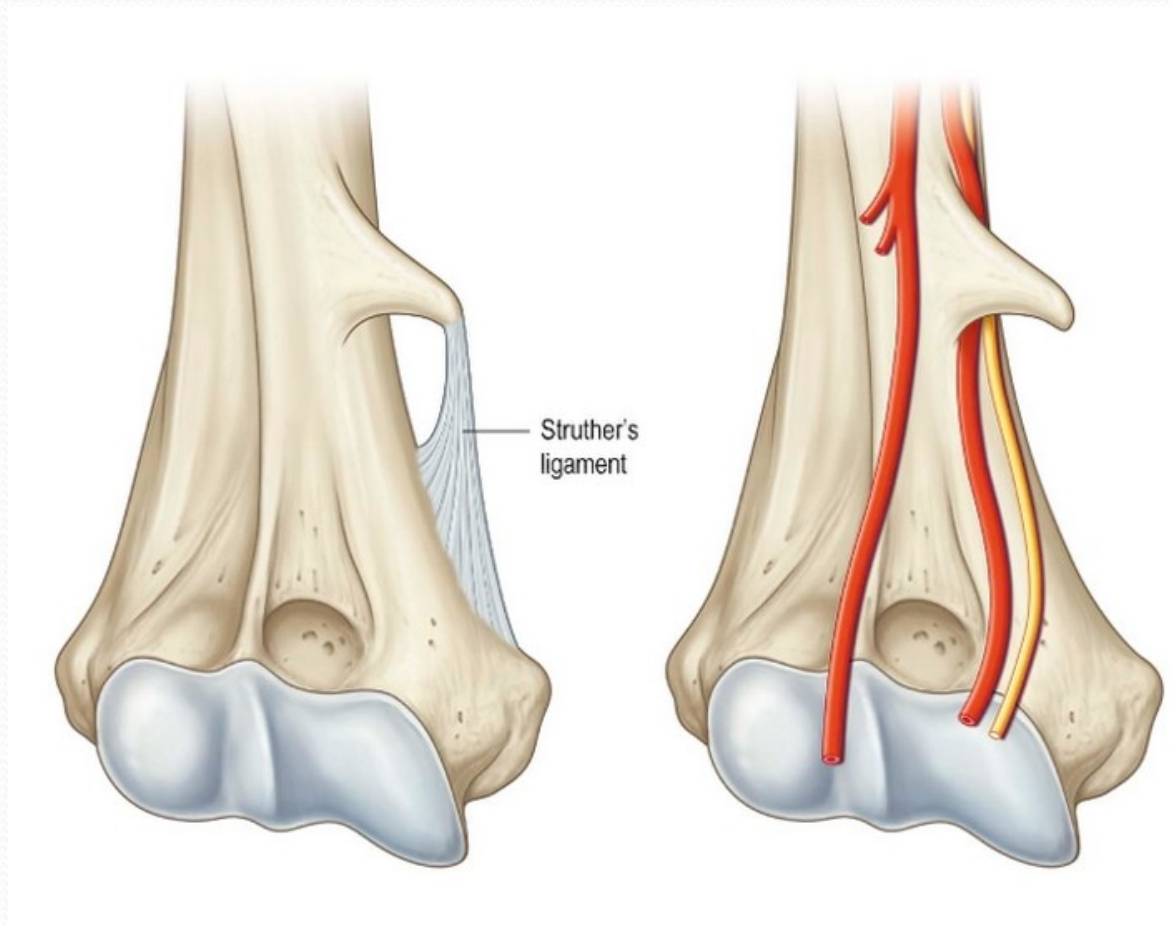


# American Academy of Orthopaedic Surgeons clinical practice guidelines

- Carpal tunnel release is recommended for treatment of CTS based on level I evidence
- Heat therapy does not have evidence to support its use in CTS.
- Surgical treatment with complete division of the flexor retinaculum is recommended, regardless of the technique used.
- Wrist immobilization is not recommended postoperatively after routine carpal tunnel release. No recommendation is made regarding use of postoperative rehabilitation.



Ligament of Struthers. This proximal site of compression of the median nerve is formed by a supracondylar bony process and a ligament that extends to the medial humeral epicondyle •

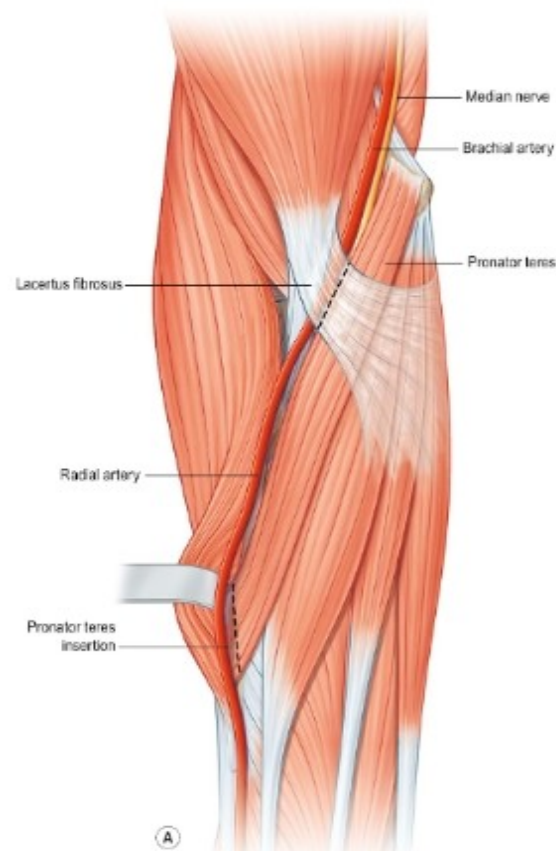


# Pronator syndrome

- aching pain in the proximal volar forearm with paresthesias
- sensation in the palmar cutaneous nerve distribution lost
- attempt to pronate the neutral forearm against resistance; if symptoms are elicited during this maneuver as the elbow is extended, compression at the level of pronator teres should be suspected.<sup>82</sup> If pain or paresthesias are triggered by resisted flexion of the fully supinated forearm, the lacertus fibrosus may represent the site of compression. Finally, if resisted contraction of the FDS to the long finger reproduces symptoms, the FDS fibrous arch is a more likely compression point



Decompression of the proximal median nerve. **(A)** The lacertus fibrosis is divided. **(B)** The exposed deep head of the pronator teres and fibrous arch of the flexor digitorum superficialis (FDS) are also divided to decompress the median nerve fully. **(C)** The radial origin of the FDS is elevated to expose the anterior interosseous nerve through its entire course.

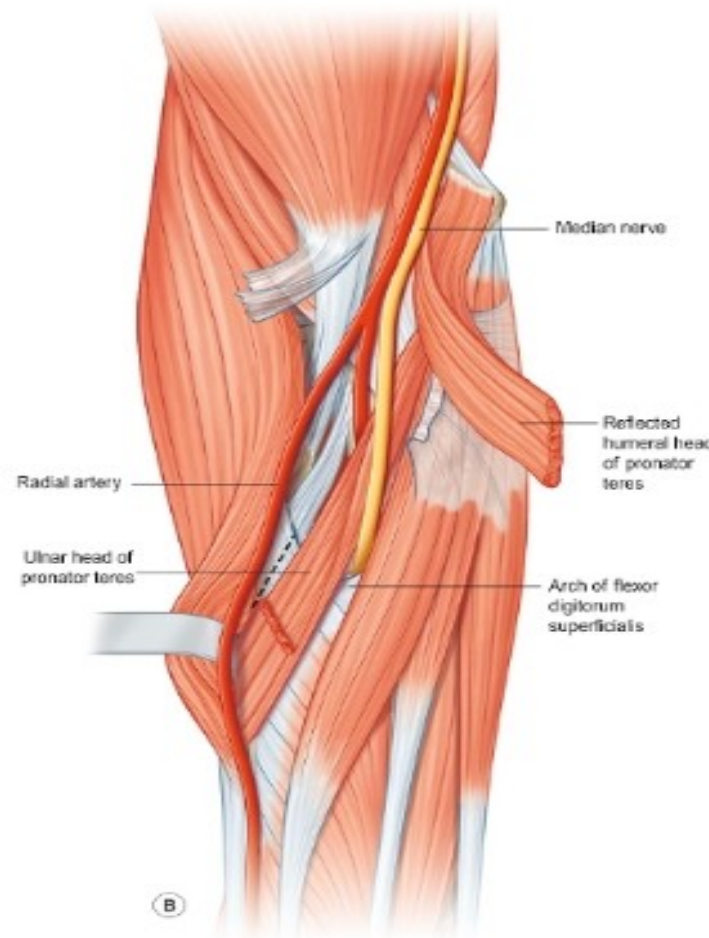




# AIN syndrome

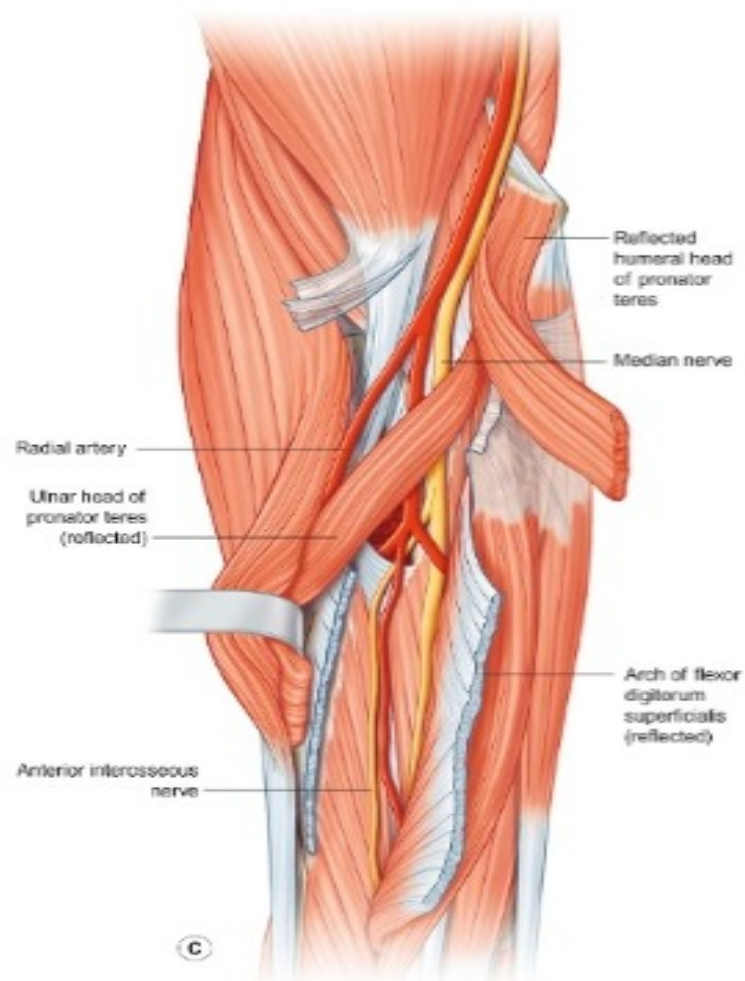
- AIN syndrome results from the isolated compression of the AIN under the fibrous arch of the FDS or the pronator teres. Patients with AIN syndrome will describe weakness of pinch, which affects activities such as picking up small objects and writing, without sensory loss.

Decompression of the proximal median nerve. **(A)** The lacertus fibrosis is divided. **(B)** The exposed deep head of the pronator teres and fibrous arch of the flexor digitorum superficialis (FDS) are also divided to decompress the median nerve fully. **(C)** The radial origin of the FDS is elevated to expose the anterior interosseous nerve through its entire course.



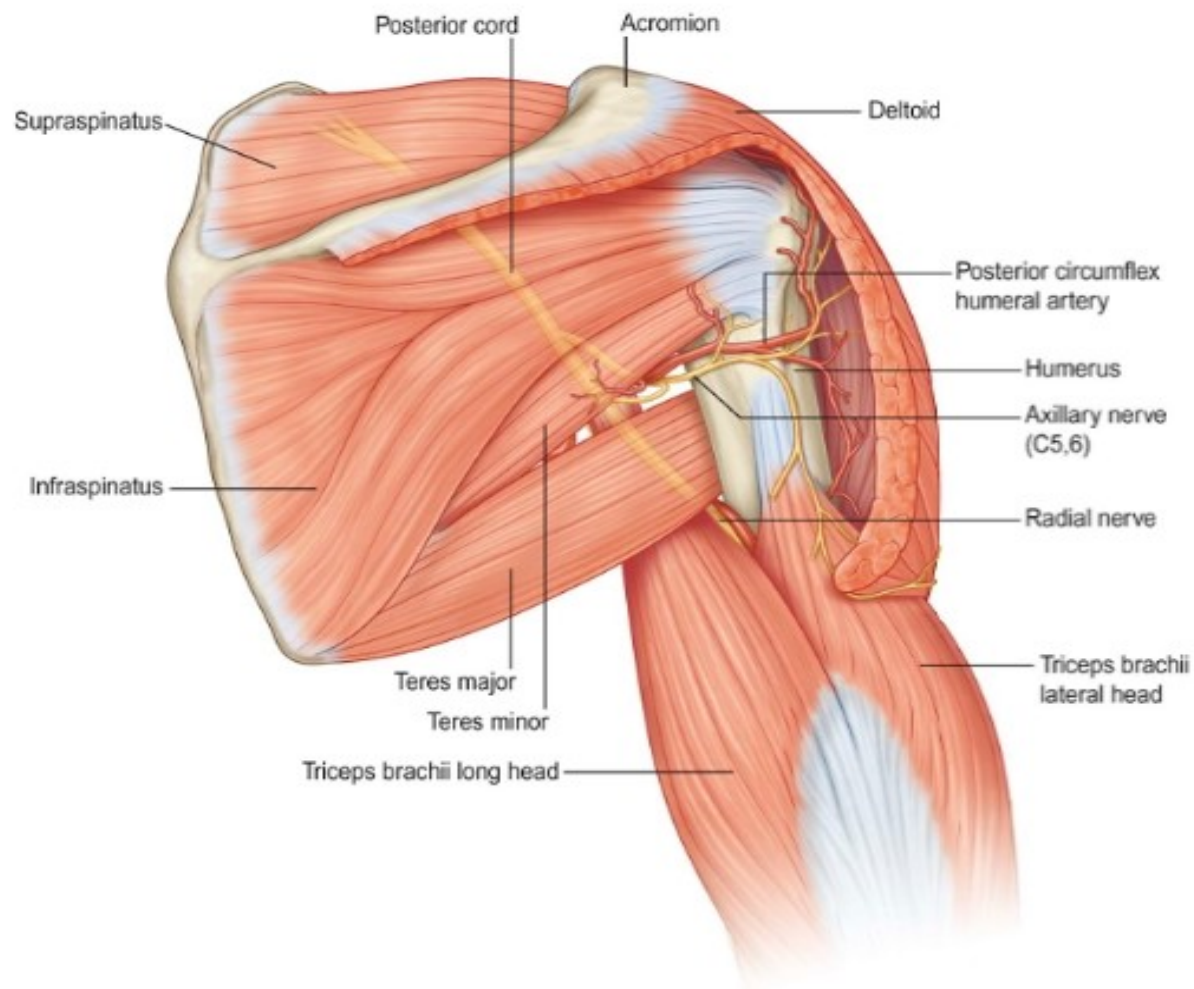


Decompression of the proximal median nerve. **(A)** The lacertus fibrosis is divided. **(B)** The exposed deep head of the pronator teres and fibrous arch of the flexor digitorum superficialis (FDS) are also divided to decompress the median nerve fully. **(C)** The radial origin of the FDS is elevated to expose the anterior interosseous nerve through its entire course.

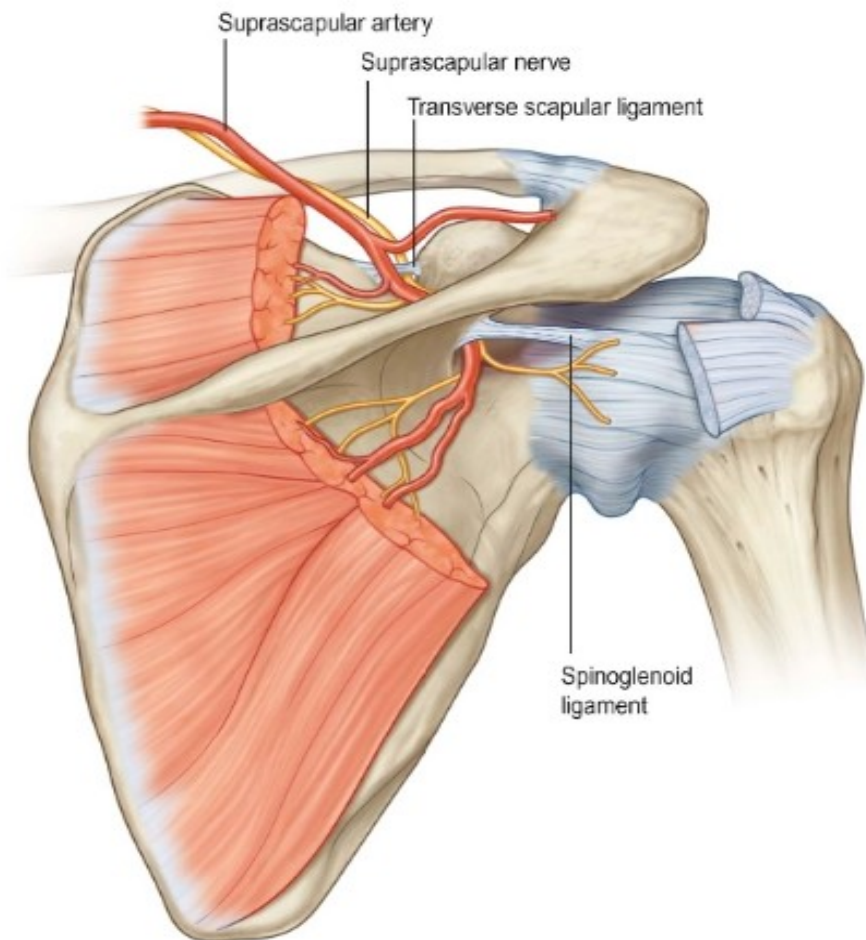




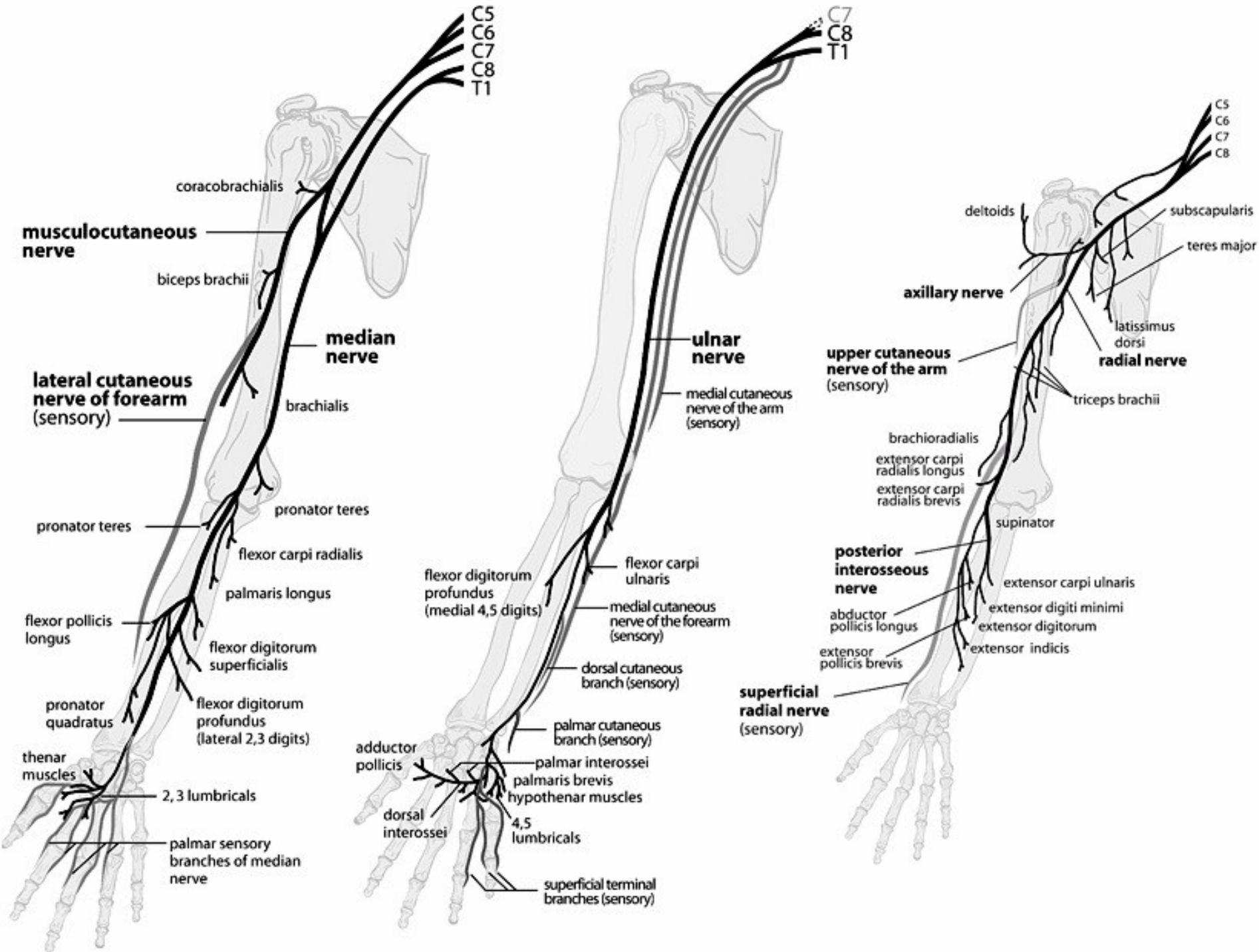
# Anatomic boundaries and contents of the quadrilateral space.



Suprascapular anatomy. The suprascapular nerve passes under the transverse scapular ligament and through the suprascapular notch. Similarly, the spinoglenoid notch is covered by the spinoglenoid ligament. Both ligaments can compress the suprascapular nerve











*thank*

**S**