

Ulrich Schiefer

## Visual field defects Essentials for neurologists

### Introduction

#### ■ The visual pathway – a highly sensitive “functional trip-wire”

The visual pathway achieves neuronal signal transduction between retinal photoreceptors, visual cortex and higher order visual areas. Lesions affecting this “trip-wire” will result in visual impairment which should induce the affected person to contact a physician. Correct interpretation of such symptoms and choice of appropriate psychophysical examination methods will usually provide the examiner with specific information on topography and eventual progression, if baseline results are available [3, 6]. These data are essential prerequisites for effective neuroimaging, as well as for an adequate follow-up.

### Functional anatomy of the human visual pathways

The different sections of the visual pathways differ markedly with respect to the number, density and extent of “intermixture” of neuronal elements, which will strongly influence local resolution power and diagnostic relevance (Fig. 1).

Received: 18 January 2003  
Accepted: 30 January 2003

Prof. Dr. med. Ulrich Schiefer (✉)  
Dept. of Pathophysiology of Vision  
and Neuro-Ophthalmology  
University Eye Hospital Tuebingen  
Schleichstr. 12–16  
72076 Tübingen, Germany  
Tel.: +49-70 71/2 98-47 86  
Fax: +49-70 71/29-50 38  
E-Mail: ulrich.schiefer@uni-tuebingen.de

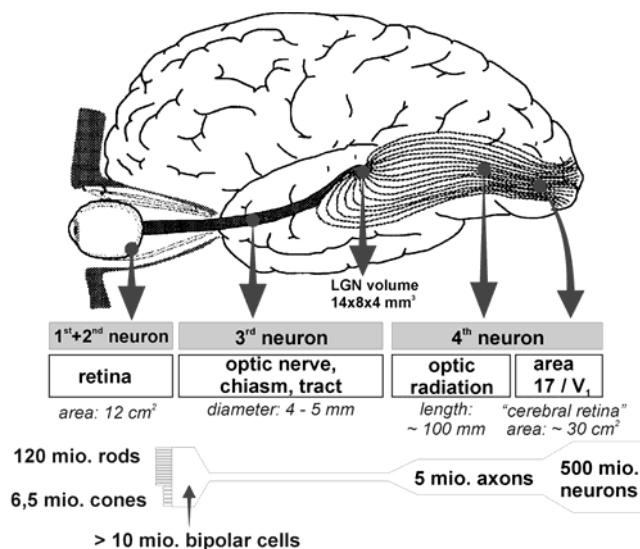


Fig. 1 Functional anatomy of the human visual pathways

About 7 million cones and approximately 120 million rods are distributed on the human retinal surface (area ~ 12 cm<sup>2</sup>). Each retinal element is directly linked to a specific location within the visual field. More than 10 million bipolar cells forward the visual information onto only 1.2 million ganglion cells. These cells are widespread on the retinal surface, and converge to 300–500 fibre-bundles with a total surface area of less than 0.2 cm<sup>2</sup>. There is a maximum neuronal density in the region of the optic chiasm: the entire visual information is “packed” into this “visual bottleneck” of about 1 cm<sup>3</sup>! In contrast to the optic nerve region, the diagnostic impact of the optic chiasm is considerable, owing to the complex “neuronal interweaving” between fibres coming from the right and left eye. Thus lesions in this region result in a highly specific “perimetric fingerprint”, characterized by a visual field defect, which (at least locally) respects the vertical meridian. On their postchiasm

course, the fibres pass the optic tracts projecting onto 5 million neurons within the lateral geniculate nucleus, which has about the size of an almond in humans. Since there is no visible transsynaptic degeneration in the visual pathways of human adults, postgeniculate lesions result in a contralateral visual field defect *without* optic atrophy. Neurons diverge considerably in their further course around the inferior parts of the lateral ventricles, invading especially the temporal and, to a minor extent, also the parietal lobe. Fibres project onto 500 million visual neurons of the primary visual cortex of the occipital lobe, covering a cortical surface of approximately 30 cm<sup>2</sup>. The central 10° of the visual field are represented by about 50% of the striate cortex.

In accordance with the geometry of this anatomy, defects of the upper visual field are related to lesions of lower parts of the visual pathways (starting from the retina through to the visual cortex) and vice versa.

## Patients' history – the diagnostic key

### ■ Time course refers to pathogenesis

*Abrupt onset* of visual impairment is typical of vascular (arterial) or traumatic processes. Functional defects with *rapid progression* (*within a few hours*) are most often due to inflammation, increased intracranial pressure or vascular (venous) processes. A slowly progressive functional impairment, which is often not noticed by the patient, is usually caused by a space-occupying lesion or a chronic disease (retinitis pigmentosa, glaucoma, hereditary optic atrophy, pituitary adenoma, etc.).

## Diagnostic strategies of visual pathway lesions

### ■ Bedside tests

The *swinging flashlight test* is an “objective” examination, i. e. it is almost independent of the patient's co-operation. Unilateral or asymmetric affection of the anterior visual pathway (up to the optic tract) induces a relative afferent pupillary defect (RAPD) in this test. Normal function of at least one pupil is essential for this procedure. The *Amsler grid* can detect circumscribed scotomata as well as metamorphopsia (in retinal oedema or other disarrangements of retinal photoreceptors) within the central 10° of the visual field. Testing reading performance, as well as far and near visual acuity (each with adequate correction) are further diagnostic instruments used to evaluate the central region of the visual field. *Confrontation perimetry* can be helpful in cases of advanced visual field defects. *Colour desaturation* (especially for red) and “*subjective monocular re-*

*duction of brightness perception*” are important in unilateral or at least asymmetric optic neuropathies. *Obscurations*, i. e. short-term (unilateral) blurred vision or other types of visual impairment, may be induced even by minor head movements. They are a critical sign in long-standing, chronic papilledema.

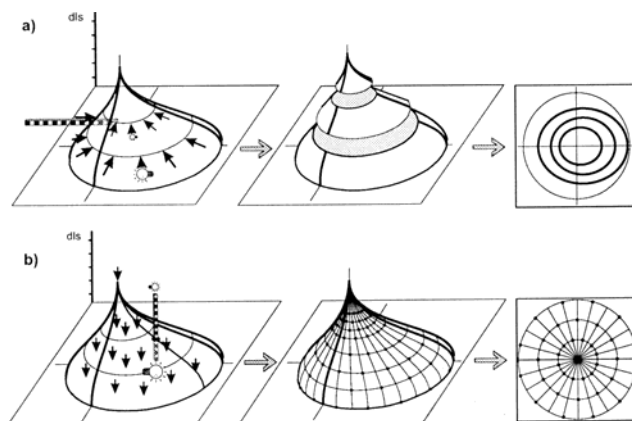
## Conventional perimetric methods

### ■ What should a neurologist know about various perimetric methods?

Nowadays there are two perimetric procedures used for evaluating the individual field of vision.

*Kinetic perimetry* (Fig. 2a) is performed with stimuli of various luminance levels. The targets are manually moved perpendicularly towards the expected borders of the scotoma or of the visual field periphery. Locations of equal differential luminance sensitivity (dls) are connected by so-called *isopters*.

In *automated static grid perimetry* (Fig. 2b) local dls is estimated at a given set of test locations (comparable to a geodesist who characterizes a certain topology with pre-defined positions of his measuring devices). Basically, the examiner has to choose between two different strategies: The so-called “*threshold-estimating*” strategy reveals a relatively exact estimation of the defect depth, but at the cost of a comparatively low number of test locations. *Threshold-oriented, slightly supraliminal methods* achieve only a moderate evaluation of defect depth, but allow a considerable spatial resolution. This is very important for neurological and neuroophthalmological diagnosis, since only with the latter method the location, the extent as well as the relation to perimetric landmarks (horizontal, and vertical meridian, blind spot, etc.) are estimated as precisely as possible. Centripetal condensation of stimuli, as well as test point location



**Fig. 2a–b** Perimetric techniques: kinetic perimetry (a), and automated static grid perimetry (b); (dls = differential luminance sensitivity)

just beside the horizontal and vertical meridians, are of special diagnostic relevance.

## Perimetric topographical diagnostics in visual pathway lesions

### Retinal processes

Visual field defects related to a retinal pathology are usually characterized by a fundoscopic correlate. A *maculopathy* is characterized by an impairment of distant and near visual acuity and an impaired reading performance. Disturbances in colour vision and face recognition are also caused by *central scotoma*. The AMSLER-grid is useful for the detection and follow-up of metamorphopsias by the patient being his own control.

*Tapetoretinal degeneration*, especially when affecting the rod receptor system, is characterized by impairment of the visual field periphery, resulting in disturbances of dark adaptation and orientation.

### Optic neuropathies

Lesions of the retinal nerve fibre layer, optic nerve head and the optic nerve itself are usually accompanied by blurred vision, colour desaturation, reduced brightness perception, relative afferent pupillary defect (RAPD) on the (more severely) affected eye. Characteristic visual field defects are shown in Fig. 3. Fundoscopic changes of the homolateral optic disc may be present but are not a necessary condition.

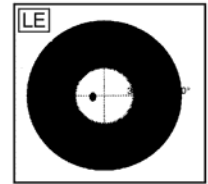
### Lesions of the optic chiasm

No other part of the visual pathway shows neurons of both eyes that are interwoven as closely as in the region of the optic chiasm. Fig. 4 illustrates the complicated course of neurons within this section, resulting in topodiagnostically specific visual field defects.

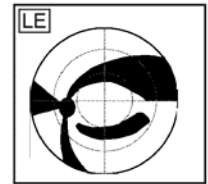
All scotomata, induced by chiasmal lesions typically respect the vertical midline of the visual field (at least in a circumscribed area). These (partially) hemianopic defects may be unilateral (when there is a pre-chiasmal lesion), heteronymous (usually bitemporal) or homonymous (with posterior chiasmal involvement). Classical bitemporal hemianopia occurs very seldom. Patients with this kind of visual field defect usually do not experience a “blinker-” or “blinder-” like visual impairment, but a so-called “hemifield-slide phenomenon”: Because of the complete bitemporal loss, there is no location within the visual field which can be perceived by corresponding retinal locations at the same time: fusional ca-

## Optic neuropathy (ON)

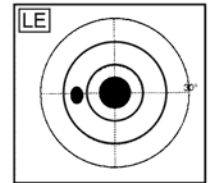
- ▶ **concentric constriction**
  - compressive ON
  - s. nerve fibre bundle defect (→ nas)



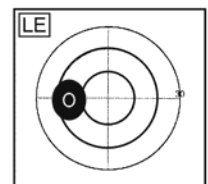
- ▶ **nerve fibre bundle defect**
  - glaucoma
  - AION
  - chorioretinitis
  - drusen
  - (chronic) papilledema
  - retinal artery (branch) occlusion



- ▶ **central- / centro-cecal-scotoma**
  - optic neuritis
  - hereditary ON
  - toxic ON
  - infiltrative ON
  - compressive ON



- ▶ **enlarged blind spot**
  - papilledema
  - myopia
  - peripapillary pathology



- ▶ **“hemianopic” defect**
  - chiasmal lesion
  - refraction scotoma
  - lesion of the optic tract

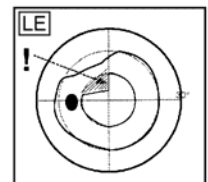


Fig. 3 Characteristic visual field defects in optic neuropathies

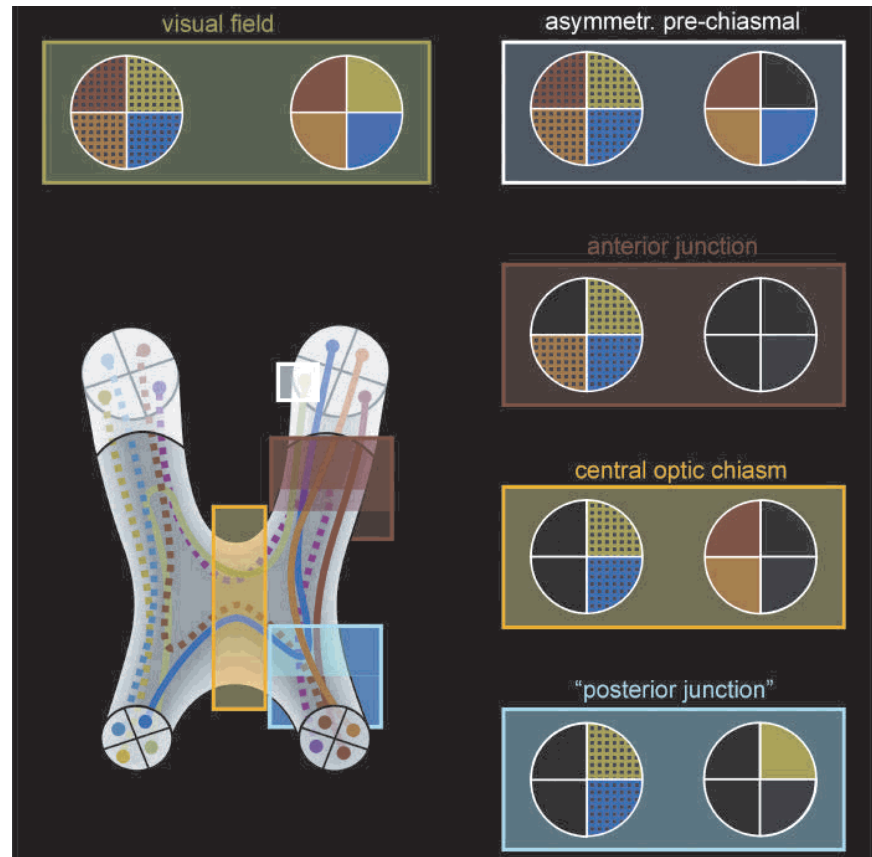
capacity is completely deficient, leading to a sliding of the intact hemifields along the vertical meridian and a merging (joining) or separation of the hemifields along the horizontal meridian, respectively.

A pituitary adenoma is the most frequent cause of chiasmal lesions. One has to keep in mind that the optic chiasm is located about 10 mm above the sellar diaphragm. This means that in a case of a manifest visual field defect, an advanced tumour within that region is to be expected, and immediate neuroimaging and further diagnostics are mandatory.

### Lesions of the optic tract

Postchiasmal lesions of the visual pathways are characterized by homonymous visual field defects. Affections of the optic tract are comparatively rare (approximately

**Fig. 4** Perimetric topodiagnosis in chiasmatal lesions



4% of all cases). This is most probably due to a reasonable blood supply and collateralization of this comparatively short section of the visual pathways, which additionally is situated in a cerebral region that does not seem to be very susceptible to lesions [4]. Since the neuronal course within this directly postchiasmatal region is still not very well-ordered, the resulting homonymous visual field defects are usually quite incongruent. In most cases, there is a relative afferent pupillary defect (RAPD) on the side of the temporal visual field defect, i. e. contralateral to the affected cerebral hemisphere. Lesions of the optic tract result in a bilateral, asymmetric partial optic atrophy. This is due to the fact that the optic tract is part of the third neuron of the visual pathways, which starts from the retinal ganglion cells. This ascending optic atrophy becomes ophthalmoscopically manifest several weeks or even months after the optic tract lesion. Classically, the eye with the RAPD, which is also characterized by the temporal visual field defect, shows as a bowtie optic atrophy. This is often enhanced by comparing the partially atrophic nasal part of this optic disc with the comparatively unaffected nasal counterpart of the fellow eye [1].

#### ■ Lateral geniculate nucleus

Isolated lesions within this region are also comparatively rare. Homonymous scotomata are still somewhat incongruent and characterized by wedge-like visual field defects, with their tips aiming towards the visual field centres.

#### ■ Lesions of the post-geniculate visual pathways

Pathologies of the fourth neuron of the visual pathway are also characterized by homonymous visual field defects. Since – at least in adults – transsynaptic degeneration does not occur, there is no ophthalmoscopically evident optic atrophy in these cases. Vascular lesions are the most frequent cause (75%). This holds especially true in the occipital pole due to a somewhat minor supply by collateral vessels [2,4]. Visual field defects due to post-geniculate lesions are usually absolute. The more the location of the lesion approaches the visual cortex, the more congruent the homonymous scotomata are. This is caused by the exact alignment of neuronal fibres diverging into the occipital cortex and allows a high topodiagnostic precision even in case of minute visual field defects.

Lesions of the *inferior* visual pathways (→ *temporal*



lobe) result in a *superior* contralateral homonymous quadrantanopia and vice versa: lesions of the *superior* post-geniculate visual pathways ( $\rightarrow$  *parietal lobe*), which are comparatively rare, induce an *inferior* contralateral homonymous quadrantanopia.

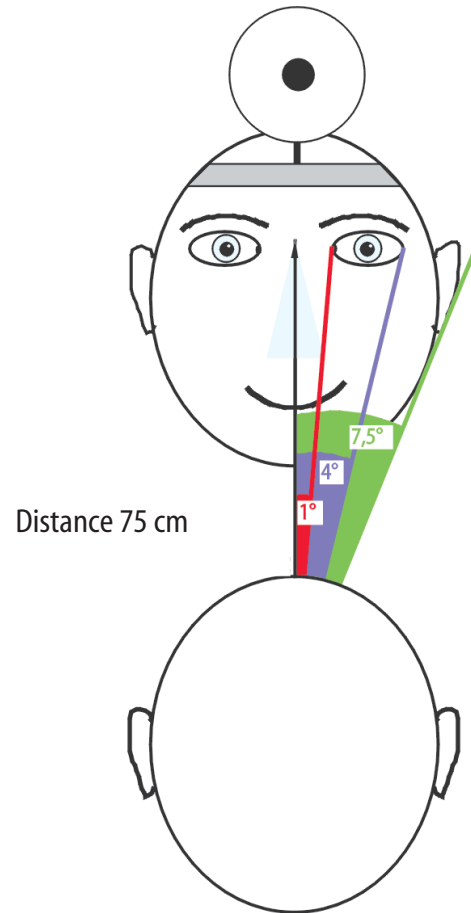
A lesion of the occipito-parieto-temporal region will additionally cause an asymmetry of the optokinetic nystagmus (OKN): OKN is particularly impaired for target movement towards the affected cerebral hemisphere.

*Bilateral infarctions* may result in quite complex, bilateral homonymous scotomata, e.g. checkerboard or “propeller-like” defects; this is due to lesions within the superior visual pathways of the one brain hemisphere and additionally inferior sections of the contralateral part of the brain [5]. If the bilateral lesions are located both within superior and inferior regions of the brain, the resulting scotoma will look like bilateral altitudinal visual field defects. In these postgeniculate cases there is no fundoscopic abnormality; this is an essential differential-diagnostic criterion towards retinal nerve fibre layer defects (see also Fig. 3), which characteristically show accompanying pathologies of the retina and/or the optic disc.

Manifestation of *macular splitting* or *macular sparing* depends mainly on whether the occipital pole is directly affected by the lesion or not. A complete “macular splitting” – i. e. a homonymous visual field defect, which exactly “cuts” the centre in both visual fields, will induce a severe impairment of reading performance. For normal reading, an intact central visual field is essential, which should cover at least  $2^\circ$  towards the left and right hemifield, as well as a minimum of  $1^\circ$  towards the superior and inferior paracentral region. A bedside test quantifying the extent of macular sparing is shown in Fig. 5.

In some patients, (homonymous) visual field defects can be found, which are comparatively small in the case of moving targets ( $\rightarrow$  kinetic perimetry) but much more advanced in the case of static targets ( $\rightarrow$  e.g. automated static grid perimetry). However, this so-called Riddoch phenomenon of *stato-kinetic dissociation* does not have major topodiagnostic or prognostic importance.

Visual agnostic impairments occur in 1–2% of all



**Fig. 5** Bedside test for quantification of macular sparing in homonymous hemianopia:

The patient is asked whether the examiner's face is completely visible while fixating the doctor's base of the nose. If the visual field defect extends towards the doctor's inner canthus, outer canthus, or ear, the macular sparing is approximately  $1^\circ$ ,  $4^\circ$ , or  $7.5^\circ$ , respectively (in a given distance of 75 cm)

posterior brain lesions, especially within the initial phase. They occur with and without visual field defects.

■ **Acknowledgement** The author thanks Miss R. Hofer and Dipl.-Ing. W. Durst for preparing the graphics. Many thanks are due to Dr. Anne Kurtenbach for carefully revising the manuscript.

## References

- Hoyt WF, Kommerell G (1973) Der Fundus oculi bei homonymer Hemianopie. *Klin Monatsbl Augenheilkd* 162: 456–464
- Kölmel HW (1988) Die homonymen Hemianopsien, Springer, Berlin Heidelberg New York
- Schiefer U, Wilhelm H (1995) Gesichtsfeld-Kompendium. *Klin Monatsbl Augenheilkd* 206:206–238
- Slamovits TL, Burde R (1994) *Neuro-ophthalmology*, Mosby, London St. Louis Baltimore Chicago Philadelphia Sydney Tokio
- Walsh TJ (1990) Visual fields. Examination and interpretation, American Academy of Ophthalmology, Palace Press, San Francisco, 1996
- Zrenner E, Wilhelm H, Schiefer U (1993) Differentialdiagnostische Strategien bei unklaren Sehstörungen. *Ophthalmologie* 90:104–119