

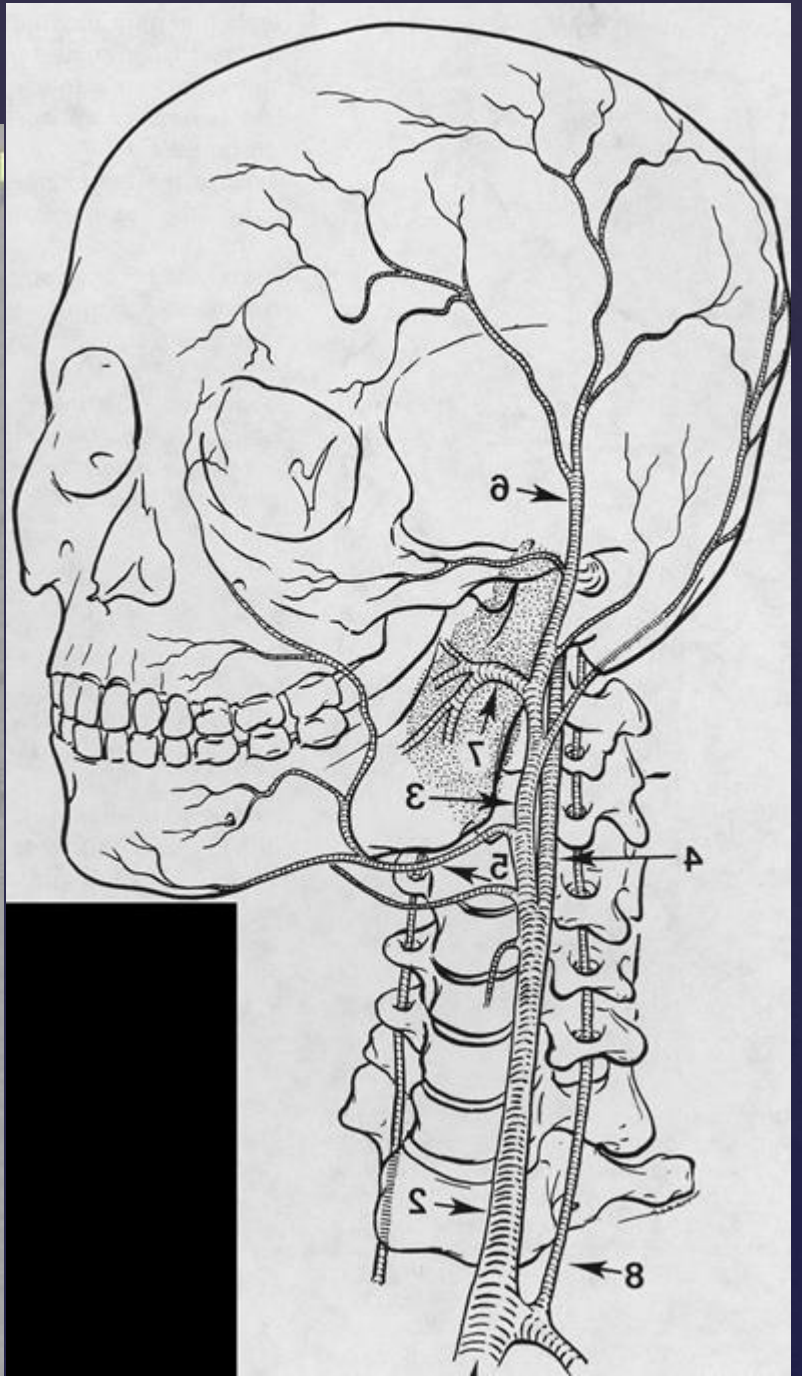
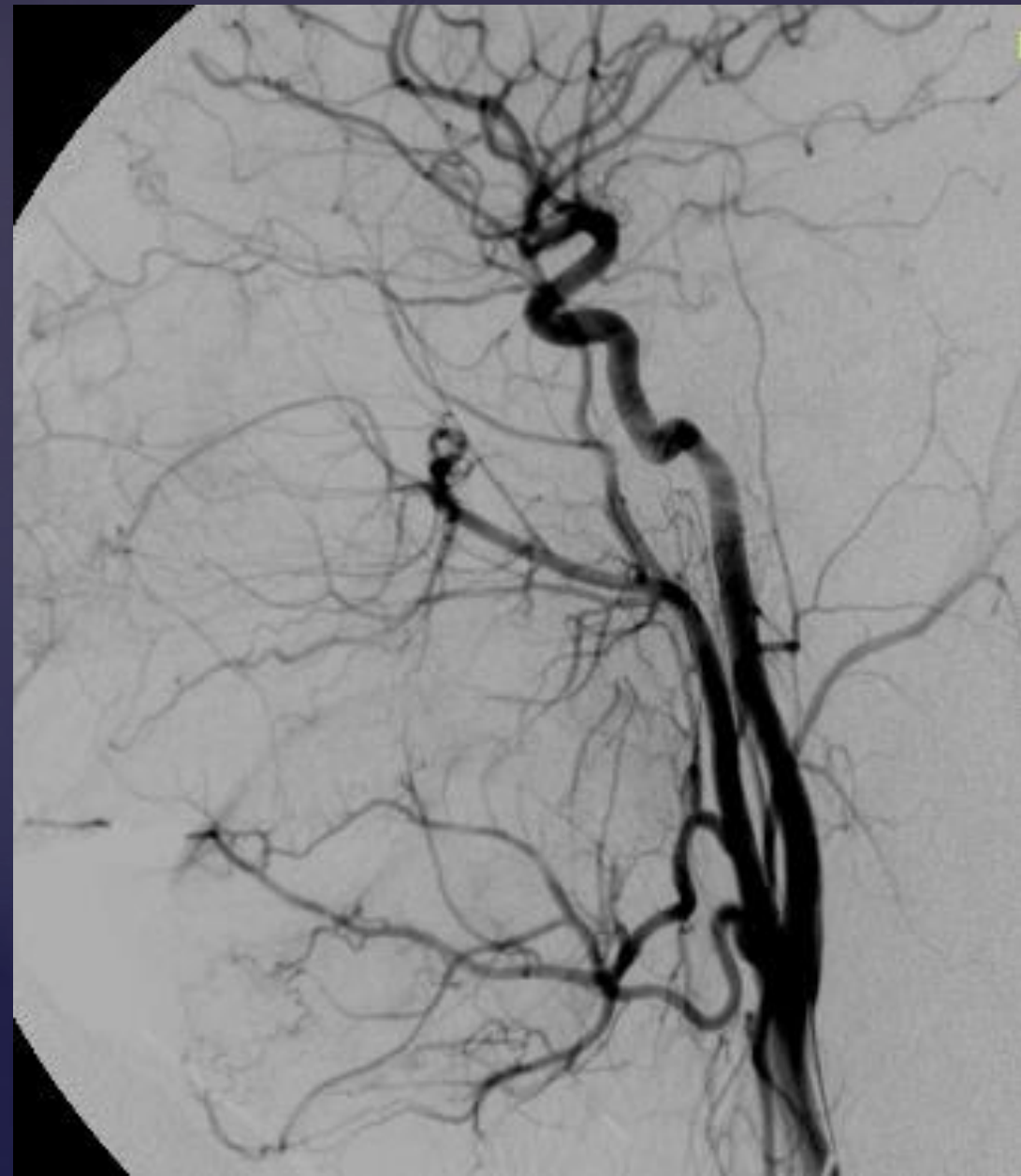
Αγγεία Κεφαλής- Τραχήλου

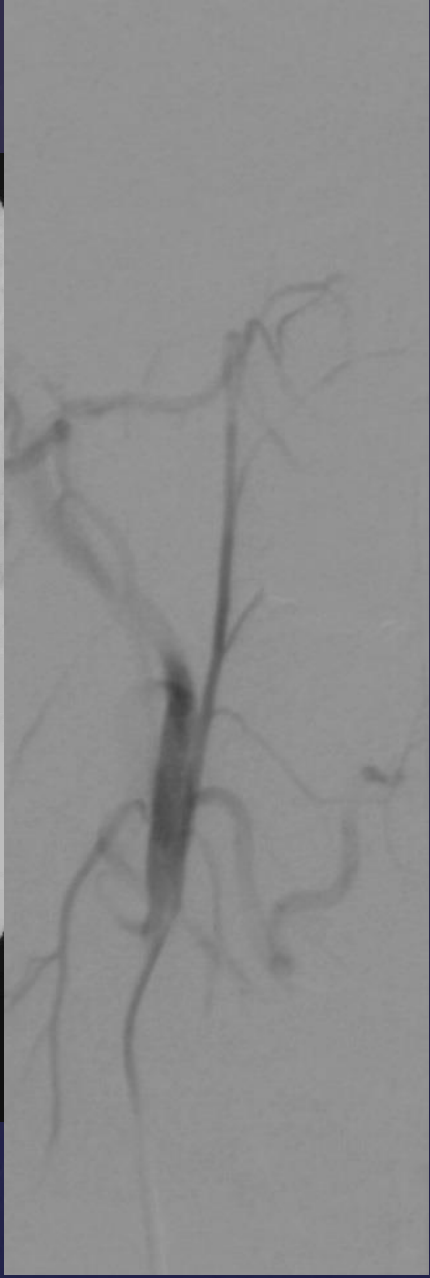
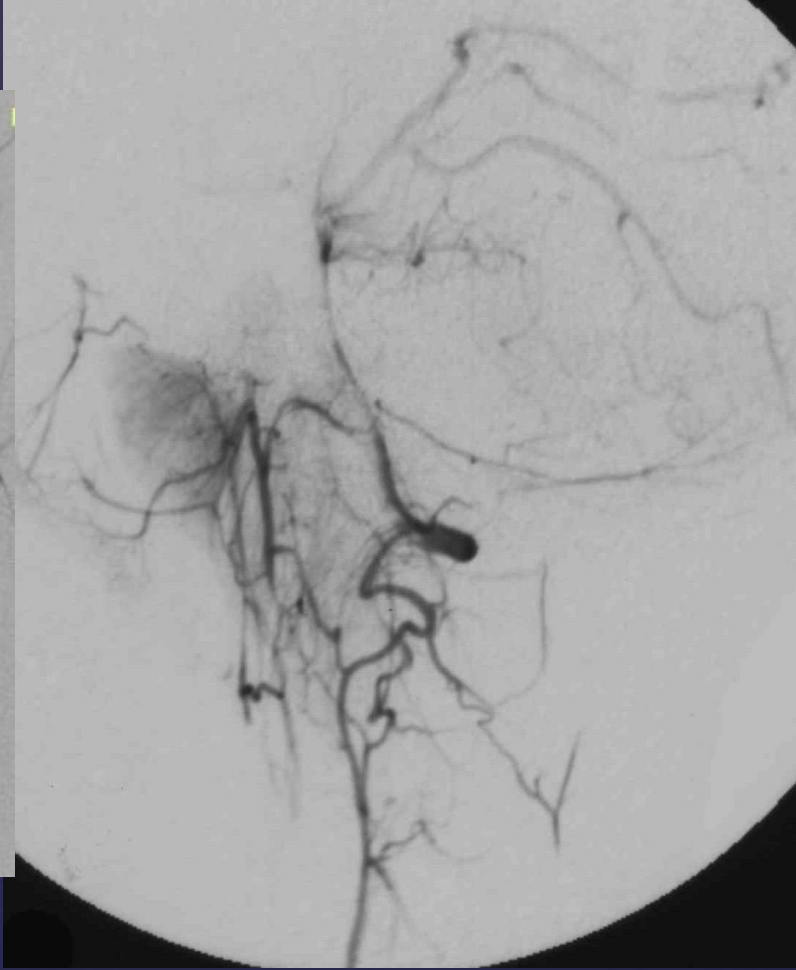
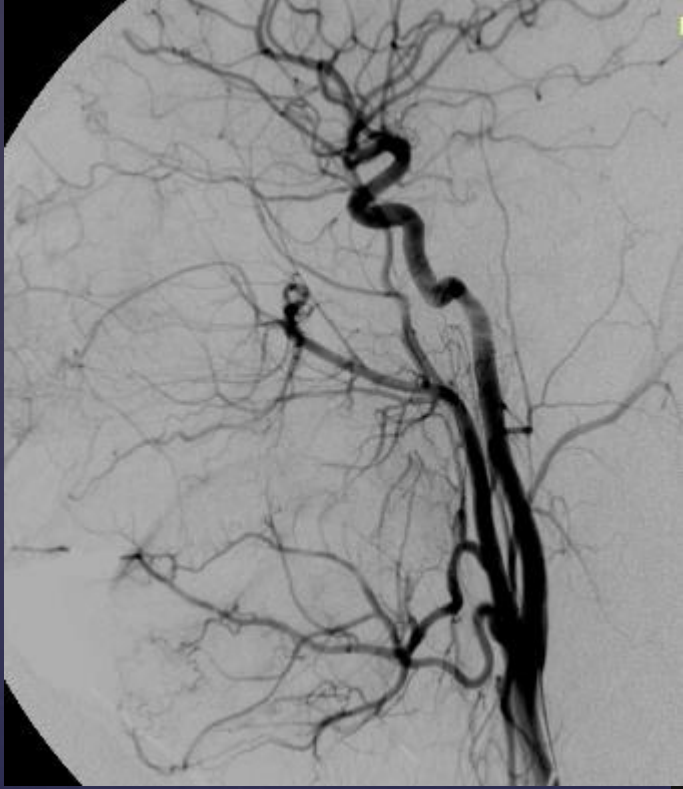
Μέρος Πρώτο

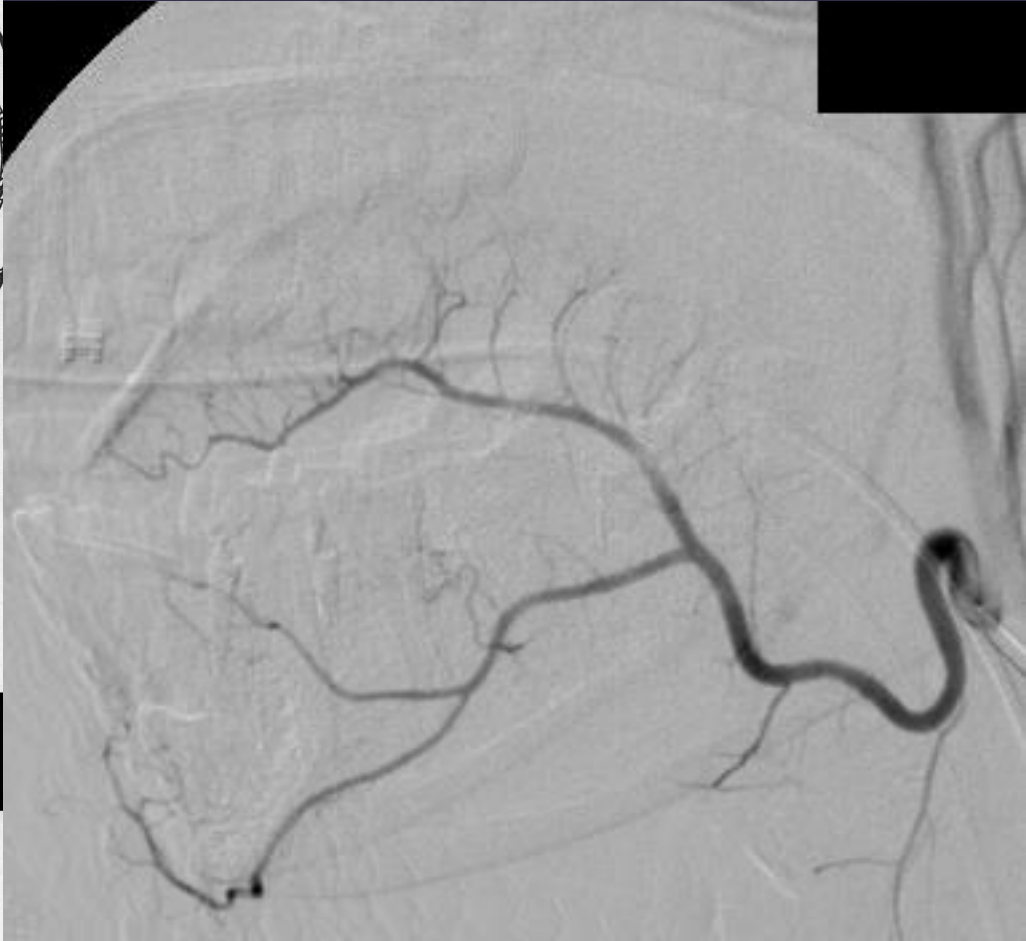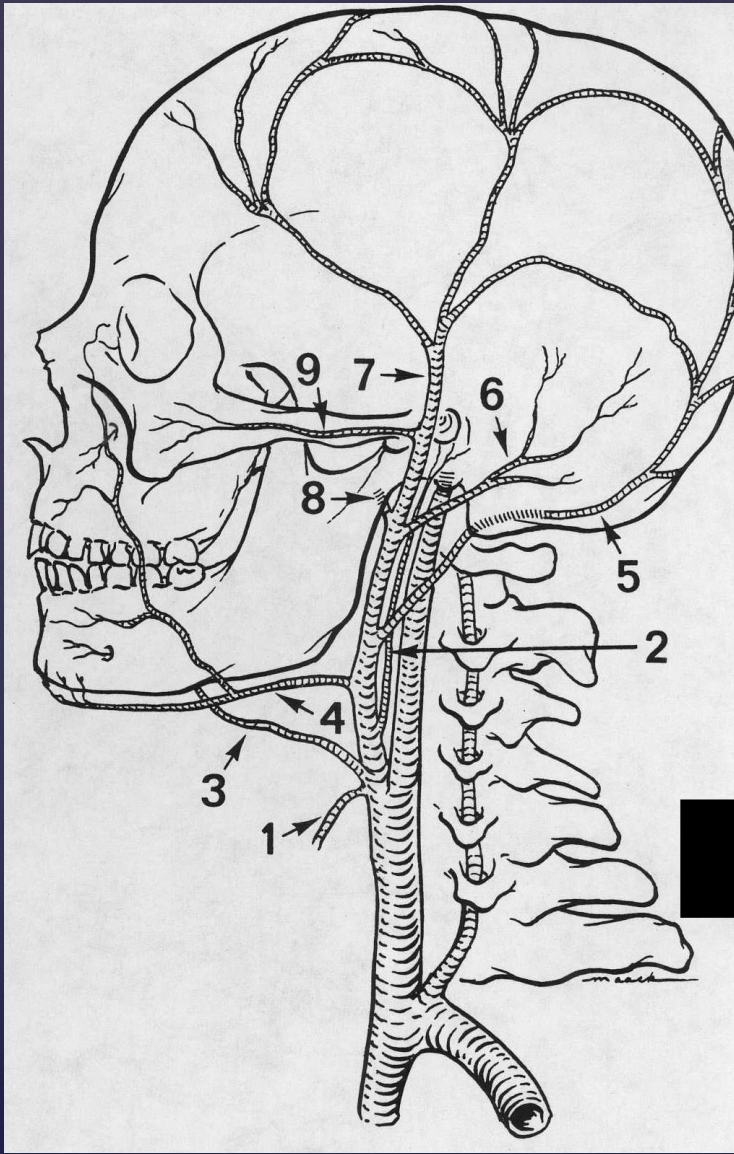
Φοινίτσης Στέφανος

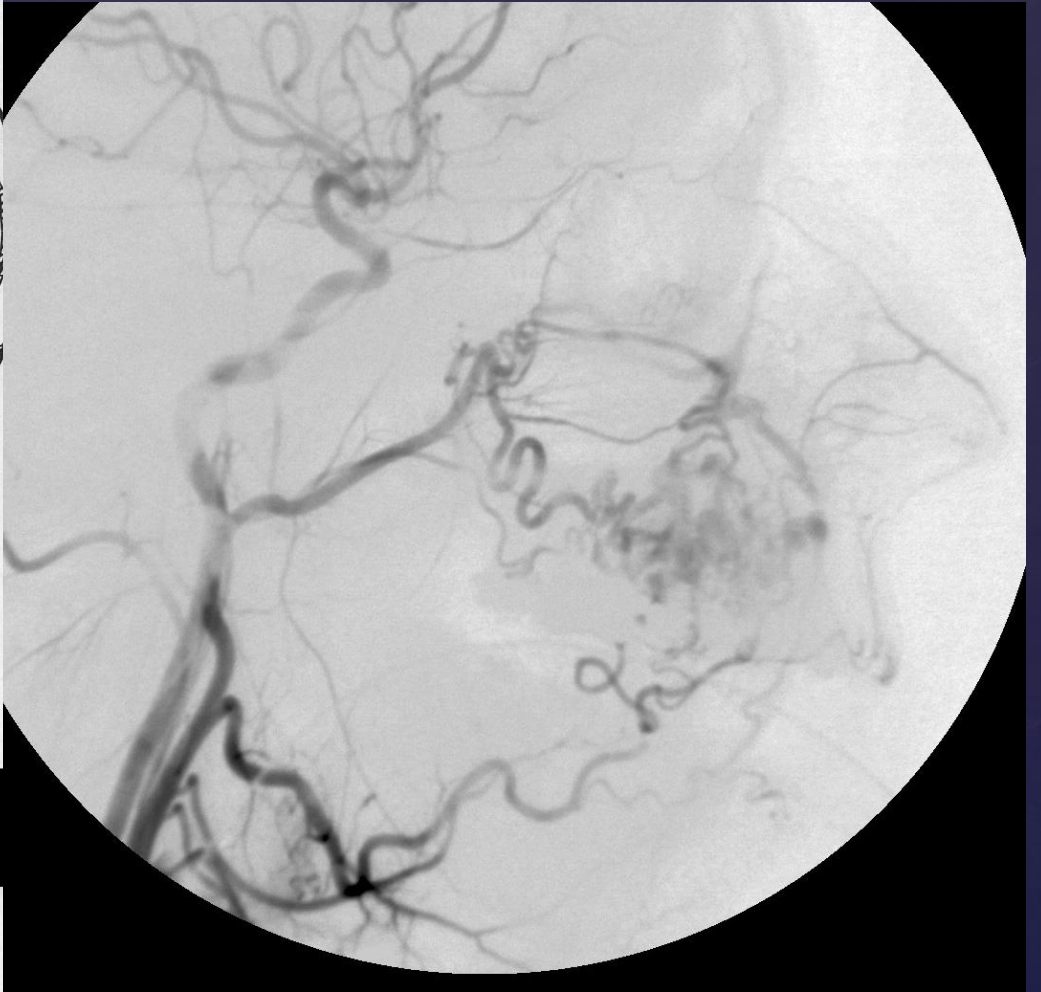
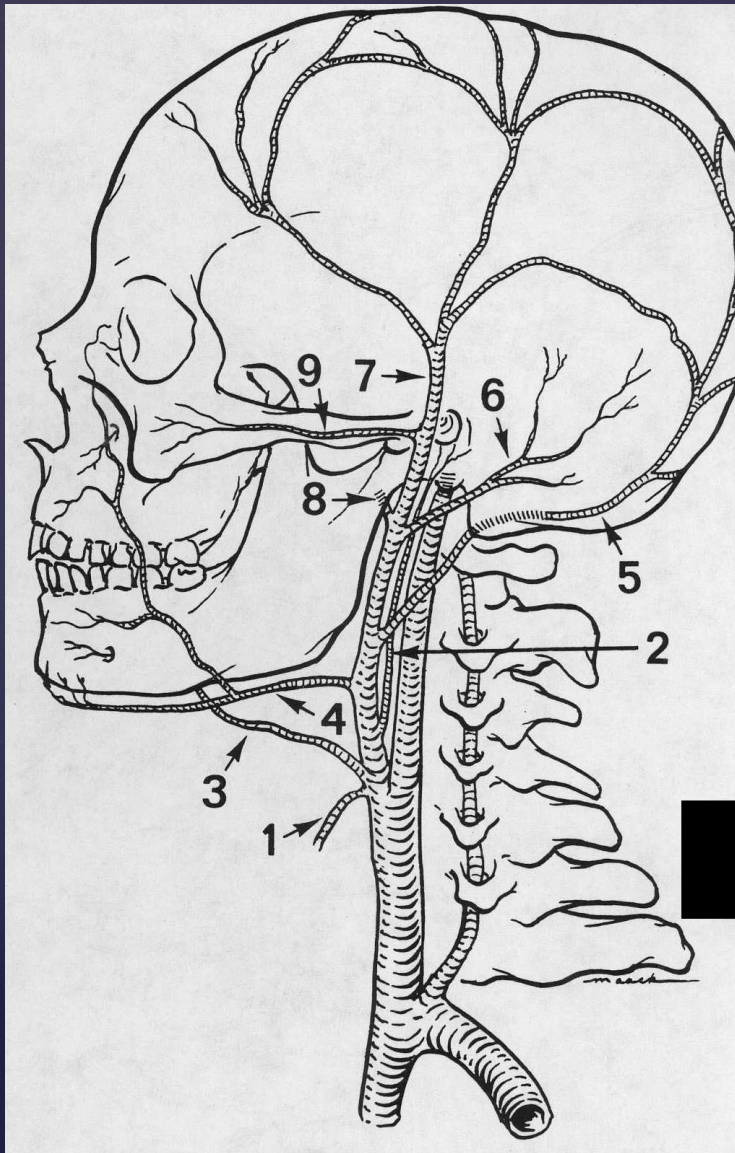
Επίκουρος Καθηγητής

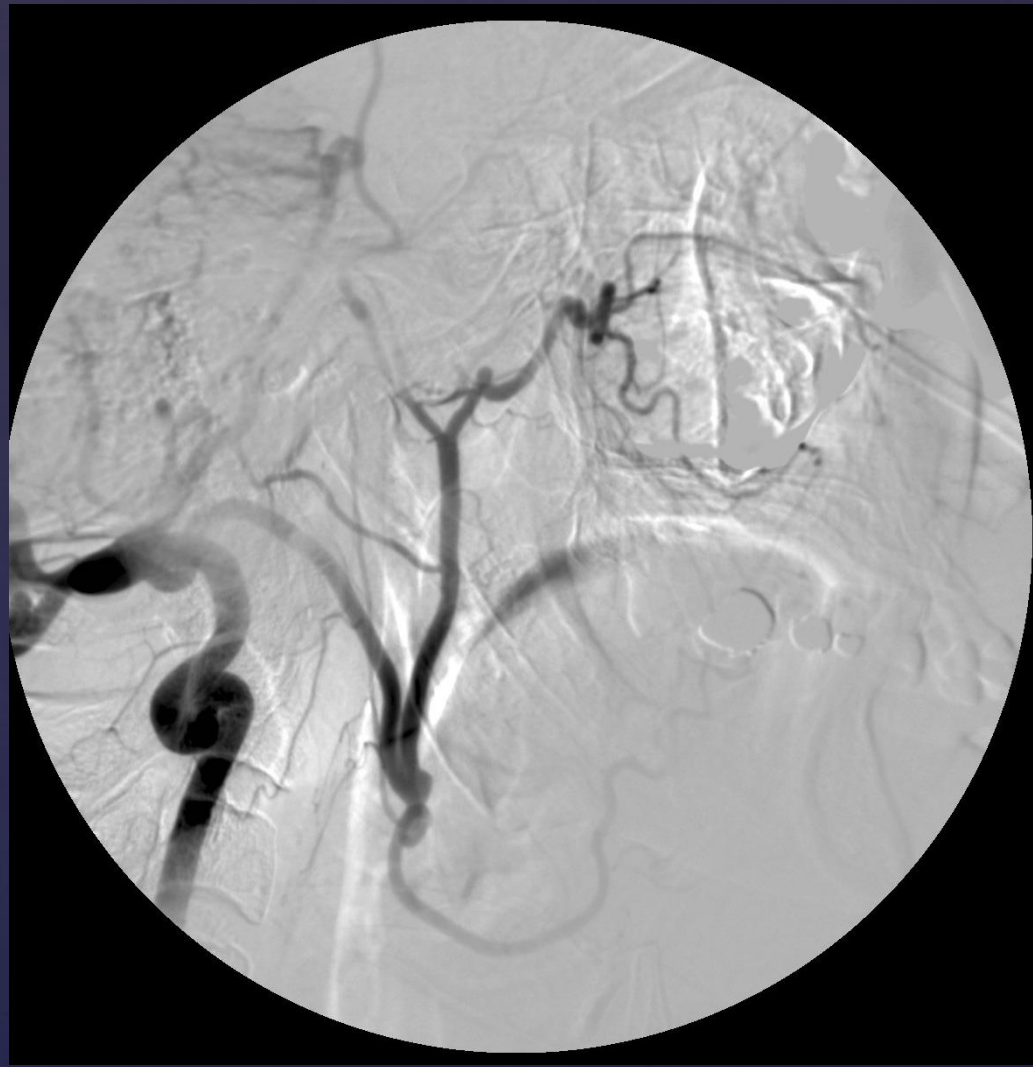
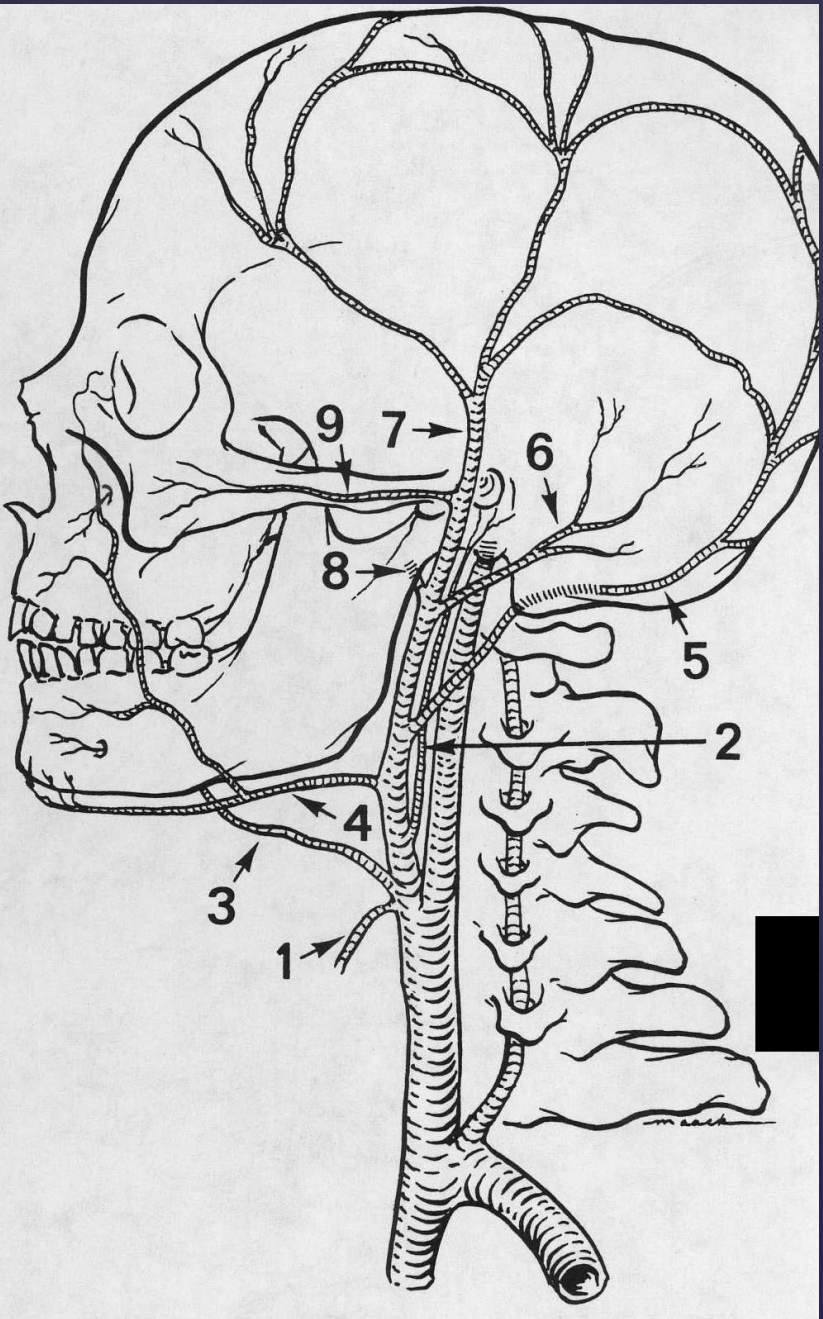
Διαγνωστικής και Επεμβατικής Νευροακτινολογίας

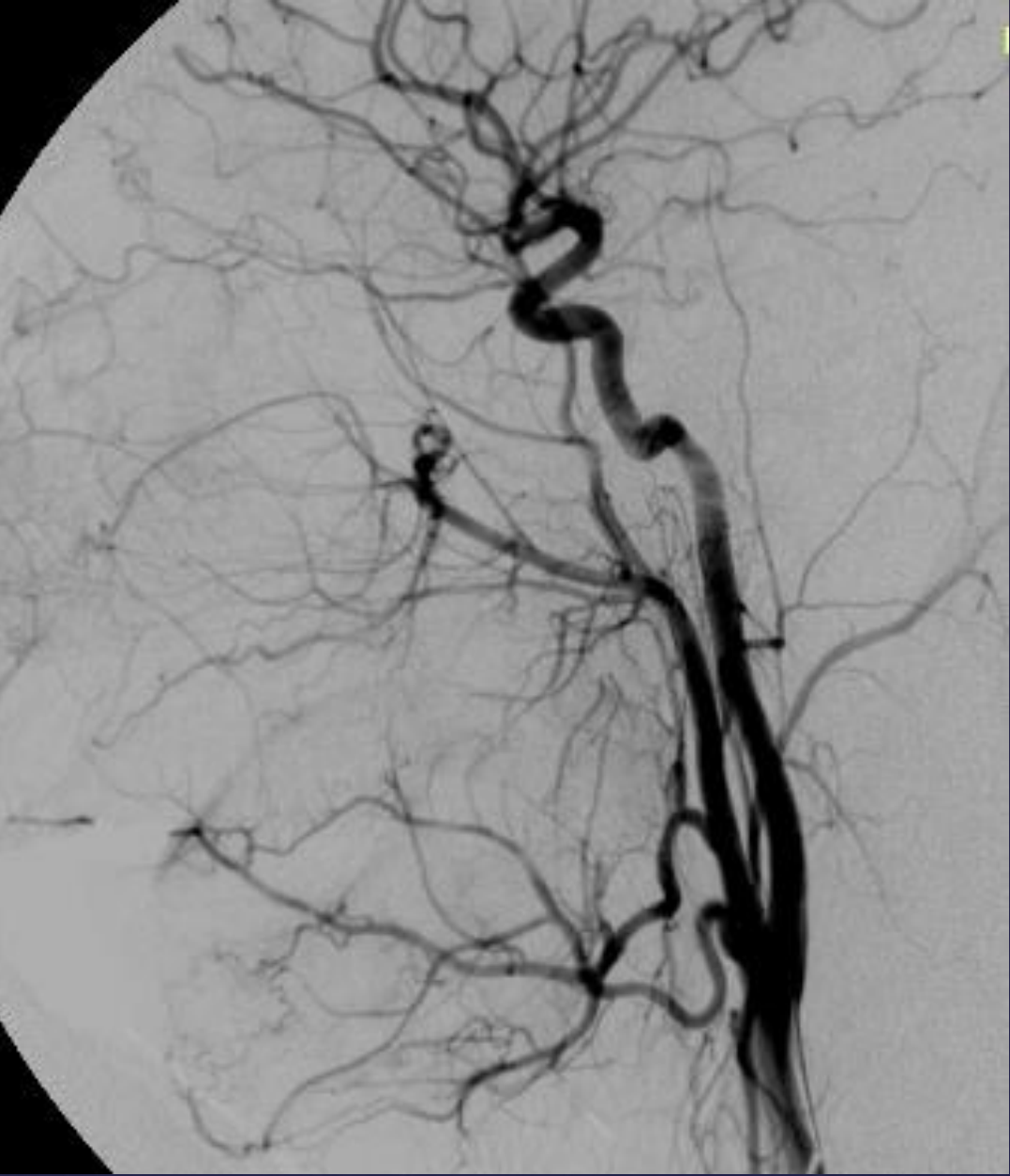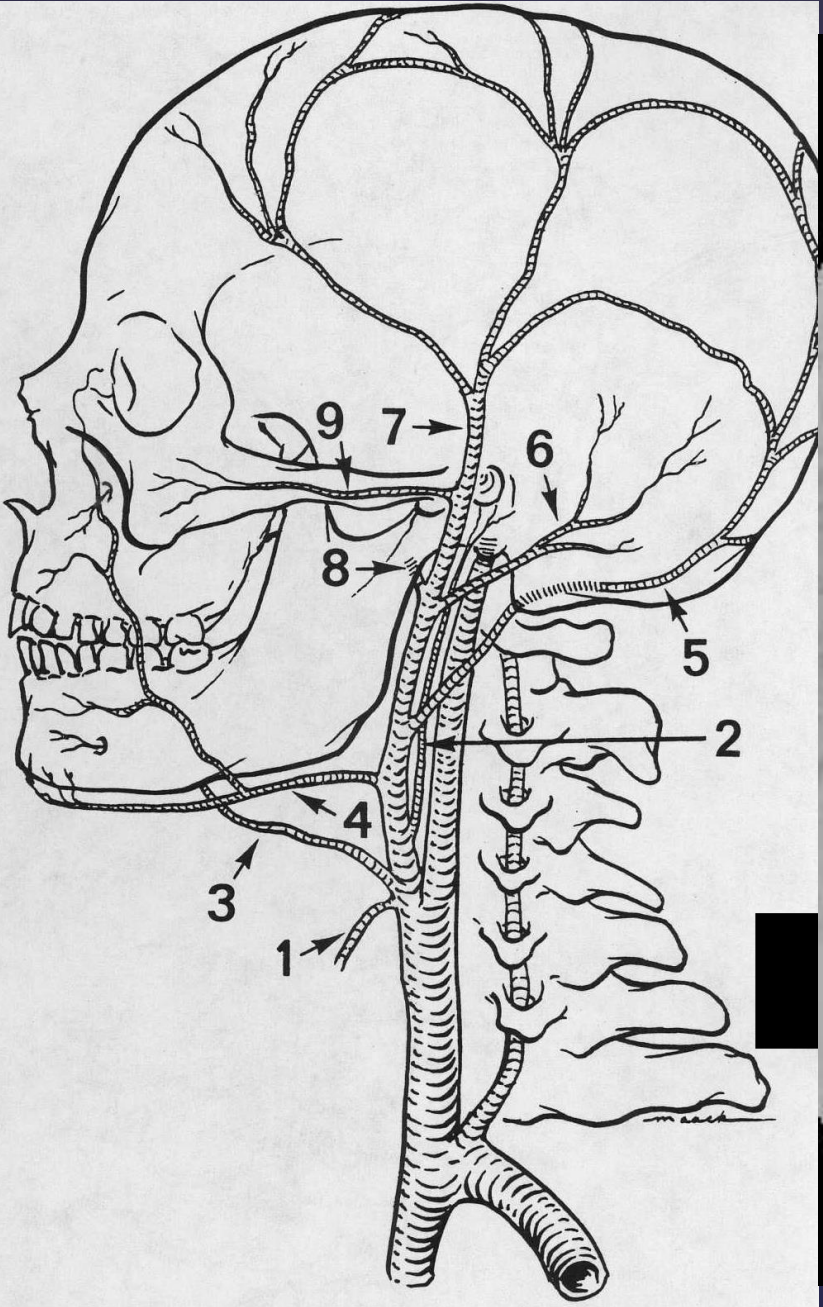


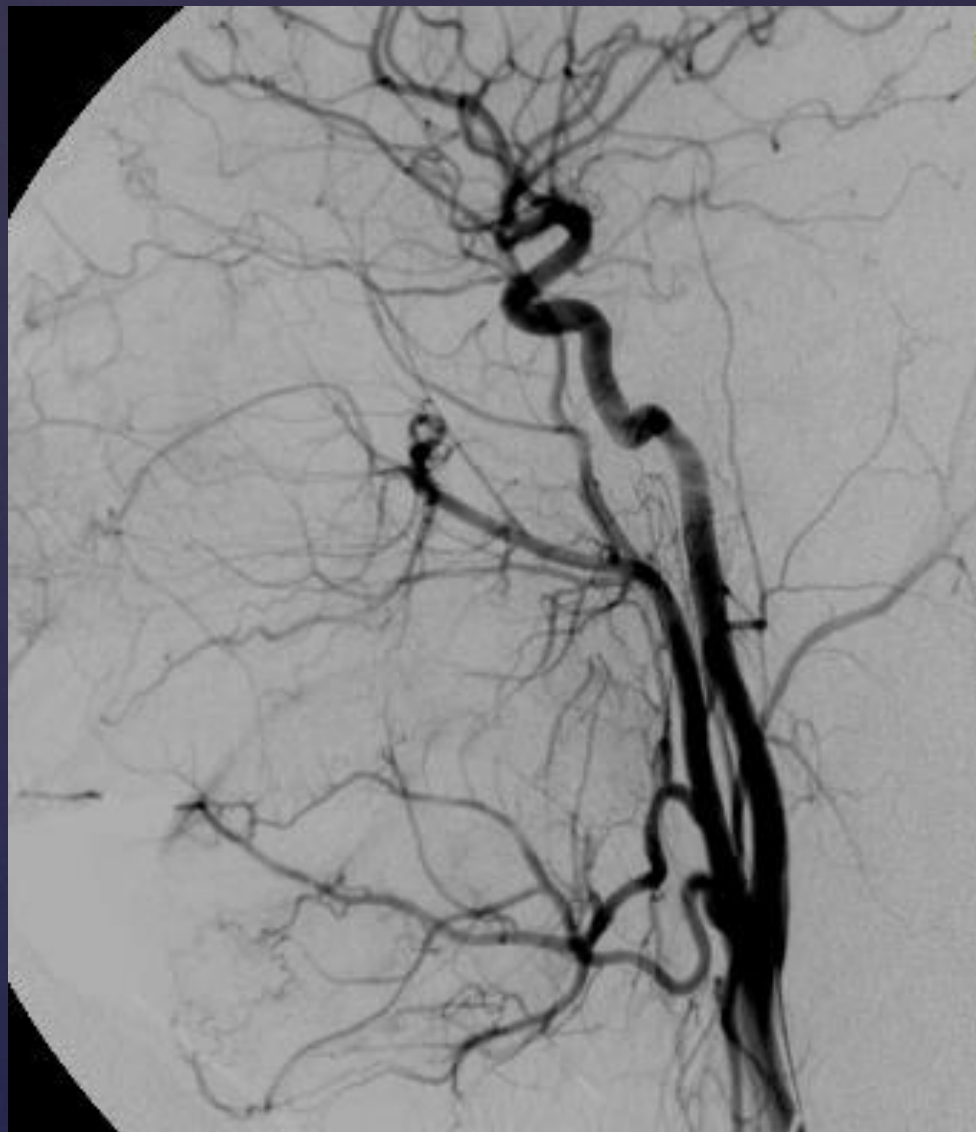
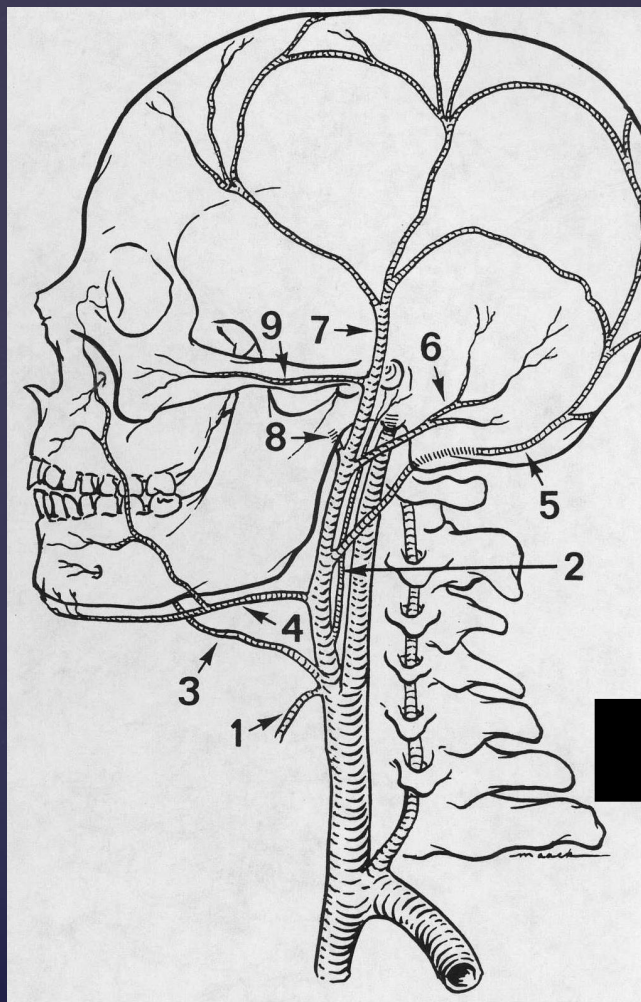


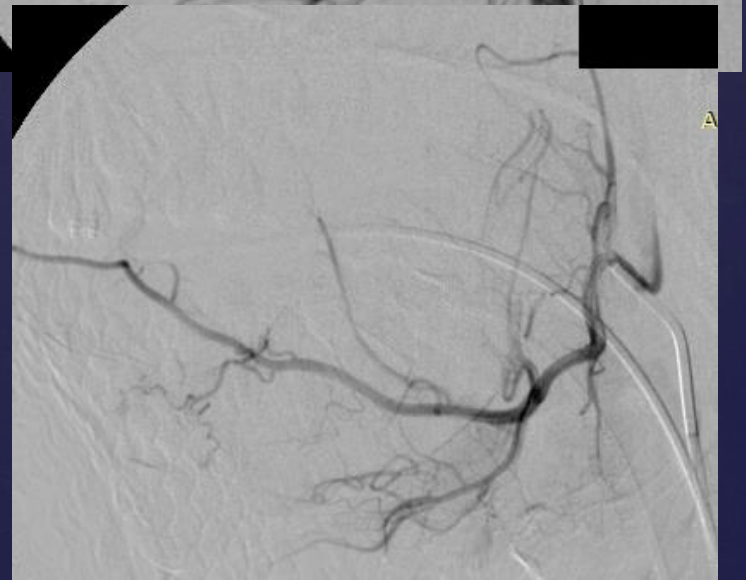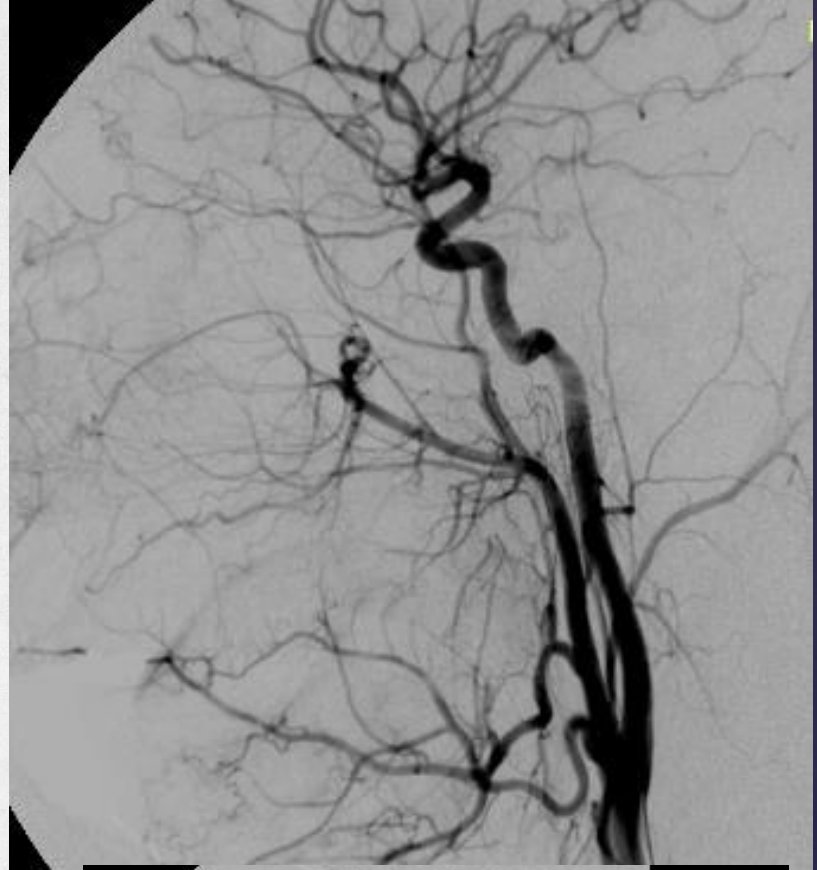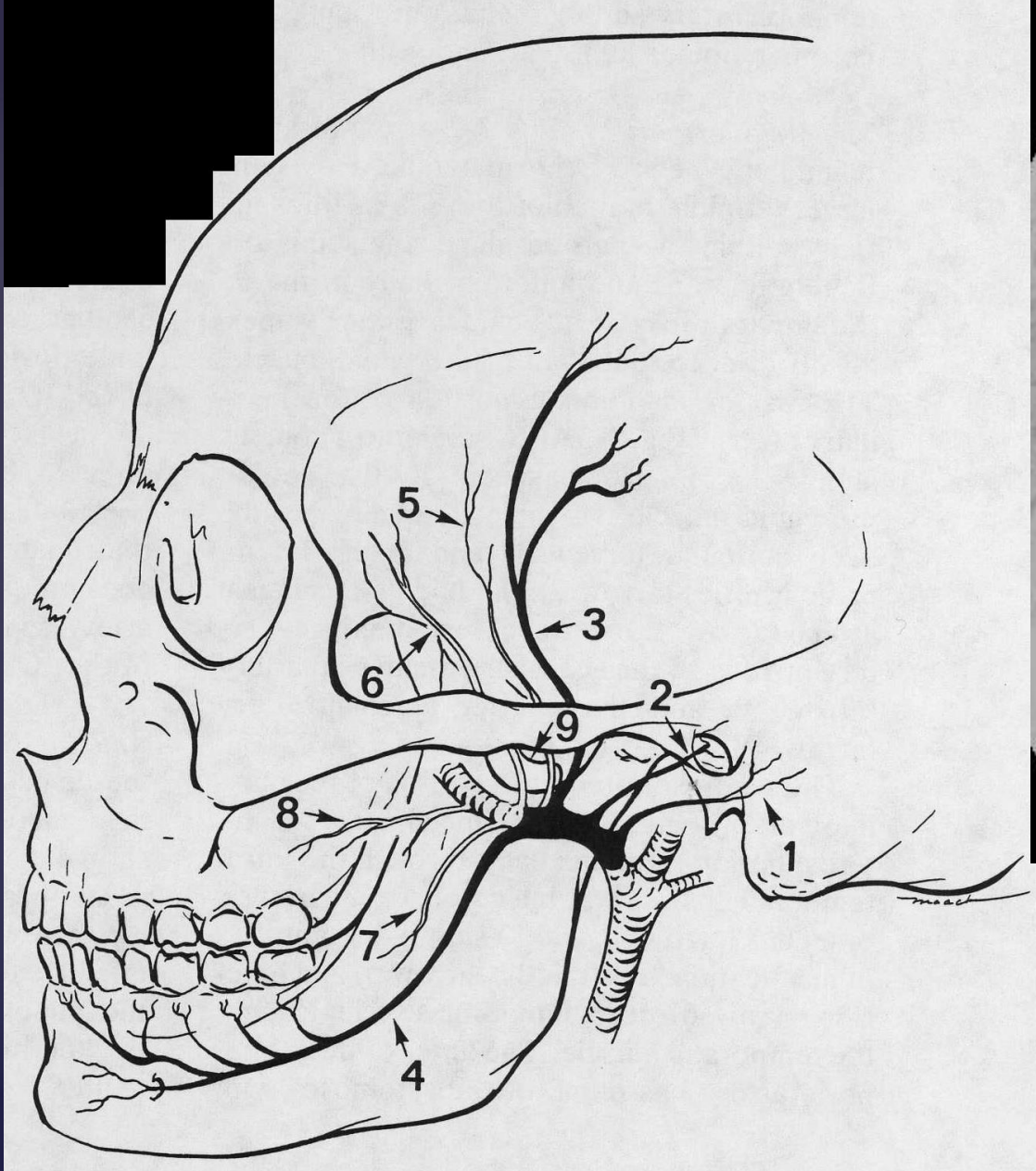


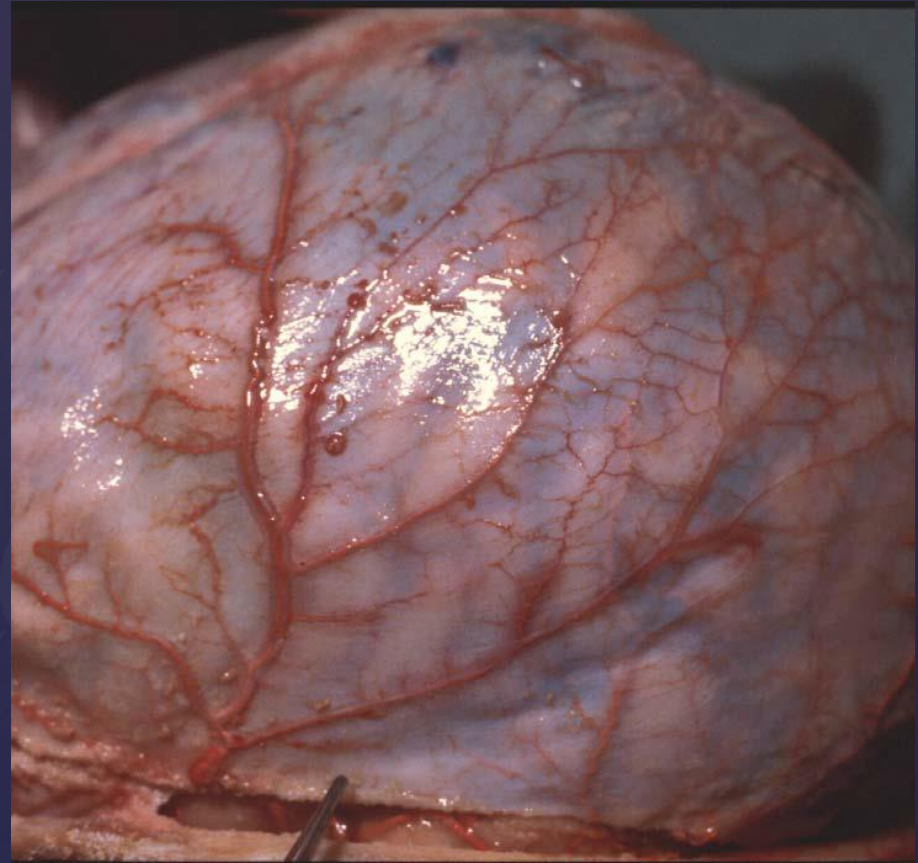
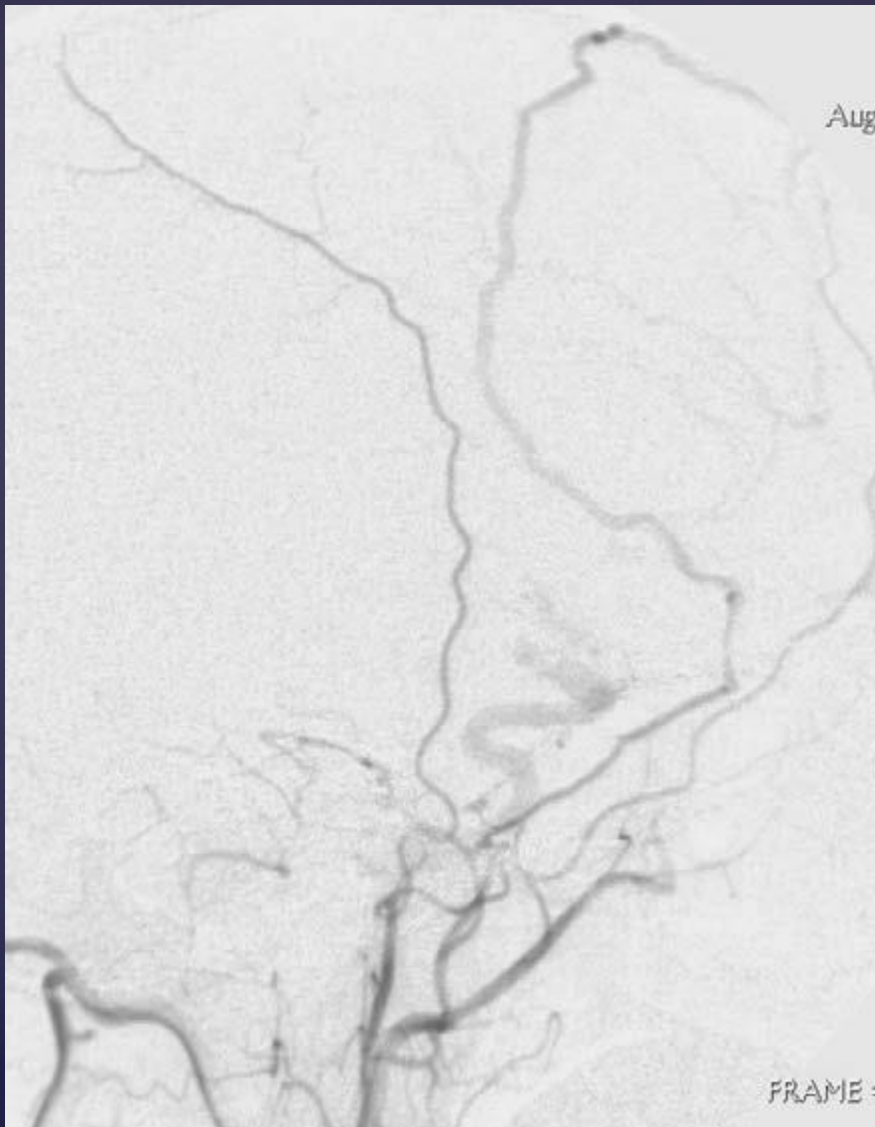


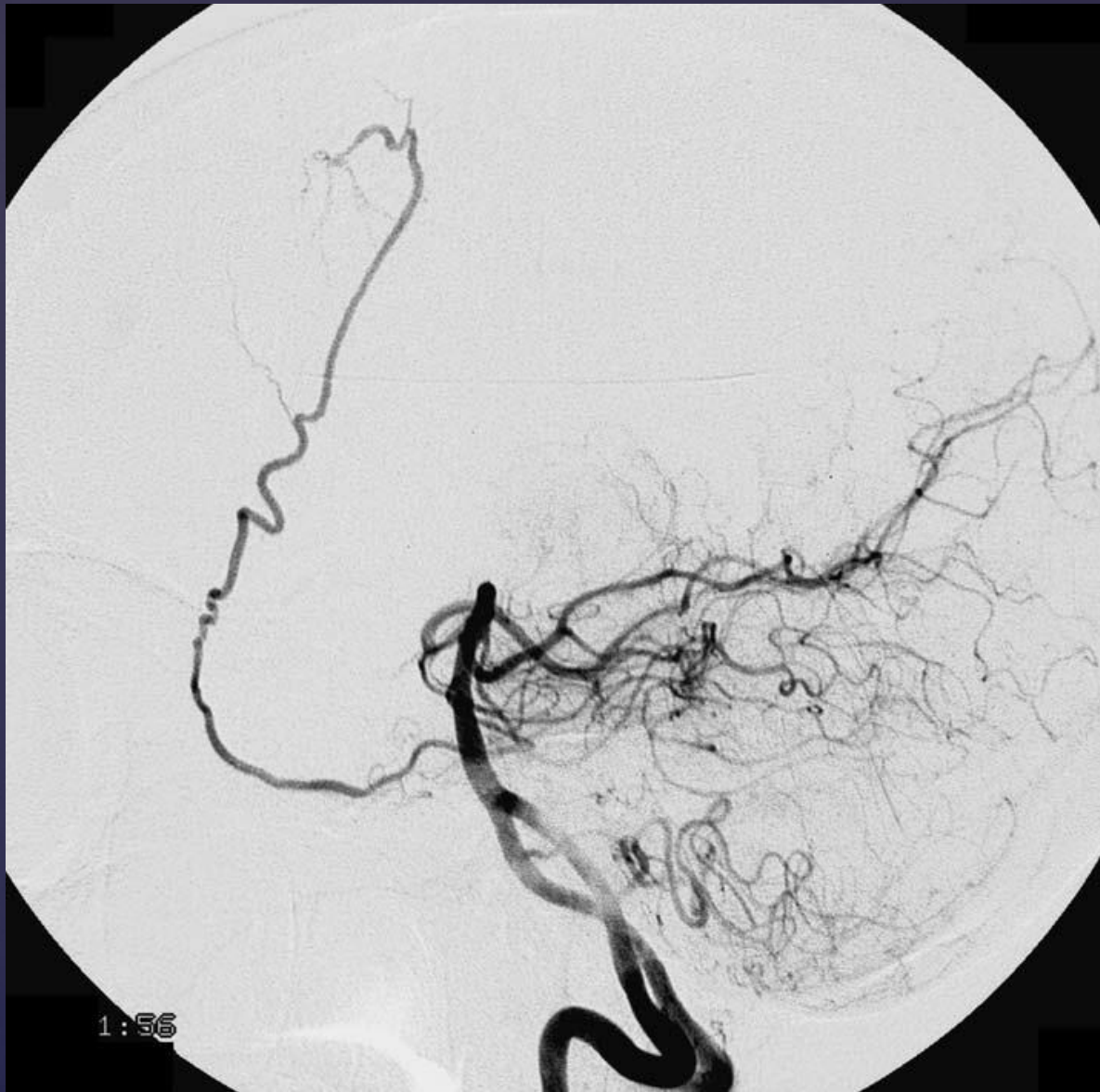


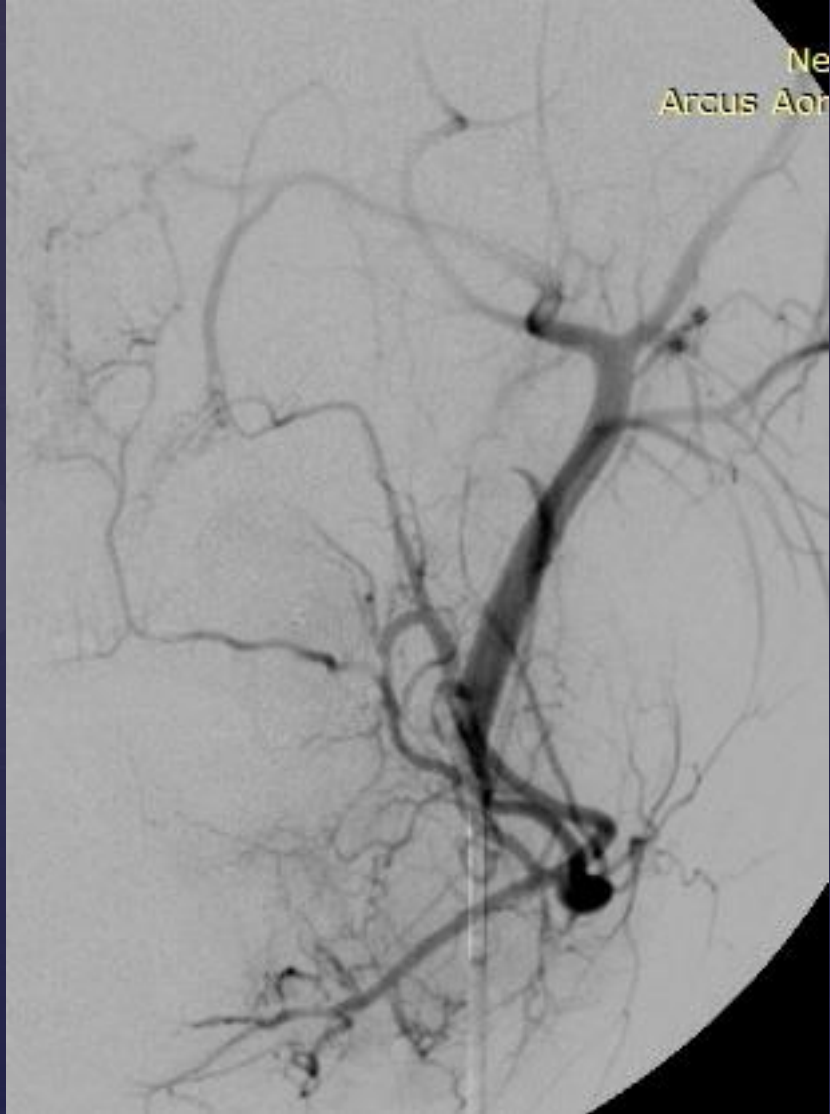
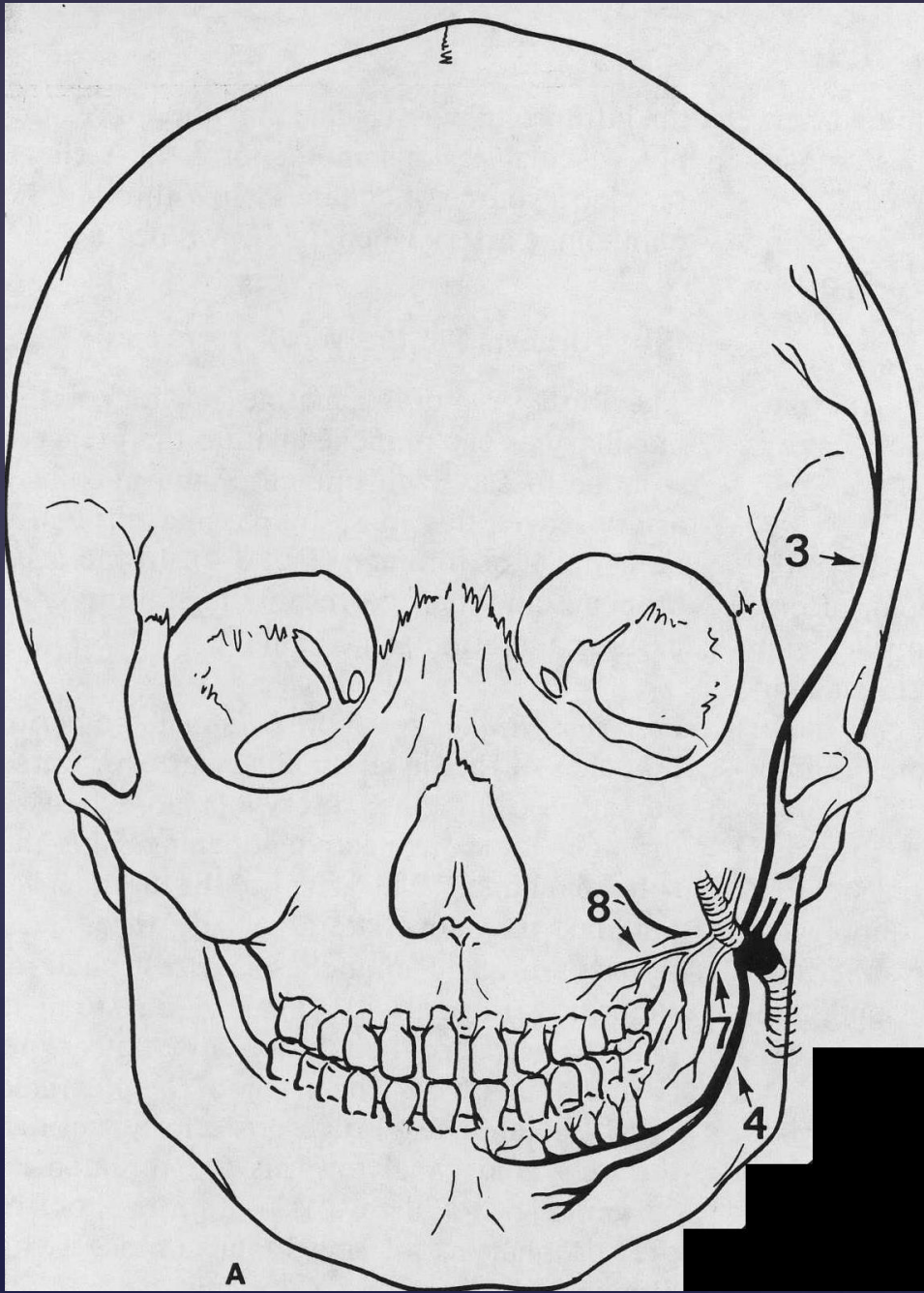


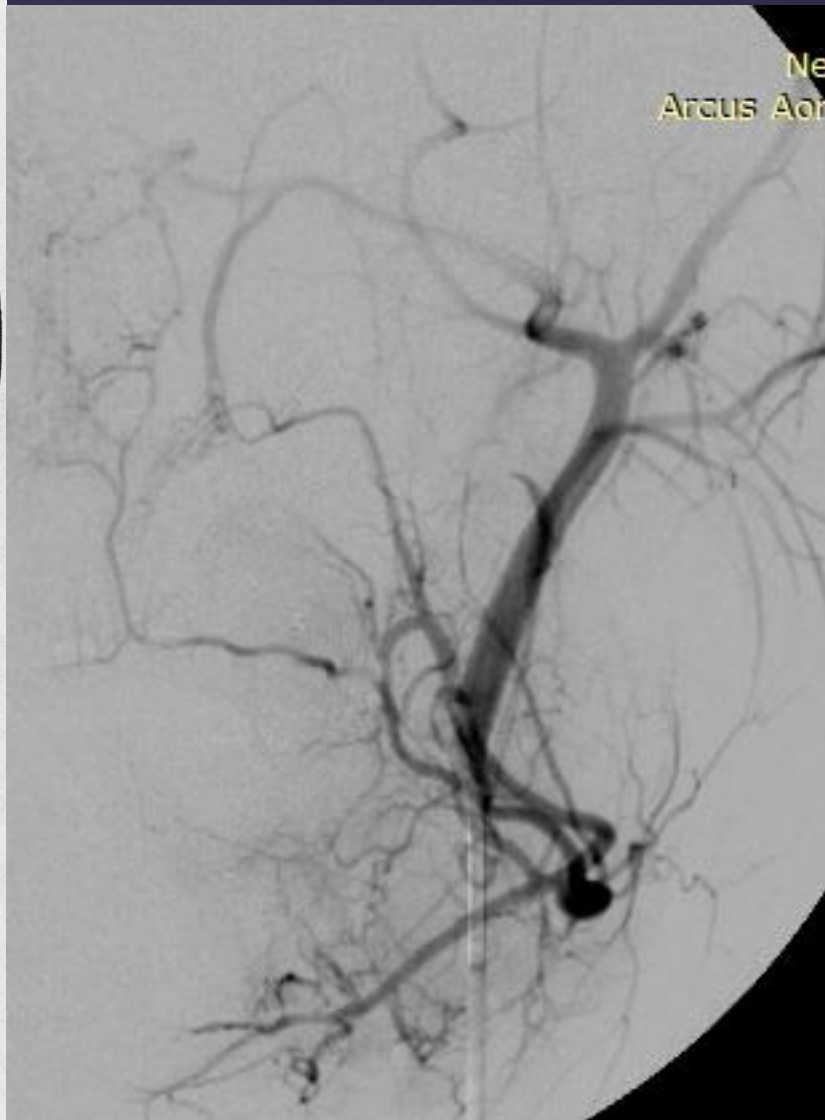
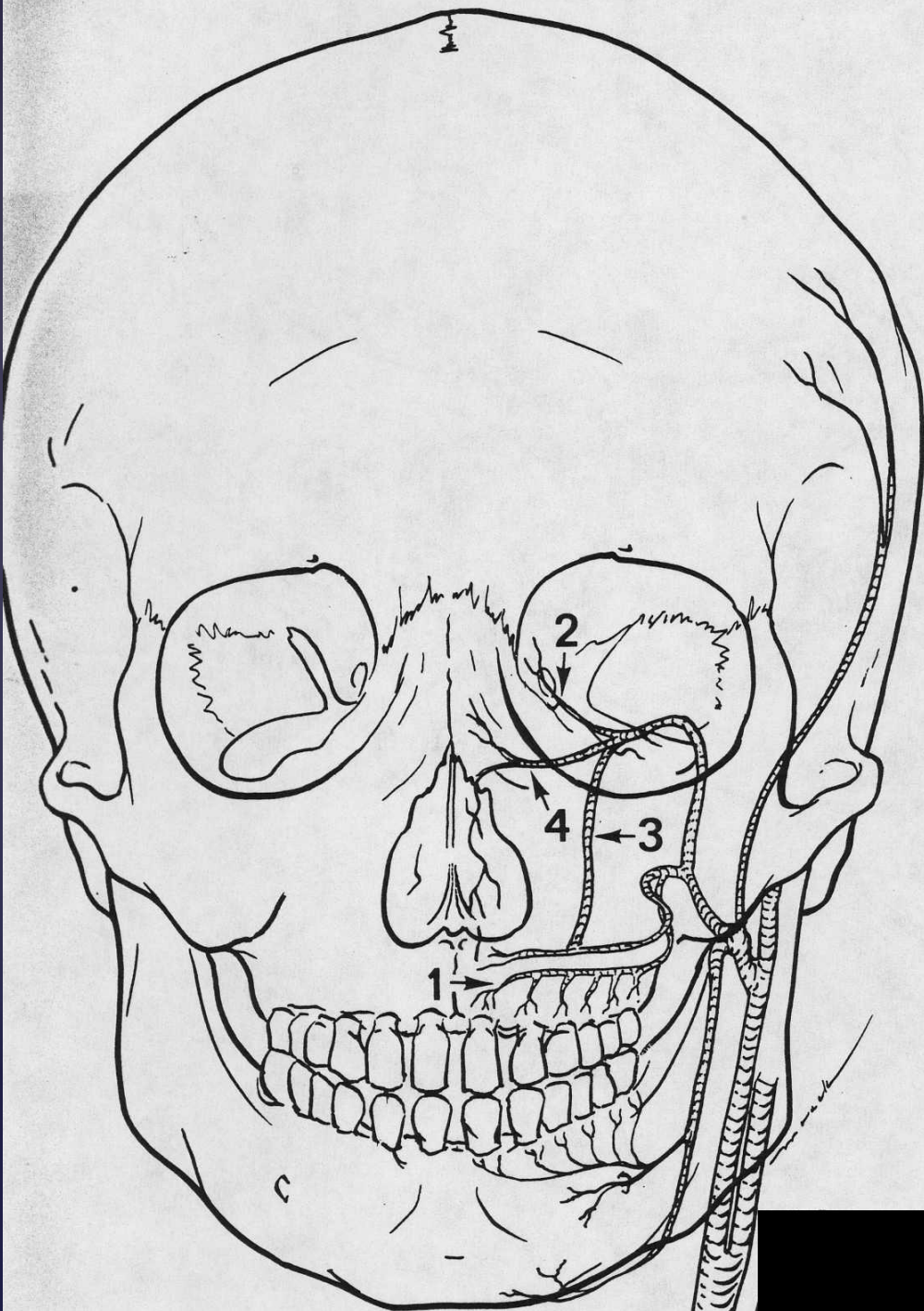


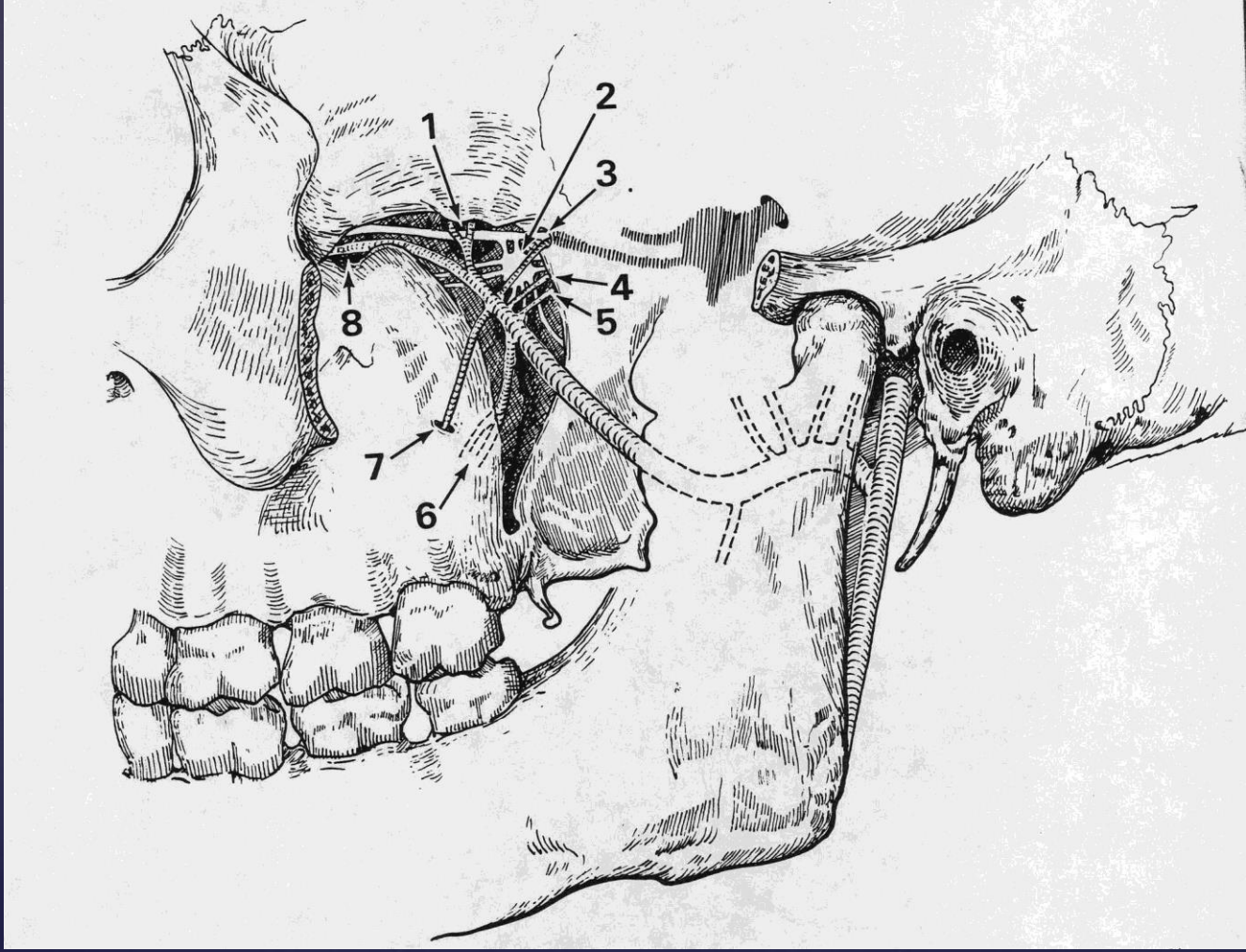


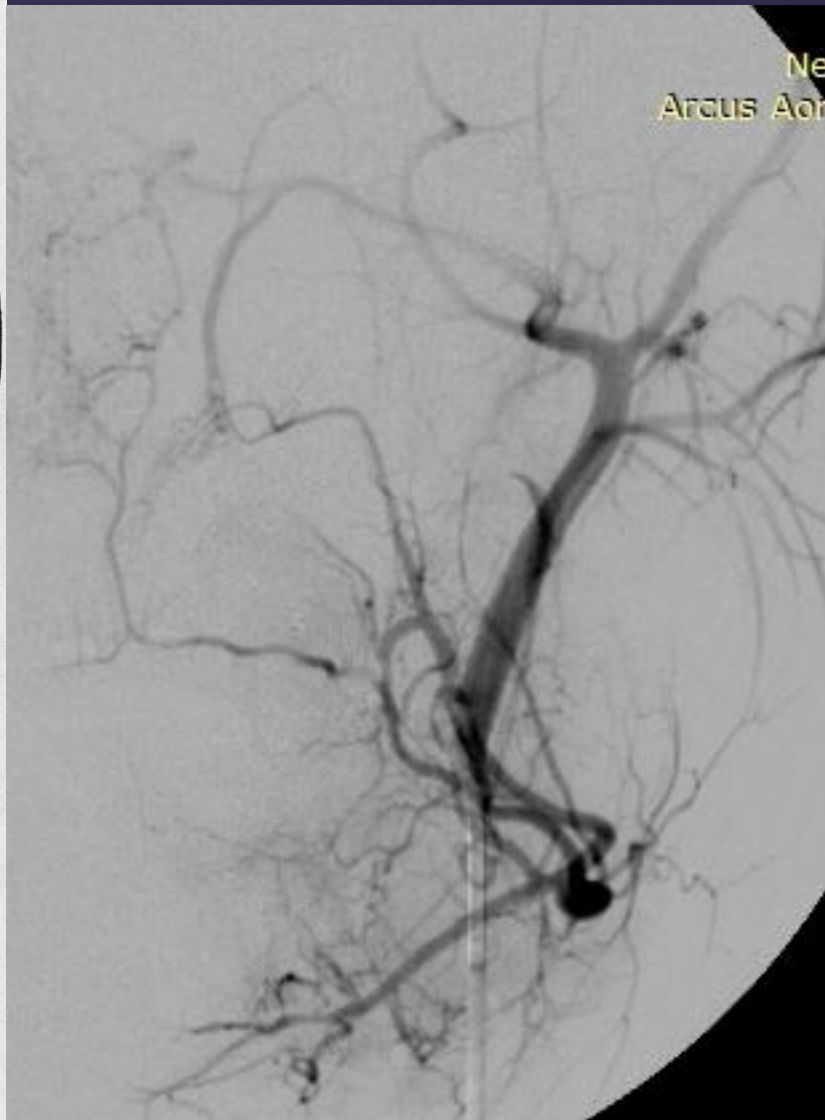
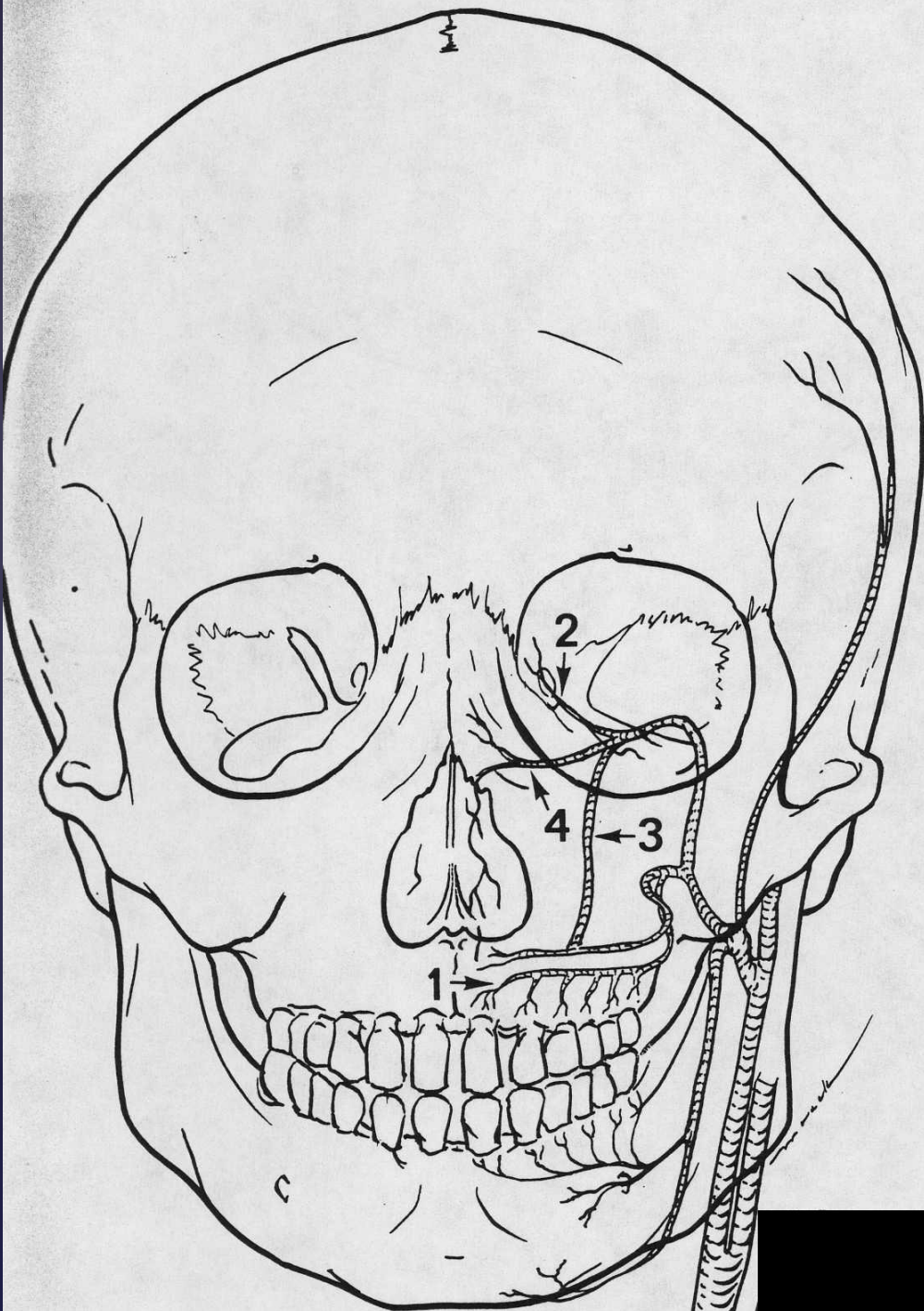


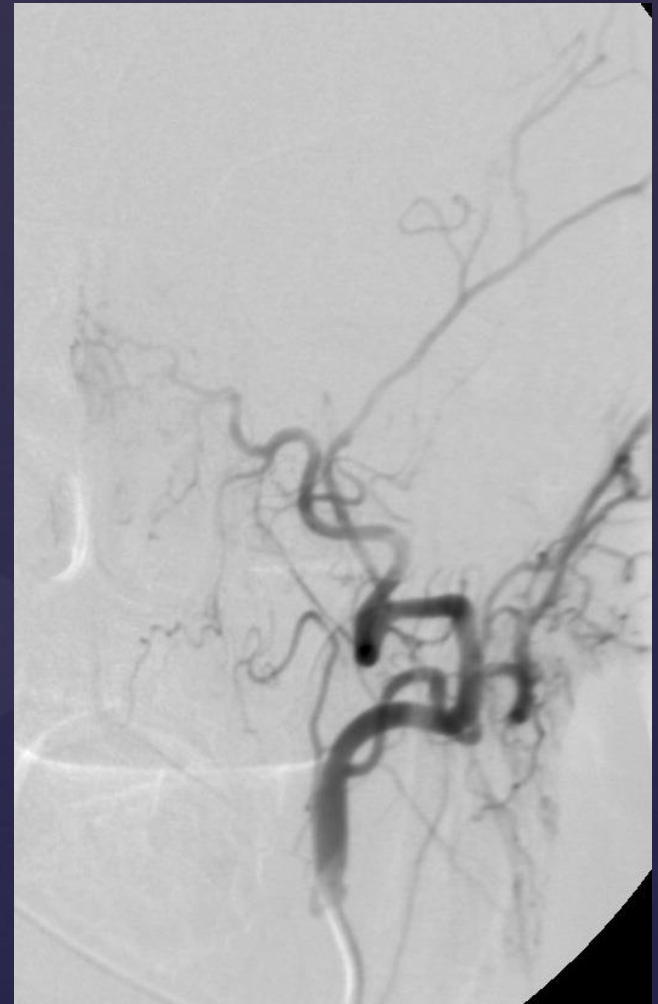
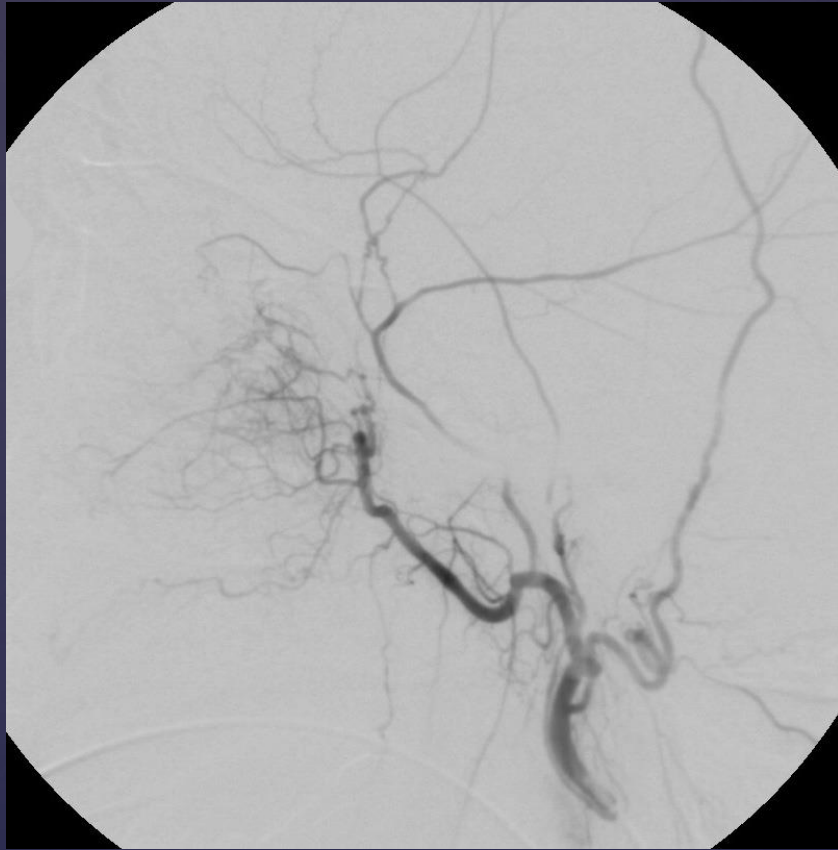







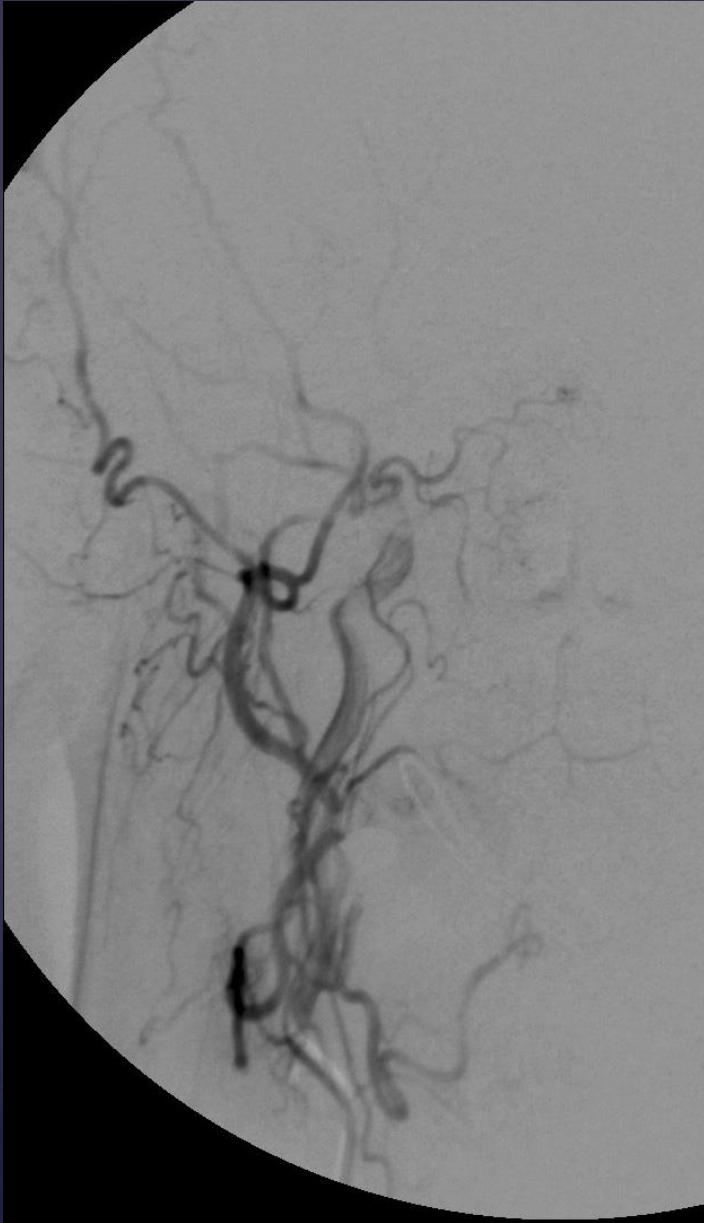


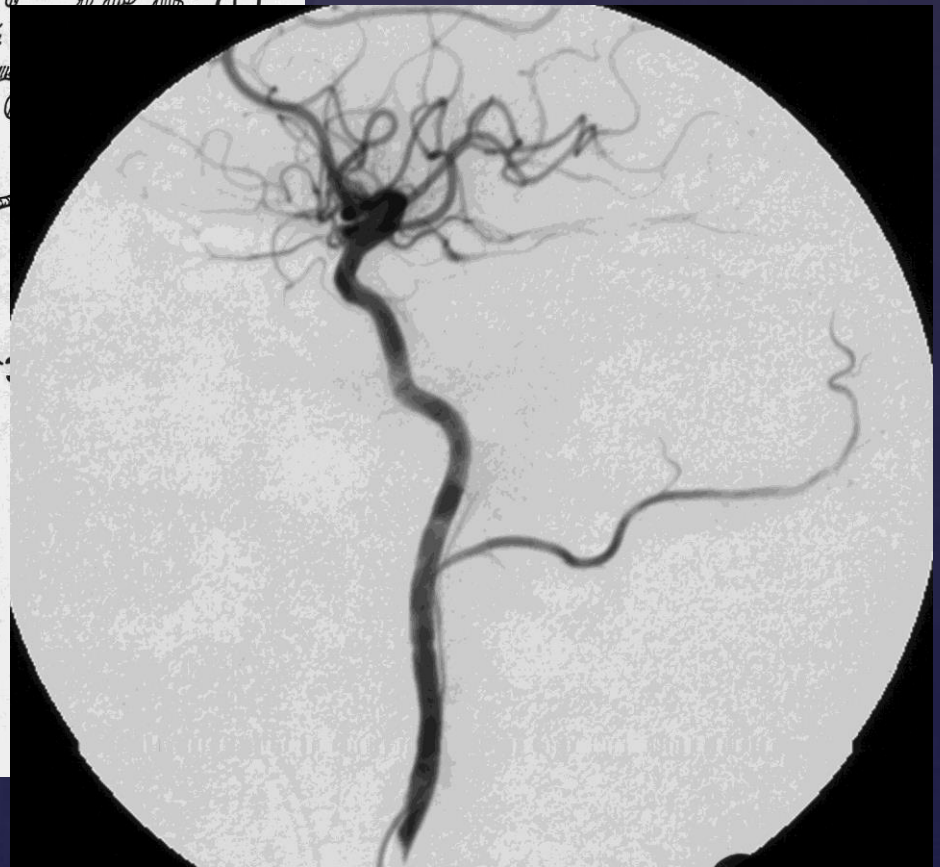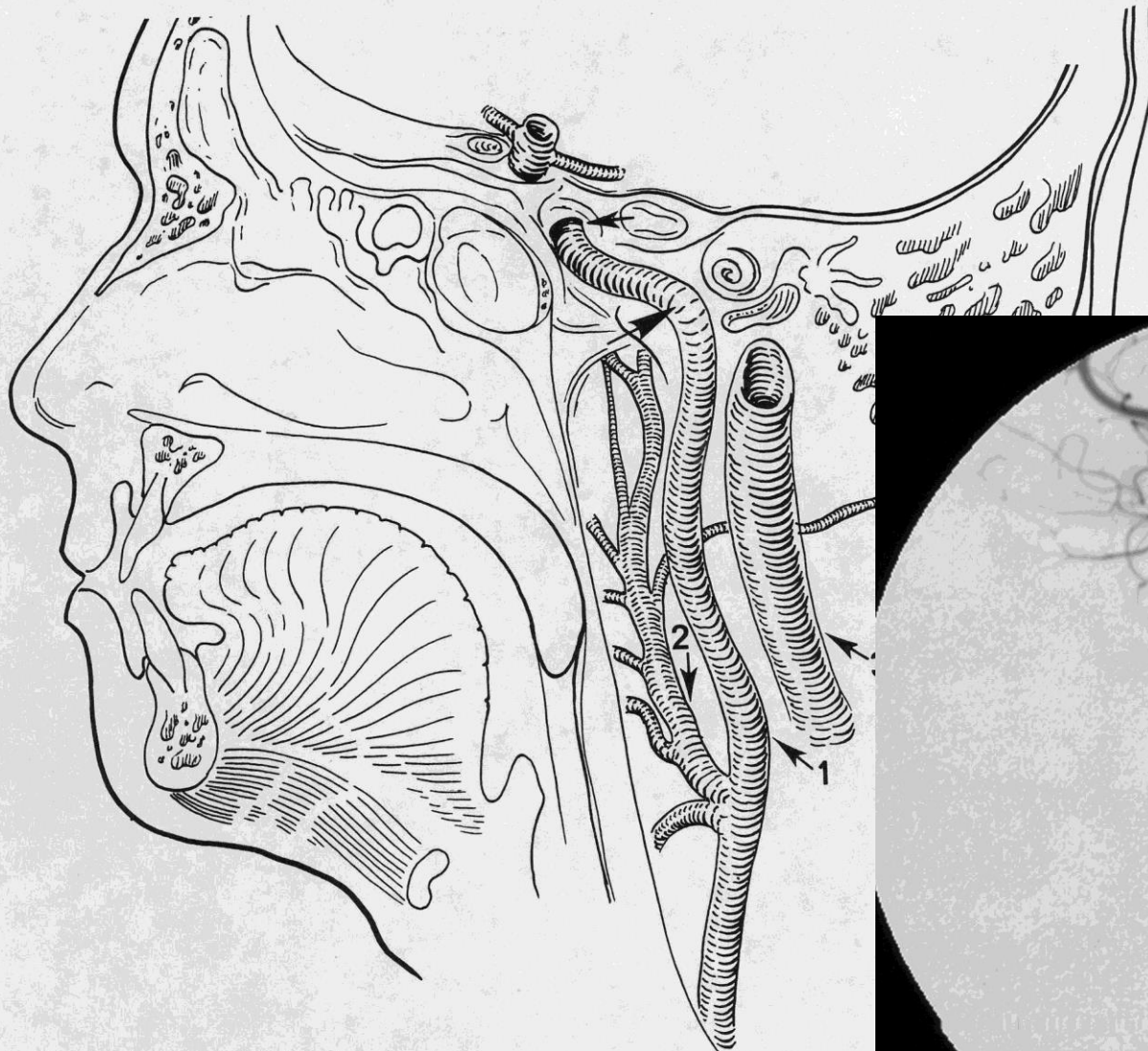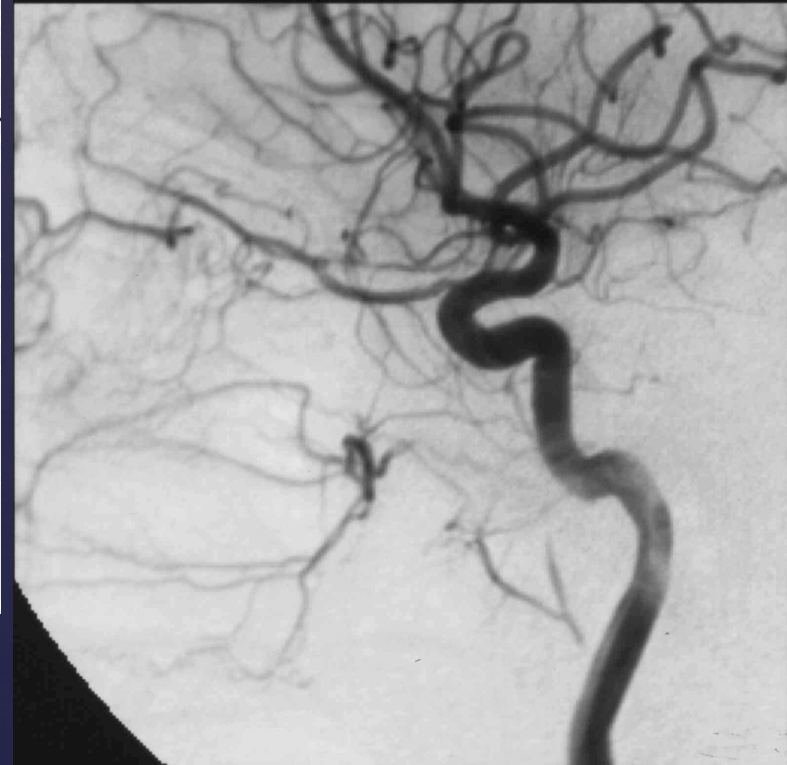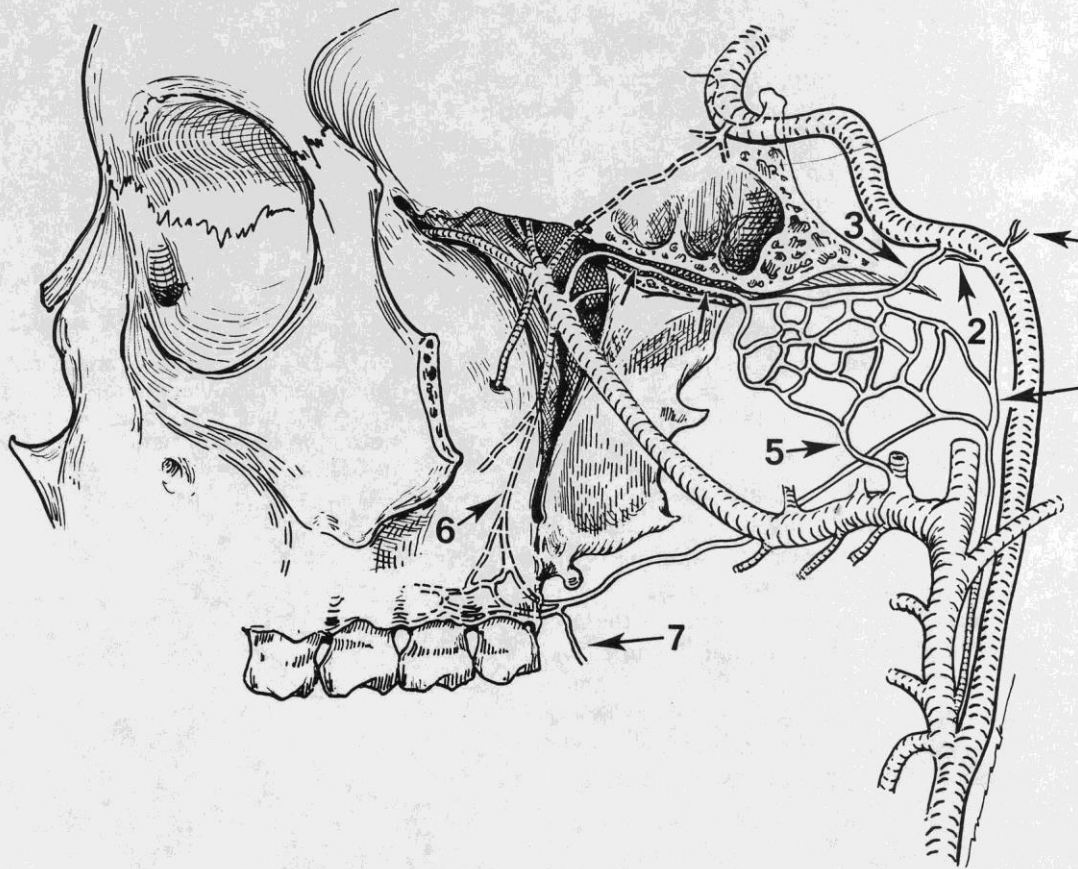


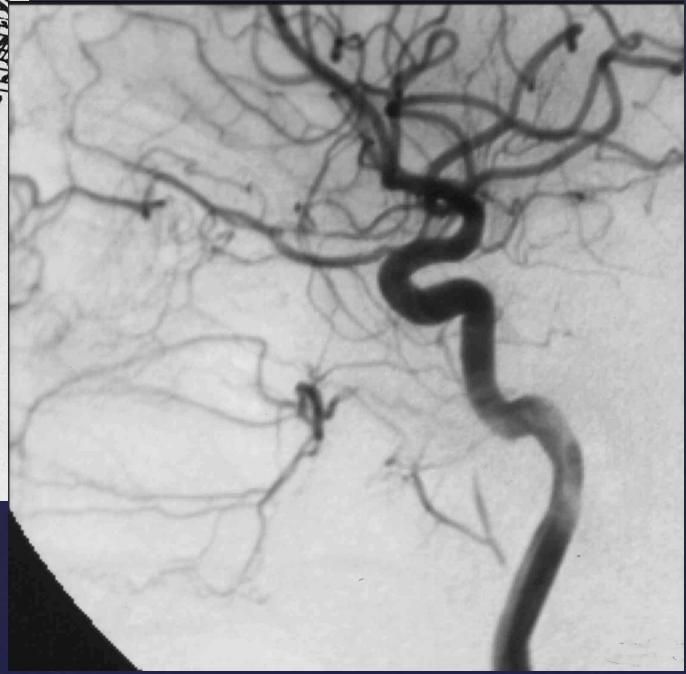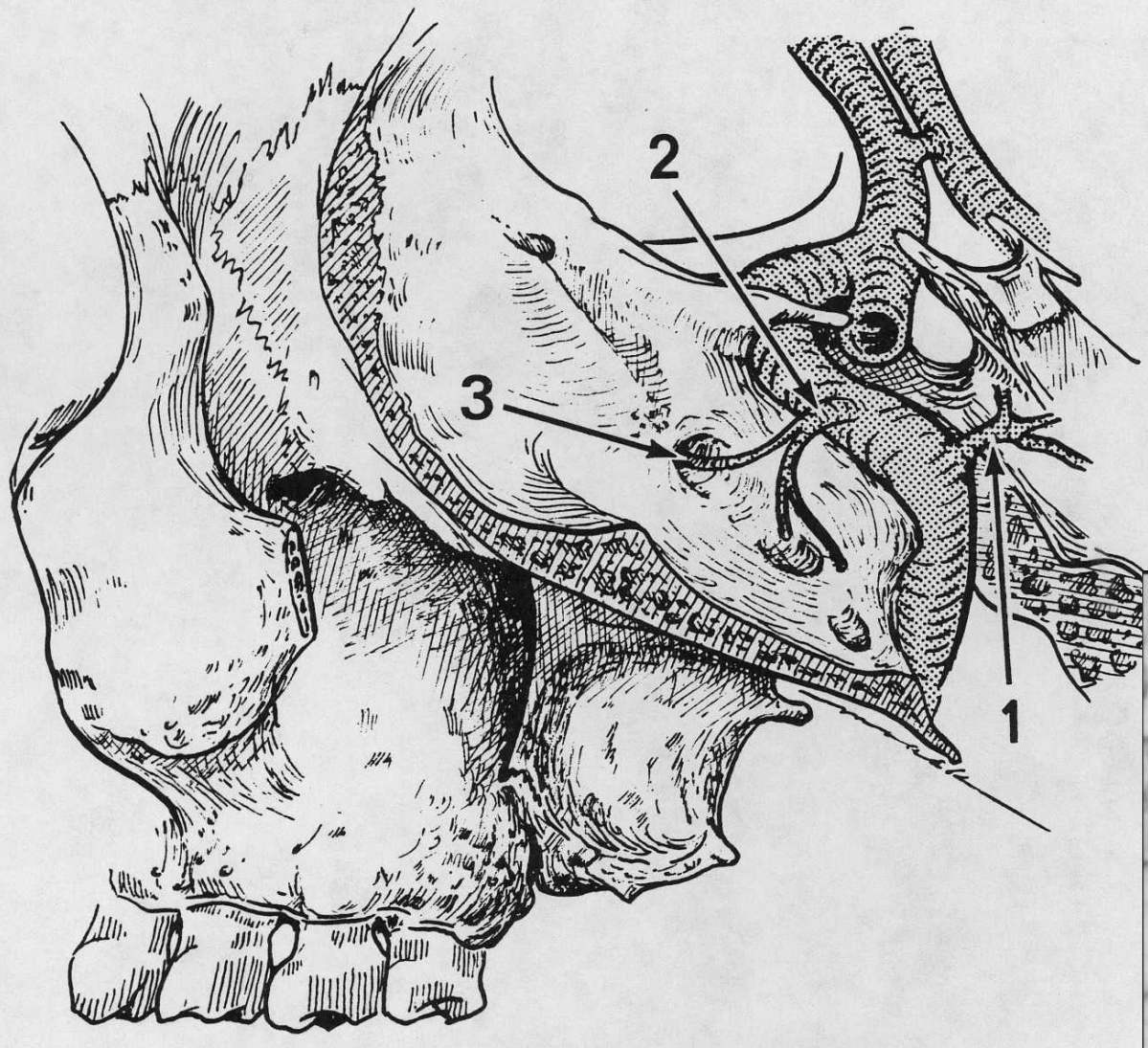
Υποκόγχιος Αρτηρία

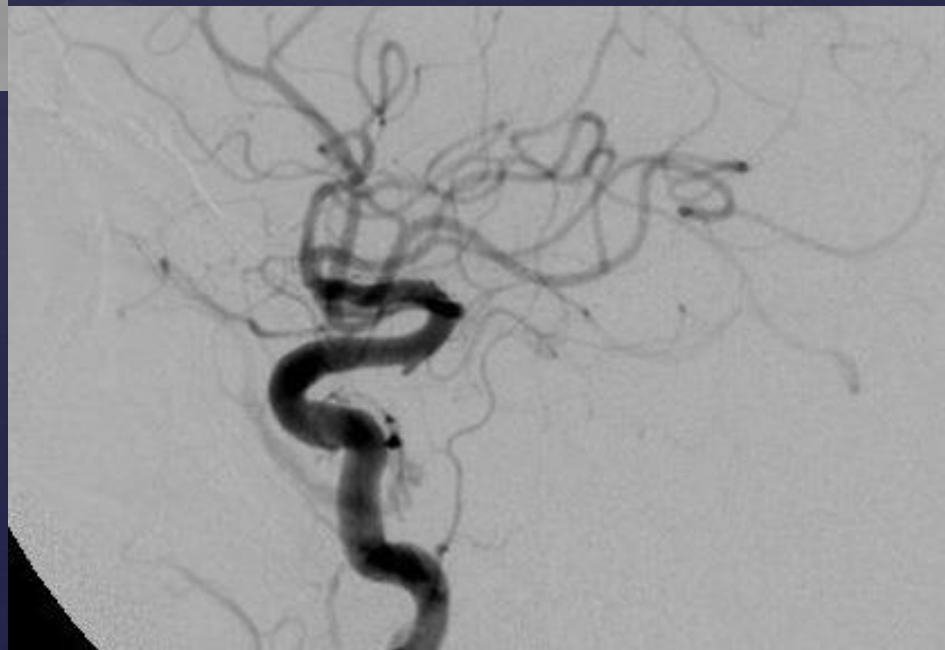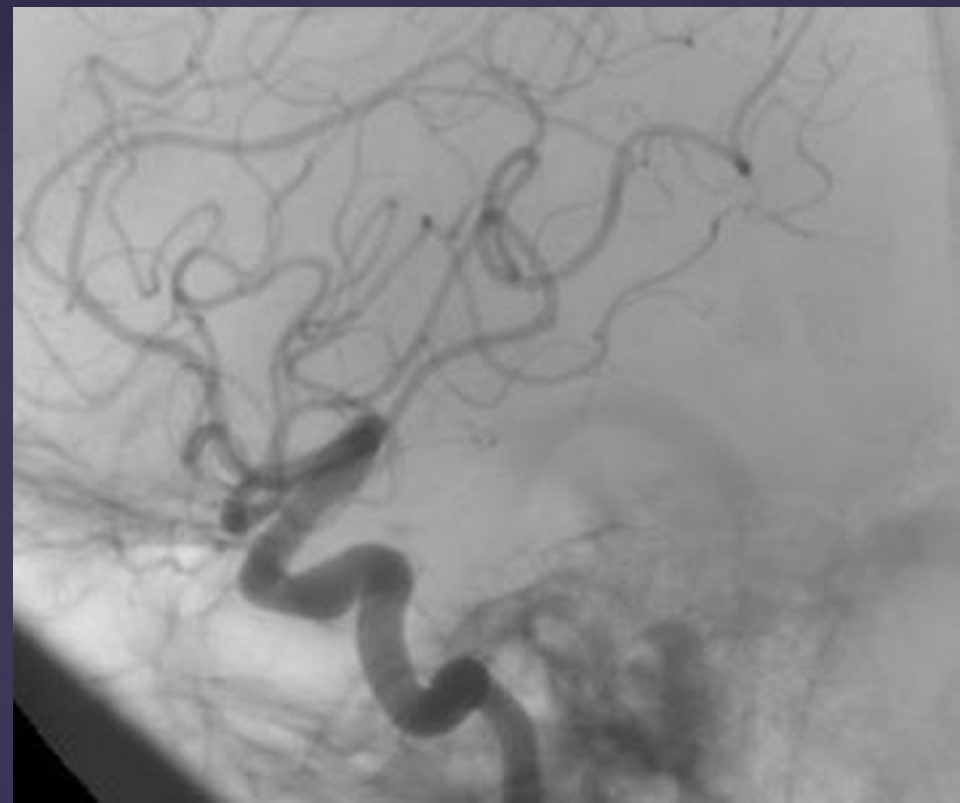


Ἐσω ρινική
αρτηρία









{

