

The cerebral isthmus: fiber tract anatomy, functional significance, and surgical considerations

Christos Koutsarnakis, MD,^{1,3} Faidon Liakos, MD,^{1,3} Evangelia Liouta, MSc,²
Konstantinos Themistoklis, MD,^{1,3} Damianos Sakas, MD, PhD,^{1,2} and George Stranjalis, MD, PhD¹⁻³

¹Department of Neurosurgery, University of Athens, Evangelismos Hospital; ²Hellenic Center for Neurosurgical Research “Petros Kokkalis;” and ³Microneurosurgery Laboratory, Evangelismos Hospital, Athens, Greece

OBJECT The cerebral isthmus is the white matter area located between the periinsular sulcus and the lateral ventricle. Studies demonstrating the fiber tract and topographic anatomy of this entity are lacking in current neurosurgical literature. Hence, the authors' primary aim was to describe the microsurgical white matter anatomy of the cerebral isthmus by using the fiber dissection technique, and they discuss its functional significance. In addition, they sought to investigate its possible surgical utility in approaching lesions located in or adjacent to the lateral ventricle.

METHODS This study was divided into 2 parts and included 30 formalin-fixed cerebral hemispheres, 5 of which were injected with colored silicone. In the first part, 15 uncolored specimens underwent the Klingner's procedure and were dissected in a lateromedial direction at the level of the superior, inferior, and anterior isthmuses, and 10 were used for coronal and axial cuts. In the second part, the injected specimens were used to investigate the surgical significance of the superior isthmus in accessing the frontal horn of the lateral ventricle.

RESULTS The microsurgical anatomy of the anterior, superior, and inferior cerebral isthmuses was carefully studied and recorded both in terms of topographic and fiber tract anatomy. In addition, the potential role of the proximal part of the superior isthmus as an alternative safe surgical corridor to the anterior part of the lateral ventricle was investigated.

CONCLUSIONS Using the fiber dissection technique along with coronal and axial cuts in cadaveric brain specimens remains a cornerstone in the acquisition of thorough anatomical knowledge of narrow white matter areas such as the cerebral isthmus. The surgical significance of the superior isthmus in approaching the frontal horn of the lateral ventricle is stressed, but further studies must be carried out to elucidate its role in ventricular surgery.

<http://thejns.org/doi/abs/10.3171/2015.3.JNS142680>

KEY WORDS cerebral isthmus; fiber dissection; microsurgical anatomy; insula; ventricular approaches; periinsular sulcus; anatomy

THE Latin word “isthmus” originates from the Greek word “isthmós” (Greek: ἴσθμός) and means a narrow strip of land, bordered on both sides by water, which connects 2 larger land areas (<http://dictionary.reference.com/browse/isthmus>). Therefore, an isthmus connects lands and separates water areas at the same time. The appreciation of this dual semantic connotation of connection-separation is what essentially led to the incorporation of this word into medical terminology. In brain anatomy, the cerebral isthmus represents a discrete strip of white matter located between the periinsular sulcus and the lateral ventricle.^{5,47} It connects anatomofunctionally the gray matter of the insula and the so-called central core

with the rest of the hemisphere⁵—the “lands”—whereas at the same time it separates the insular cistern from the ventricular system—the “water areas.”

With respect both to its pivotal topographic anatomy and its complex white matter composition, the cerebral isthmus seems to play a key role in the dissemination of gliomas from and to the insula and paralimbic structures.^{13,34,35,63,66,67} Hence, accurate knowledge of the location, orientation, trajectory, and function of the fiber tracts that make up this anatomical entity is crucial for the optimal management of patients harboring such pathologies.^{9,10,18}

Coronal and axial cuts of cerebral hemispheres can de-

ABBREVIATIONS DTI = diffusion tensor imaging; MCA = middle cerebral artery.

SUBMITTED November 23, 2014. **ACCEPTED** March 30, 2015.

INCLUDE WHEN CITING Published online September 11, 2015; DOI: 10.3171/2015.3.JNS142680.

dict the location and correlative anatomy of the cerebral isthmus sufficiently. However, it is the implementation of the fiber dissection technique that reveals the intricate configuration and delicate white matter tract composition of this confined parenchymal area. The integration and reciprocal enrichment of these 2 methods—i.e., sectional cuts and fiber dissection—provides an accurate and thorough 3D anatomical knowledge for surgical practice. The fact that the cerebral isthmus is not just a white matter band that “wraps” the central core in a circumferential manner but is literally a cluster of fiber pathways that connects the insular and central gray matter with the remaining hemisphere has to be stressed.

Furthermore, the proximity of the entire isthmus to the lateral ventricle raises surgical considerations about the optimal access of intra- and paraventricular pathological lesions. Apart from the distinct role of the transcalsal and transcortical approaches to ventricular surgery, the significance of specific segments of the isthmus as alternative surgical corridors should be evaluated.^{16,48,53}

Methods

This study was divided into 2 parts and included 30 adult, formalin-fixed cerebral hemispheres, 5 of which were injected with blue and red silicone for vascular enhancement. For the fixation process a 10%–15% formalin solution was used for a minimum period of 6 weeks.

In the first part we used the 25 noncolored specimens after carefully removing the vessels and arachnoid membrane. Fifteen specimens underwent the Klinger’s procedure and were investigated using the fiber dissection technique and the microscope (Carl Zeiss OPMI Plus).^{26,31} Five hemispheres were used for each segment of the isthmus— anterior, superior, inferior—and were dissected in a lateromedial direction at the level of their respective periinsular sulci until the ventricular ependyma was encountered. The remaining 10 specimens were explored with sectional cuts at the level of the superior, inferior, and anterior isthmuses to measure their dimensions and demonstrate their relationship to the insular surface anatomy and central core structures.

After carefully reviewing the anatomical considerations revealed during the first part, we used the 5 colored specimens to investigate the surgical utility of the proximal segment of the superior isthmus in accessing the frontal horn of the lateral ventricle. Initially, the sylvian fissure was widely split⁶² and the insular surface anatomy was studied. Due to the “rigid” consistency of the specimens, we were obliged to remove segments of the frontoparietal and temporal operculum, to demonstrate more accurately the feasibility of the proximal superior isthmus in approaching the frontal horn. Special emphasis was given to the topographic anatomy of the insular arteries, lying over this part of the isthmus, as well as to the optimal surgical trajectory.

Our primary dissection tools for the white matter anatomy were fine metallic periosteal dissectors, various-sized anatomical forceps, and microsurgical scissors since we found them easier and more precise in handling than the traditional wooden spatulas.^{55,68}

During the study numerous digital photographs were taken. It must be emphasized that the photographs included in the current study were not edited by picture processing software, thus resembling closely the actual fiber tract anatomy and configuration encountered during the dissections.

Results

Cerebral Isthmus

The cerebral isthmus is divided into 3 segments: anterior, superior, and inferior.^{5,47}

Anterior Isthmus

The anterior isthmus is defined as the band of white matter situated between the anterior periinsular sulcus and the frontal horn of the lateral ventricle.^{5,47} To study the fiber tract anatomy of this complex region, parts of the frontoorbital and temporal opercula are carefully removed, exposing the insular apex and the anterior insular surface (Fig. 1A).^{49,52,54} Peeling away the gray matter of the insular apex along with that of the transverse and accessory gyri discloses the extreme capsule, which constitutes the first layer of the anterior isthmus. Dissecting the extreme capsule reveals the second isthmic layer composed of the anterior parts of the occipitofrontal and uncinate fasciculi, both intermingling with the fibers of the external capsule at the periphery (Fig. 1B). We observed that, at this layer level, the occipitofrontal fasciculus occupies the superior two-thirds of the anterior isthmus while the uncinate fasciculus covers the remaining one-third (Fig. 1C). Progressive dissection discloses the gray matter of the putamen and superiorly to the fibers of the anterior limb of the internal capsule, which compose the third white matter layer of the anterior isthmus (Fig. 1D). Dissection of the anterior limb of the internal capsule reveals the ependyma of the frontal horn and head of the caudate nucleus (Fig. 1E). Axial cuts demonstrate that the medial boundary of the anterior isthmus consists of the frontal horn superiorly and the putamen and the head of the caudate nucleus inferiorly. The average length and width of the anterior isthmus were 29.2 mm and 7.6 mm, respectively (Tables 1 and 2).

Superior Isthmus

The superior isthmus is defined as the strip of white matter between the superior periinsular sulcus and the lateral ventricle (frontal horn, body, and superior part of the atrium).^{5,47} To reveal the intricate fiber tract anatomy of this region, the frontoparietal operculum and a part of the frontoparietal convexity are carefully removed with attention to preserve the upper insular cortex. The superior periinsular sulcus, spanning between the anterior and posterior insular points and the upper parts of the short and long insular gyri are identified (Fig. 2A).^{49,52,54} Peeling away the gray matter of the periinsular sulcus and upper insular surface reveals the extreme capsule, which constitutes the first layer of the superior isthmus (Fig. 2B). Gradual dissection of the extreme capsule discloses the fibers of the dorsal external capsule—the second layer of the superior isthmus—passing through the isthmus to the fiber system of corona radiata (Fig. 2C). Further delicate

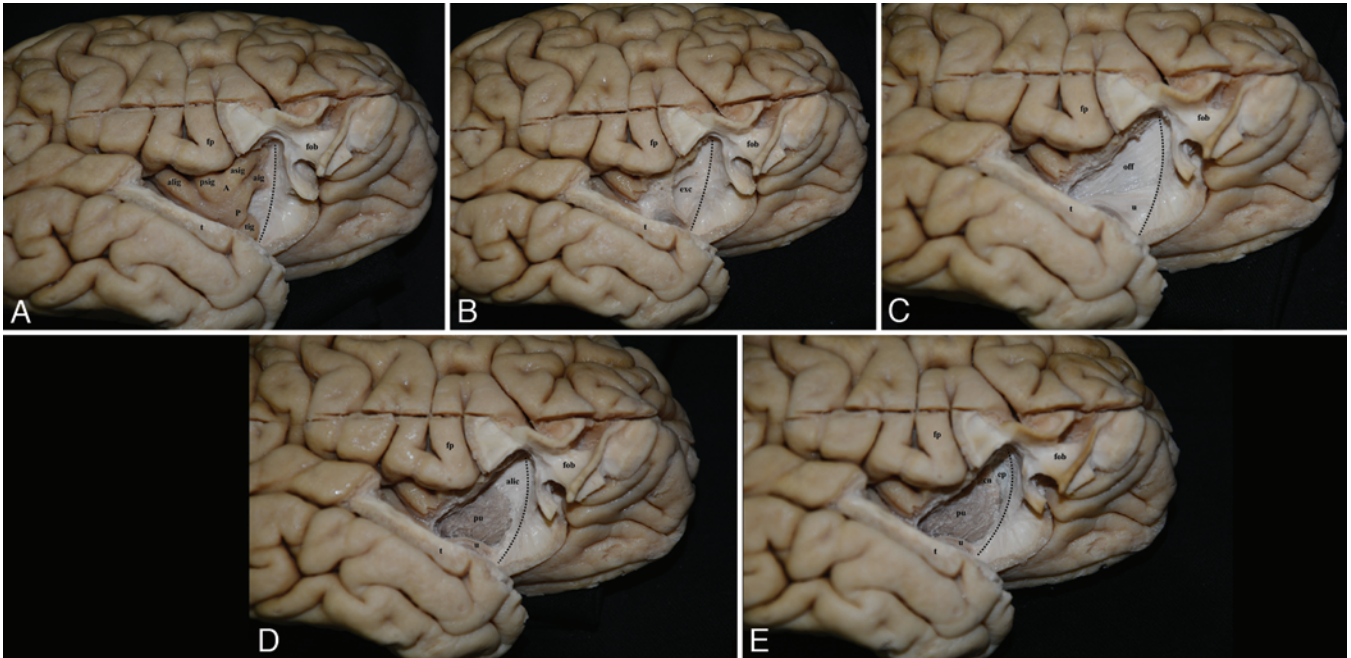


FIG. 1. Stepwise lateromedial dissection of the anterior cerebral isthmus in a right cerebral hemisphere. The *dotted black line* represents the level of the anterior periinsular sulcus in each panel. **A:** Anterior periinsular sulcus. Parts of the fronto-orbital and temporal opercula have been removed to expose the insular apex and the anterior insular surface. **B:** First layer: extreme capsule. The extreme capsule is revealed after peeling away the gray matter of the insular apex, transverse and accessory gyri. **C:** Second layer: occipitofrontal and uncinata fasciculi. The extreme capsule has been dissected. The second layer of the anterior isthmus composed of the fibers of the anterior parts of the occipitofrontal and uncinata fasciculi is revealed. **D:** Third layer: anterior limb of the internal capsule. Progressive dissection at the level of the anterior isthmus exposes the fibers of the anterior limb of the internal capsule, i.e., the third layer. The putamen is also evident centrally, demonstrating the proximity of these 2 anatomical entities. **E:** Ependyma of the frontal horn. The ependyma of the frontal horn is encountered at the end of the dissection procedure of the anterior isthmus. The head of the caudate nucleus, lying adjacent to the frontal horn, is also demonstrated. A = insular apex; aig = accessory insular gyrus; alic = anterior limb of the internal capsule; alig = anterior long insular gyrus; asig = anterior short insular gyrus; cn = caudate nucleus; ep = ventricular ependymal; exc = extreme capsule; fob = fronto-orbital operculum; fp = frontoparietal operculum; off = occipitofrontal fasciculus; P = insular pole; psig = posterior short insular gyrus; pu = putamen; t = temporal operculum; tig = transverse insular gyrus; u = uncinata fasciculus. Figure is available in color online only.

dissection of the external capsule at the level of the peri-insular sulcus exposes the superficial layer of the internal capsule while inferiorly the upper part of the putamen is identified (Fig. 2D). Removing the putamen and the gray matter of the globus pallidus clearly demonstrates the fibers of the anterior limb, genu, and posterior limb of the internal capsule, which constitute the third and last layer of the superior isthmus (Fig. 2E). We noticed that the anterior limb occupies a maximum length of 25 mm in the hemispheres measured and its fibers pursue a rather oblique course. The genu follows a straighter course compared with the anterior limb, while the posterior limb runs again obliquely. The demarcation distinguishing the aforementioned parts of the internal capsule is their respective fiber direction. The transition point between the anterior limb and the genu was observed at the level of the posterior short insular gyrus, whereas the central insular sulcus and anterior long gyrus correspond to the transition of the genu to the posterior limb. Gradual dissection of the dense and compact fibers of the internal capsule exposes the ependymal layer of the frontal horn and body of the lateral ventricle along with the head and body of the caudate nucleus (Fig. 2F). Although the internal capsule at the level of the superior isthmus is composed of differ-

ent fiber tracts (frontopontine fibers, corticobulbar fibers, corticospinal fibers, parietopontine fibers, and superior and anterior thalamic peduncles), these cannot be properly demonstrated since they share the same orientation and direction.^{17,18,55,68} Sectional cuts depict thoroughly the relationship of the superior isthmus to the insular surface anatomy and central core structures (Figs. 3A–C and 4B–E). The curved shape of the anterior part of the superior isthmus, resulting from the anatomical indentation of the caudate and lentiform nuclei on it is also evident. The average length of the superior isthmus was 56.4 mm, while its width varies, ranging from an average of 10.8 mm in the anterior part (anterior insular point to the frontal horn), 16.4 mm in the middle (level of central insular sulcus to the body of lateral ventricle), and 10.2 mm in the posterior part (posterior insular point to the superior part of the atrium) (Tables 1 and 2).

Inferior Isthmus

The inferior isthmus is defined as the white matter area between the inferior periinsular sulcus and the temporal horn and inferior part of the atrium of the lateral ventricle.^{5,47} To study the fiber tract anatomy of this region, the temporal operculum and part of the temporal lobe are re-

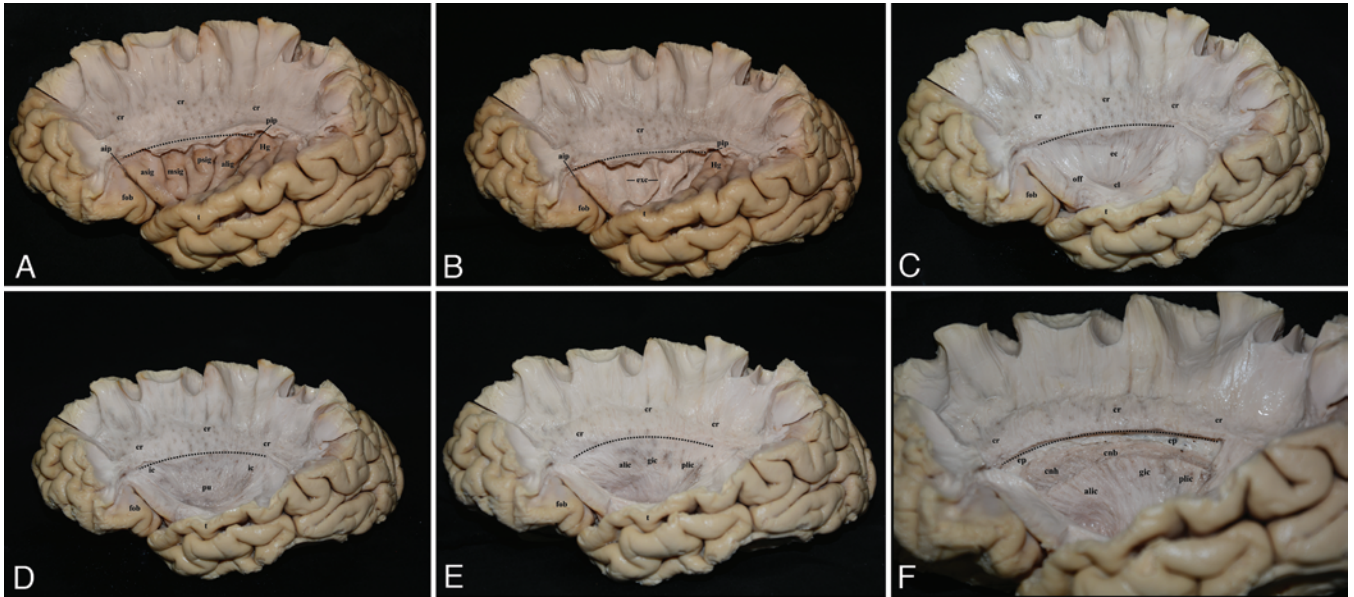


FIG. 2. Stepwise lateromedial fiber dissection of the superior cerebral isthmus in a left cerebral hemisphere. The *dotted black line* represents the level of the superior periinsular sulcus in each panel. **A:** Superior periinsular sulcus. The frontoparietal operculum and a part of the frontoparietal convexity are carefully removed with attention to preserve the upper insular cortex. The fiber system of the corona radiata is revealed. The superior periinsular sulcus and the upper part of the short and long insular gyri are identified. **B:** First layer: extreme capsule. The extreme capsule is revealed after peeling away the gray matter of the periinsular sulcus and upper insular surface. The extreme capsule constitutes the first layer of the superior isthmus. **C:** Second layer: external capsule. Dissection of the extreme capsule discloses the fibers of the external capsule, which constitute the second layer of the superior isthmus. Note the transition and intermingling of the external capsule to the fibers of the corona radiata at the level of the superior isthmus. This photograph also demonstrates the occipitofrontal fasciculus and the claustrum, since the dissection was directed further inferiorly. **D:** Third layer: internal capsule. The fibers of the superficial layer of the internal capsule are revealed after dissecting the external capsule. The internal capsule forms the third layer of the superior isthmus. The gray matter of the putamen is also depicted inferiorly. **E:** Third layer: anterior limb, genu, and posterior limb of the internal capsule. Carefully dissecting the gray matter of the putamen and globus pallidus demonstrates more accurately the fiber direction of the anterior limb, genu, and posterior limb of the internal capsule. **F:** Ependyma of the lateral ventricle. Gradual dissection of the compact and dense fibers of the internal capsule at the level of the superior isthmus reveals the ependymal layer of the lateral ventricle. Inferiorly the head and body of the caudate nucleus are demonstrated. alic = anterior limb of the internal capsule; alig = anterior long insular gyrus; aip = anterior insular point; asig = anterior short insular gyrus; cl = claustrum; cnb = body of the caudate nucleus; chn = head of the caudate nucleus; cr = corona radiata; ec = external capsule; ep = ventricular ependymal; exc = extreme capsule; fob = fronto-orbital operculum; gic = genu of the internal capsule; Hg = Heschl gyrus; ic = internal capsule; msig = middle short insular gyrus; off = occipitofrontal fasciculus; pip = posterior insular point; plic = posterior limb of the internal capsule; psig = posterior short insular gyrus; pu = putamen; t = temporal operculum. Figure is available in color online only.

moved, with attention to preserve the inferior periinsular sulcus and the lower part of the insular surface (Fig. 5A). Peeling away the gray matter of the periinsular sulcus, insular apex, and inferior surface of the insula reveals the extreme capsule, which constitutes the first layer of the inferior isthmus (Fig. 5B). Careful dissection of the extreme capsule discloses the fibers of the external capsule—the second layer of the inferior isthmus—and a part of the dorsal claustrum. At this dissection step, the characteristic fibers of the occipitofrontal and uncinate fasciculi are also revealed. Therefore, the inferior isthmus, at this layer level, is composed of the inferior part of the uncinate and oc-

cipitofrontal fasciculi anteriorly and the dorsal part of the external capsule posteriorly (Fig. 5C). Removal of these white matter bundles reveals the anterior commissure and the sub- and retrolenticular parts of the internal capsule—all of them composing the third layer of the inferior isthmus (Fig. 5D). Progressive dissection reveals the fibers of the tapetum of the temporal horn and atrium of the lateral ventricle, which form the fourth and last layer (Fig. 5E). It

TABLE 1. A summary of the length of the anterior, superior, and inferior cerebral isthmuses

Isthmus	Mean Length (range) in mm
Anterior	28 (25–32)
Superior	56.4 (53–64)
Inferior	52.8 (45–60)

TABLE 2. A summary of the width of the anterior, superior, and inferior cerebral isthmuses

Isthmus	Mean (range) in mm
Anterior	7.6 (7–9)
Superior	
Anterior portion	10.8 (10–15)
Middle portion	16.4 (15–20)
Posterior portion	10.2 (10–13)
Inferior	9.0 (8–10)

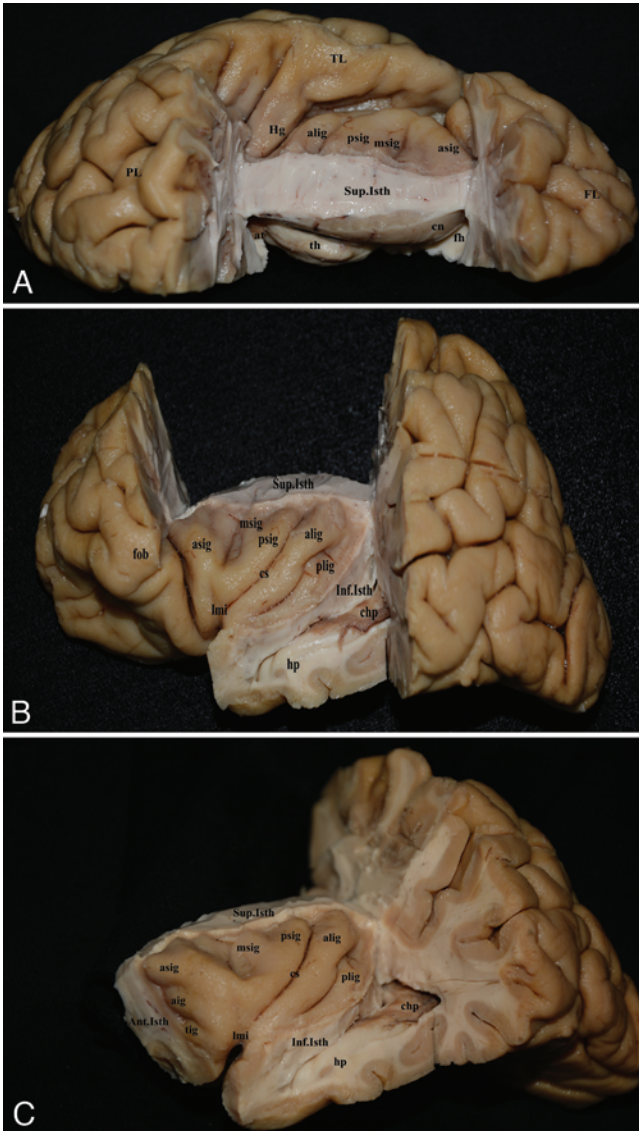


FIG. 3. Photographs of brain specimens demonstrating the correlation between the cerebral isthmus and the insular surface anatomy. **A:** Superior view of a left cerebral hemisphere following removal of the frontoparietal operculum through the superior periinsular sulcus. The entire length of the superior cerebral isthmus is demonstrated. Notice the “anatomical indentation” of the head of the caudate nucleus on the proximal part of the superior isthmus. Appreciate the complex relationship between the insular surface anatomy, the superior isthmus, and the head of the caudate nucleus. **B:** Lateral view of a left cerebral hemisphere following removal of the frontoparietal and temporal opercula through the superior and inferior periinsular sulci respectively. The insular surface anatomy and its relationship to the superior and inferior isthmuses are demonstrated. Notice the proximity of the inferior isthmus to the temporal horn and hippocampus. **C:** Anterolateral view of a left cerebral hemisphere following removal of all the opercula and their respective lobes through the anterior, superior, and inferior periinsular sulci. The correlation between the insular surface anatomy and the entire cerebral isthmus is demonstrated. aig = accessory insular gyrus; Ant.Isth = anterior isthmus; alig = anterior long insular gyrus; asig = anterior short insular gyrus; at = atrium; chp = choroid plexus; cn = caudate nucleus; cs = central sulcus of the insula; fh = frontal horn; FL = frontal lobe; fob = frontoorbital operculum; Hg = Heschl gyrus; hp = hippocampus; Inf.Isth = inferior isthmus; lmi = limen insula; msig = middle short insular gyrus; PL = parietal lobe; plig = posterior long insular gyrus; psig = posterior short insular gyrus; Sup.Isth = superior isthmus; th = thalamus; tig = transverse insular gyrus; TL = temporal lobe. Figure is available in color online only.

must be emphasized that although the sub- and retrolenticular parts of the internal capsule are composed of different fiber tracts, (i.e., temporopontine, parietopontine, occipitopontine, inferior and posterior thalamic peduncles, and optic radiation), they cannot be individually dissected and demonstrated.^{17,18,45,55} The only exception is the anterior optic bundle or Meyer’s loop, which courses prominently in the sublenticular part. At the end of the dissection process the ventricular ependyma and the tail of the caudate nucleus are demonstrated. Sectional cuts clearly depict the correlation of this segment of the isthmus to the insular surface anatomy and the deep structures such as the hippocampus and the tail of caudate nucleus (Figs. 3B and C and 4B–E). The average length and width of the inferior isthmus were 52.8 mm and 9 mm, respectively. (Tables 1 and 2).

It has to be noted that the temporal stem, although closely related to the inferior isthmus in terms of anatomy and function, is actually a different anatomical entity. It is defined as the white matter area between the temporal

horn and the inferior periinsular sulcus, originating at the level of the limen insula and terminating at the level of the lateral geniculate body.^{25,35,59} Hence, it is smaller than the inferior isthmus. The average length of the temporal stem was 32 mm. For this measurement we used the intersection point of the gyrus of Heschl with the inferior periinsular sulcus as a surface landmark of the lateral geniculate body.^{5,59}

Transisthmus Approach to the Frontal Horn

Given the aforementioned anatomical considerations, we sought to investigate the surgical utility of the proximal 2–2.5 cm of the superior cerebral isthmus in safely accessing the frontal horn. Since it is mainly composed of the anterior limb of the internal capsule, this segment is relatively noneloquent in terms of functional significance, when compared with the rest of the cerebral isthmus.^{32,51} For that purpose, 5 formalin-fixed and silicone-injected cerebral hemispheres were used. After meticulous dissection of both the proximal and distal rami of the sylvian

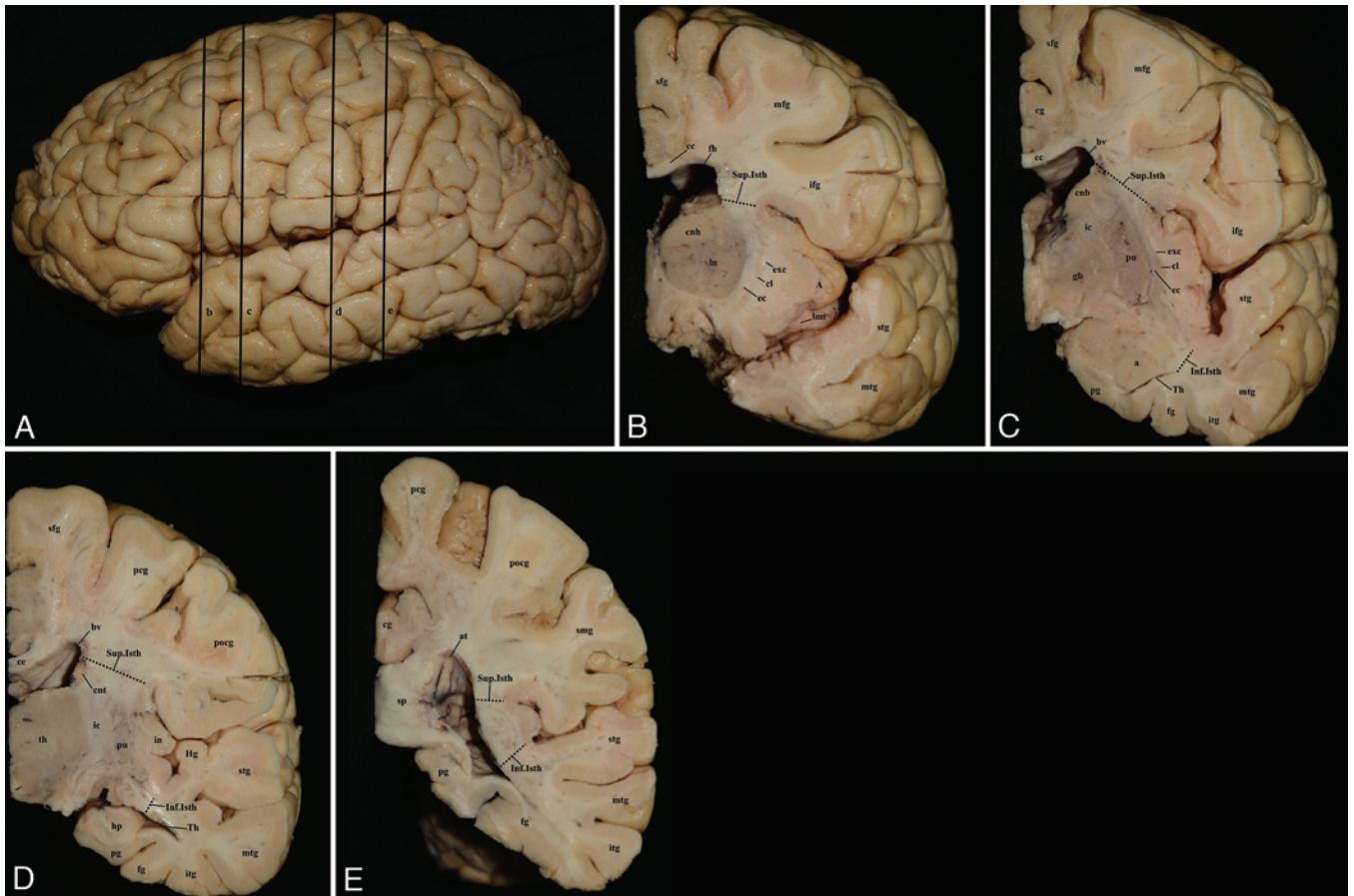


FIG. 4. Coronal cuts of a left cerebral hemisphere accomplished through the levels b, c, d, and e. **A:** Photograph of a left cerebral hemisphere. The *black lines* represent the levels of coronal cuts made. b = level of the sylvian point; c = level of the amygdala; d = level of Heschl gyrus; e = level of the posterior insular point. Appreciate the topographic anatomy of the superior and inferior cerebral isthmuses with respect to central core structures and lateral ventricular compartments (B–E). Note the proximity of the superior isthmus to the head and body of the caudate nucleus. The relationship of the superior isthmus to the frontal horn as well as that of the inferior isthmus to the temporal horn is also evident. **B:** Coronal cut at the level of the sylvian point (b). Appreciate the relationship of the superior isthmus to the frontal horn of the lateral ventricle and to the head of caudate nucleus. **C:** Coronal cut at the level of the amygdala (c). This part of the inferior isthmus is incised down to the temporal horn during the transsylvian transinsular approach for selective amygdalohippocampectomy. **D:** Coronal cut at the level of the Heschl gyrus (d). Notice the enlarged width of the superior isthmus due to the participation of the posterior limb of the internal capsule at this level. **E:** Coronal cut at the level of the posterior insular point (e). Transecting the superior and inferior isthmuses at this level leads to the superior and inferior part of the atrium, respectively. A = insular apex; a = amygdala; at = atrium; bv = body of the ventricle; cc = corpus callosum; cg = cingulate gyrus; cl = claustrum; cnb = body of the caudate nucleus; chn = head of the caudate nucleus; cnt = tail of the caudate nucleus; ec = external capsule; exc = extreme capsule; fg = fusiform gyrus; fh = frontal horn; gb = globus pallidus; Hg = Heschl gyrus; hp = hippocampus; ic = internal capsule; ifg = inferior frontal gyrus; in = insula; Inf.Isth = inferior isthmus; itg = inferior temporal gyrus; lmi = limen insula; In = lentiform nucleus; mfg = middle frontal gyrus; mtg = middle temporal gyrus; pcg = precentral gyrus; pg = parahippocampal gyrus; pocg = postcentral gyrus; pu = putamen; sfg = superior frontal gyrus; smg = supramarginal gyrus; sp = splenium; stg = superior temporal gyrus; Sup.Isth = superior isthmus; Th = temporal horn; th = thalamus. Figure is available in color online only.

fissure,⁶⁴ the opposing opercula are gently retracted with self-retaining retractors (Fig. 6A). The insular surface anatomy is exposed along with the branches of the middle cerebral artery (MCA). Due to the relatively “rigid” consistency of the cadaveric brain specimens, parts of the frontal and temporal operculum are carefully removed to demonstrate more accurately the regional anatomy and to dissect more easily without the retractors obstructing the surgical view (Fig. 6B). The superior periinsular sulcus, originating at the anterior insular point, is exposed along with the M₂ and M₃ branches of the MCA. The vascular complex of the prefrontal and precentral arteries and their

candelabra lying over this part of the periinsular sulcus are identified and microsurgically mobilized from their arachnoid adhesions (Fig. 6C). Blunt dissection along the proximal 2–2.5 cm of the sulcus with an almost straight trajectory gradually leads to the frontal horn of the lateral ventricle (Fig. 7). The anterior and posterior points that demarcate the extent of the dissection along the superior periinsular sulcus are the anterior insular point and the initiation of the posterior short insular gyrus, respectively. Furthermore, the ideal angle of the brain transgression was measured to be 10° superiorly off the horizontal plane of the surgeon’s view. This surgical trajectory facilitates

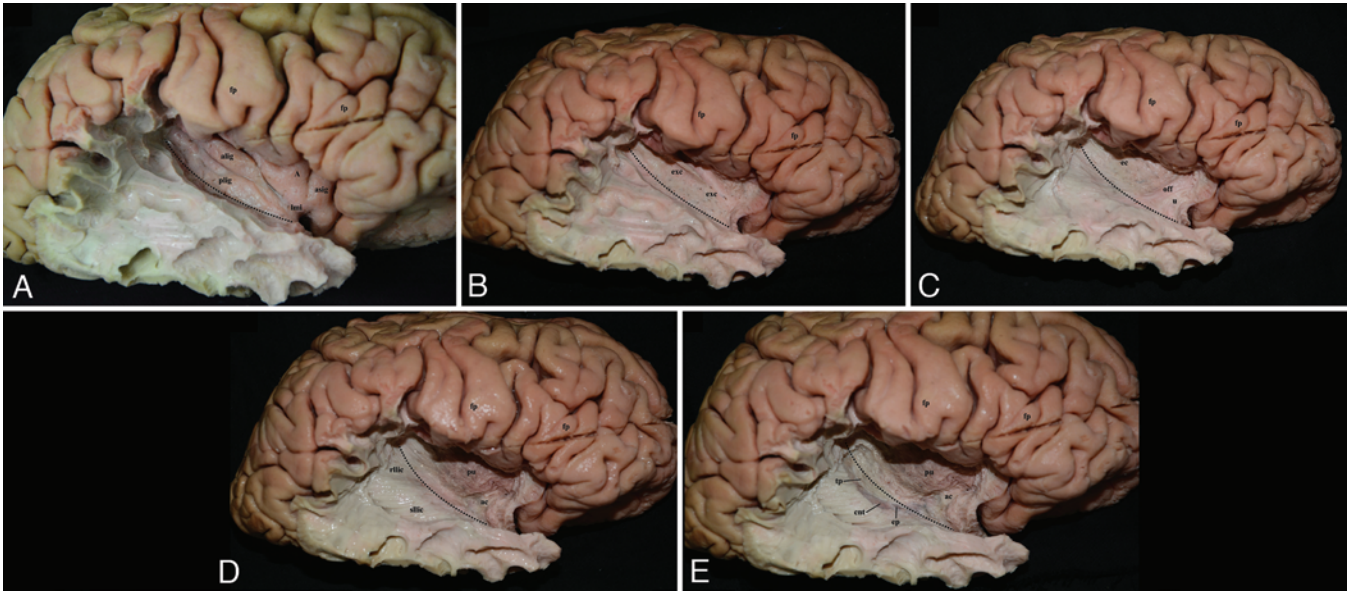


FIG. 5. Stepwise lateromedial fiber dissection of the inferior cerebral isthmus in a right cerebral hemisphere. The *dotted black line* represents the level of the inferior periinsular sulcus in each panel. **A:** Inferior periinsular sulcus. The temporal operculum and a part of the temporal lobe are removed with attention to expose the inferior periinsular sulcus and the lower part of the insular surface. **B:** First layer: extreme capsule. Peeling away the gray matter of the periinsular sulcus, insular apex, and inferior insular surface reveals the extreme capsule, which constitutes the first layer of the inferior isthmus. **C:** Second layer: external capsule and occipitofrontal and uncinale fasciculi. Carefully dissecting the fibers of the extreme capsule discloses the second layer of the inferior isthmus composed of the inferior parts of the uncinale and occipitofrontal fasciculi rostrally and of the dorsal part of the external capsule caudally. **D:** Third layer: anterior commissure and sublenticular and retrolenticular parts of the internal capsule. Removal of the second white matter layer of the inferior isthmus reveals the anterior commissure and the sub- and retrolenticular parts of the internal capsule, all of them composing the third layer of the inferior isthmus. At this step of dissection the gray matter of the putamen is also exposed superiorly. **E:** Fourth layer: tapetum. The fibers of the tapetum of the temporal horn and atrium of the lateral ventricle, consisting of the fourth and last layer of the inferior isthmus, are demonstrated. Inferiorly, the tail of the caudate nucleus is also exposed during this dissection step. A = insular apex; ac = anterior commissure; alig = anterior long insular gyrus; asig = anterior short insular gyrus; cnt = tail of the caudate nucleus; ec = external capsule; ep = ventricular ependymal; exc = extreme capsule; fp = frontoparietal operculum; lmi = limen insula; off = occipitofrontal fasciculus; plig = posterior longinsular gyrus; pu = putamen; rlic = retrolenticular limb of the internal capsule; sllic = sublenticular limb of the internal capsule; tp = tapetum; u = uncinale fasciculus. Figure is available in color online only.

safe entry to the frontal horn without violating the adjacent head of the caudate nucleus.

Discussion

Accurate knowledge of intrinsic brain anatomy, architecture, and function is a cornerstone of performing modern glioma surgery.^{18,55,63,64} Understanding the dissemination patterns of gliomas through fiber tracts refines the presurgical planning and surgical strategy by tailoring the exposure needed and by estimating the maximal extent of a safe resection in each case.^{9,10,63,64,66} Furthermore, sufficient explanation of pre- and postoperative clinical syndromes and also proper interpretation of modern neuroimaging studies, such as diffusion tensor imaging (DTI), can be accomplished successfully.^{18,49} This complicated yet crucial intellectual process leads to the optimal treatment of patients harboring intraparenchymal lesions and should be carried out in the everyday practice of neurosurgeons who specialize in glioma surgery.

By definition, the cerebral isthmus is a strip of white matter that anatomically and functionally connects the gray matter of the insula and central core with the remaining cerebral hemisphere.^{5,47} It consists of distinctive fiber

bundles that converge in a relatively narrow brain region situated between the periinsular sulcus and the lateral ventricle. With respect to its inherent nature, the cerebral isthmus proves to be one of the main white matter diffusion pathways through which gliomas spread.^{13,34,35,63,64,67} Thus, precise knowledge of the location, orientation, trajectory, and function of these tracts is mandatory to accomplish the aforementioned intellectual process and provide optimal neurosurgical management. This is of extreme importance when dealing with gliomas that reside in or extend to the insula and central core since the regional anatomy is complex and the function highly eloquent, thus rendering the surgical treatment a challenging procedure.

Although each of the fiber tracts that compose the cerebral isthmus has been thoroughly described in the past, their convergence and intermingling, eventually composing what we call the cerebral isthmus, has been rather incompletely investigated and illustrated. Interestingly, although modern and elegant neuroimaging studies, such as DTI, can adequately reconstruct and noninvasively map several fiber pathways, they are prone to multiple artifacts when applied to narrow and complex white matter areas due to the “crossing” and “termination” problems.^{17,18,22,29,59} Hence, we chose to study this anatomical entity through

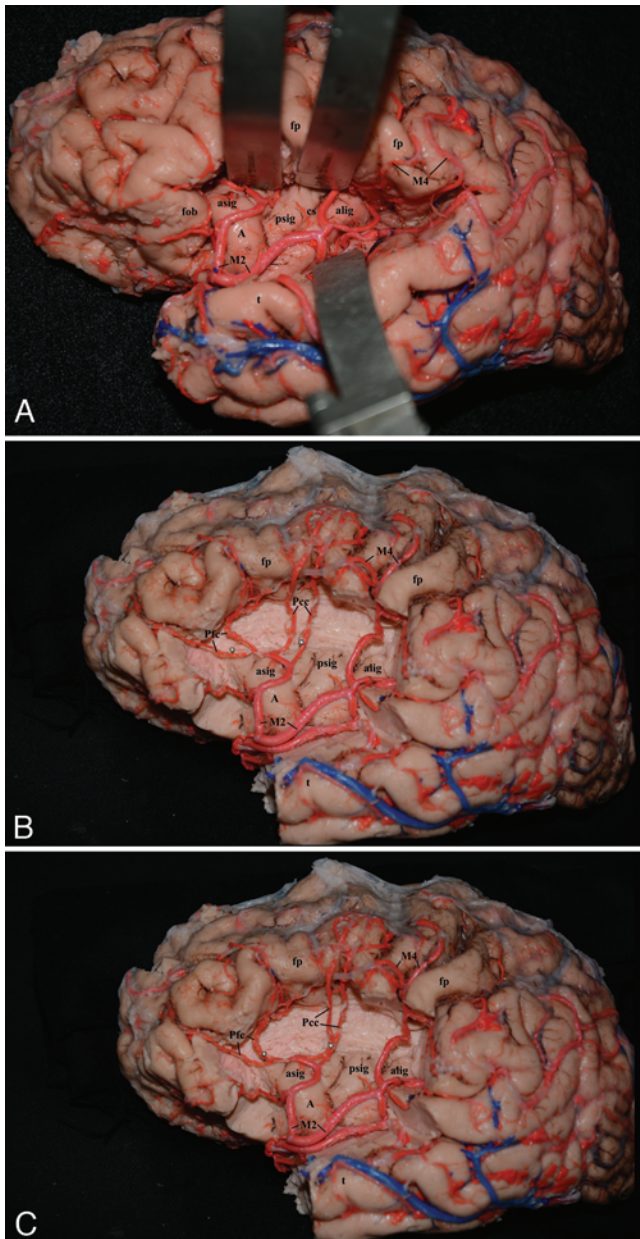


FIG. 6. Photographs of a left cerebral hemisphere injected with colored silicone for vascular enhancement, used for the application of the proximal superior transisthmic approach to the frontal horn. **A:** The opercula have been retracted to expose the insula and the MCA with its branches. The self-retaining retractors demarcate the level of the superior and inferior periinsular sulci. A wide dissection of both the proximal and distal rami of the sylvian fissure is mandatory to reveal the entire periinsular sulcus. **B:** The same specimen is shown, following removal of the frontoparietal and temporal opercula with preservation of the MCA branches lying over the superior periinsular sulcus. The pins demarcate the part of the superior periinsular sulcus that can be incised down to the frontal horn during the proximal superior transisthmic approach. The proximal pin indicates the anterior insular point. Attention must be paid to the vascular complex of the prefrontal and precentral arteries that interfere with the surgeon's view. **C:** The same specimen is shown following mobilization of the prefrontal and precentral arteries. The proximal part of the superior periinsular sulcus can now be safely incised down to the frontal horn. A = insular apex; alig = anterior long insular gyrus; asig = anterior short insular gyrus; cs = central sulcus of the insula; fob = frontoorbital operculum; fp = frontoparietal operculum; M2 = M₂ segment of the MCA; M4 = M₄ segment of the MCA; Pcc = precentral vascular complex; Pfc = prefrontal vascular complex; psig = posterior short insular gyrus; t = temporal operculum. Figure is available in color online only.

the fiber dissection technique since it provides a 3D knowledge of both the gray and white matter anatomy simultaneously, and we further discuss its functional and surgical significance.

Microsurgical Anatomy of the Cerebral Isthmus

The cerebral isthmus is defined as the white matter zone between the periinsular or circular sulcus and the lateral ventricular system.^{5,47} It is topographically divided into 3 segments: anterior, superior, and inferior. The anterior isthmus is located between the anterior periinsular sulcus and the frontal horn; the superior isthmus is situated between the superior periinsular sulcus and the frontal horn, body, and superior part of the atrium; and the inferior isthmus covers the area between the inferior periinsular sulcus and the inferior part of the atrium and temporal horn.^{5,47}

Even though it is a narrow white matter band, the ce-

rebral isthmus is composed of several distinct fiber tracts and fasciculi organized in specific layers. Therefore, the anterior and superior isthmuses consist of 3 fiber layers, while the inferior isthmus has 4 layers. More specifically, in a lateromedial direction, the anterior isthmus comprises the extreme capsule, the external capsule, the anterosuperior part of both the uncinate and occipitofrontal fasciculi, and the proximal fibers of the anterior limb of the internal capsule. The superior isthmus in turn contains the extreme capsule, the external capsule, the remaining part of the anterior limb of the internal capsule, the genu, and posterior limb. Finally, the inferior isthmus is formed by the extreme capsule, the external capsule, the posteroinferior parts of the uncinate and occipitofrontal fasciculi, the retrolenticular and sublenticular limbs of the internal capsule, the anterior commissure, and the tapetum.

It must be emphasized that the inferior cerebral isthmus

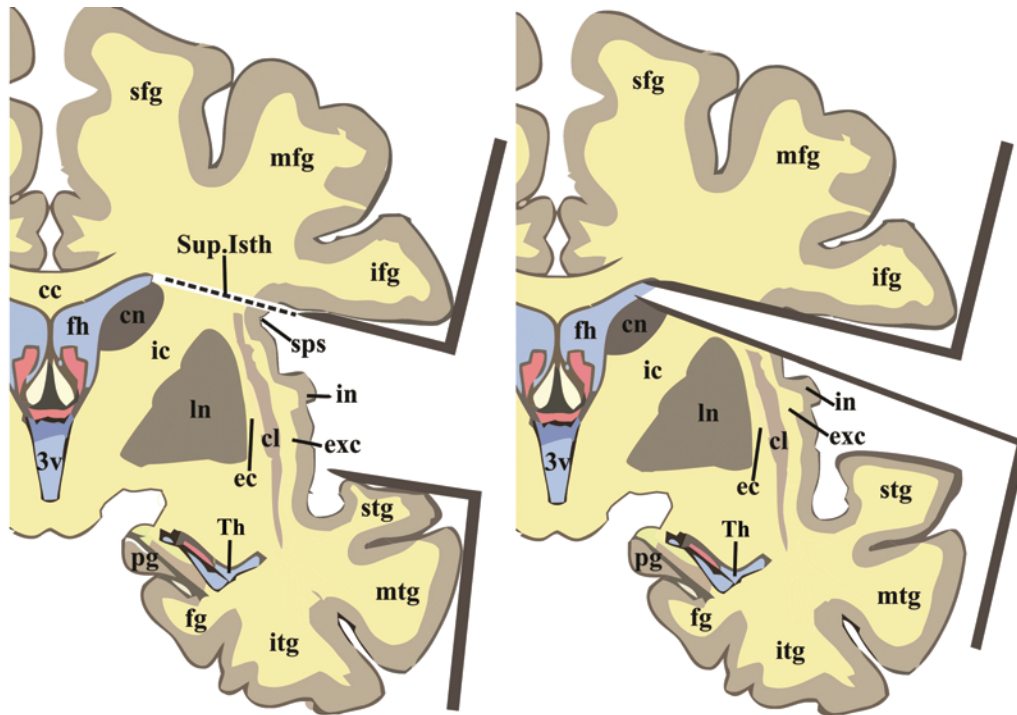


FIG. 7. Schematic drawings showing coronal sections of a hemisphere at the level of the proximal part of the superior periinsular sulcus. **Left:** The direction of the spatula retracting the inferior frontal gyrus indicates the ideal surgical trajectory that facilitates safe entry to the frontal horn, without violating the adjacent head of the caudate nucleus. **Right:** This angle of brain transgression was measured to be 10° off the plane of the surgeon's view. cc = corpus callosum; cl = claustrum; cn = caudate nucleus; ec = external capsule; exc = extreme capsule; fg = fusiform gyrus; fh = frontal horn; ic = internal capsule; ifg = inferior frontal gyrus; in = insula; itg = inferior temporal gyrus; ln = lentiform nucleus; mfg = middle frontal gyrus; mtg = middle temporal gyrus; pg = parahippocampal gyrus; sfg = superior frontal gyrus; sps = superior periinsular sulcus; stg = superior temporal gyrus; Sup.Isth = superior isthmus; Th = temporal horn; 3v = third ventricle. Copyright Christos Koutsarnakis. Published with permission. Figure is available in color online only.

and the temporal stem, although very similar in terms of location and white matter composition, are in fact discrete anatomical entities. While both originate at the level of the limen insula, the temporal stem ends up at the level of the intersection point of the gyrus of Heschl and the inferior periinsular sulcus (the surface landmark of the lateral geniculate body), whereas the inferior isthmus extends to the level of the posterior insular point.^{25,59} According to the study measurements, the average length of the temporal stem and that of the inferior isthmus are 32 and 46 mm, respectively. Regarding their differences in white matter fiber tract composition, the former contains the anterior bundle of the optic radiation, i.e., Meyer's loop, whereas the latter includes the entire optic radiation.^{14,42,44,45,50} It is, therefore, delineated that the temporal stem actually forms the anterior part of the inferior cerebral isthmus.

Anatomofunctional Significance of the Cerebral Isthmus

Functionally, the significance of each part of the cerebral isthmus is directly related to its fiber tract and white matter layer anatomy. Thus, the first layer—the extreme capsule—is common in all 3 segments of the isthmus and lies just beneath the gray matter of the periinsular sulcus. Recent *in vivo* imaging studies in humans demonstrated its role in connecting the caudal orbitofrontal cortex and inferior frontal gyrus to the middle third of the superior temporal gyrus. Furthermore, increasing evidence deriving from experimental studies in primates has led to the

hypothesis that the extreme capsule participates in the ventral language pathway along with the middle longitudinal fasciculus.³³

The second layer of the cerebral isthmus, namely the external capsule, forms the projection fiber system between the claustrum and the cerebral cortex. Recent studies have highlighted its implication in the integration of the neuronal correlate of consciousness, since it highly connects the claustrum with multiple cortical areas in a reciprocal manner.^{6,19} Additionally, the second layer of both the anterior and inferior isthmuses includes 2 long association fiber tracts, the inferior occipitofrontal and uncinate fasciculi. The former connects, anatomically and functionally, the frontal lobe (orbitofrontal and prefrontal cortex) to the temporal lobe (posterolateral area of middle and inferior temporal gyri and fusiform gyri) and occipital lobe (lingual gyrus).^{3,18,35,39} It courses through the superior two-thirds of the anterior isthmus in the frontal lobe, dorsal to the uncinate fasciculus at the level of the limen insula, and through the posterior two-thirds of the inferior isthmus to end up at the temporal and occipital lobes.^{3,4,17,18} Increasing evidence deriving from intraoperative subcortical electrostimulation in glioma surgery highlights its role in the semantic component of the language pathway.^{11,12,35} The uncinate fasciculus is, in turn, situated ventrally to the occipitofrontal fasciculus, occupying the most anterior and inferior parts of the inferior and anterior isthmuses, respectively. It courses, in a hook-like manner, from the frontal to the temporal

lobe connecting the gyrus rectus, the medial, lateral, and posterior orbitofrontal gyri to the temporal pole, amygdala, uncus, anterior part of the hippocampus, and lateral temporal gyri.¹⁵ Current research in epilepsy and psychiatric disorders highlights its implication in memory, language, and behavioral/emotional functions.^{18,57}

The third layer of the cerebral isthmus consists of the internal capsule and the anterior commissure, the latter participating only in the formation of the inferior isthmus. The internal capsule is the major projection fiber system of the human brain, connecting the cerebral cortex to the brainstem and basal ganglia. It is divided into the anterior limb, genu, posterior limb, and retrolenticular and sublenticular parts.^{18,39,47} The anterior limb is a component of the anterior and superior isthmuses; the genu and posterior limb are included in the superior isthmus, whereas the sub- and retrolenticular limbs are incorporated in the inferior isthmus.

Each part of the internal capsule has distinct anatomical and functional characteristics. Hence, the anterior limb of the internal capsule contains the anterior thalamic peduncle along with frontopontine fibers and is functionally related to set shifting. Set shifting is the ability to dynamically change focus and attention between different environmental stimuli and is essentially a reflection of cognitive flexibility.^{37,38} DTI studies in healthy subjects and research in the field of bipolar disorder and major depression have documented the aforementioned anatomofunctional correlation.^{20,27,30,51,70,71} Furthermore, human studies using electrical stimulation have indicated reciprocal connections between the anterior limb of the internal capsule and the dorsolateral and ventrolateral prefrontal cortex, findings consistent with anatomical tracing research in nonhuman primates.³² The genu of the internal capsule in turn contains pyramidal fibers that connect the precentral gyrus to the motor nuclei of the cranial nerves, and also the anterior part of the superior thalamic peduncle. Functionally, the genu serves swallowing, facial expression, eye movement, and oral-buccal motor activity.⁴⁷ The posterior limb is composed of corticospinal, corticopontine, and corticogemental fibers along with the remaining part of the superior thalamic peduncle and controls the motor and sensory functions of the contralateral half of the body.⁴⁷ The retrolenticular limb includes parietopontine, occipitopontine, and posterior thalamic peduncle fibers.^{18,55} Functionally, the role of the occipitopontine and parietopontine fibers remains unclear, whereas the posterior thalamic peduncle, since mainly composed of the optic radiation, conveys visual stimuli from the contralateral half of the visual field to the cerebral cortex of the lips of the calcarine fissure. Finally, the sublenticular limb, the last part of the internal capsule, comprises the anterior bundle of the optic radiation, i.e., Meyer's loop, the auditory radiation, and the temporopontine fibers.^{18,55} Meyer's loop serves the contralateral superior quadrant of the visual field whereas auditory radiations convey auditory stimuli from the medial geniculate body to the primary auditory cortex located in the Heschl gyrus.^{46,47} The role of the temporopontine fibers has not been thoroughly elucidated.

Regarding the function of the anterior commissure, which participates in the third layer of the inferior isthmus, it seems to connect both the temporal and occipital lobes

with the contralateral ones. Increasing evidence derived from DTI studies in humans suggests the anterior commissure's implication in language processing. However, its comprehensive role continues to remain obscure.^{18,40}

The fourth white matter layer is present only in the inferior isthmus and consists of the tapetum. The tapetum is formed primarily by splenial callosal radiations, arching over the lateral walls of the atrium and temporal horn. Although its function remains widely unclear, recent evidence arising from DTI studies in humans postulate its role in the pathway of language comprehension.^{48,56,58}

Summarizing, the anterior isthmus participates mainly in language and memory through the occipitofrontal and uncinate fasciculi. The superior isthmus serves the motor and sensory functions of the contralateral half of the body, since it contains the genu and posterior limb of the internal capsule. The inferior isthmus is intimately related to language processing, memory, and vision since it comprises the entire optic radiation along with parts of the occipitofrontal and uncinate fasciculi. It has to be noted that the anterior commissure, included in the third layer of the inferior isthmus, is the only white matter bundle of the cerebral isthmus that connects the cerebral hemispheres across the midline, hence participating in the generalization of seizure activity.¹⁸

The Surgical Significance of the Cerebral Isthmus and the Introduction of the Proximal Superior Transisthmus Approach to the Frontal Horn

Besides the utility of transecting the entire cerebral isthmus for the control of drug resistant pediatric epilepsy during functional hemispherectomy,^{2,28} the surgical significance of this narrow white matter area lies in its anatomical proximity to the lateral ventricle. As it is emphasized and demonstrated in most anatomical publications pertinent to insular anatomy,^{5,24,52,54} the width of the isthmus averages between 9 and 16 mm, thus rendering this structure a potential corridor in accessing ventricular and paraventricular areas.^{24,46} However, the eloquence of its composing fiber tracts (internal capsule, optic radiations, uncinate, and occipitofrontal fasciculi) along with the natural vascular barrier posed by the MCA offsets its advantageous anatomical location and limits its surgical implementation. Apparently, the development of delicate microneurosurgical techniques coupled with the application of the detailed and thorough neuroanatomical knowledge about the insula yielded new perspectives regarding the surgical utility of the cerebral isthmus. Surgery through the isthmus was popularized by Yaşargil with the evolution of the transylvian transinsular approach to the temporal horn.^{61,65,67,69} According to this approach the anterior one-third of the inferior periinsular sulcus is incised down to the temporal horn by transecting the proximal part of the inferior cerebral isthmus. Special emphasis must be placed not only on the extent of the incision but also on the surgical trajectory applied to access and selectively remove the amygdala and hippocampal head without damaging vital neural structures. So far, this is the only part of the entire cerebral isthmus that the neurosurgeon can dissect in order to explore a specific part of the ventricular system without major postoperative neurological deficit.^{60,65,69}

In our study we sought to determine additional safe surgical zones along the cerebral isthmus through which the lateral ventricles and adjacent structures can be effectively accessed. Interestingly, it was revealed that the proximal part of the superior isthmus can be safely incised down to the frontal horn by transgressing relatively noneloquent white matter pathways. More specifically, the proximal 2 to 2.5 cm of the superior cerebral isthmus, lying between the anterior insular point and the end of the middle short insular gyrus along the superior periinsular sulcus, are composed of fiber tracts (insuloopercular fibers, external capsule, and anterior limb of the internal capsule) that can be transected down to the frontal horn without major neurological sequelae. The average distance between this part of the periinsular sulcus and the frontal horn is 10.8 mm (ranging between 10 and 15 mm). The prefrontal and precentral branches of the MCA residing in this area pose a vascular barrier and must be carefully mobilized from their arachnoid adhesions. Special attention must be paid to the angle of the dissection, which should be directed up to 10° superiorly off the horizontal plane of the surgeon's view, to avoid inadvertent injury to the head of the caudate nucleus (Fig. 7).

To approach and dissect this part of the superior isthmus, an extended pterional craniotomy coupled with a wide splitting of the sylvian fissure are mandatory. Both the proximal and distal rami of the sylvian fissure must be meticulously opened, respecting the pial planes, the terminal branches of the MCA, and the overlying middle cerebral veins. Particularly, the distal part of the sylvian fissure is more difficult to split since the opposing opercula are more adherent and the risk of vascular, especially venous, injury is higher. Furthermore, the wide insular exposure facilitated by the entire sylvian fissure dissection necessitates the use of brain retractors to optimize surgical view and increase maneuverability. Widening the surgical corridor ensures adequate exposure of the insular surface and periinsular sulci while reducing the ill effects of brain retraction. Once the proximal part of the periinsular sulcus is reached, the frontal horn can be easily accessed through minimal brain transgression.

It has to be stressed that the proximal superior transisthmus approach to the frontal horn and adjacent area was the observational outgrowth of our anatomical study regarding the cerebral isthmus. Thus, we have performed and tested it exclusively in the setting of the microneurosurgery laboratory. Nonetheless, it features certain advantages, at least on a theoretical basis, when compared with the most commonly used approaches in anterior ventricular surgery, namely the anterior transcallosal and transcortical approaches.

More specifically and regarding surgical anatomy, the "transisthmus" approach shortens the distance to access pathological lesions located in or adjacent to the frontal horn compared with the transcallosal and transcortical variants, thus improving surgical maneuverability and dissection accuracy. Furthermore, the rather common "issue" of surgical orientation regarding which ventricle the surgeon has entered when using the transcallosal approach is eliminated with the transisthmus approach. This is crucial when exploring small lesions situated in the anterior part

of the frontal horn and when the regional pattern of ventricular venous anatomy is severely distorted. Additionally, the surgical limitations of the transcallosal and transcortical approaches regarding the access and treatment of an exclusively intraventricular lesion in the former along with the presence of ventriculomegaly to perform the latter are absent in the transisthmus approach.^{7,16,21} Theoretically, with the transisthmus approach the neurosurgeon can effectively treat both intra- and paraventricular lesions with minimal brain retraction, when the sylvian fissure is widely split, and maximal dissection accuracy since the surgical distance is reduced.

Moreover, from a functional perspective, since the transcortical and transcallosal approaches traverse the entire middle frontal gyrus and the anterior corpus callosum, respectively, they are prone to postoperative neurological and neuropsychological deficits. The former is related to the increased incidence of postoperative seizures due to the cortical incision involved while the latter has been associated with permanent impairment in long-term memory, deficits in the interhemispheric transfer of motor learning, and frontal disconnection syndrome.^{1,7,21,36,41,43} On the contrary, we postulate that the transisthmus approach, through the incision of the periinsular sulcus and the white matter of the proximal part of the superior isthmus, is advantageous when compared with the transcortical and transcallosal variants in terms of neuropsychological morbidity.

More specifically, the periinsular sulcus, since it is a paralimbic structure, is lined by mesocortex, which is less organized in terms of cytoarchitecture and thus phylogenetically older than the neocortex of the middle frontal gyrus.^{8,18,23,49,55,66} In this context it would be preferable to transgress a mesocortical structure, such as the periinsular sulcus, than recourse to the cortical incision of the frontal lobe when performing the transcortical approach. Additionally, we consider incising the proximal superior isthmus less destructive than the anterior corpus callosum, since the former is mainly related to the ability of set shifting while the latter participates in the vital functions of memory and learning.^{20,27,30,37,38,41,43,51,70,71}

Undoubtedly, approaching the frontal horn through the proximal part of the superior isthmus is not an easy and straightforward procedure. It requires thorough neuroanatomical knowledge of the insular anatomy, flawless microneurosurgical technique, and proper planning of the surgical trajectory. However, the proximal superior transisthmus approach shortens the surgical distance to lesions located in or adjacent to the frontal horn and minimizes brain transgression when compared with transcortical or transcallosal approaches. Theoretically it could be useful in the surgical treatment of intra- or paraventricular pathological entities, such as ependymomas, astrocytomas, lymphomas, choroid plexus papillomas, metastases, and cavernomas, but whether this approach can be safely extrapolated to real operative settings remains a project for future studies.

Conclusions

The cerebral isthmus, although a narrow strip of white matter, is composed of important and distinct fiber tracts

which anatomofunctionally connect the insular and central core gray matter with the remaining hemisphere. Profound knowledge of this intricate anatomy can only be obtained using the fiber dissection technique in combination with sectional cuts in cadaveric specimens. This is particularly true since the implementation of modern neuroimaging methods, such as DTI, cannot reveal the 3D anatomical perplexity of narrow and delicate areas. The significance of the proximal part of the superior isthmus as a surgical corridor to the frontal horn and paraventricular area is emphasized but should be definitely further investigated.

References

1. Asgari S, Engelhorn T, Brondics A, Sandalcioglu IE, Stolke D: Transcortical or transcallosal approach to ventricle-associated lesions: a clinical study on the prognostic role of surgical approach. *Neurosurg Rev* **26**:192–197, 2003
2. Binder DK, Schramm J: Transsylvian functional hemispherectomy. *Childs Nerv Syst* **22**:960–966, 2006
3. Catani M, Howard RJ, Pajevic S, Jones DK: Virtual in vivo interactive dissection of white matter fasciculi in the human brain. *Neuroimage* **17**:77–94, 2002
4. Catani M, Jones DK, ffytche DH: Perisylvian language networks of the human brain. *Ann Neurol* **57**:8–16, 2005
5. Choi CY, Han SR, Yee GT, Lee CH: Central core of the cerebrum. *J Neurosurg* **114**:463–469, 2011
6. Crick FC, Koch C: What is the function of the claustrum? *Philos Trans R Soc Lond B Biol Sci* **360**:1271–1279, 2005
7. D'Angelo VA, Galarza M, Catapano D, Monte V, Bisceglia M, Carosi I: Lateral ventricle tumors: surgical strategies according to tumor origin and development—a series of 72 cases. *Neurosurgery* **56** (1 Suppl):36–45, 2005
8. Dennis EL, Jahanshad N, McMahon KL, de Zubicaray GI, Martin NG, Hickie IB, et al: Development of insula connectivity between ages 12 and 30 revealed by high angular resolution diffusion imaging. *Hum Brain Mapp* **35**:1790–1800, 2014
9. Duffau H: New concepts in surgery of WHO grade II gliomas: functional brain mapping, connectionism and plasticity—a review. *J Neurooncol* **79**:77–115, 2006
10. Duffau H, Capelle L, Lopes M, Faillot T, Sichez JP, Fohanno D: The insular lobe: physiopathological and surgical considerations. *Neurosurgery* **47**:801–811, 2000
11. Duffau H, Gatignol P, Mandonnet E, Capelle L, Taillandier L: Intraoperative subcortical stimulation mapping of language pathways in a consecutive series of 115 patients with Grade II glioma in the left dominant hemisphere. *J Neurosurg* **109**:461–471, 2008
12. Duffau H, Gatignol P, Mandonnet E, Peruzzi P, Tzourio-Mazoyer N, Capelle L: New insights into the anatomofunctional connectivity of the semantic system: a study using cortico-subcortical electrostimulations. *Brain* **128**:797–810, 2005
13. Duffau H, Khalil I, Gatignol P, Denvil D, Capelle L: Surgical removal of corpus callosum infiltrated by low-grade glioma: functional outcome and oncological considerations. *J Neurosurg* **100**:431–437, 2004
14. Ebeling U, Reulen HJ: Neurosurgical topography of the optic radiation in the temporal lobe. *Acta Neurochir (Wien)* **92**:29–36, 1988
15. Ebeling U, von Cramon D: Topography of the uncinate fascicle and adjacent temporal fiber tracts. *Acta Neurochir (Wien)* **115**:143–148, 1992
16. Ellenbogen RG: Transcortical surgery for lateral ventricular tumors. *Neurosurg Focus* **10**(6):E2, 2001
17. Fernández-Miranda JC, Pathak S, Engh J, Jarbo K, Verstyne T, Yeh FC, et al: High-definition fiber tractography of the human brain: neuroanatomical validation and neurosurgical applications. *Neurosurgery* **71**:430–453, 2012
18. Fernández-Miranda JC, Rhoton AL Jr, Alvarez-Linera J, Kakizawa Y, Choi C, de Oliveira EP: Three-dimensional microsurgical and tractographic anatomy of the white matter of the human brain. *Neurosurgery* **62** (6 Suppl 3):989–1028, 2008
19. Fernández-Miranda JC, Rhoton AL Jr, Kakizawa Y, Choi C, Alvarez-Linera J: The claustrum and its projection system in the human brain: a microsurgical and tractographic anatomical study. *J Neurosurg* **108**:764–774, 2008
20. Greenberg BD, Malone DA, Friehs GM, Rezai AR, Kubu CS, Malloy PF, et al: Three-year outcomes in deep brain stimulation for highly resistant obsessive-compulsive disorder. *Neuropsychopharmacology* **31**:2384–2393, 2006
21. Jeeves MA, Simpson DA, Geffen G: Functional consequences of the transcallosal removal of intraventricular tumours. *J Neurol Neurosurg Psychiatry* **42**:134–142, 1979
22. Johansen-Berg H, Rushworth MF: Using diffusion imaging to study human connective anatomy. *Annu Rev Neurosci* **32**:75–94, 2009
23. Kalani MY, Kalani MA, Gwinn R, Keogh B, Tse VC: Embryological development of the human insula and its implications for the spread and resection of insular gliomas. *Neurosurg Focus* **27**(2):E2, 2009
24. Kaneko N, Boling WW, Shonai T, Ohmori K, Shiokawa Y, Kurita H, et al: Delineation of the safe zone in surgery of sylvian insular triangle: morphometric analysis and magnetic resonance imaging study. *Neurosurgery* **70** (2 Suppl Operative):290–299, 2012
25. Kier EL, Staib LH, Davis LM, Bronen RA: MR imaging of the temporal stem: anatomic dissection tractography of the uncinate fasciculus, inferior occipitofrontal fasciculus, and Meyer's loop of the optic radiation. *AJNR Am J Neuroradiol* **25**:677–691, 2004
26. Klingler J: Erleichterung der makroskopischen Präparation des Gehirns durch den Gefrierprozeß. *Schweiz Arch Neurol Psychiatr* **36**:247–256, 1935
27. Koch K, Reess TJ, Rus OG, Zimmer C, Zaudig M: Diffusion tensor imaging (DTI) studies in patients with obsessive-compulsive disorder (OCD): a review. *J Psychiatr Res* **54**:26–35, 2014
28. Kucukyuruk B, Yagmurlu K, Tanriover N, Uzan M, Rhoton AL Jr: Microsurgical anatomy of the white matter tracts in hemispherotomy. *Neurosurgery* **10** (Suppl 2):305–324, 2014
29. Le Bihan D, Poupon C, Amadon A, Lethimonnier F: Artifacts and pitfalls in diffusion MRI. *J Magn Reson Imaging* **24**:478–488, 2006
30. Linke J, King AV, Poupon C, Hennerici MG, Gass A, Wessa M: Impaired anatomical connectivity and related executive functions: differentiating vulnerability and disease marker in bipolar disorder. *Biol Psychiatry* **74**:908–916, 2013
31. Ludwig E, Klingler J: *Atlas Cerebri Humani*. Basel: S. Karger, Inc., 1956
32. Machado A, Haber S, Sears N, Greenberg B, Malone D, Rezai A: Functional topography of the ventral striatum and anterior limb of the internal capsule determined by electrical stimulation of awake patients. *Clin Neurophysiol* **120**:1941–1948, 2009
33. Makris N, Pandya DN: The extreme capsule in humans and rethinking of the language circuitry. *Brain Struct Funct* **213**:343–358, 2009
34. Mandonnet E, Capelle L, Duffau H: Extension of paralimbic low grade gliomas: toward an anatomical classification based on white matter invasion patterns. *J Neurooncol* **78**:179–185, 2006
35. Martino J, Vergani F, Robles SG, Duffau H: New insights into the anatomic dissection of the temporal stem with special emphasis on the inferior fronto-occipital fasciculus:

- implications in surgical approach to left mesiotemporal and temporoinular structures. **Neurosurgery** **66** (3 Suppl **Operative**):4–12, 2010
36. Mazza M, Di Rienzo A, Costagliola C, Roncone R, Casacchia M, Ricci A, et al: The interhemispheric transcallosal-transversal approach to the lesions of the anterior and middle third ventricle: surgical validity and neuropsychological evaluation of the outcome. **Brain Cogn** **55**:525–534, 2004
 37. Milner B: Effects of different brain lesions on card sorting: The role of the frontal lobes. **Arch Neurol** **9**:90–100, 1963
 38. Moore TL, Schettler SP, Killiany RJ, Rosene DL, Moss MB: Effects on executive function following damage to the prefrontal cortex in the rhesus monkey (*Macaca mulatta*). **Behav Neurosci** **123**:231–241, 2009
 39. Nieuwenhuys R, Voogd J, van Huijzen C: **The Human Central Nervous System**, ed 4. Berlin: Springer, 2008
 40. Northam GB, Liégeois F, Tournier JD, Croft LJ, Johns PN, Chong WK, et al: Interhemispheric temporal lobe connectivity predicts language impairment in adolescents born preterm. **Brain** **135**:3781–3798, 2012
 41. Peltier J, Roussel M, Gerard Y, Lassonde M, Deramond H, Le Gars D, et al: Functional consequences of a section of the anterior part of the body of the corpus callosum: evidence from an interhemispheric transcallosal approach. **J Neurol** **259**:1860–1867, 2012 (Erratum in **J Neurol** **260**:1199, 2013)
 42. Peltier J, Travers N, Destrieux C, Velut S: Optic radiations: a microsurgical anatomical study. **J Neurosurg** **105**:294–300, 2006
 43. Peltier J, Vercllytte S, Delmaire C, Deramond H, Pruvo JP, Le Gars D, et al: Microsurgical anatomy of the ventral callosal radiations: new destination, correlations with diffusion tensor imaging fiber-tracking, and clinical relevance. **J Neurosurg** **112**:512–519, 2010
 44. Peltier J, Vercllytte S, Delmaire C, Pruvo JP, Godefroy O, Le Gars D: Microsurgical anatomy of the temporal stem: clinical relevance and correlations with diffusion tensor imaging fiber tracking. **J Neurosurg** **112**:1033–1038, 2010
 45. Peuskens D, van Loon J, Van Calenbergh F, van den Bergh R, Goffin J, Plets C: Anatomy of the anterior temporal lobe and the frontotemporal region demonstrated by fiber dissection. **Neurosurgery** **55**:1174–1184, 2004
 46. Potts MB, Chang EF, Young WL, Lawton MT: Transsylvian-transinsular approaches to the insula and basal ganglia: operative techniques and results with vascular lesions. **Neurosurgery** **70**:824–834, 2012
 47. Rhoton AL Jr: The cerebrum. **Neurosurgery** **51** (4 Suppl):S1–S51, 2002
 48. Rhoton AL Jr: The lateral and third ventricles. **Neurosurgery** **51** (4 Suppl):S207–S271, 2002
 49. Ribas GC: The cerebral sulci and gyri. **Neurosurg Focus** **28**(2):E2, 2010
 50. Sincoff EH, Tan Y, Abdulrauf SI: White matter fiber dissection of the optic radiations of the temporal lobe and implications for surgical approaches to the temporal horn. **J Neurosurg** **101**:739–746, 2004
 51. Sullivan EV, Zahr NM, Rohlfing T, Pfefferbaum A: Fiber tracking functionally distinct components of the internal capsule. **Neuropsychologia** **48**:4155–4163, 2010
 52. Tanriover N, Rhoton AL Jr, Kawashima M, Ulm AJ, Yasuda A: Microsurgical anatomy of the insula and the sylvian fissure. **J Neurosurg** **100**:891–922, 2004
 53. Timurkaynak E, Rhoton AL Jr, Barry M: Microsurgical anatomy and operative approaches to the lateral ventricles. **Neurosurgery** **19**:685–723, 1986
 54. Türe U, Yaşargil MG, Al-Mefty O, Yaşargil MG: Topographic anatomy of the insular region. **J Neurosurg** **90**:720–733, 1999
 55. Türe U, Yaşargil MG, Friedman AH, Al-Mefty O: Fiber dissection technique: lateral aspect of the brain. **Neurosurgery** **47**:417–427, 2000
 56. Turken AU, Dronkers NF: The neural architecture of the language comprehension network: converging evidence from lesion and connectivity analyses. **Front Syst Neurosci** **5**:1, 2011
 57. Von Der Heide RJ, Skipper LM, Klobusicky E, Olson IR: Dissecting the uncinate fasciculus: disorders, controversies and a hypothesis. **Brain** **136**:1692–1707, 2013
 58. Wakana S, Jiang H, Nagae-Poetscher LM, van Zijl PC, Mori S: Fiber tract-based atlas of human white matter anatomy. **Radiology** **230**:77–87, 2004
 59. Wang F, Sun T, Li XG, Liu NJ: Diffusion tensor tractography of the temporal stem on the inferior limiting sulcus. **J Neurosurg** **108**:775–781, 2008
 60. Wieser HG, Siegel AM, Yaşargil GM: The Zürich amygdalo-hippocampectomy series: a short up-date. **Acta Neurochir Suppl (Wien)** **50**:122–127, 1990
 61. Wieser HG, Yaşargil MG: Selective amygdalohippocampectomy as a surgical treatment of mesiotemporal limbic epilepsy. **Surg Neurol** **17**:445–457, 1982
 62. Yaşargil MG: **Microneurosurgery**. Stuttgart: Thieme, 1984, Vol I
 63. Yaşargil MG: **Microneurosurgery**. Stuttgart: Thieme, 1994, Vol IVA
 64. Yaşargil MG: **Microneurosurgery**. Stuttgart: Thieme, 1995, Vol IVB
 65. Yaşargil MG, Krayenbühl N, Roth P, Hsu SP, Yaşargil DC: The selective amygdalohippocampectomy for intractable temporal limbic seizures. **J Neurosurg** **112**:168–185, 2010
 66. Yaşargil MG, Reeves JD: Tumours of the limbic and paralimbic system. **Acta Neurochir (Wien)** **116**:147–149, 1992
 67. Yaşargil MG, Türe U, Yaşargil DC: Impact of temporal lobe surgery. **J Neurosurg** **101**:725–738, 2004
 68. Yaşargil MG, Türe U, Yaşargil DC: Surgical anatomy of supratentorial midline lesions. **Neurosurg Focus** **18**(6B):E1, 2005
 69. Yaşargil MG, Wieser HG, Valavanis A, von Ammon K, Roth P: Surgery and results of selective amygdala-hippocampectomy in one hundred patients with nonlesional limbic epilepsy. **Neurosurg Clin N Am** **4**:243–261, 1993
 70. Zhang A, Leow A, Ajilore O, Lamar M, Yang S, Joseph J, et al: Quantitative tract-specific measures of uncinate and cingulum in major depression using diffusion tensor imaging. **Neuropsychopharmacology** **37**:959–967, 2012
 71. Zhu X, Wang X, Xiao J, Zhong M, Liao J, Yao S: Altered white matter integrity in first-episode, treatment-naive young adults with major depressive disorder: a tract-based spatial statistics study. **Brain Res** **1369**:223–229, 2011

Disclosure

The authors report no conflict of interest concerning the materials or methods used in this study or the findings specified in this paper.

Author Contributions

Conception and design: Koutsarnakis, Liakos. Acquisition of data: Koutsarnakis, Liakos, Themistoklis. Analysis and interpretation of data: Koutsarnakis, Liakos, Liouta. Drafting the article: Koutsarnakis. Critically revising the article: Sakas, Stranjalis. Administrative/technical/material support: Stranjalis. Study supervision: Koutsarnakis, Stranjalis.

Correspondence

Christos Koutsarnakis, Department of Neurosurgery, University of Athens, Evangelismos Hospital, Ipsilantou 45-47, 10676 Athens, Greece. email: ckouts@hotmail.co.uk.