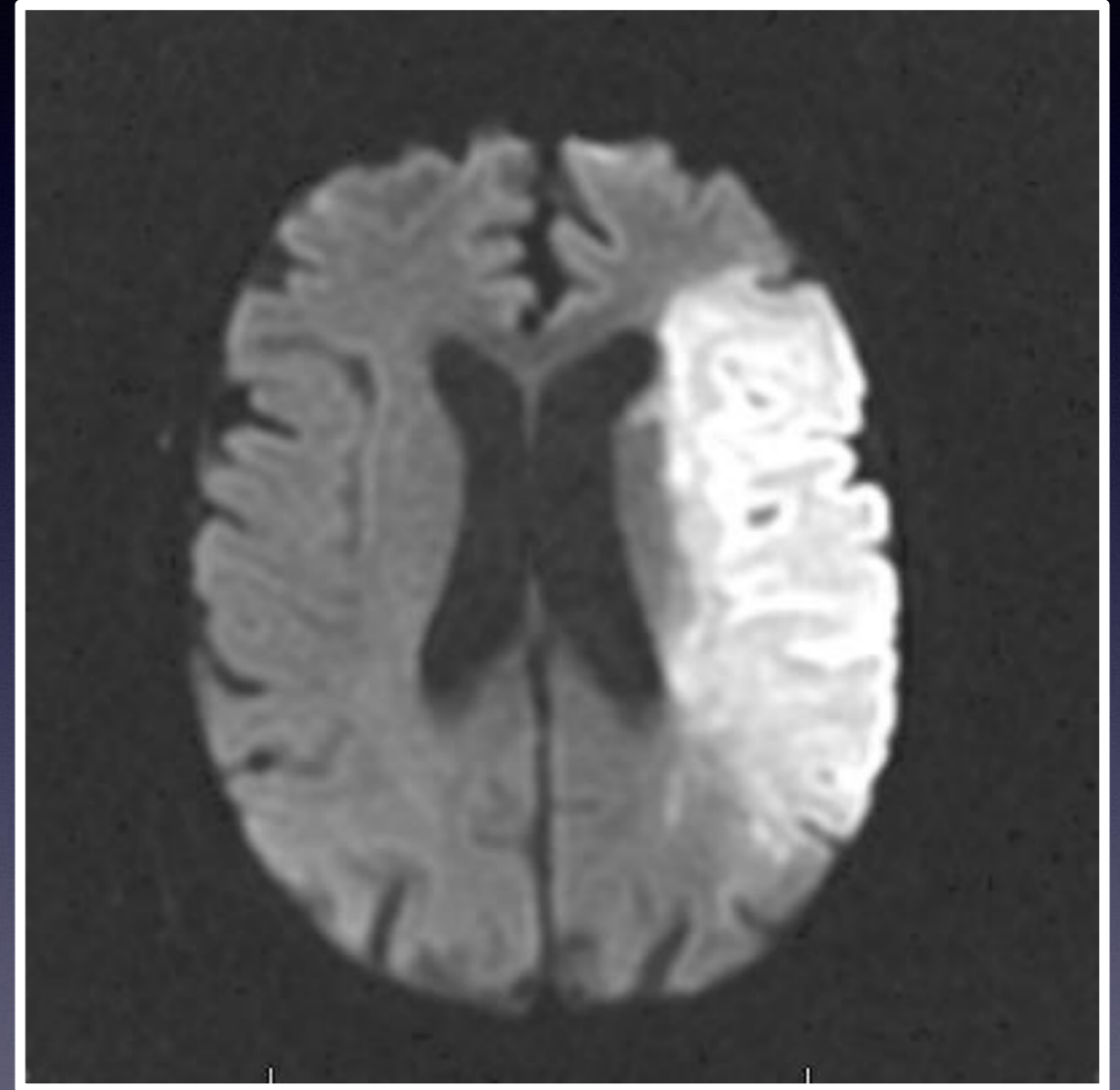
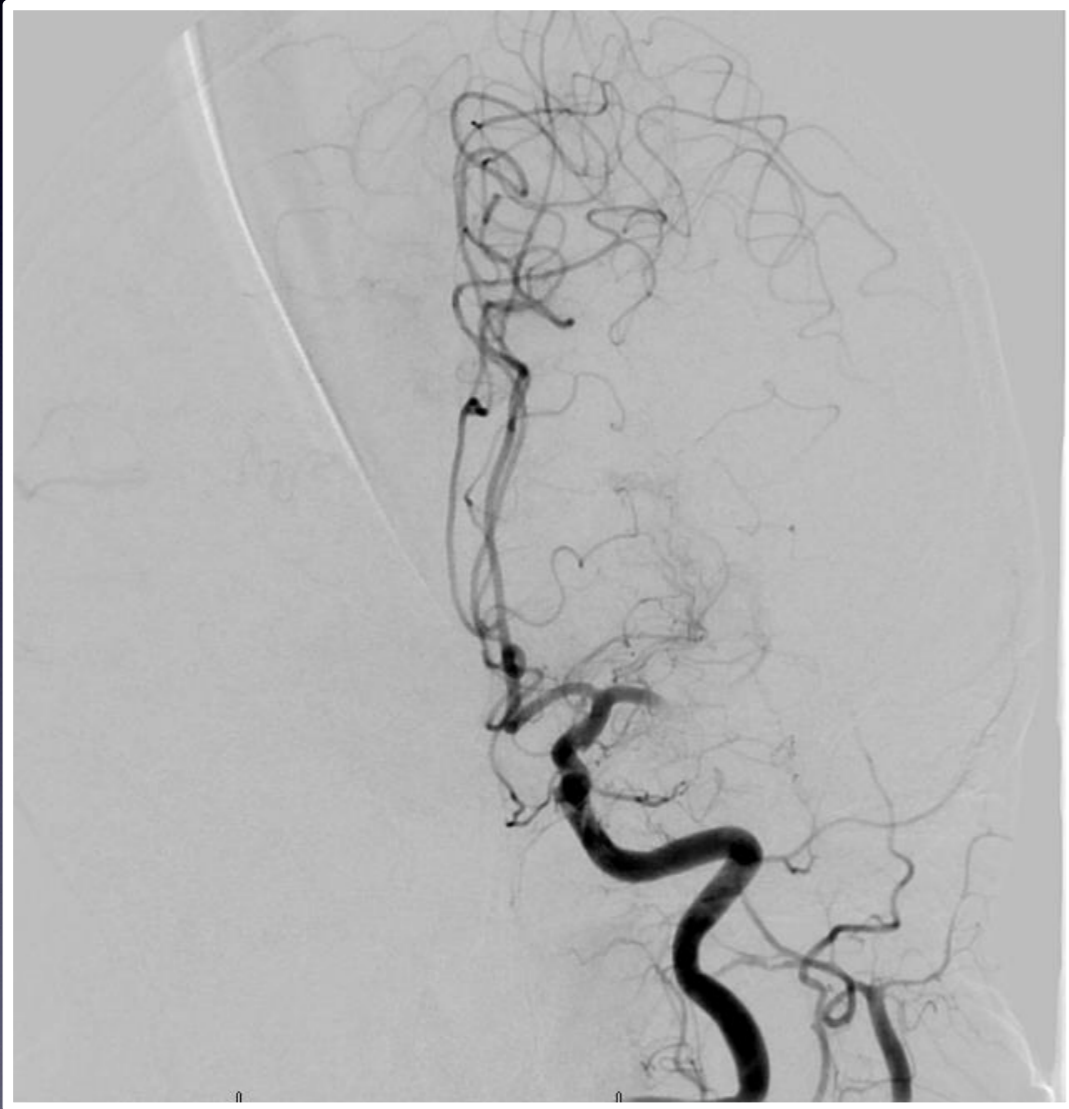

**ΑΠΕΙΚΟΝΙΣΗ ΑΓΓΕΙΑΚΩΝ  
ΕΓΚΕΦΑΛΙΚΩΝ ΕΠΕΙΣΟΔΙΩΝ ΚΑΙ  
ΑΝΕΥΡΥΣΜΑΤΩΝ**

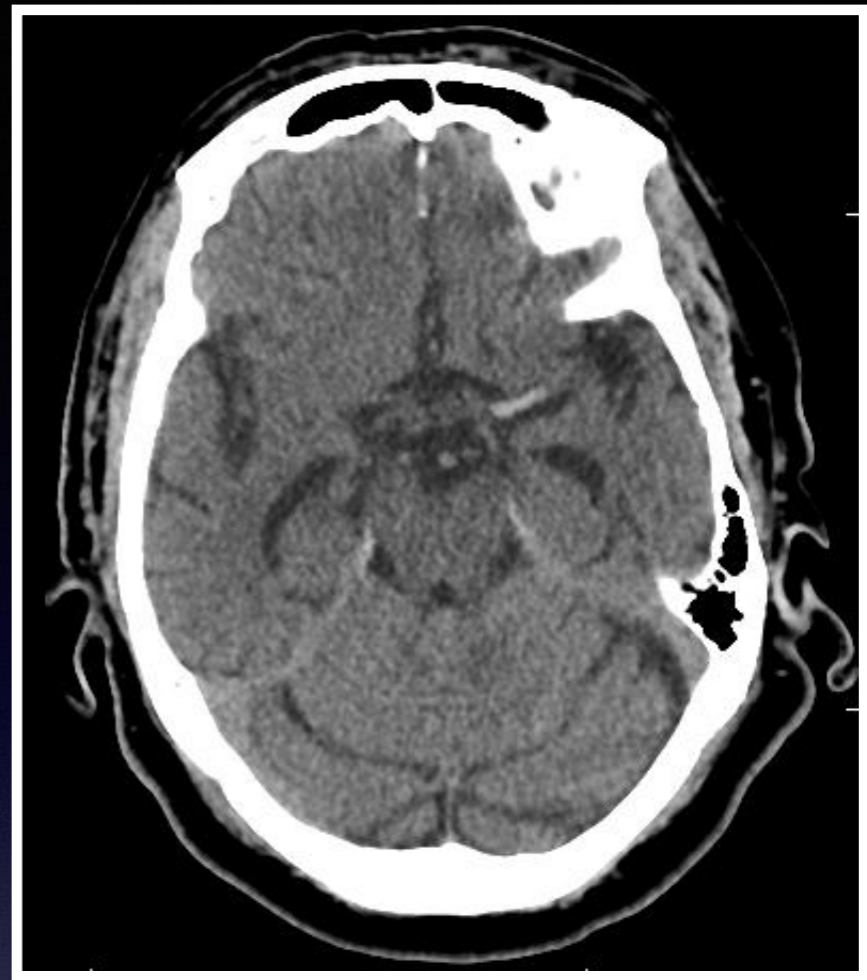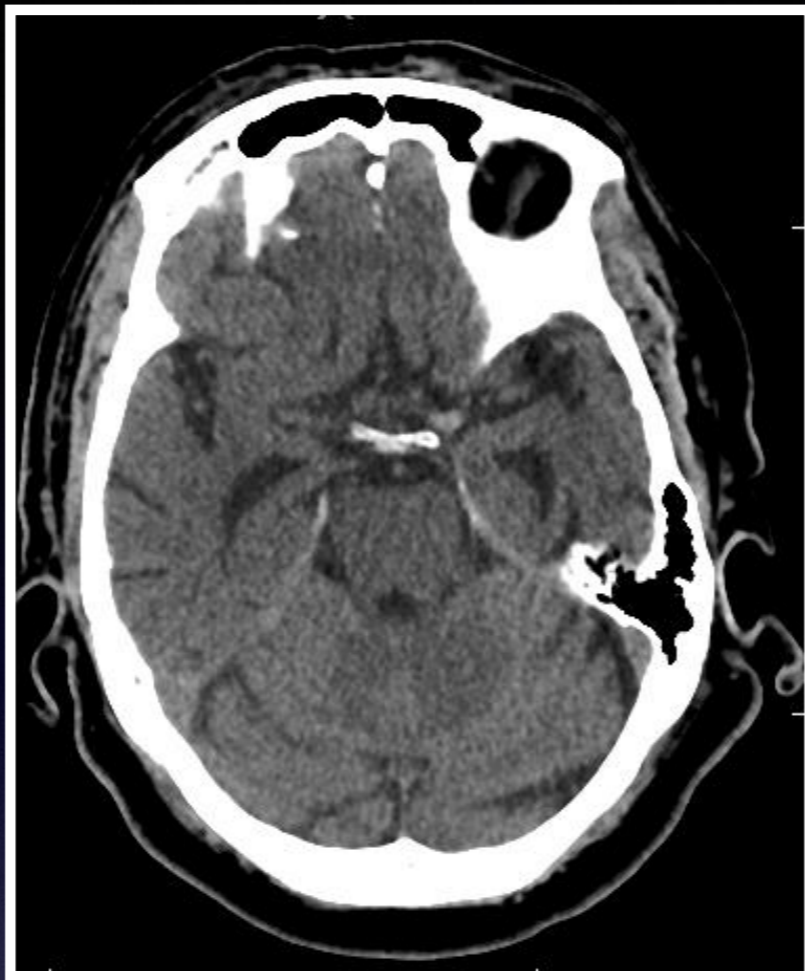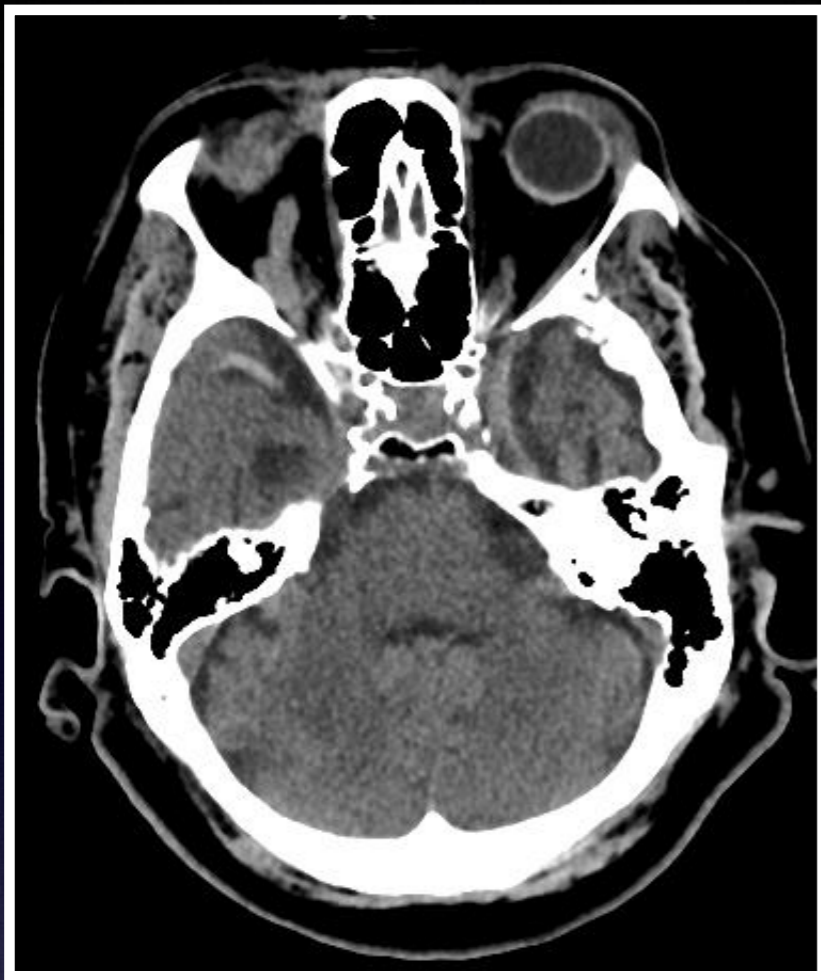*Χρήστος Γκόγκας,  
Επεμβατικός Νευροακτινολόγος*

# Ischemic Stroke



# Acute Stroke

- What is the role of imaging?

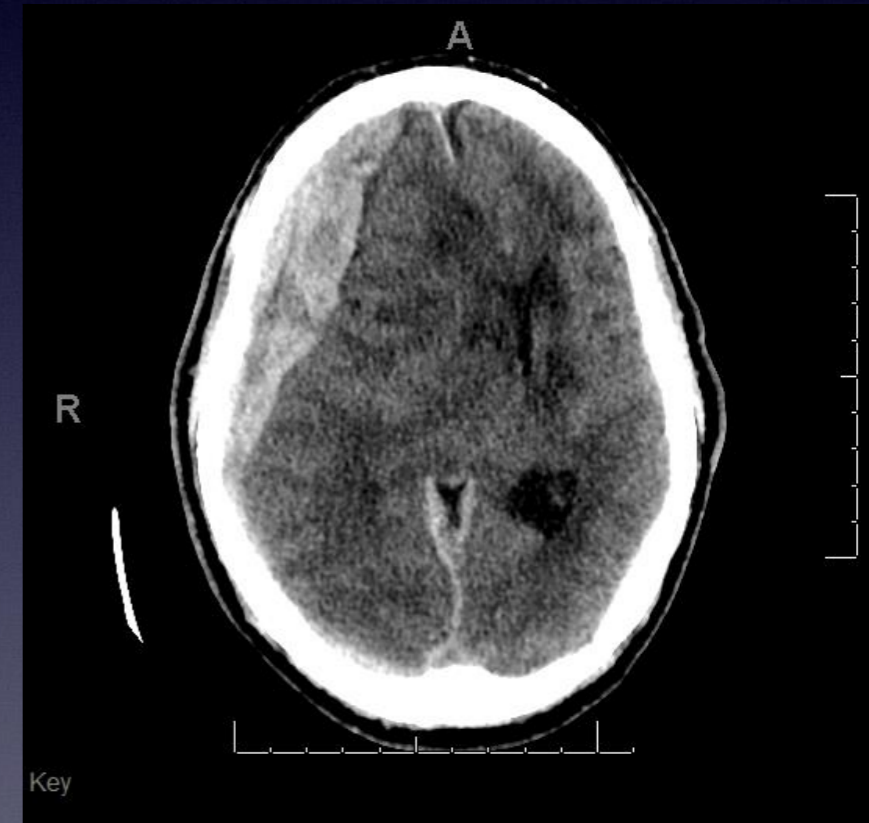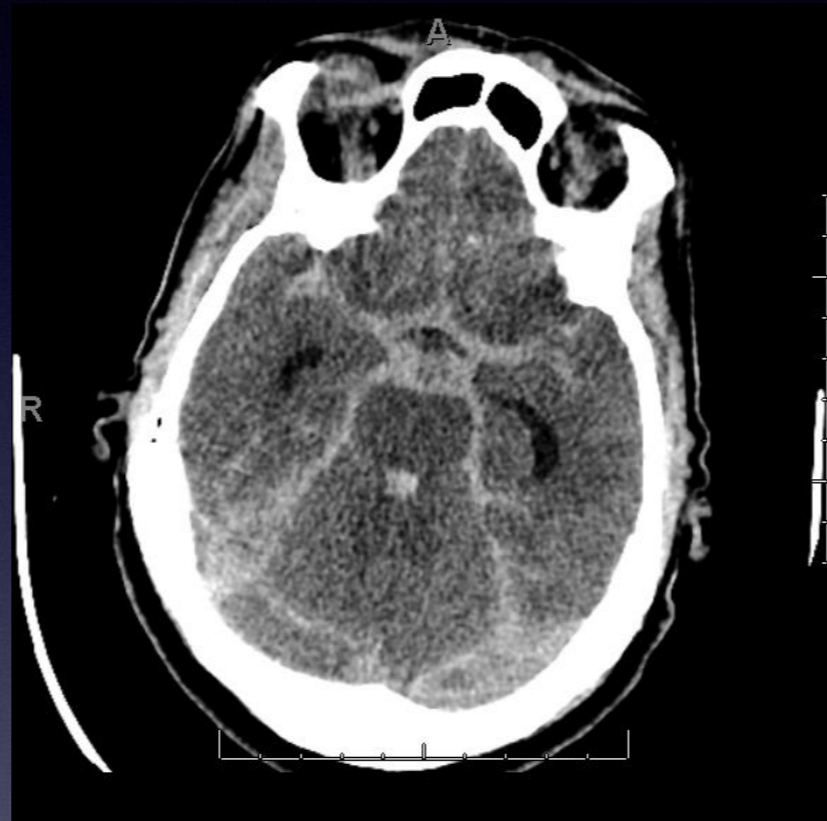

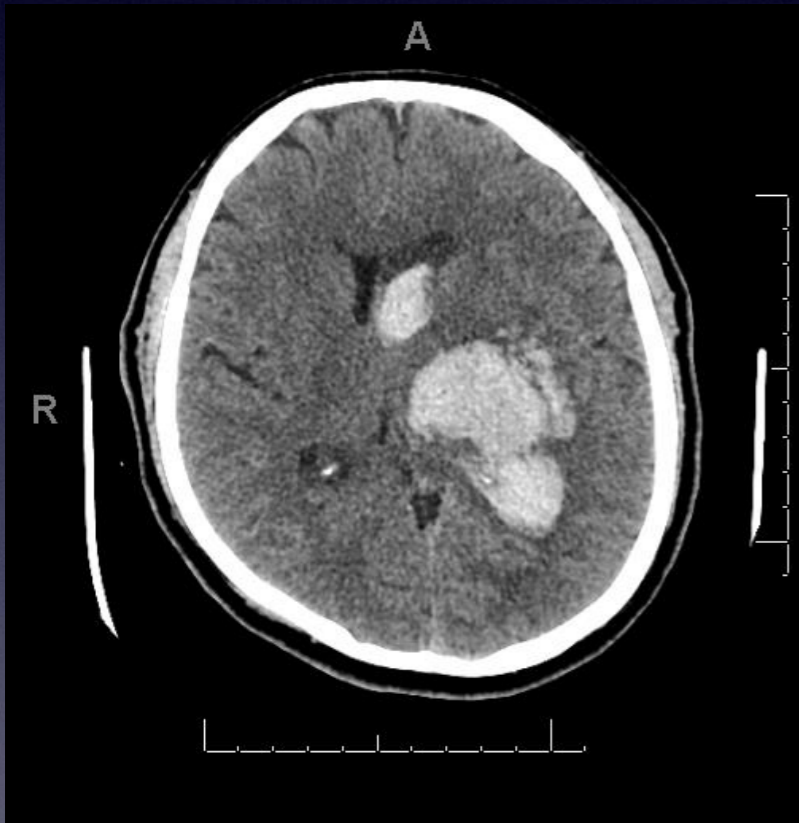
84 yo with sudden loss of consciousness, GCS 4

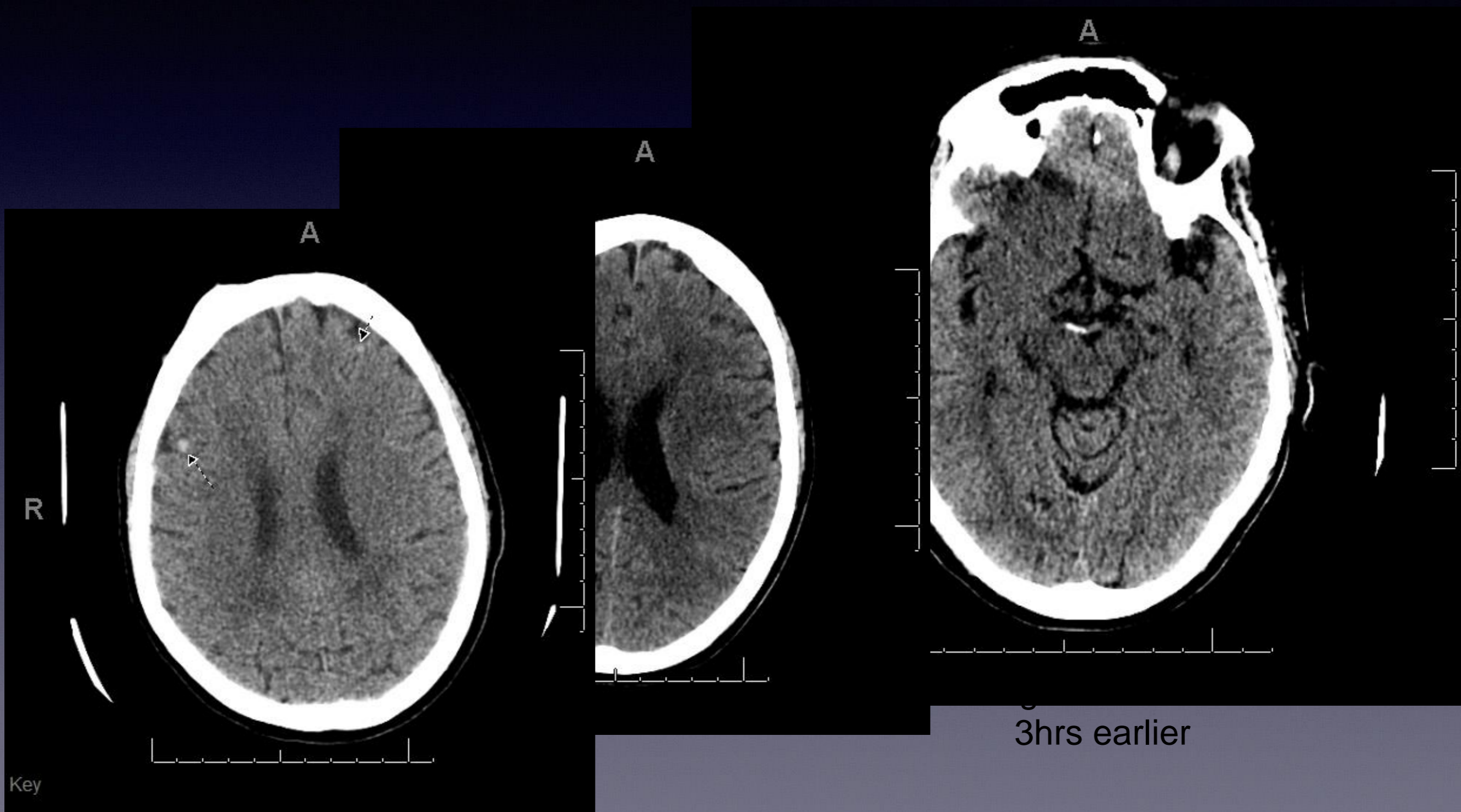
# I. What is the role of imaging?

- Patient with acute onset neurologic deficit.
  - Rule-out hemorrhage
  - Rule out other pathology
  - Identify and quantify early ischemic changes

# Rule-out hemorrhage

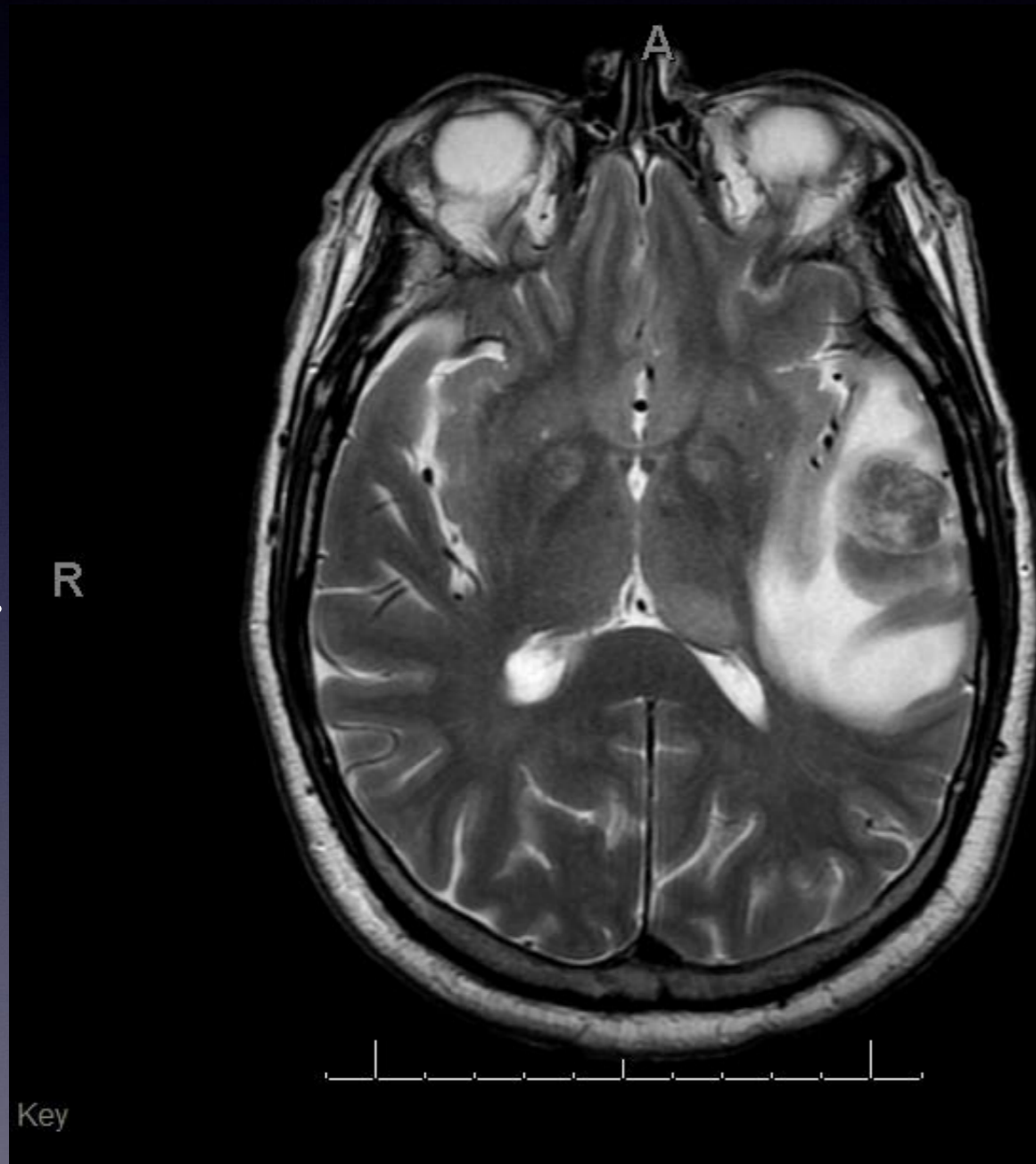


# I. What is the role of imaging?

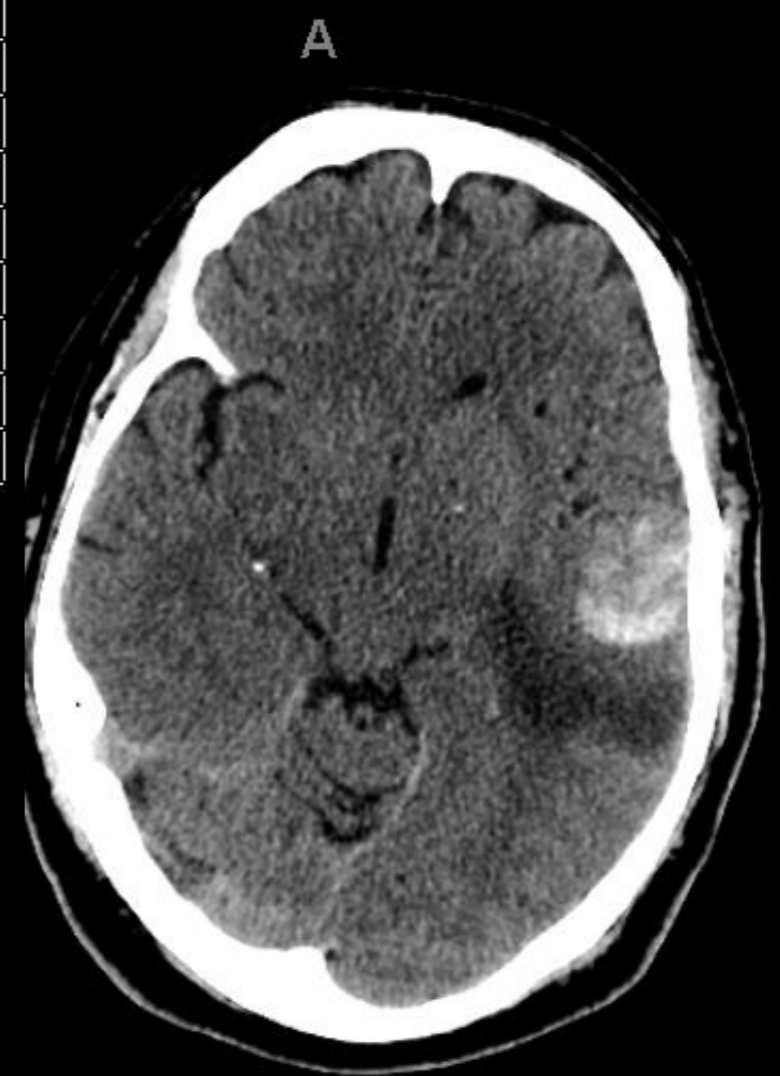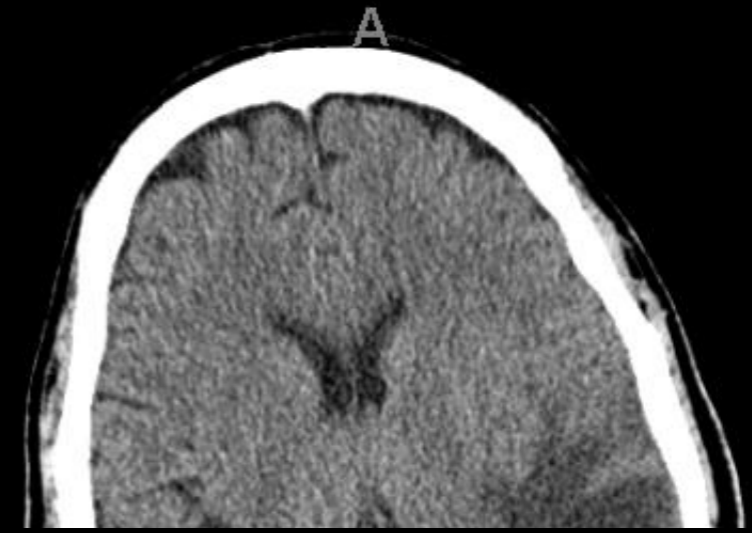


# I. What is the role of imaging?

1. R



Key

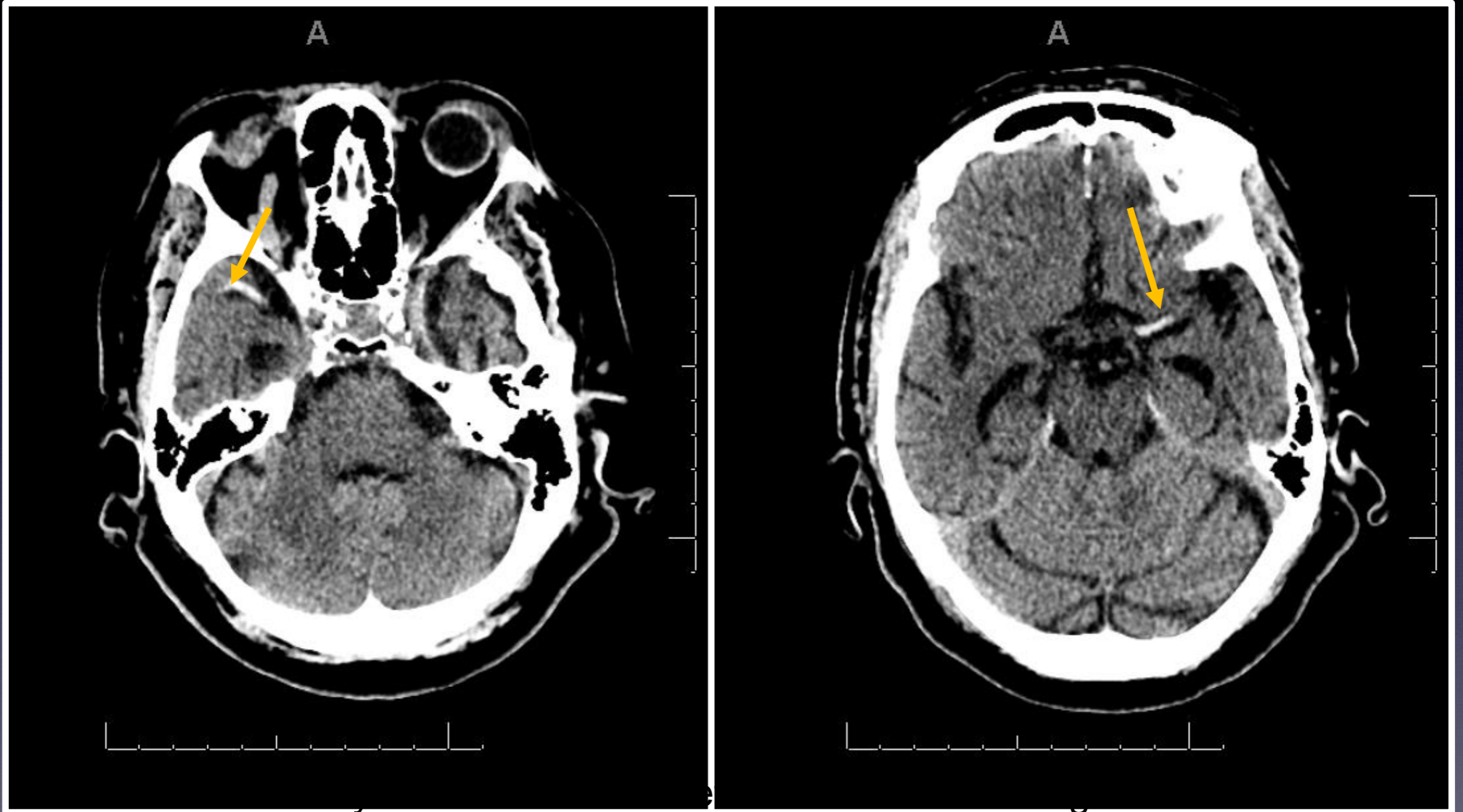


asia

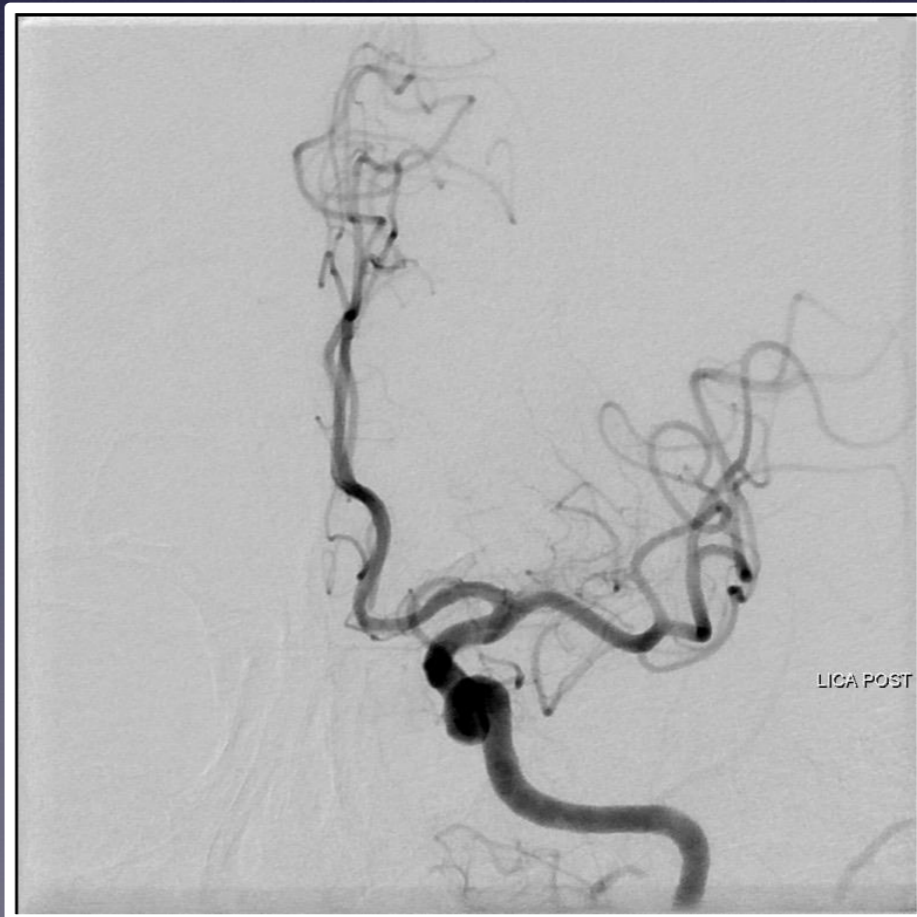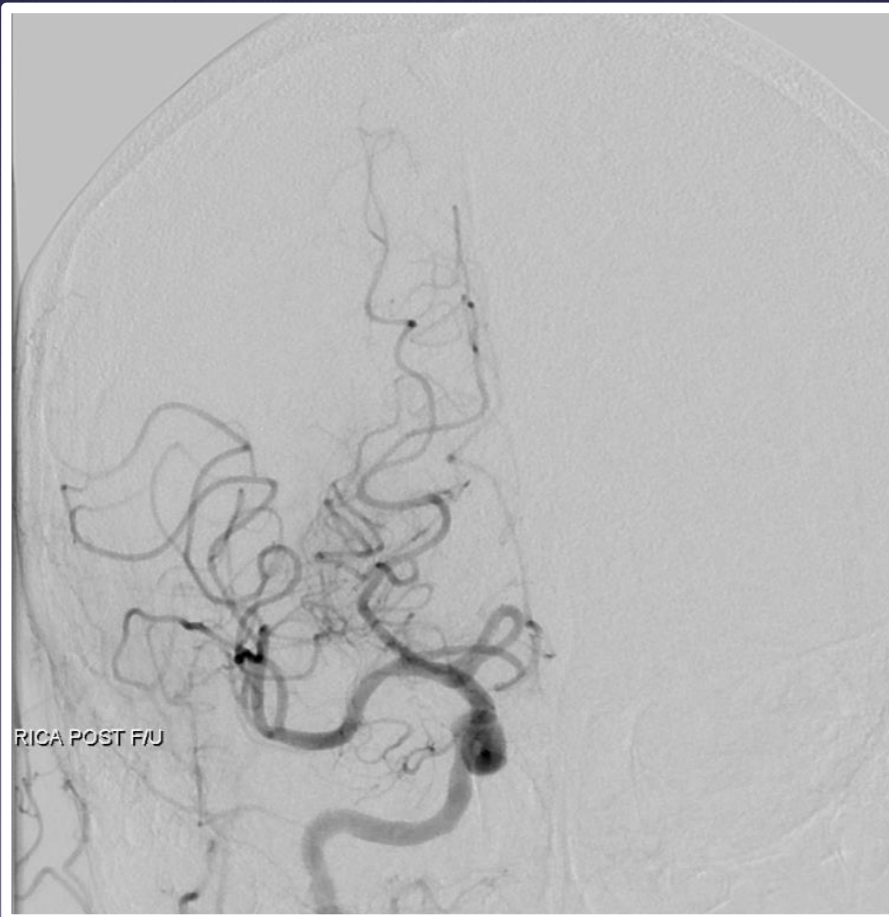

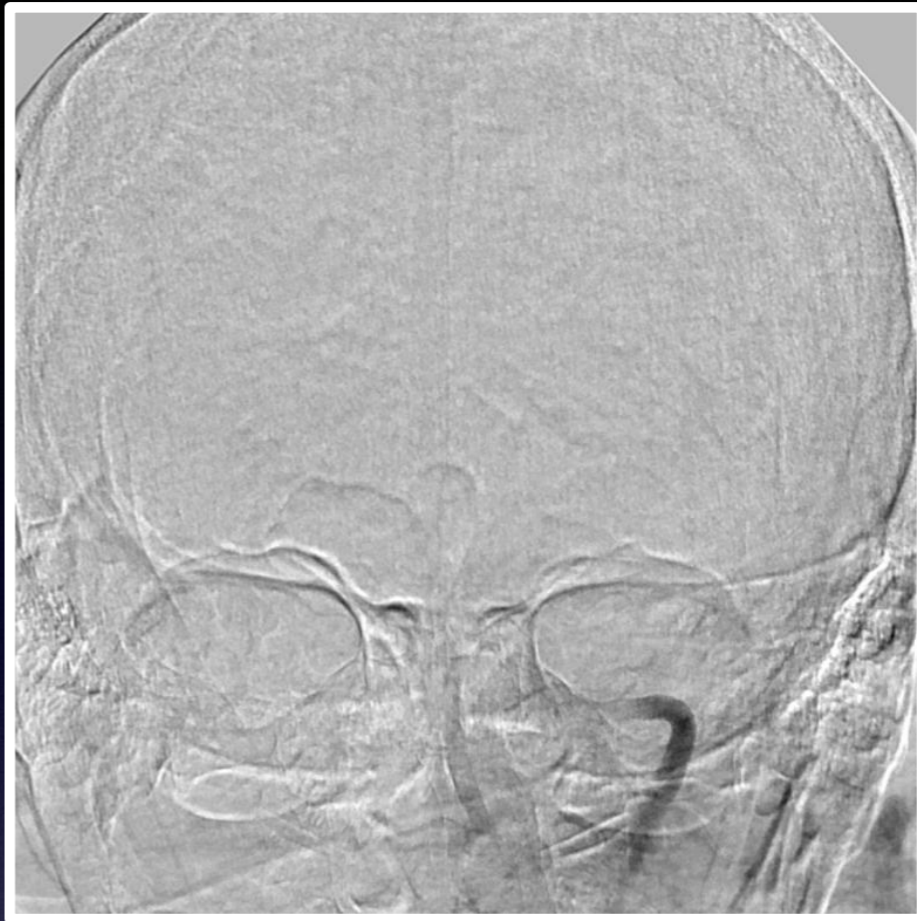
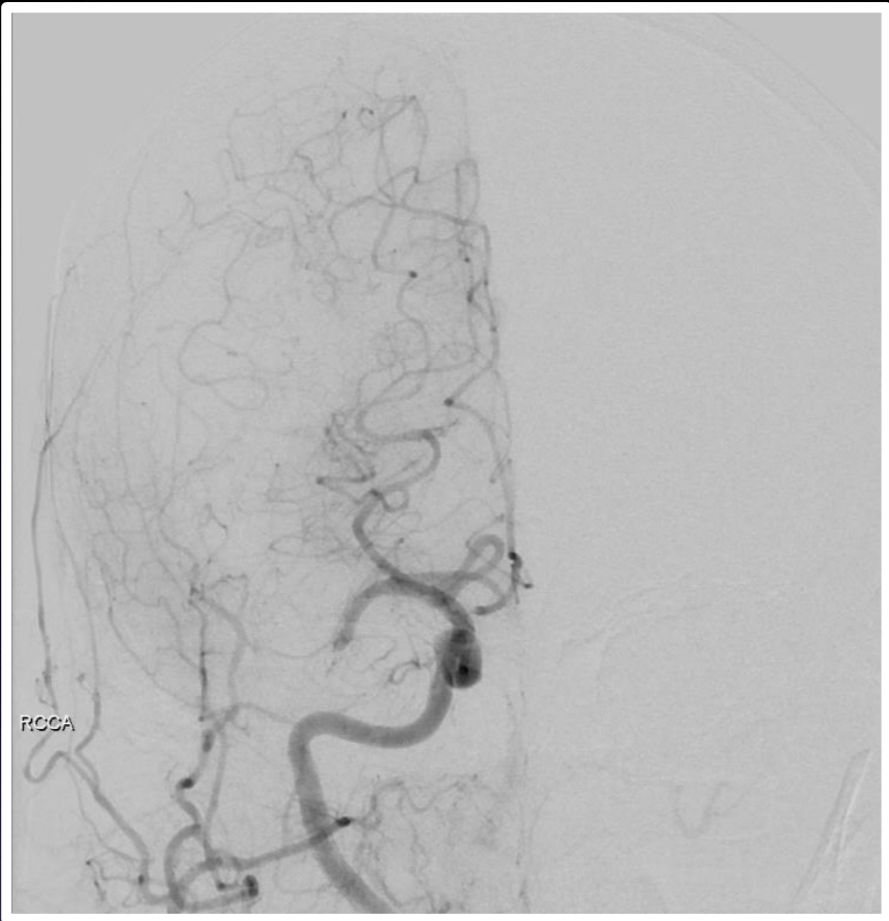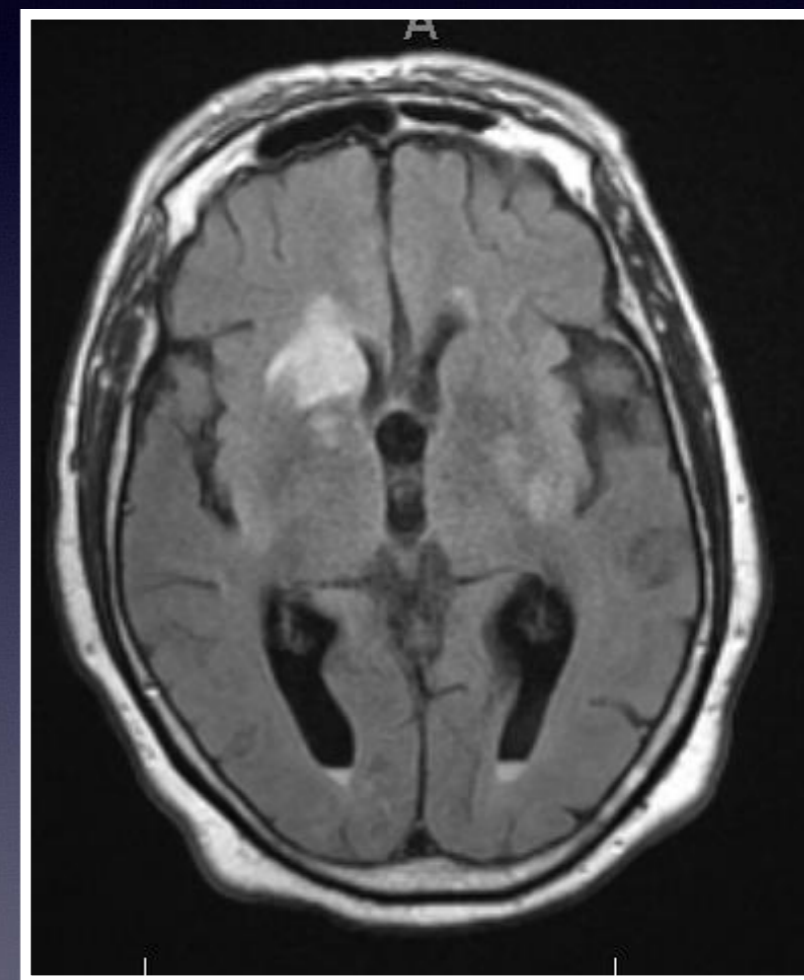
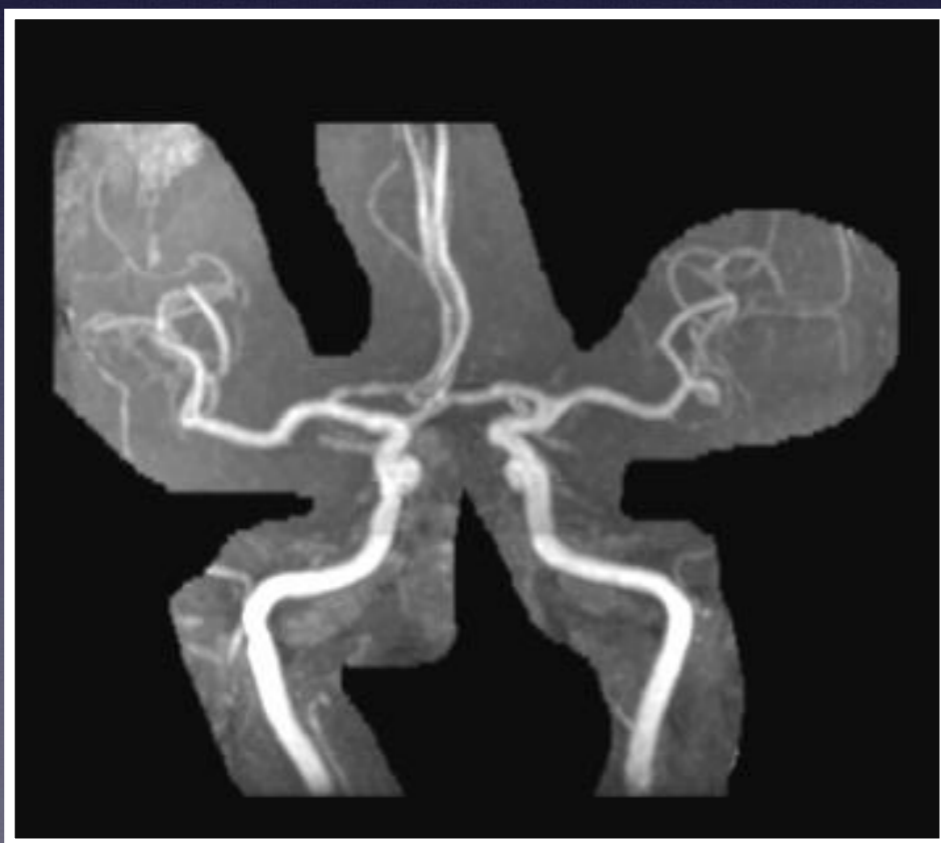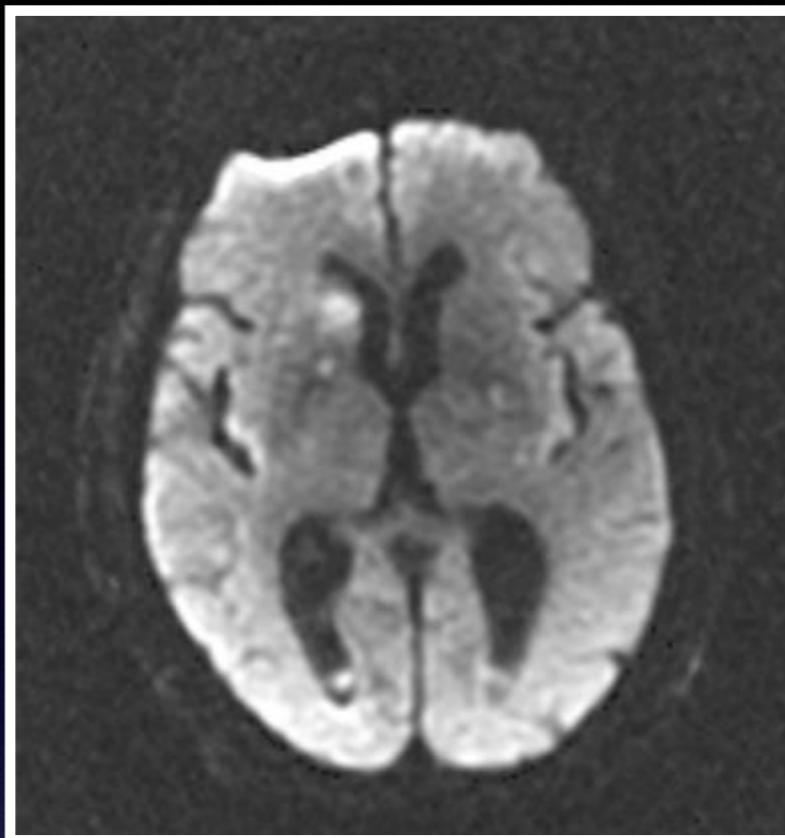
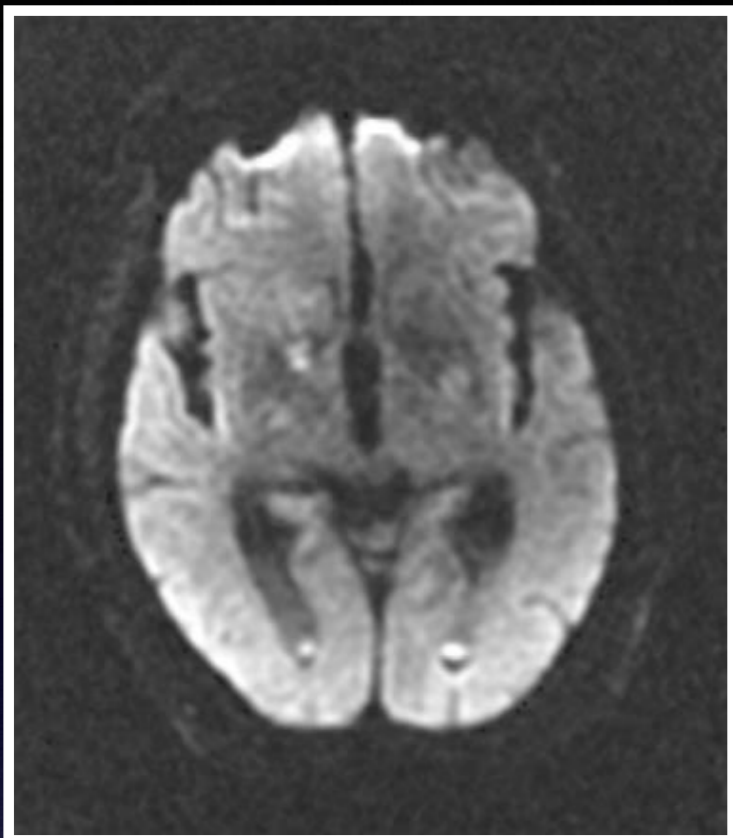
# Early ischemic changes NECT

- **Hyperdense vessel sign**
- Parenchymal changes secondary to increased water accumulation and neuronal death:
  - Loss of gray/white matter differentiation ('insular ribbon sign')
  - Swelling (sulcal/ventricular effacement)
  - Hypodensity



84 yo with sudden loss of consciousness, GCS 4



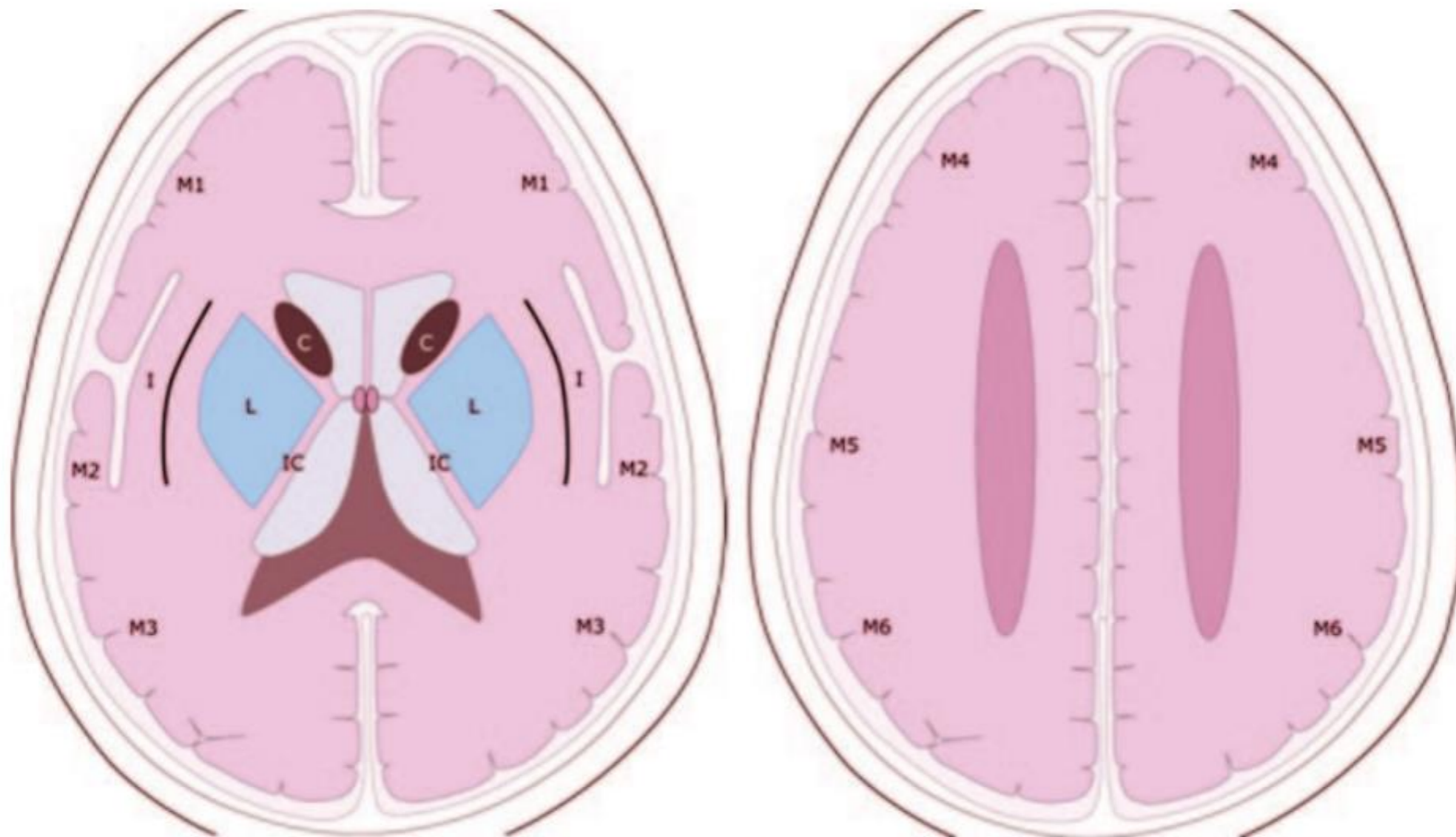


MRI 48 hrs later

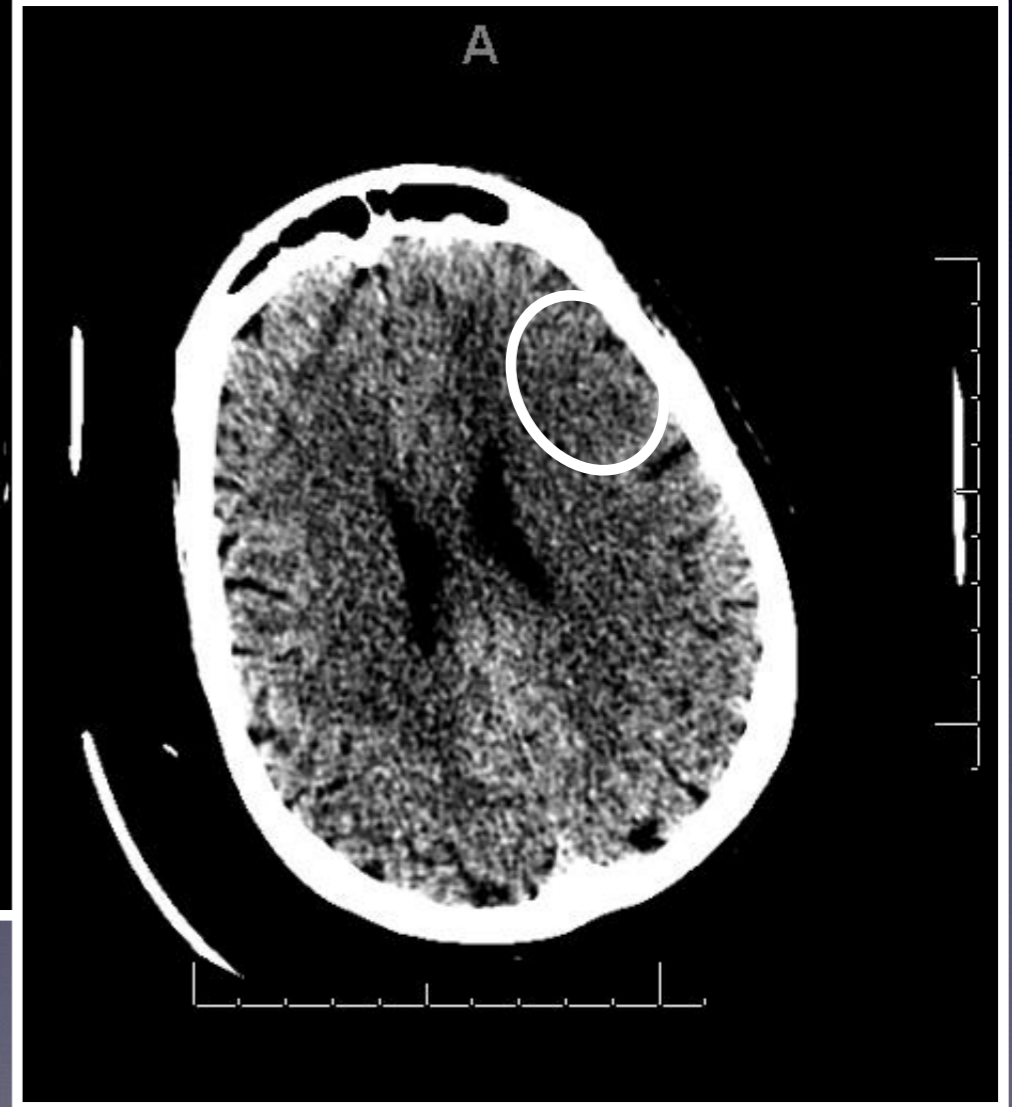
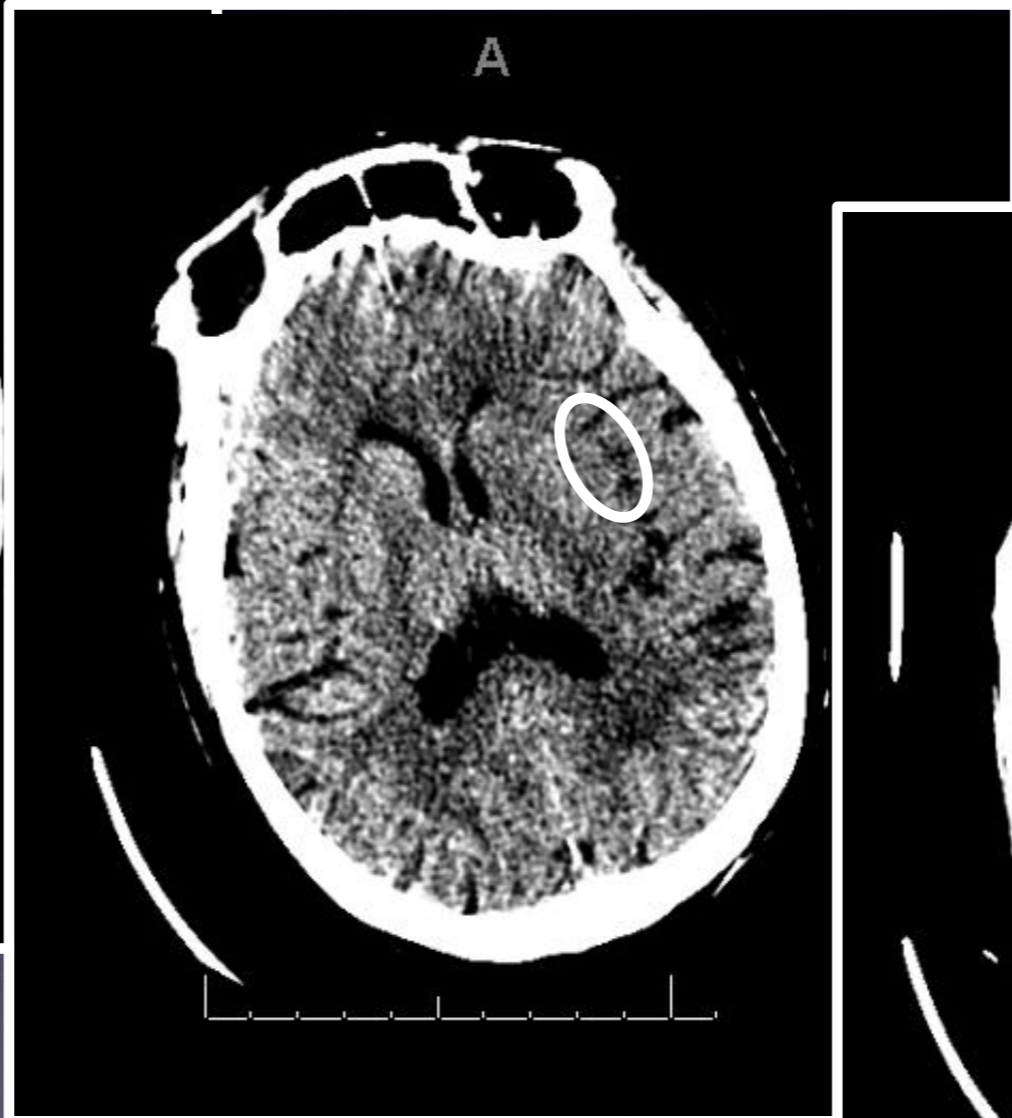
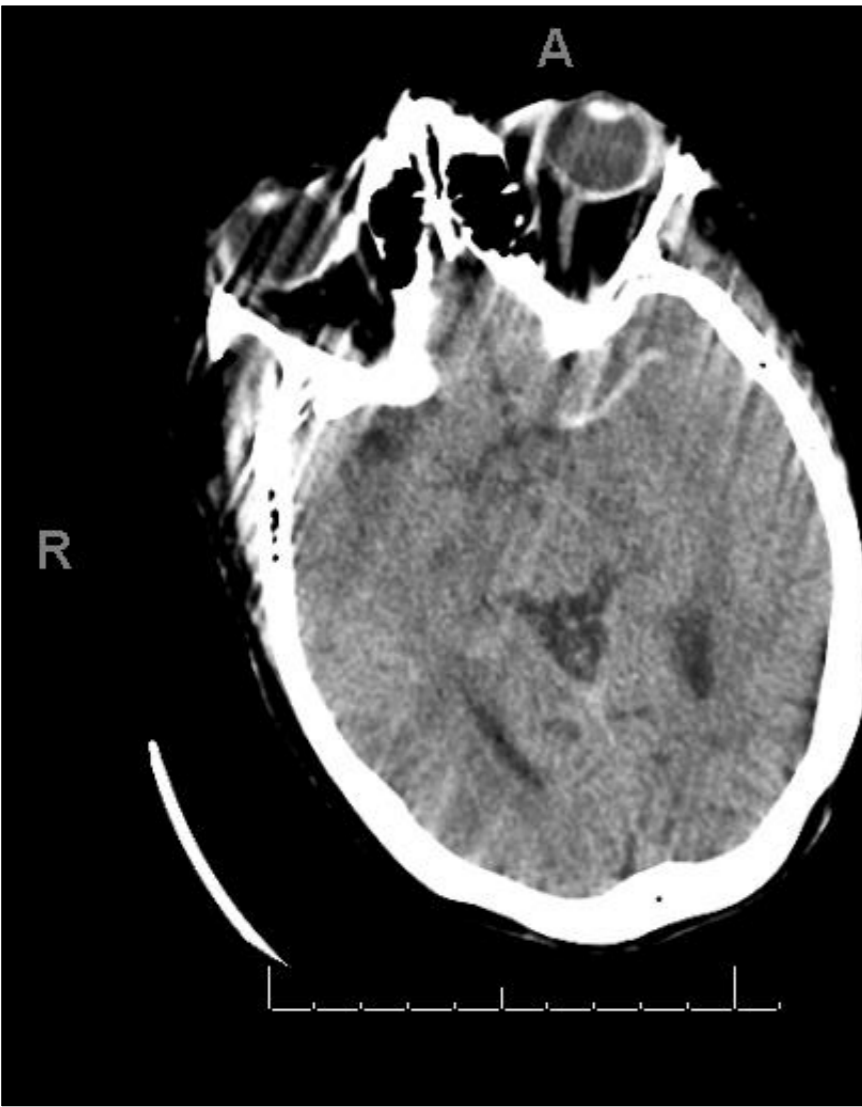# Early ischemic changes NECT

- Hyperdense vessel sign
- **Parenchymal changes** secondary to increased water accumulation and neuronal death:
  - Loss of gray/white matter differentiation ('insular ribbon sign')
  - Swelling (sulcal/ventricular effacement)
  - Hypodensity
- ASPECTS: Alberta Stroke Program Early CT Score

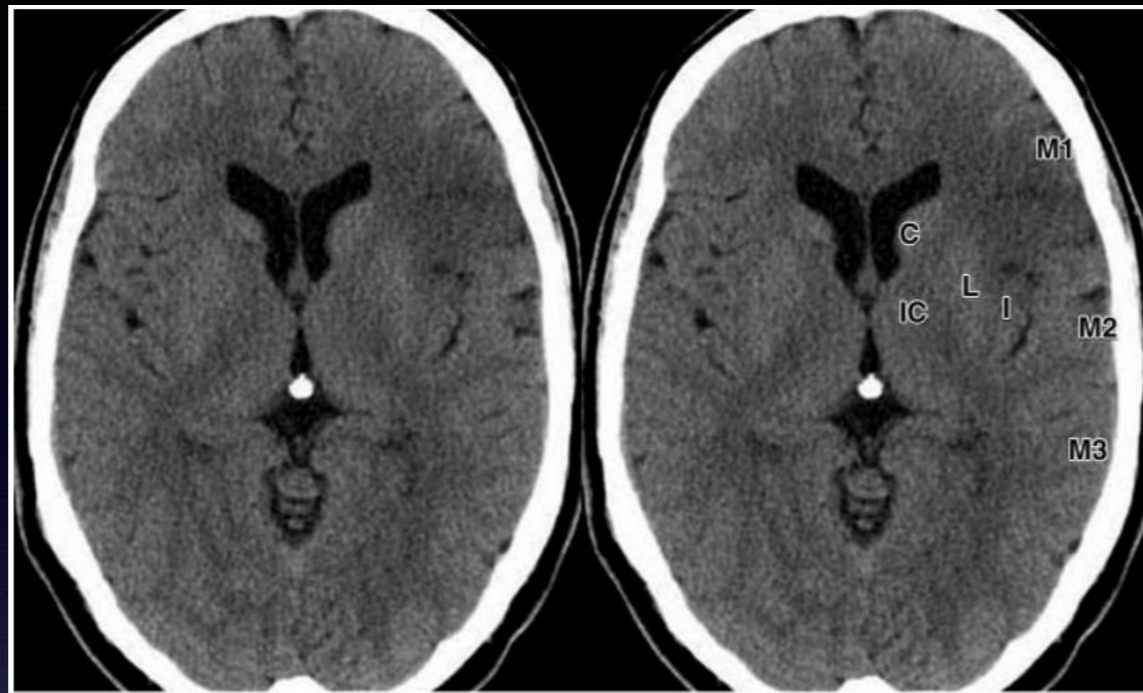



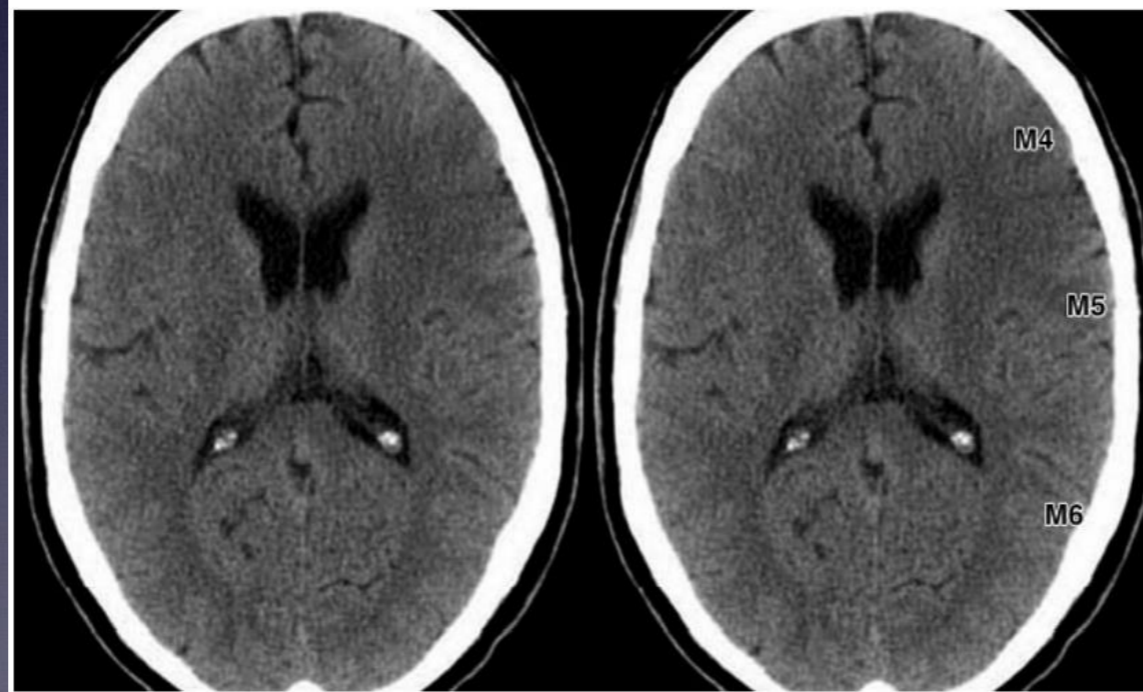
**Figure 6.** Schematic shows the 10 regions of the MCA distribution, each of which accounts for one point in the ASPECTS system: M1, M2, M3, M4, M5, M6, the caudate nucleus (*C*), the lentiform nucleus (*L*), the internal capsule (*IC*), and the insular cortex (*I*). For each area involved in ischemia depicted at unenhanced CT, one point is subtracted from the total score of 10.



ASPECTS: 8

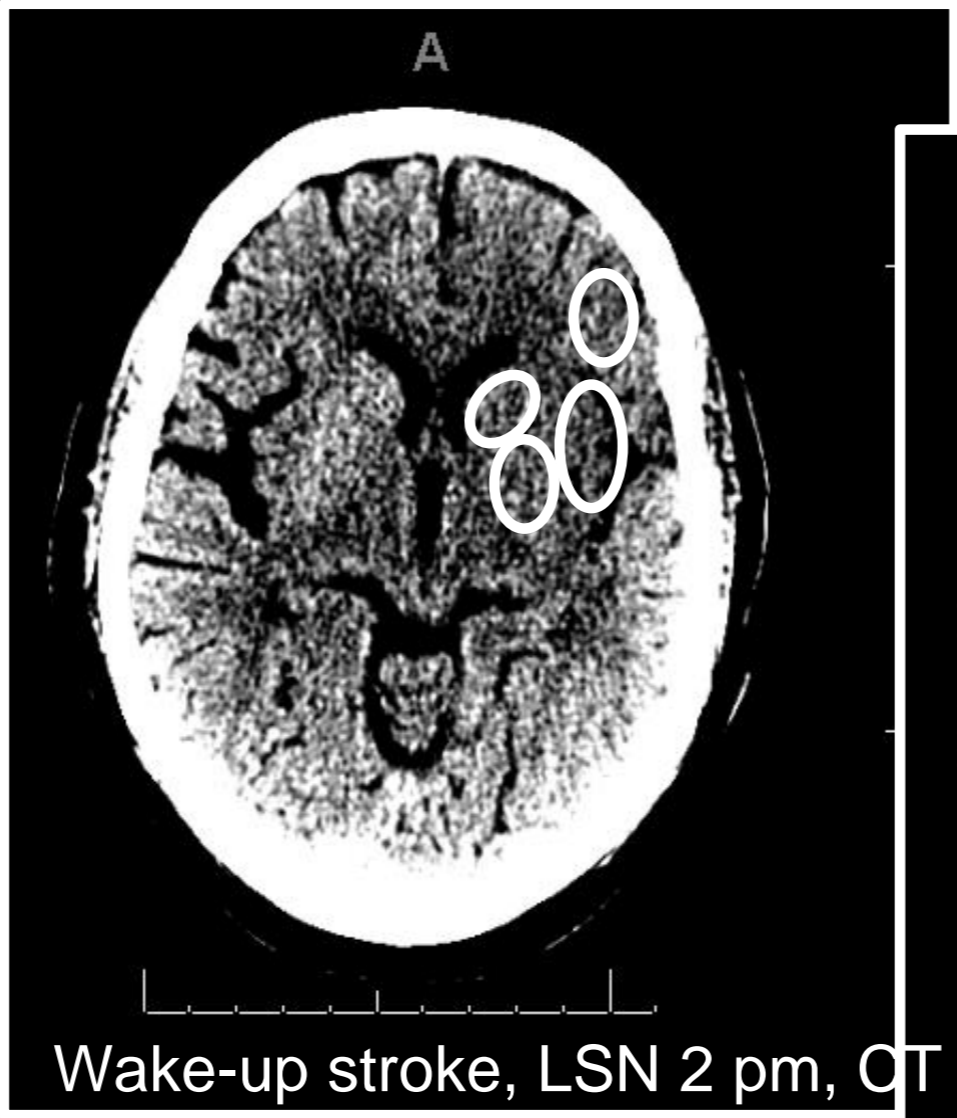
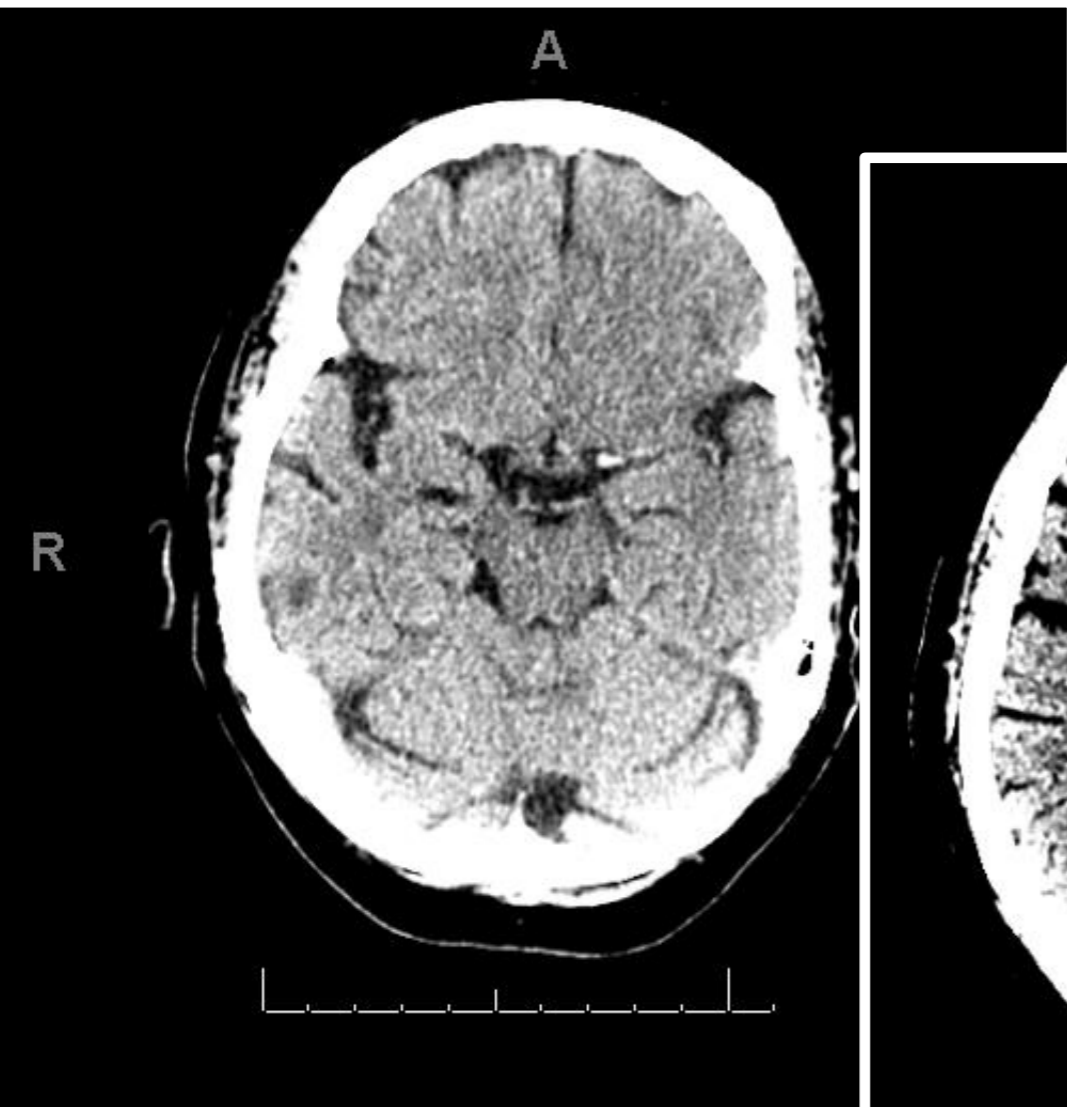

a.

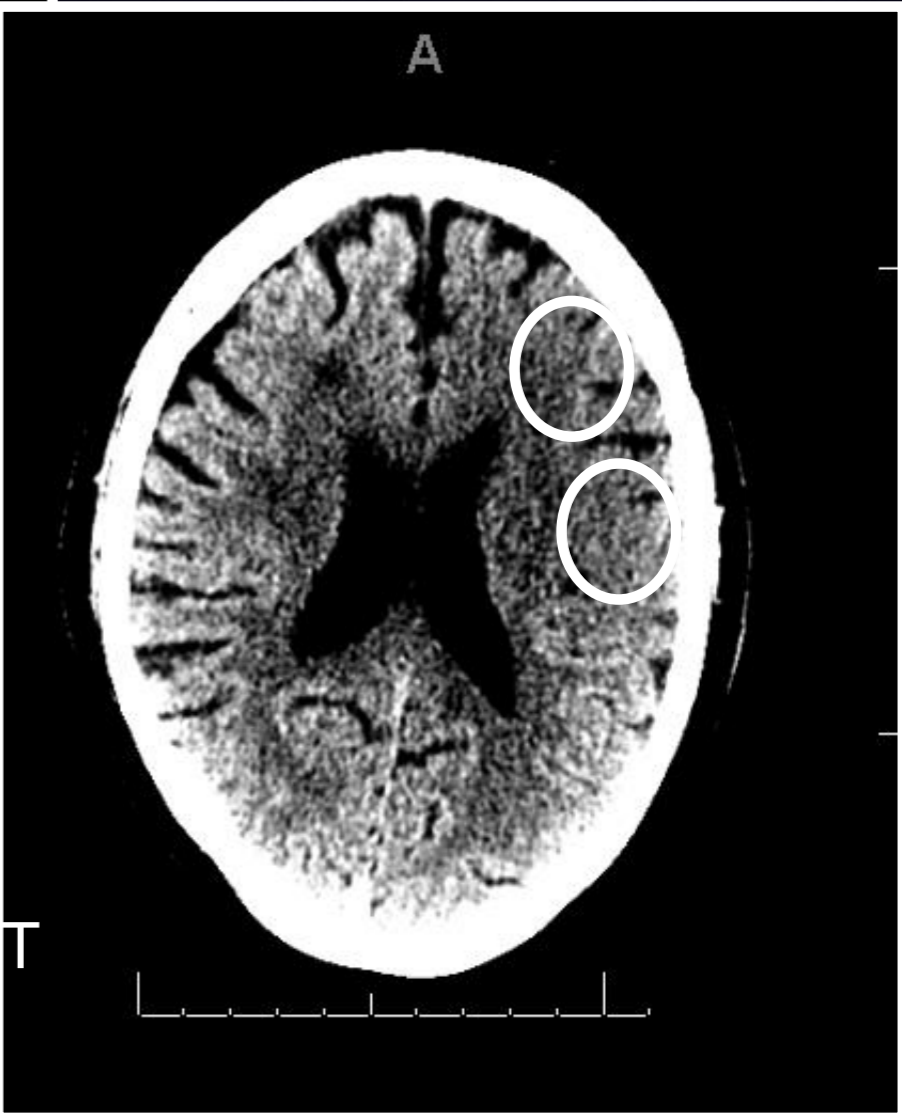

ASPECTS: 7



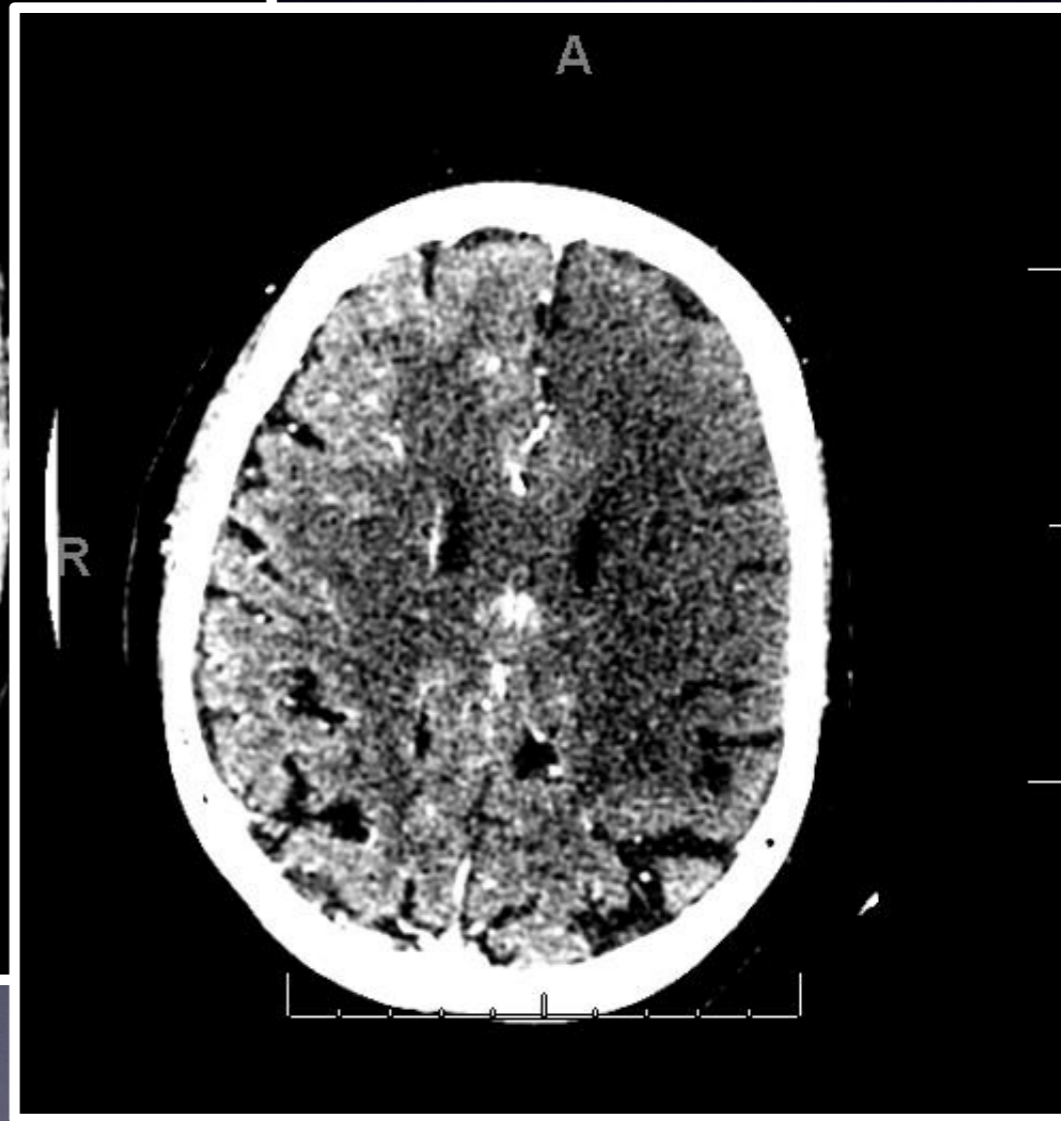
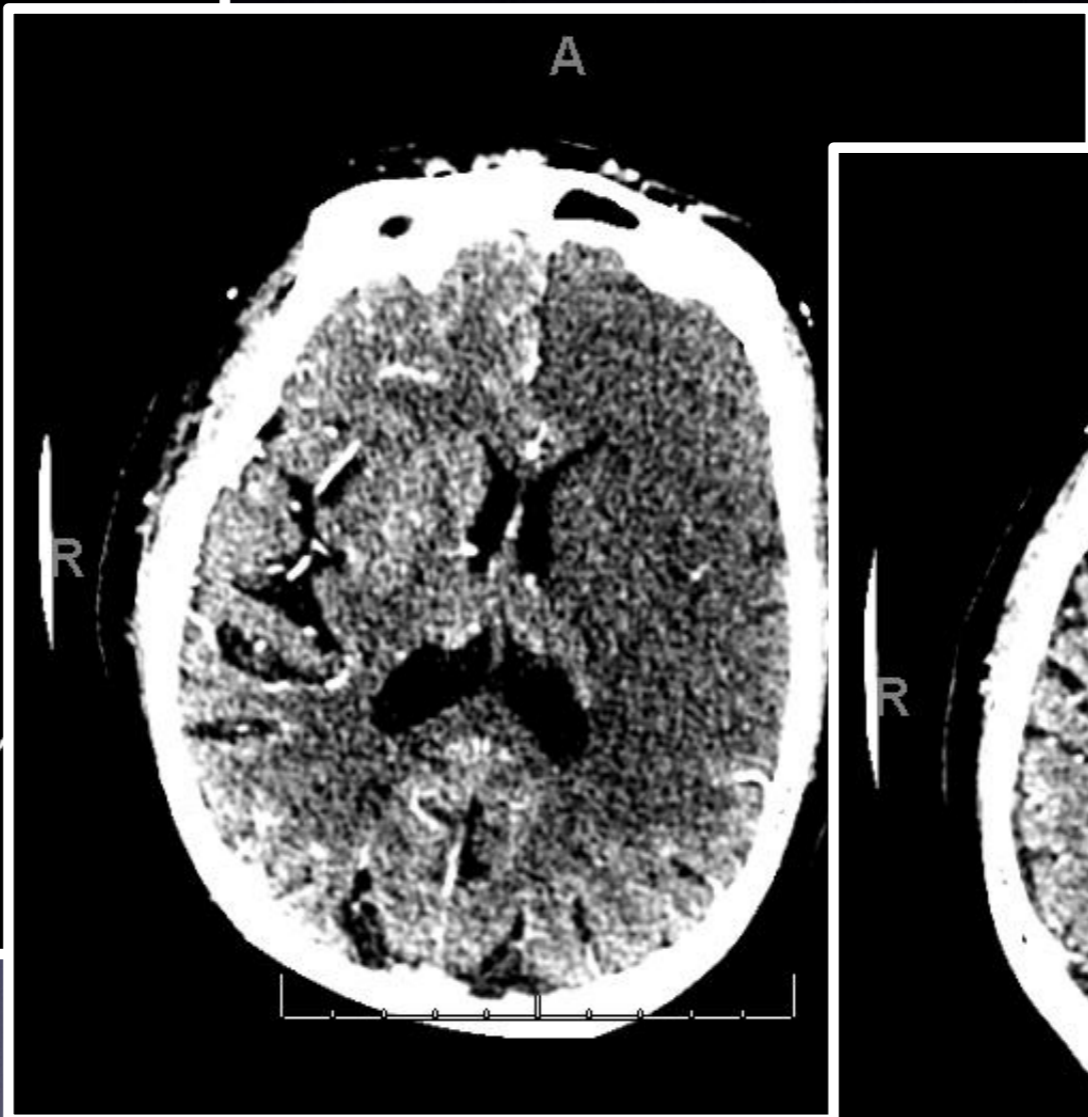
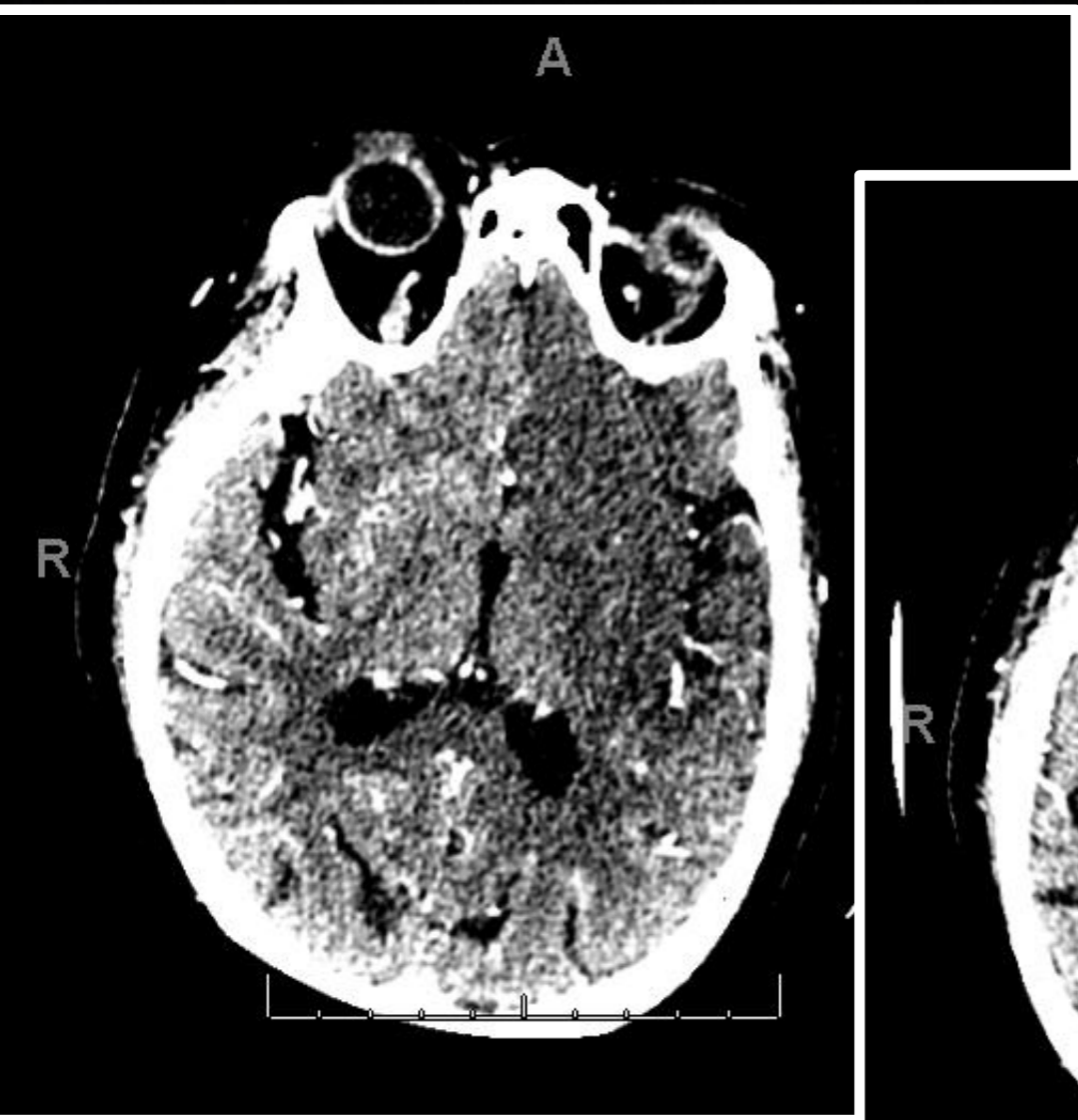


7:10 PM



ASPECTS: 4

**CTA**



Wake-up stroke, LSN 2 pm, CTA:  
8:00 PM

## II. What is the role of imaging?

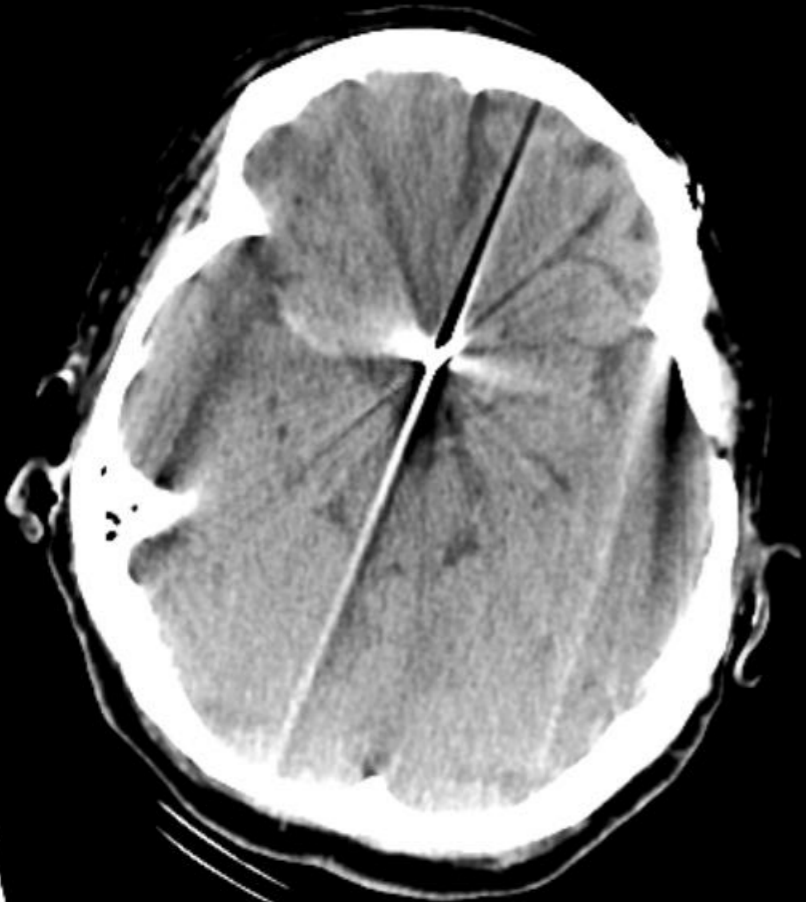- Patient with acute onset neurologic deficit.
  - Rule-out hemorrhage
  - Rule out other pathology
  - Identify and quantify early ischemic changes
  - Evaluate for large vessel occlusion
  - Evaluate for collateral flow

# CTA in acute stroke

- Evaluate for large vessel occlusion
- Evaluate for collateral flow
- [Identify and quantify early ischemic changes]
- Help in procedural planning
- Evaluate for tandem occlusion, arch disease, multiple occlusions

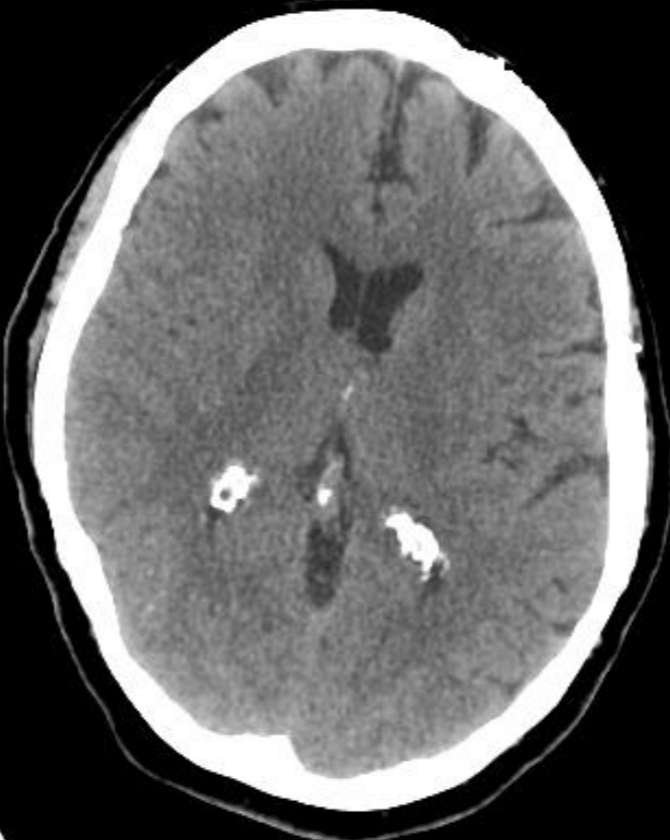A

R

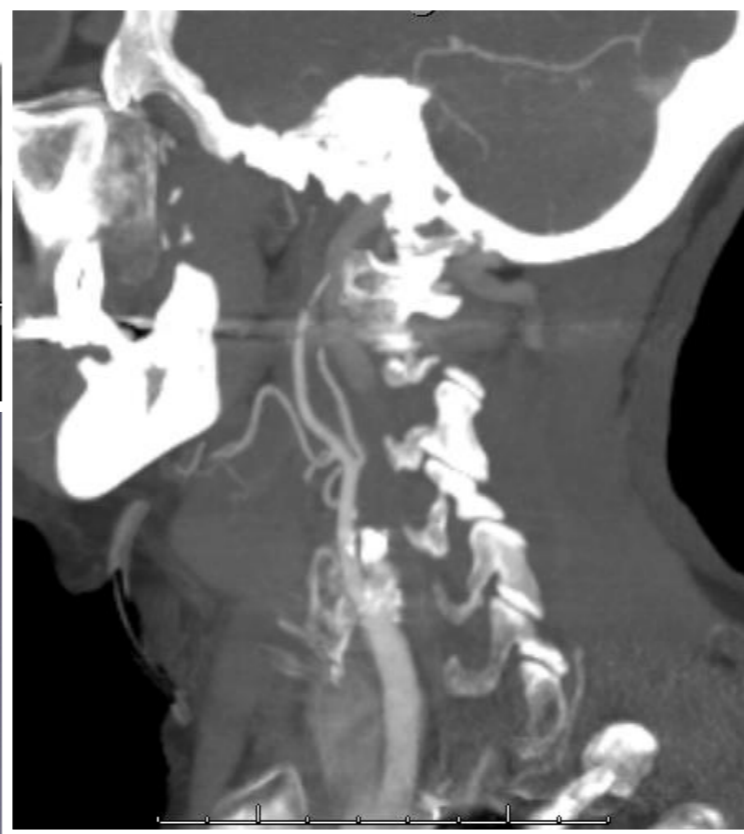
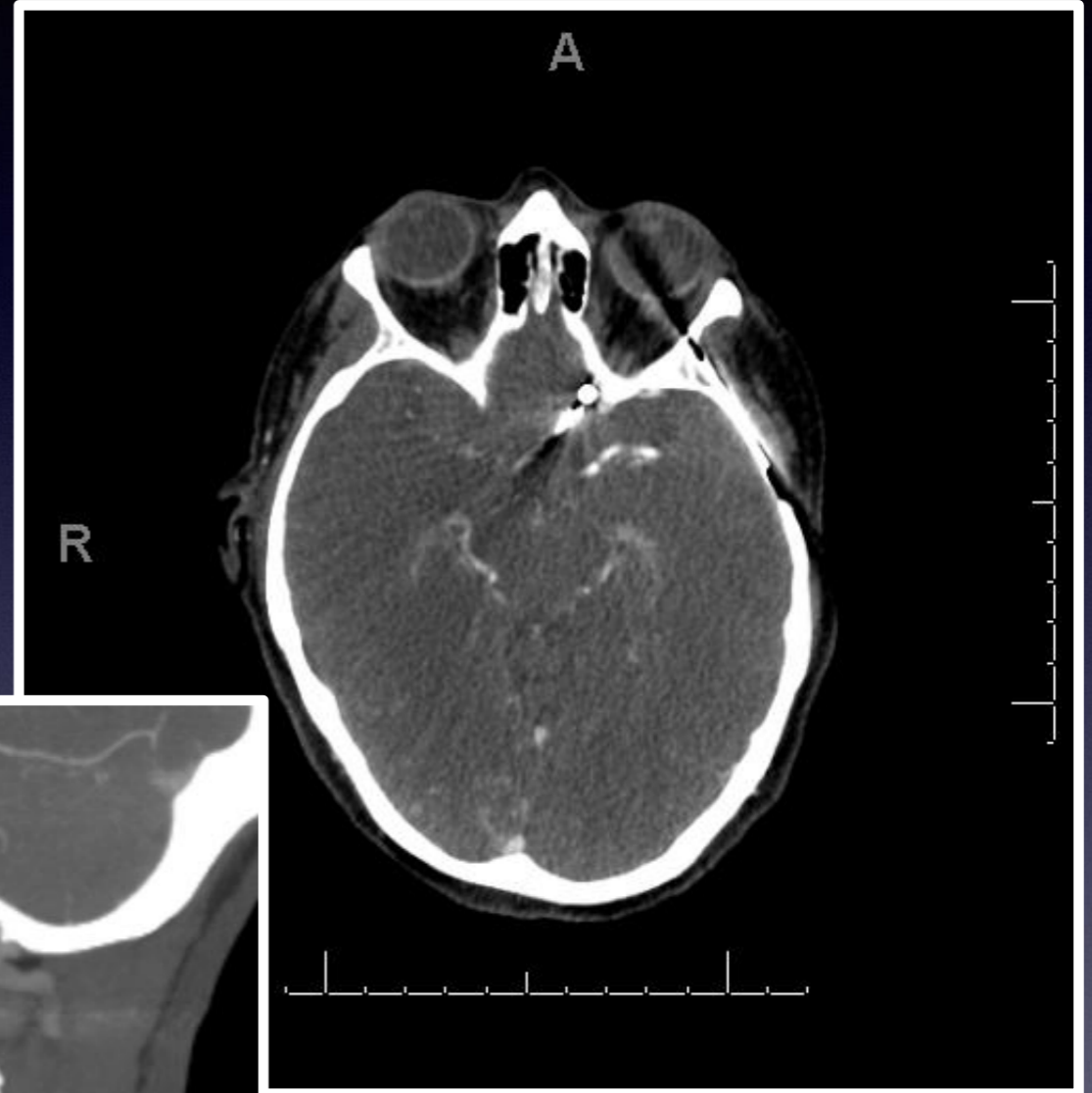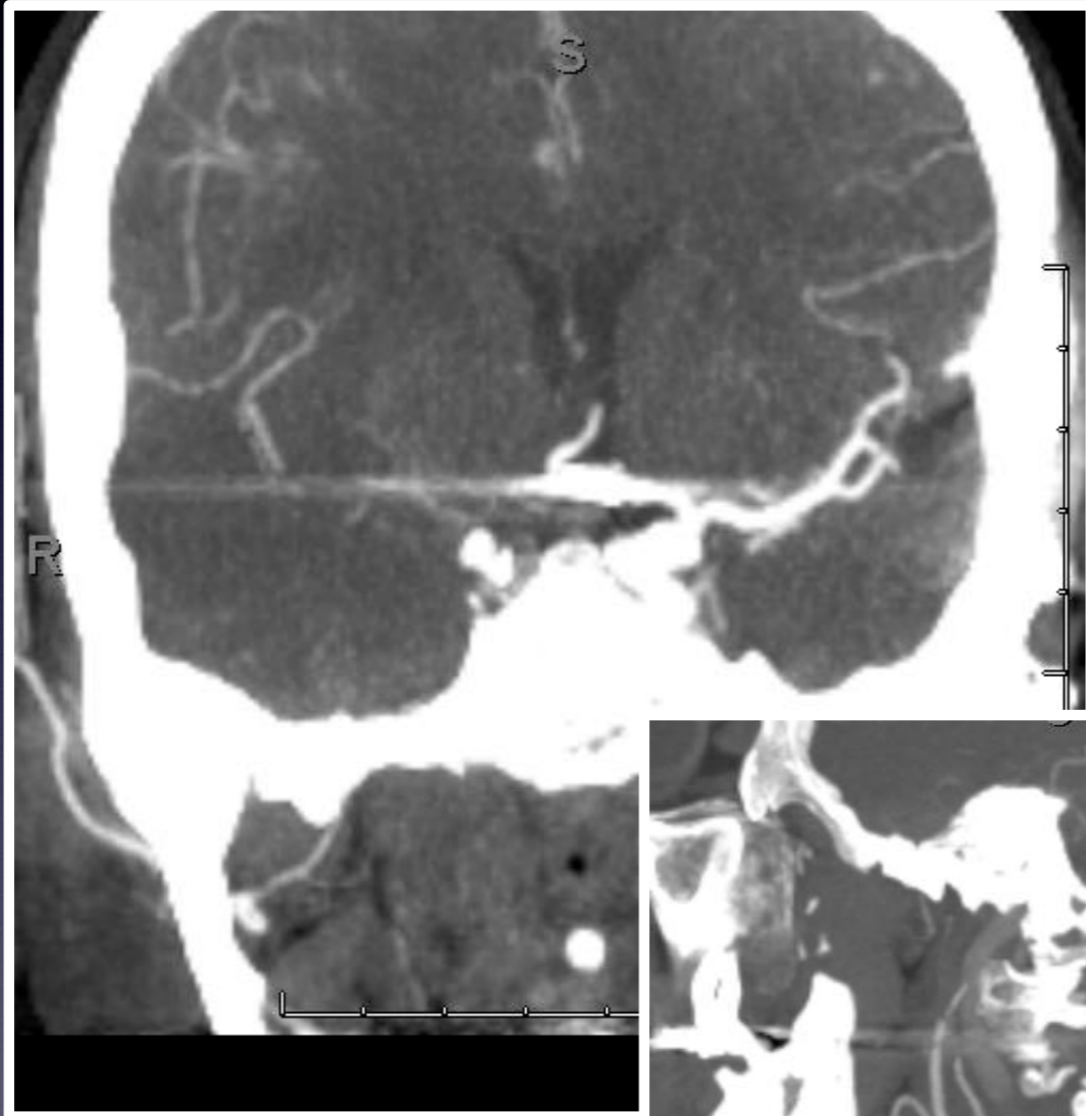


A

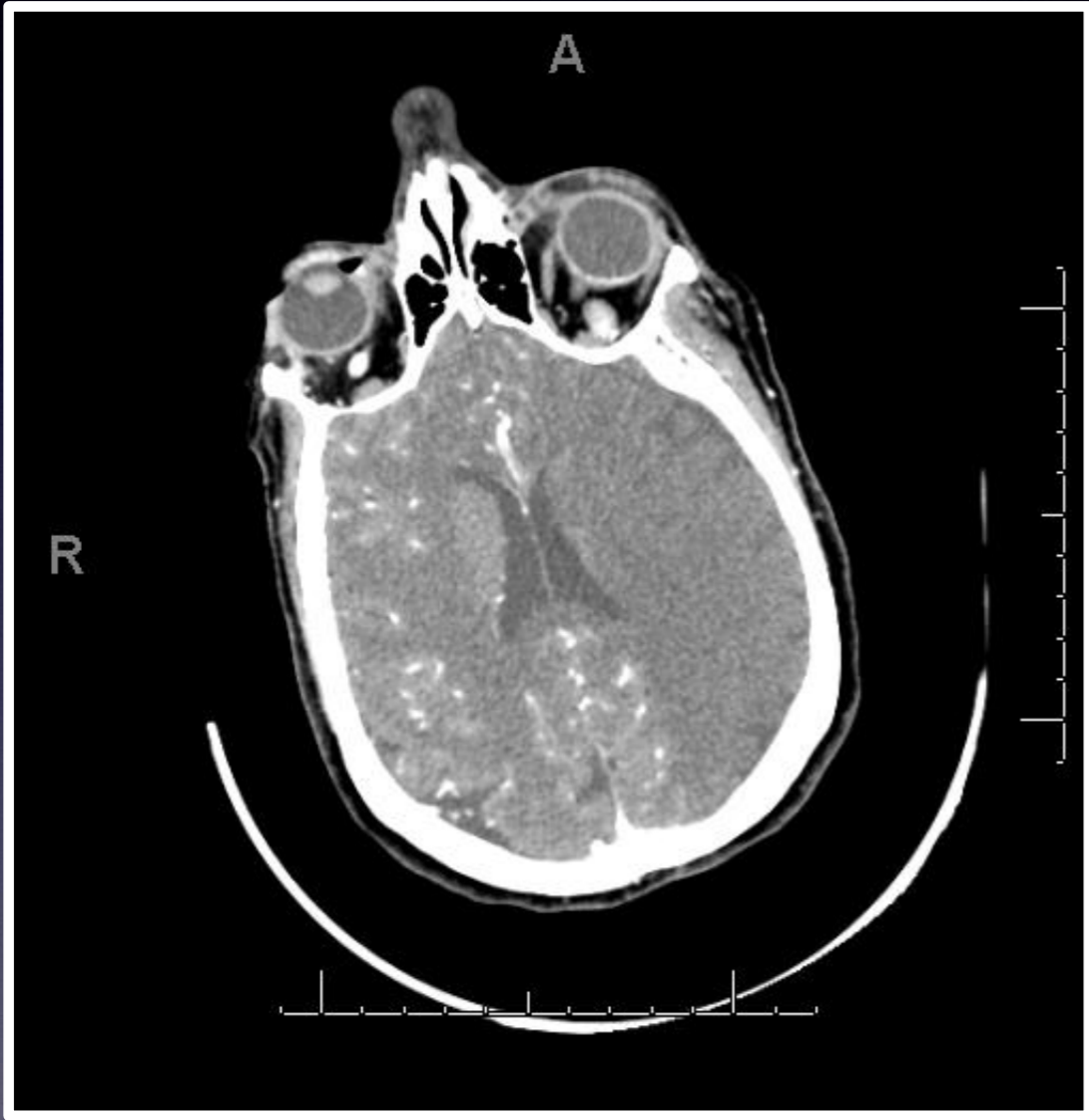
R



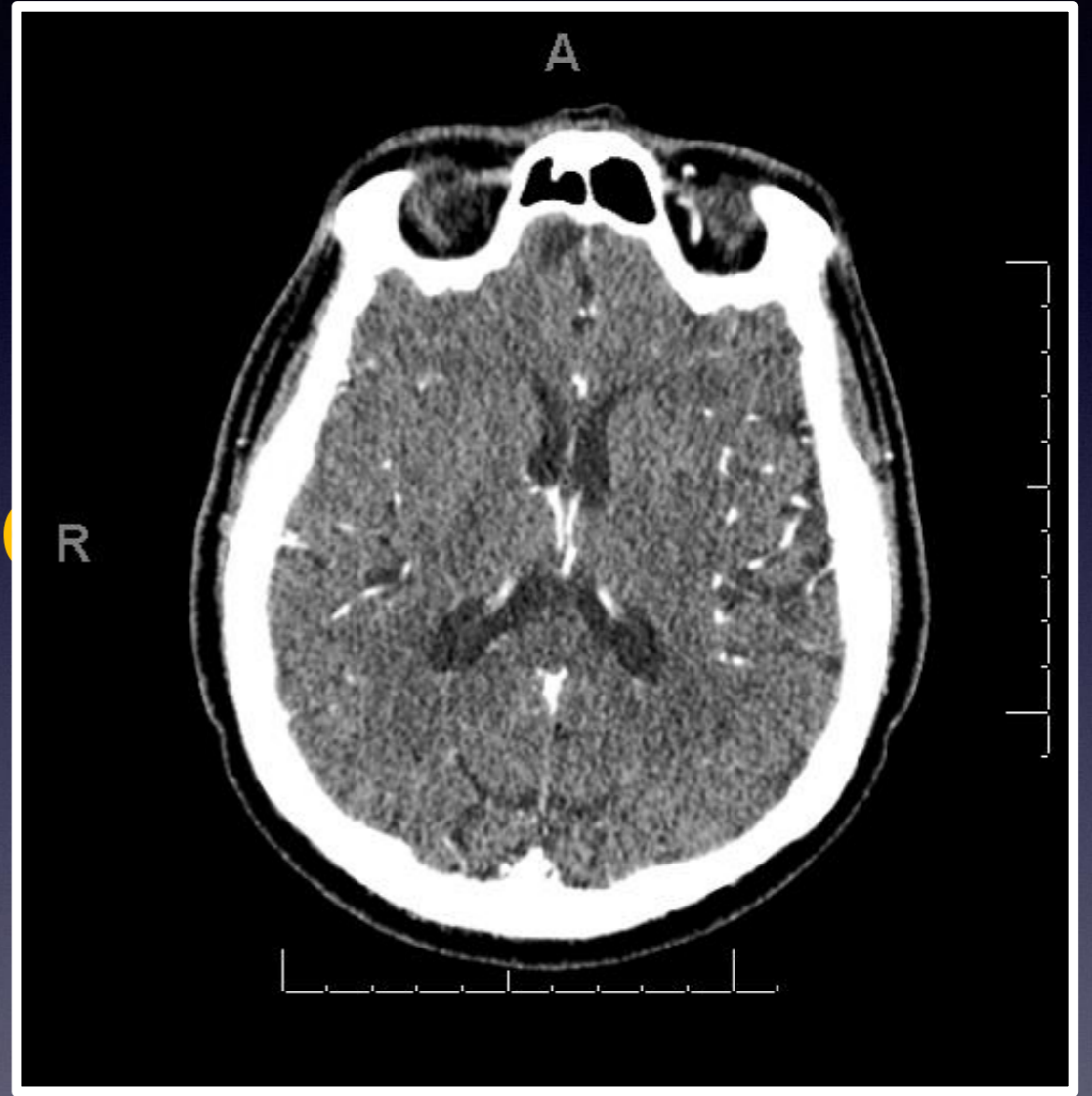2/18/2017  
16:40

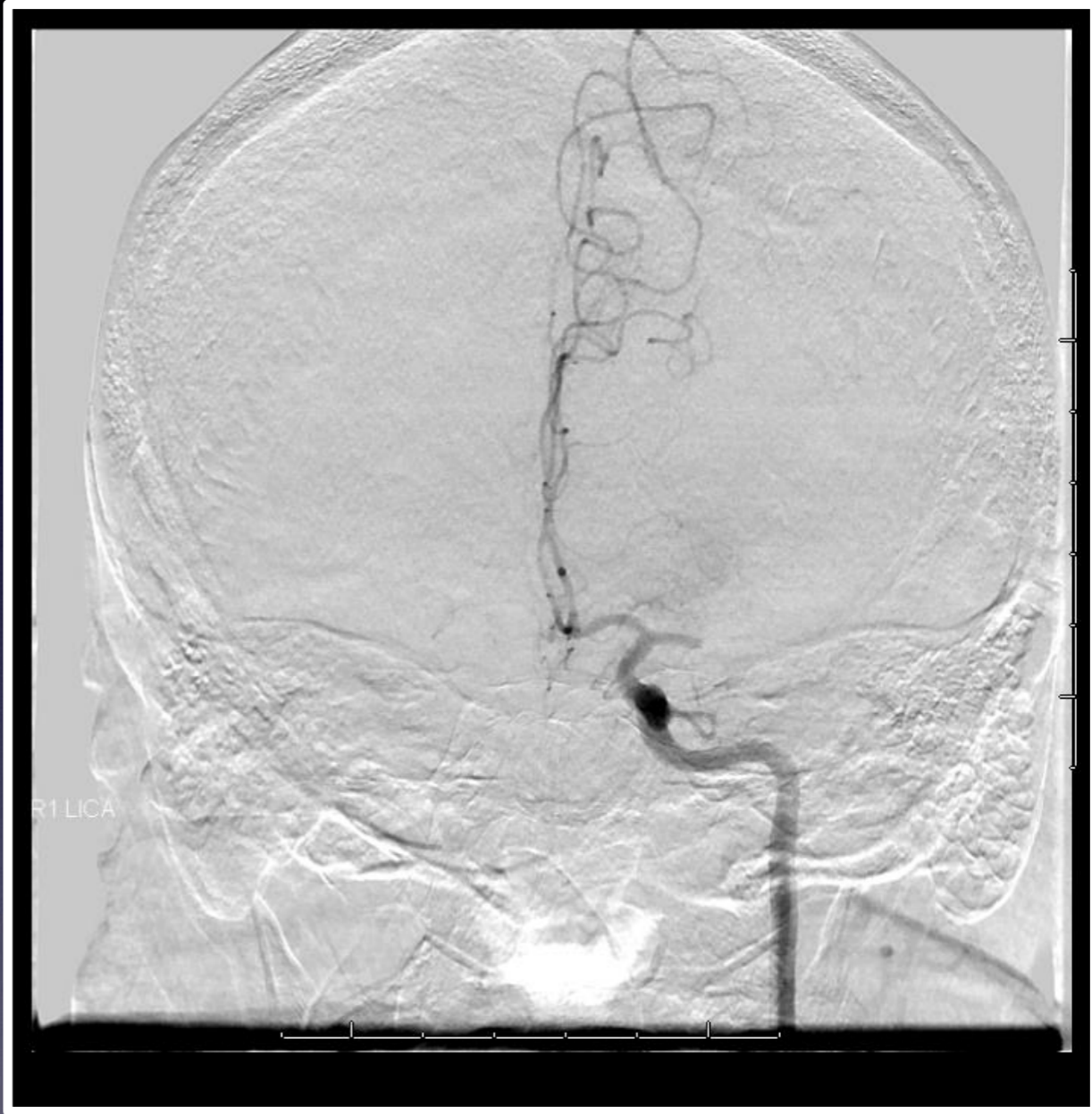
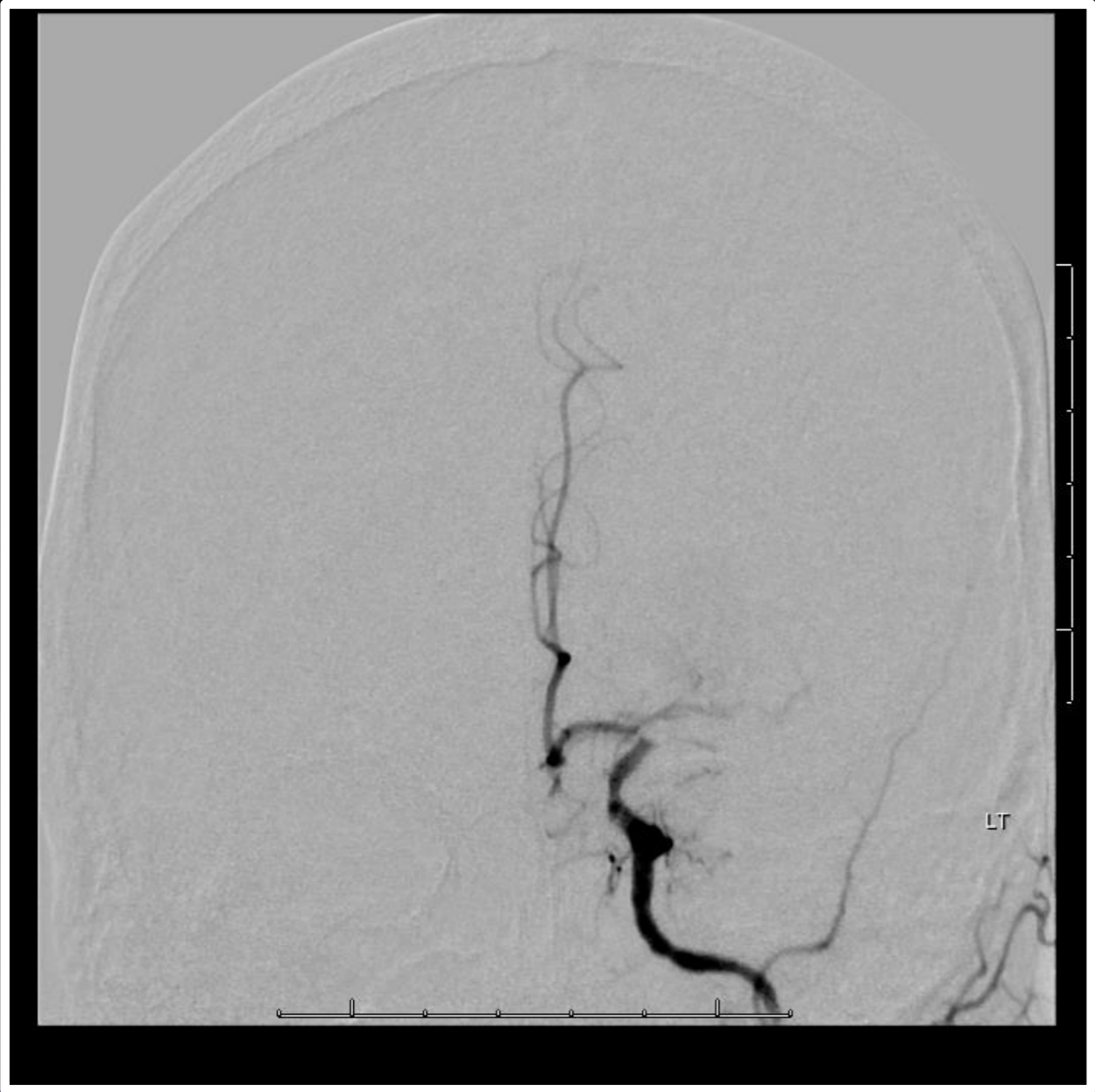

2/18/2017  
17:37

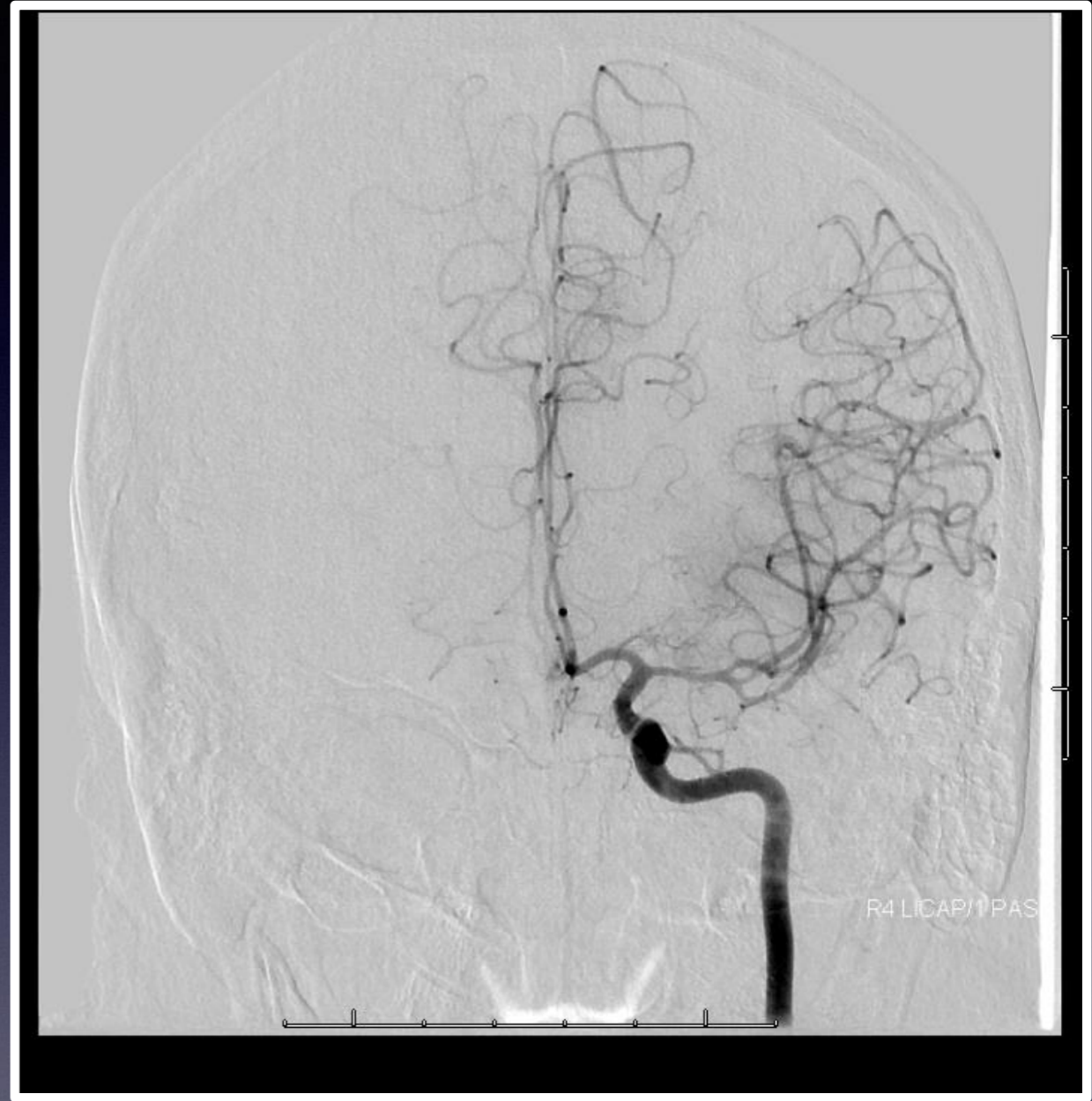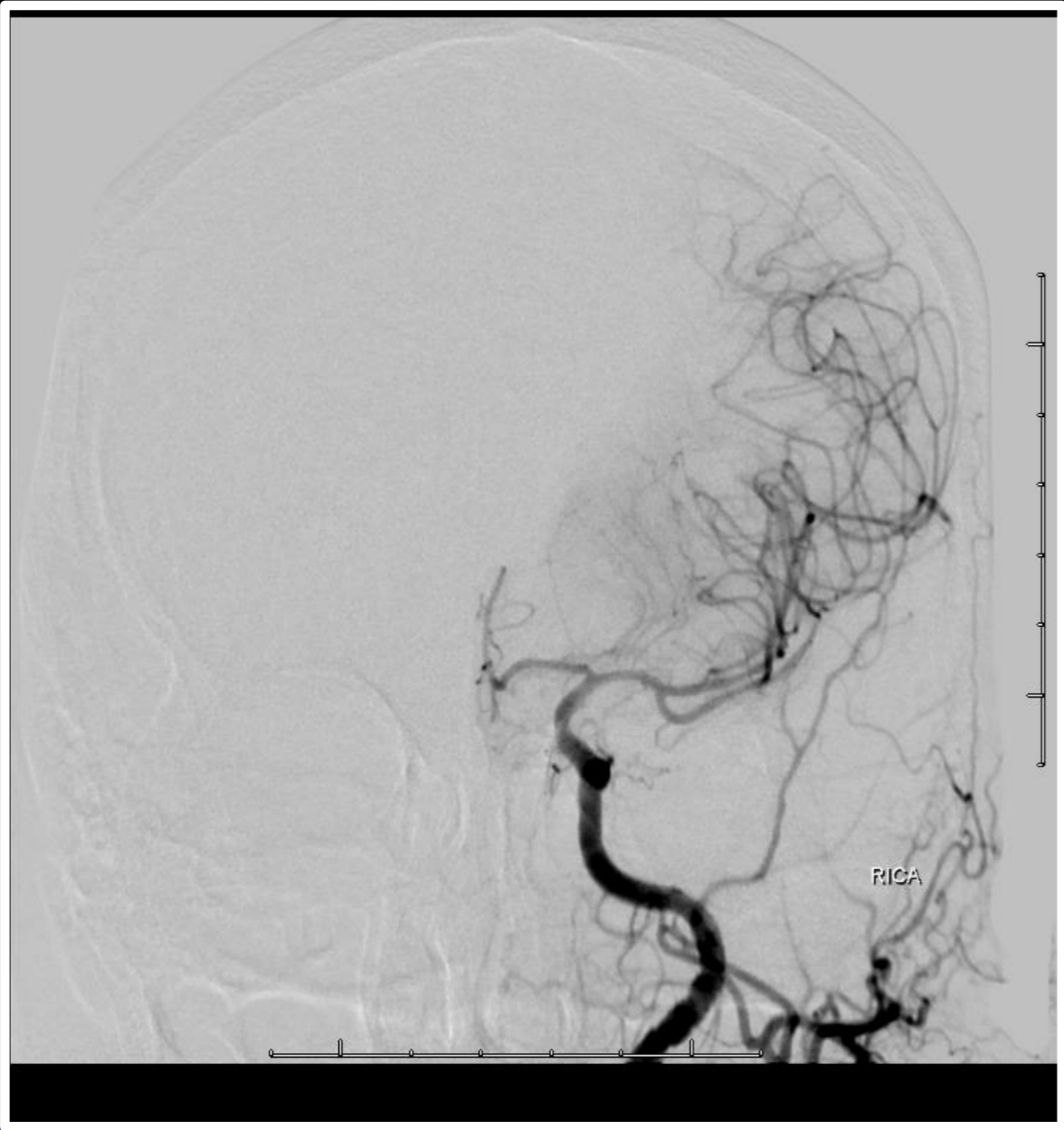


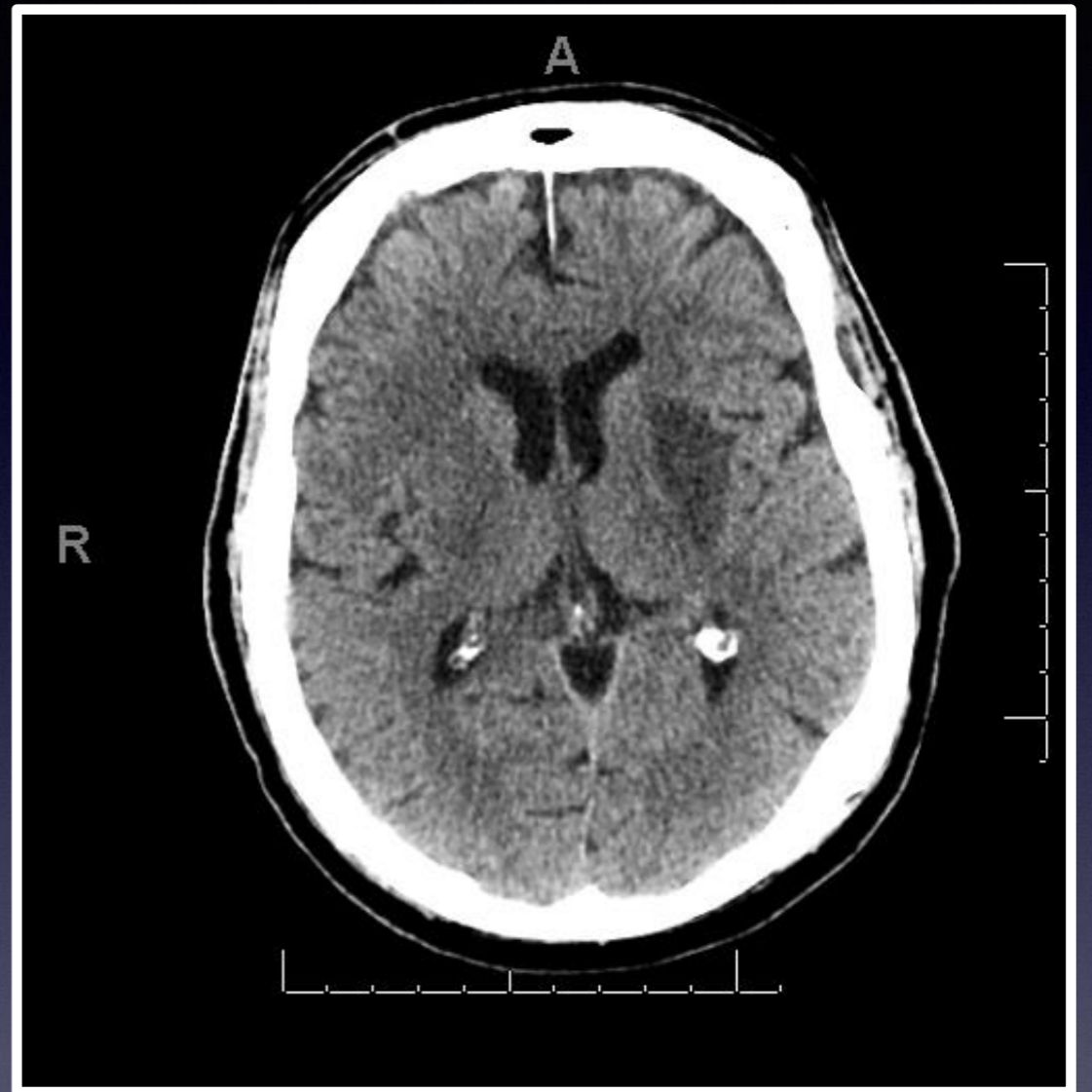
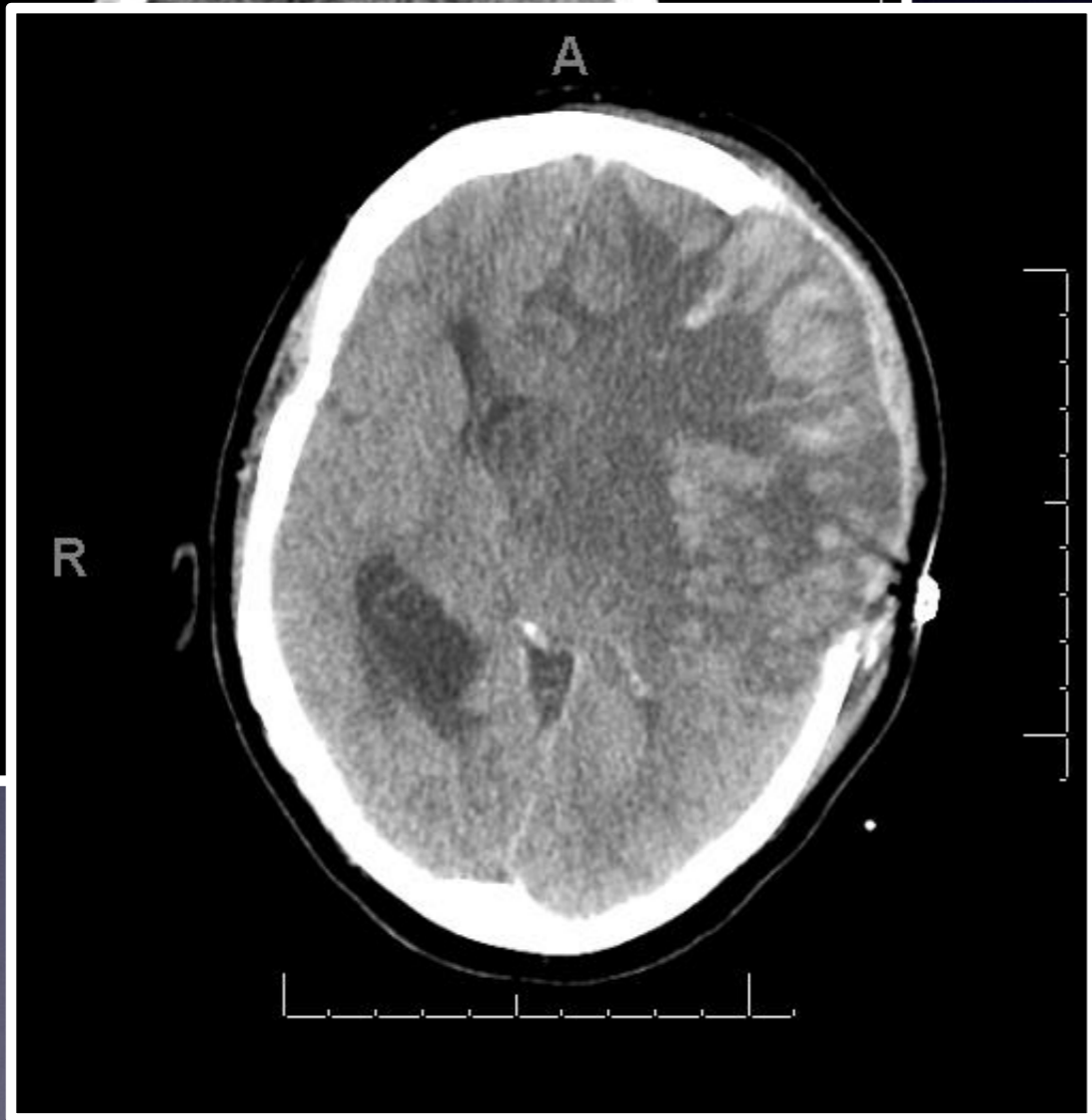
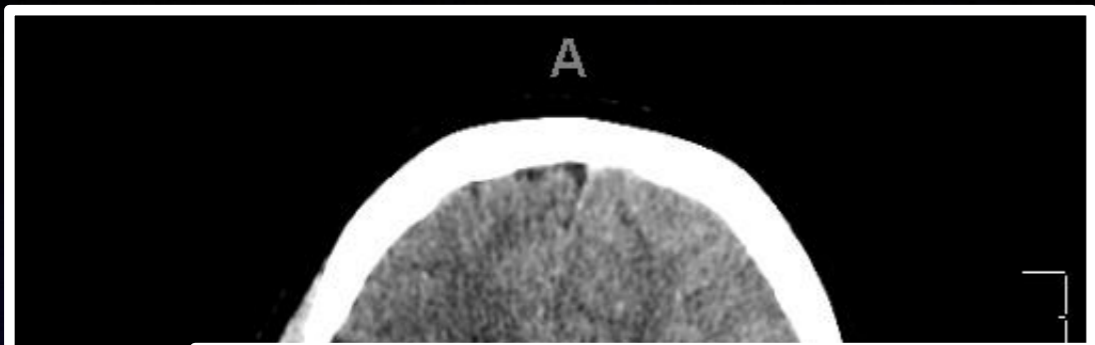
ra Flo











# III. What is the role of imaging?

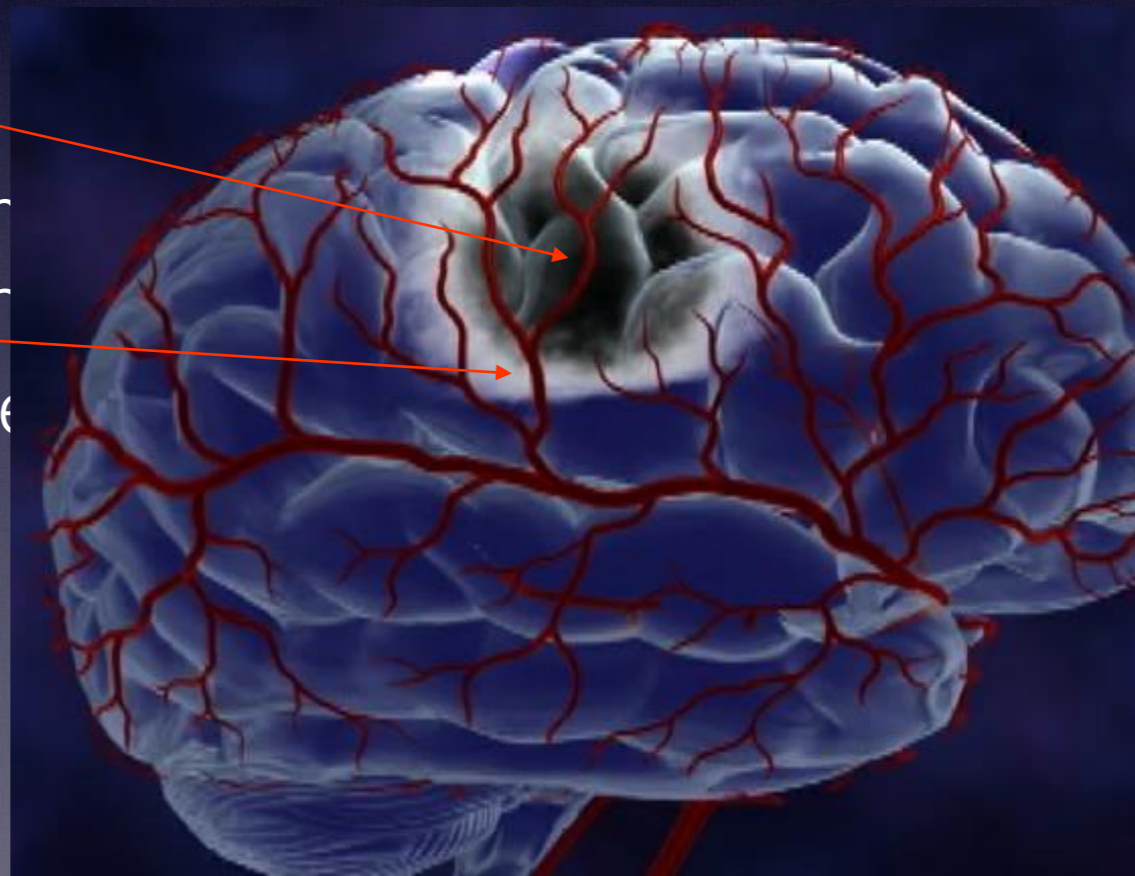- Patient with acute onset neurologic deficit.
  - Rule-out hemorrhage
  - Rule out other pathology
  - Identify and quantify early ischemic changes
  - Evaluate for large vessel occlusion
  - Evaluate for collateral flow
  - Evaluate the perfusion status and identify salvageable brain

# The Penumbra

## Ischemic core

- Surrounding this ischemic core is a region called the ischemic penumbra.
- The penumbra's cells receive

## Penumbra



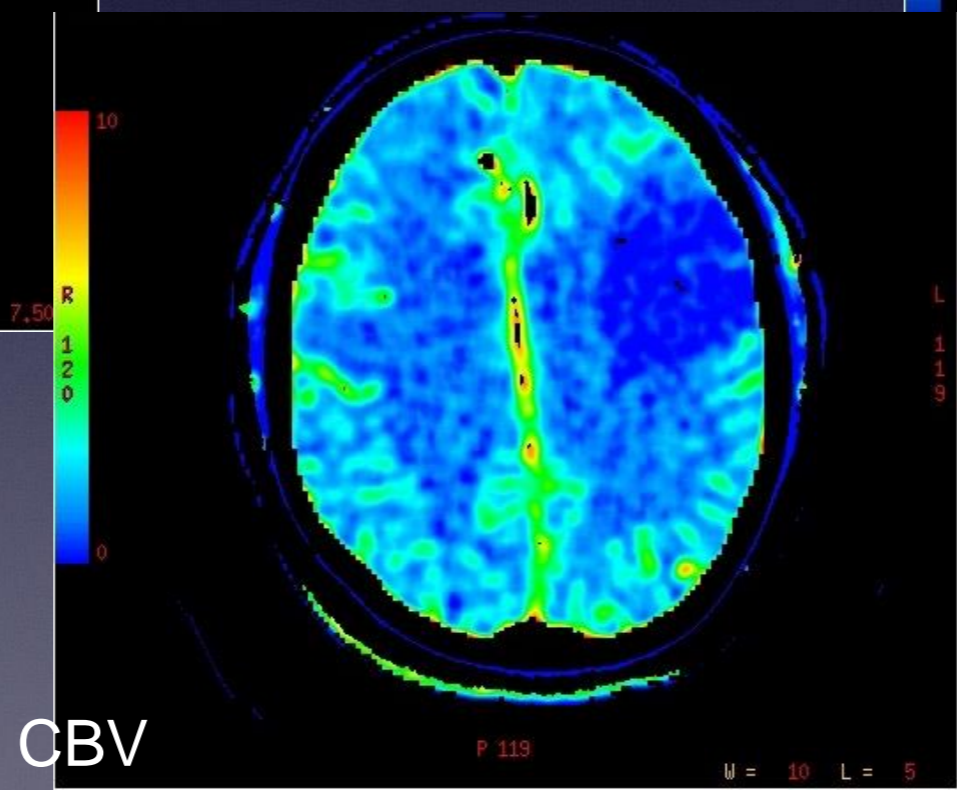
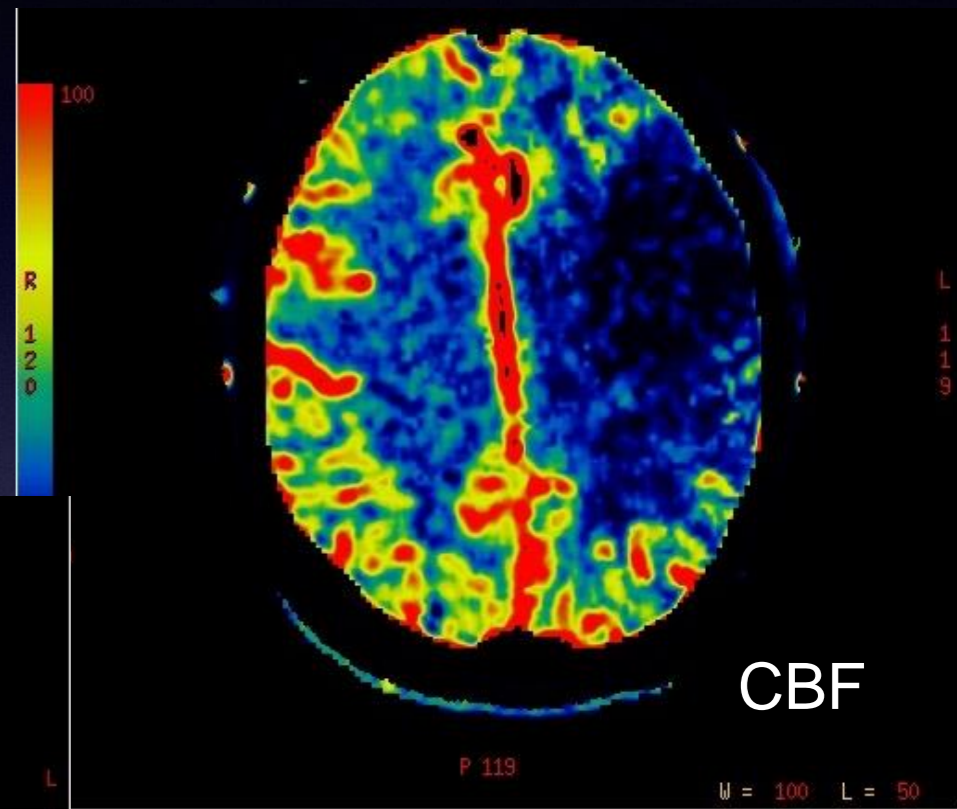
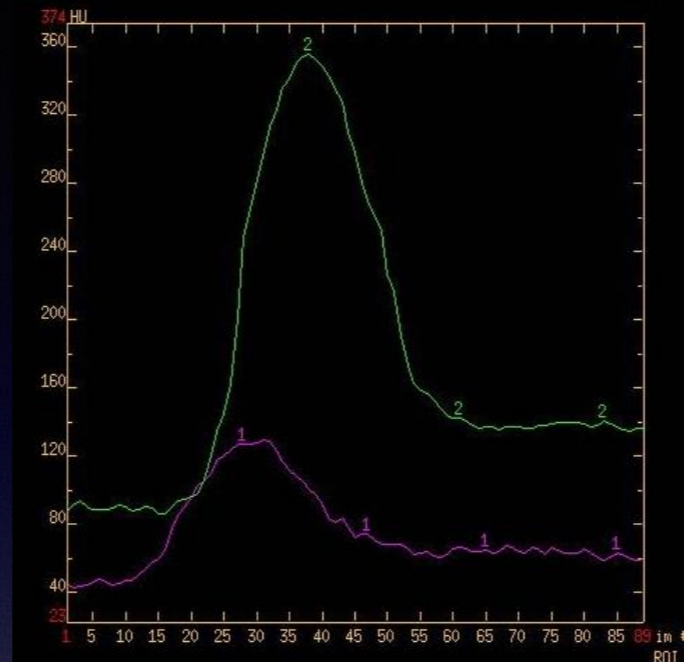
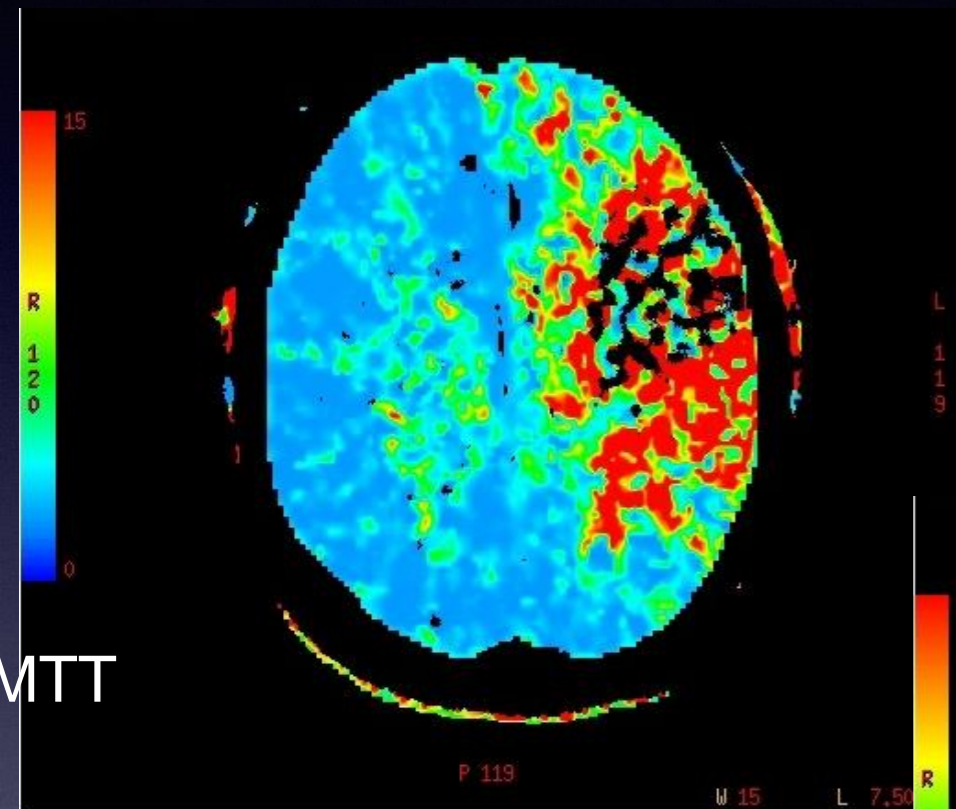
flow

)<sup>2</sup>

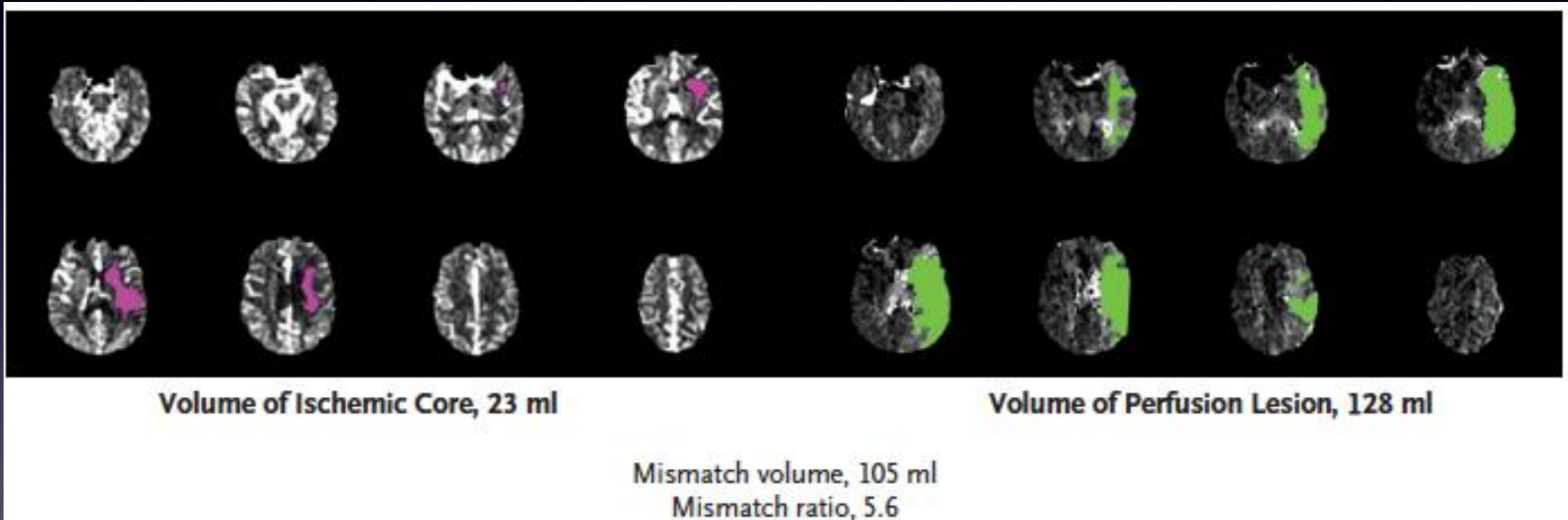
# CT Perfusion in Hyperacute Stroke

3 maps:

- Cerebral Blood Volume (CBV) – Infarct core  
CBV normal 4–6 ml/100 g
- Mean Transit Time [MTT ( $MTT = \frac{\text{cerebral blood volume (CBV)}}{\text{cerebral blood flow (CBF)}}$ )]
  - – Penumbra + core  
MTT normal < 4 sec
- Cerebral Blood Flow (CBF) – Penumbra + core  
CBF normal 50–60 ml/100 g/min  
CBF=CBV/MTT
- Automated software can be used: e.g. RAPID



# DEFUSE 3 TRIAL PATIENT SELECTION



# CT Perfusion in Hyperacute Stroke

## **Infarct core**

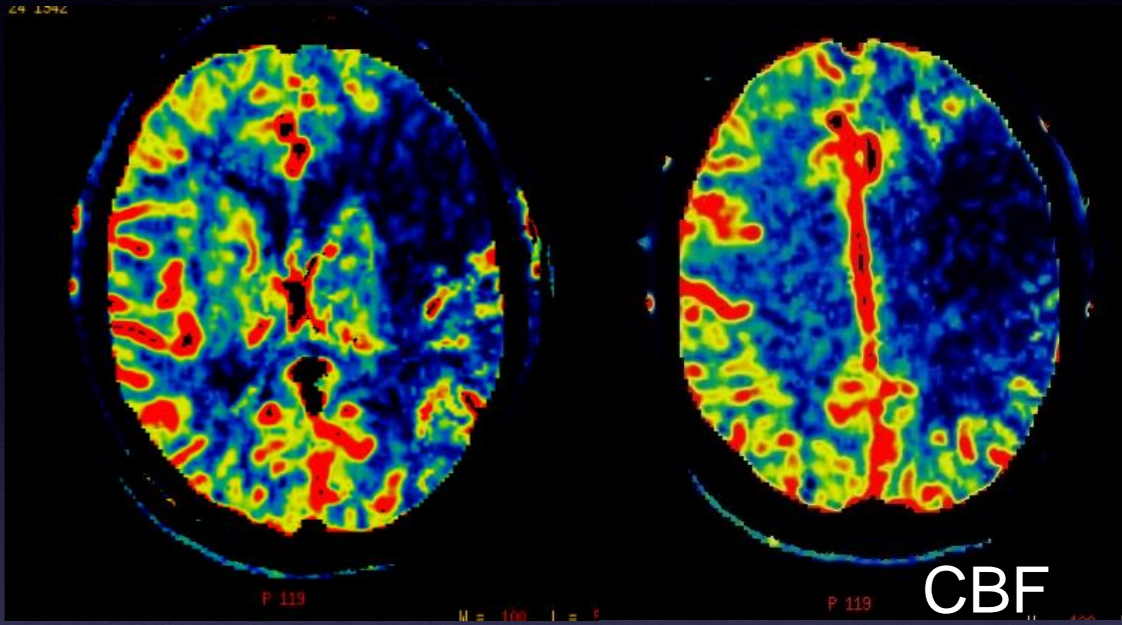
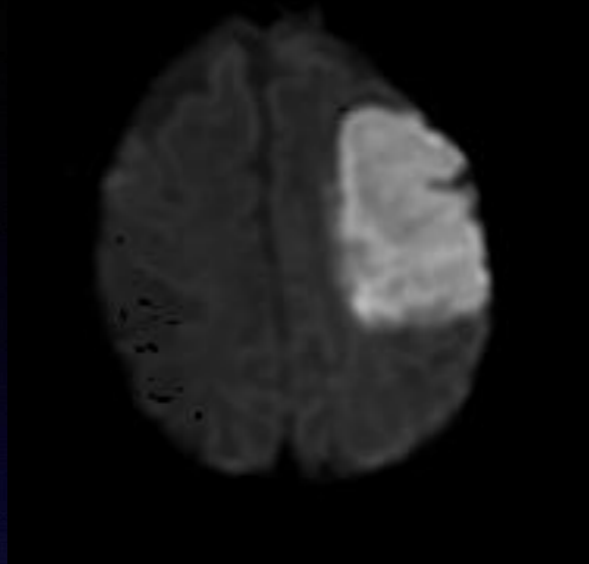
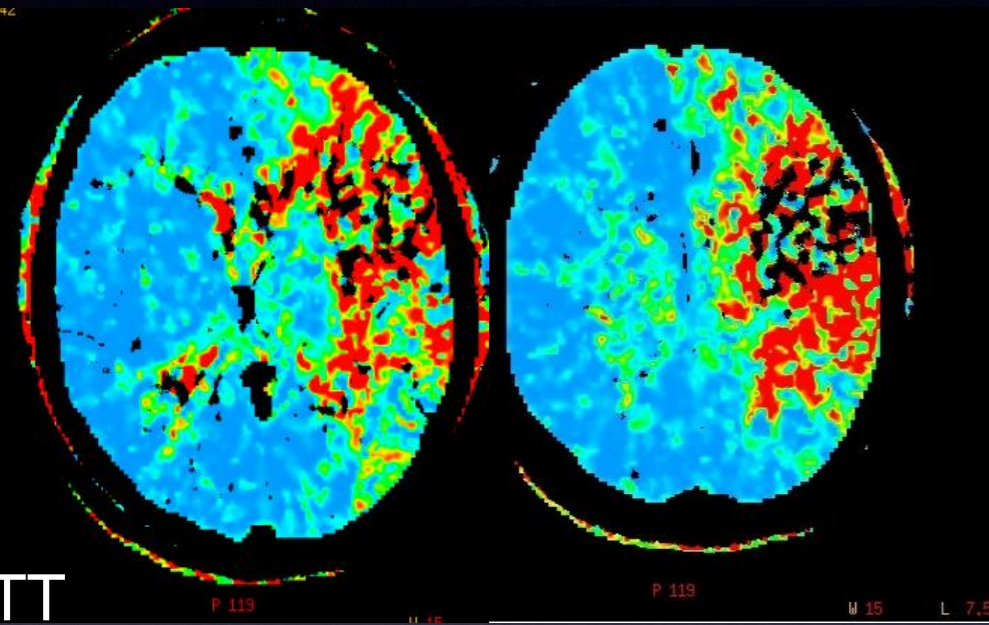
- unsalvageable tissue (better than NECT)
- Area CBF < 30% normal
- Low CBV (<2 ml/100g) / delayed Time to Peak
- Core volume cutoff for treatment: < 70 ml

## **Penumbra**

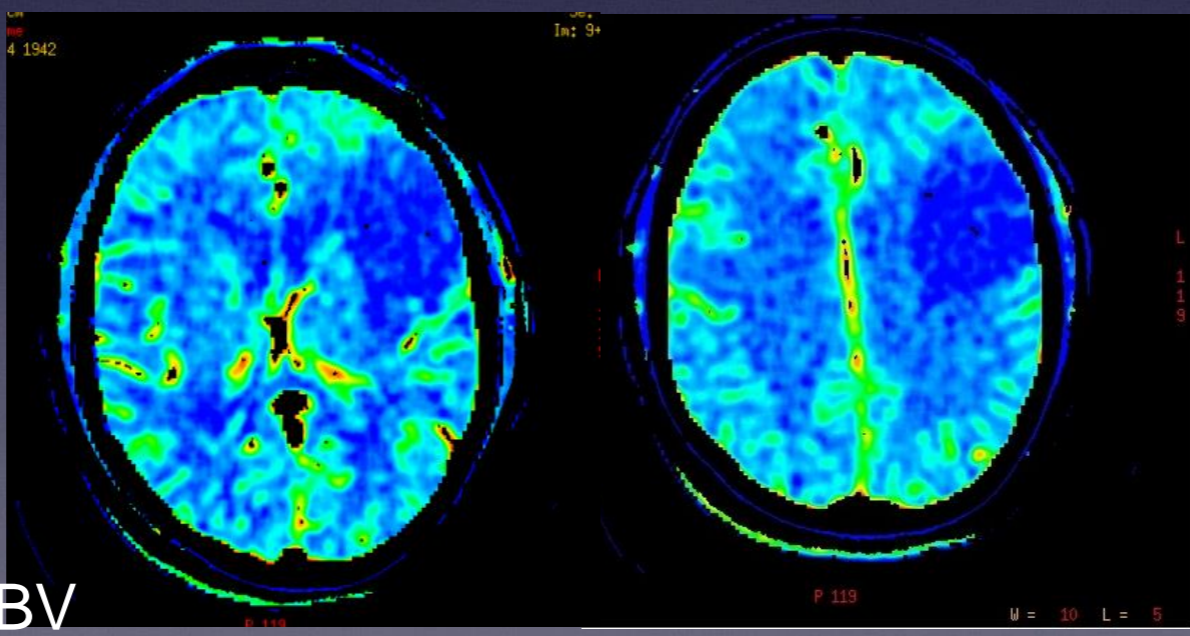
- salvageable tissue with reperfusion
  - MTT >6 sec
- Mismatch to benefit from treatment:
- Ratio: Penumbra/core: 1.8
  - Volume difference  
Penumbra - core: >15 ml



TT



CBV



# CT Perfusion in Patient Selection

- **Rule in:**

- Patients > 6hrs
- Wake-up strokes
- 'Target Mismatch\*'

- a ratio between the hypoperfused tissue (on  $T_{max} > 6$  s maps) and ischemic core on DWI maps of  $\geq 1.8$ , with an absolute difference of  $\geq 15$  mL
- DWI ischemic core volumes  $\leq 70$  mL
- volume of tissue with severe hypoperfusion ( $T_{max} > 10$  s) of  $\leq 100$  mL

- **Rule out:**

- Patients with established infarct (large core)
- Patients with 'malignant profile\*\*'
- Patients with stroke mimickers

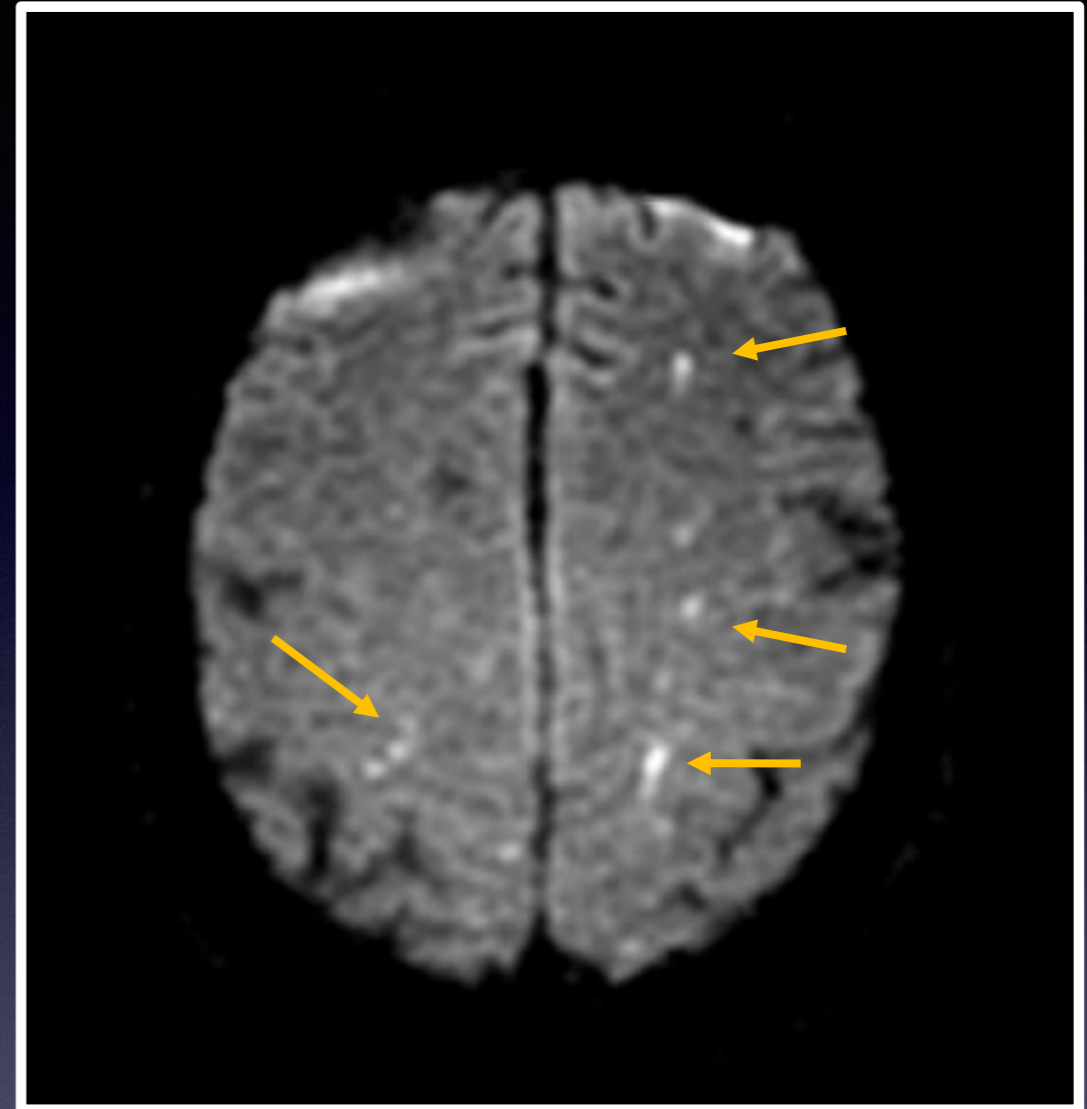
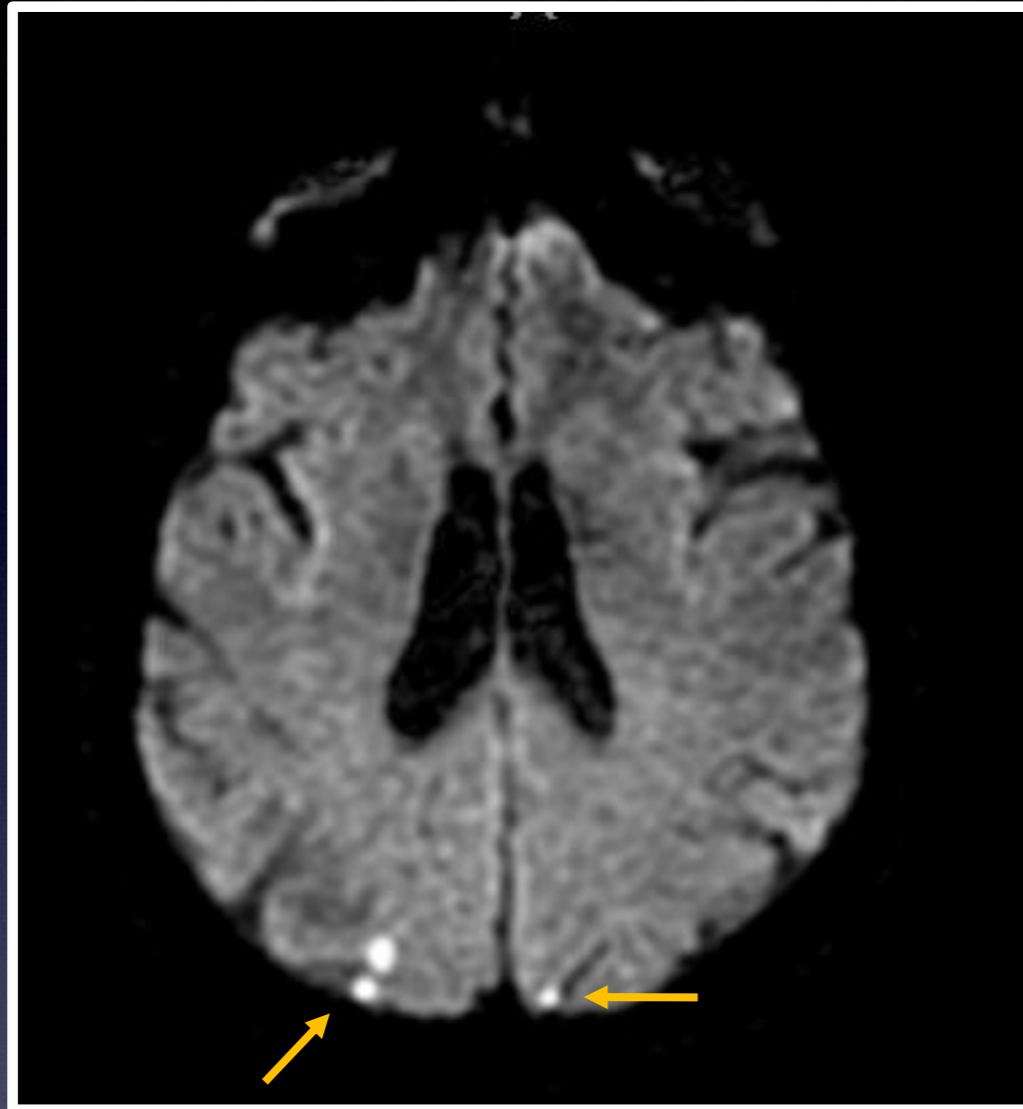
\* patients who would presumably be ideal candidates for reperfusion therapy  
severe cerebral ischemia associated with high likelihood of symptomatic intracranial hemorrhage (SICH) or poor outcome after reperfusion in acute ischemic stroke

# Interventional Stroke Treatment

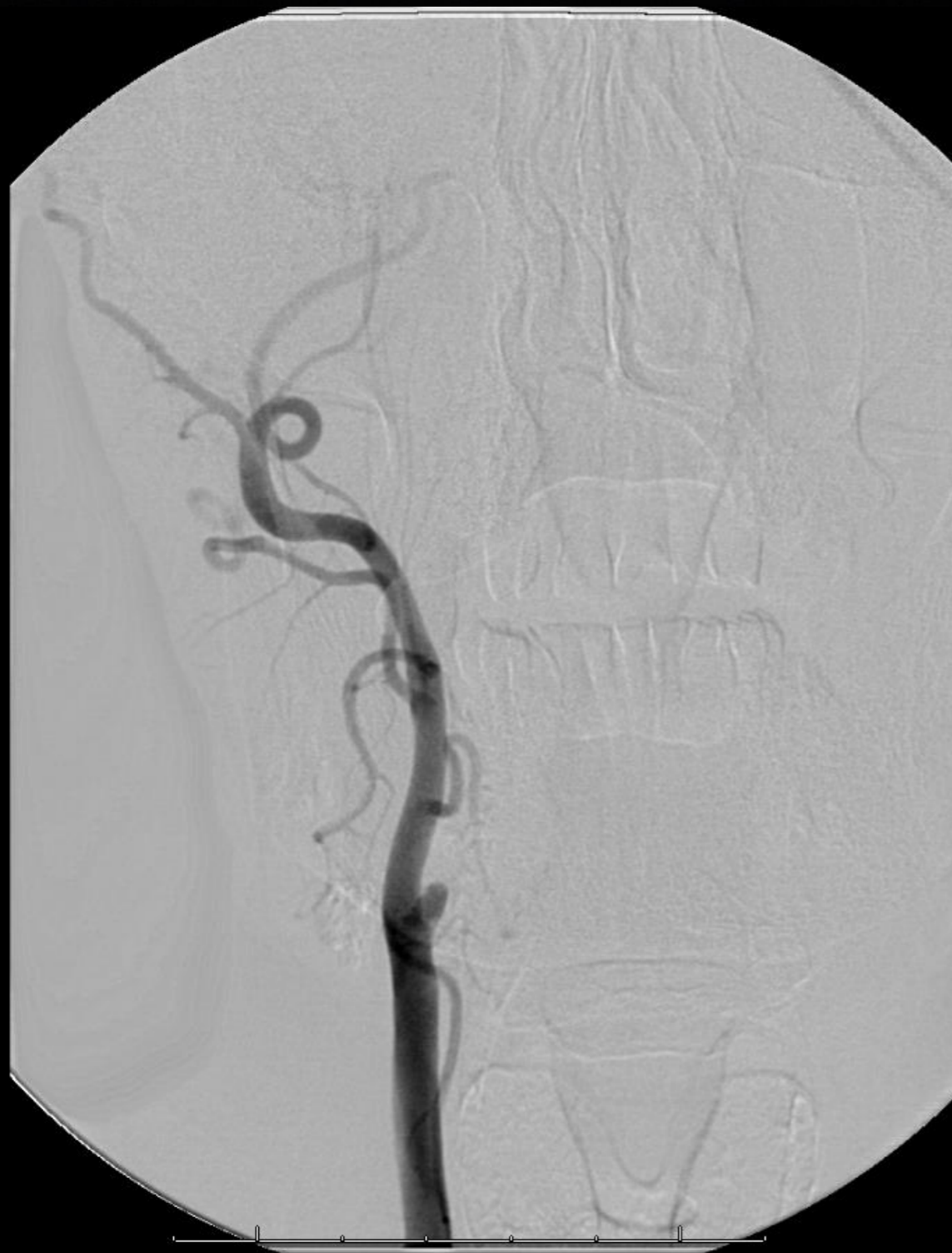## Potential IA candidate?

1. Neurologic deficit - NIHSS > 6
2. Presence of salvageable brain tissue
  - Time window - **up to 24** hrs
  - ?ASPECTS score >3
3. Presence of large vessel occlusion (LVO)
  - => vascular imaging (CTA, angio), collateral circulation

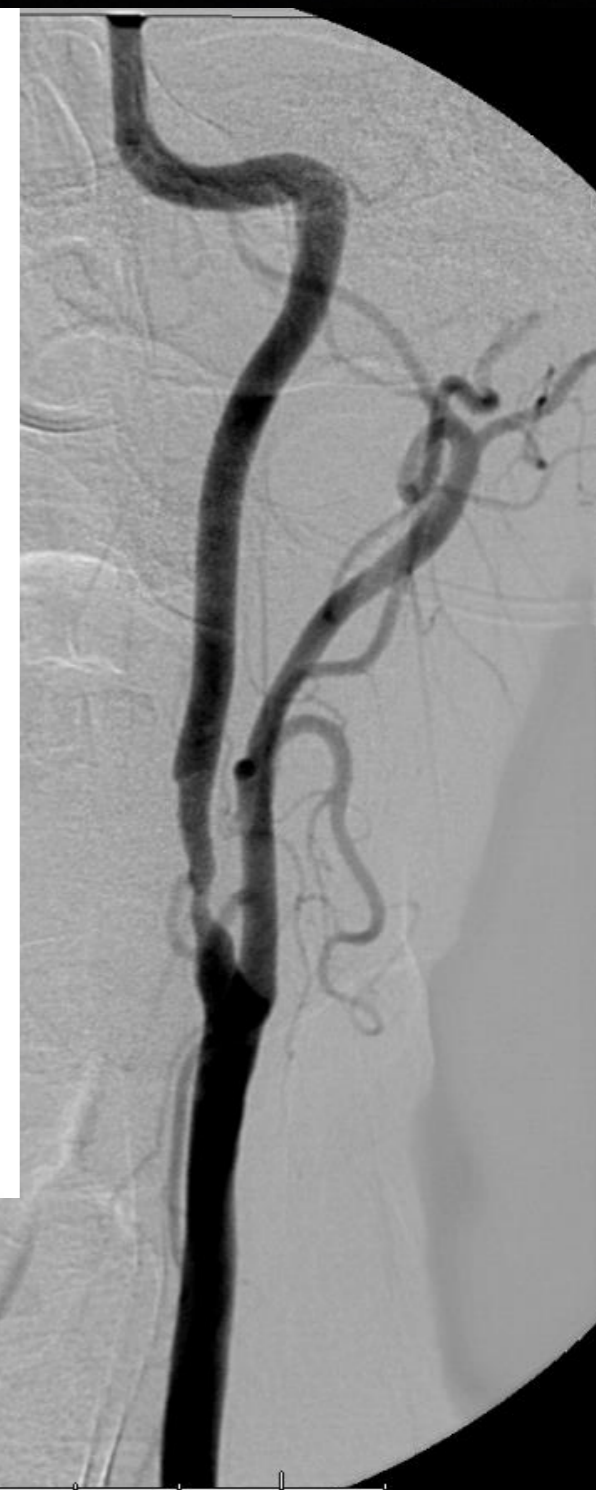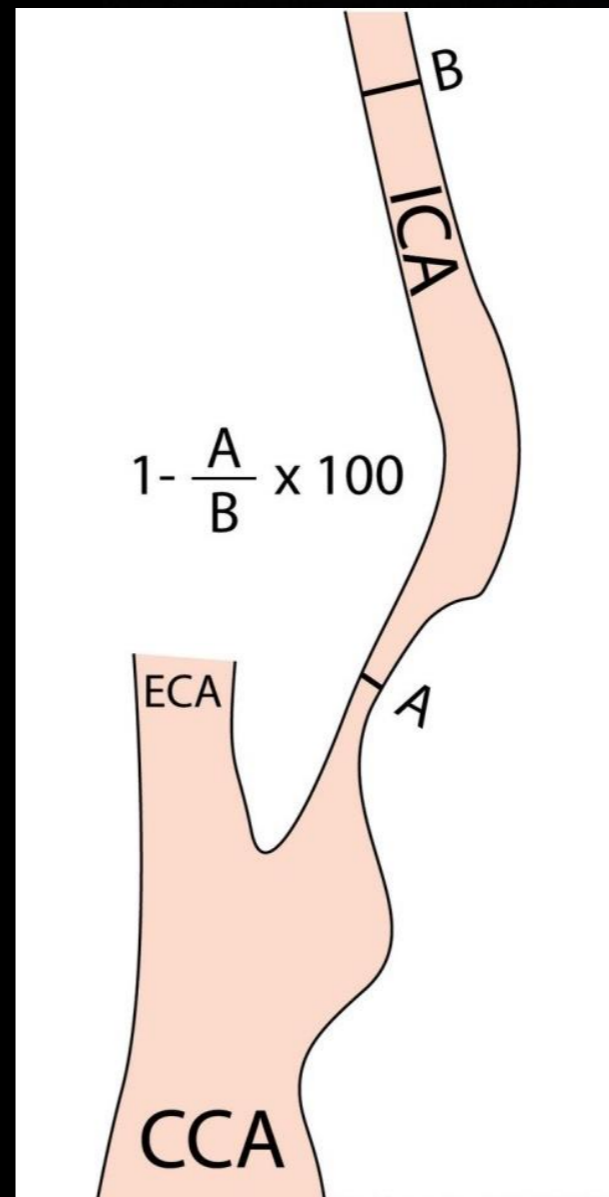
- ▣ 75 yo M with shaking weakness of RUE.



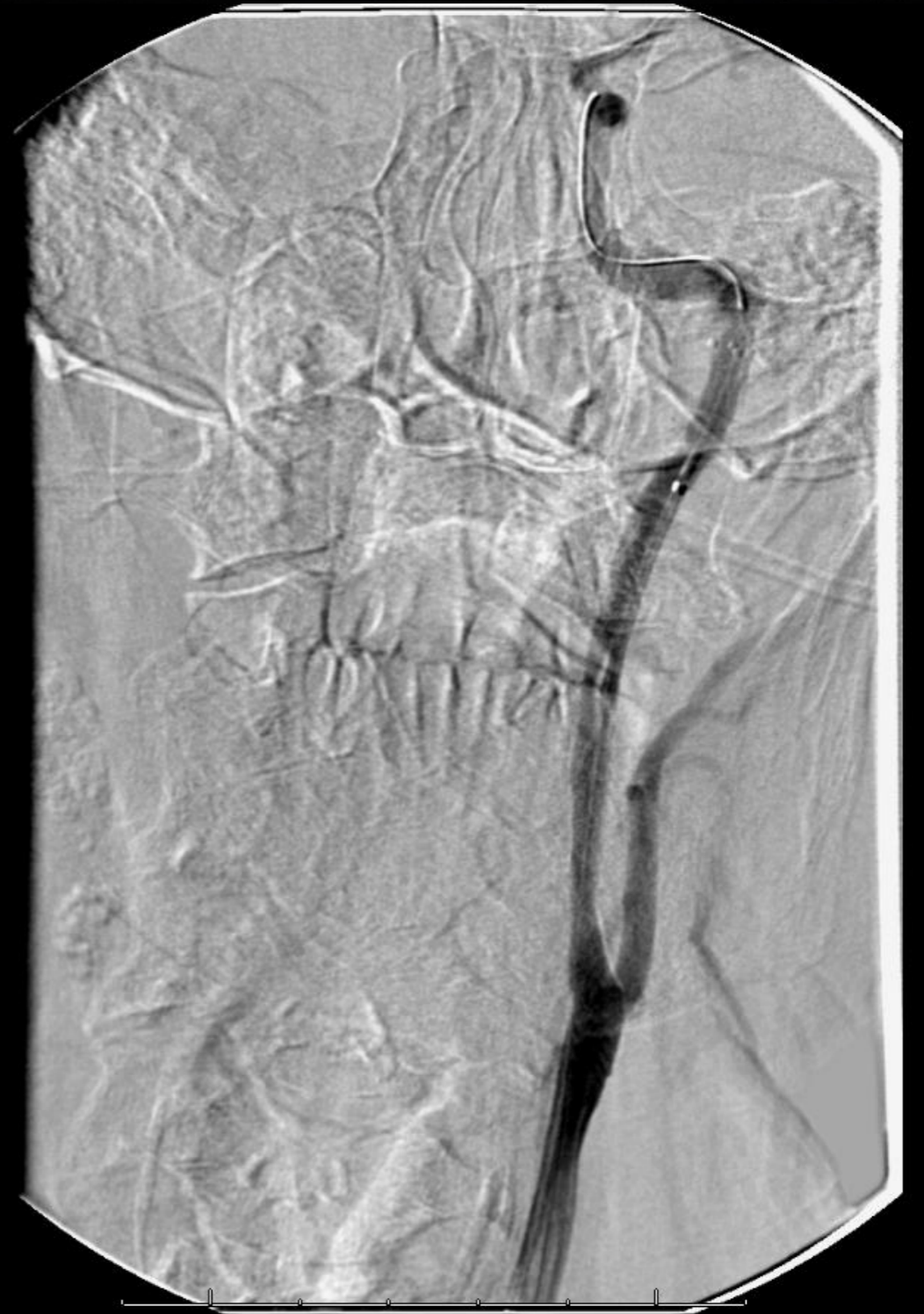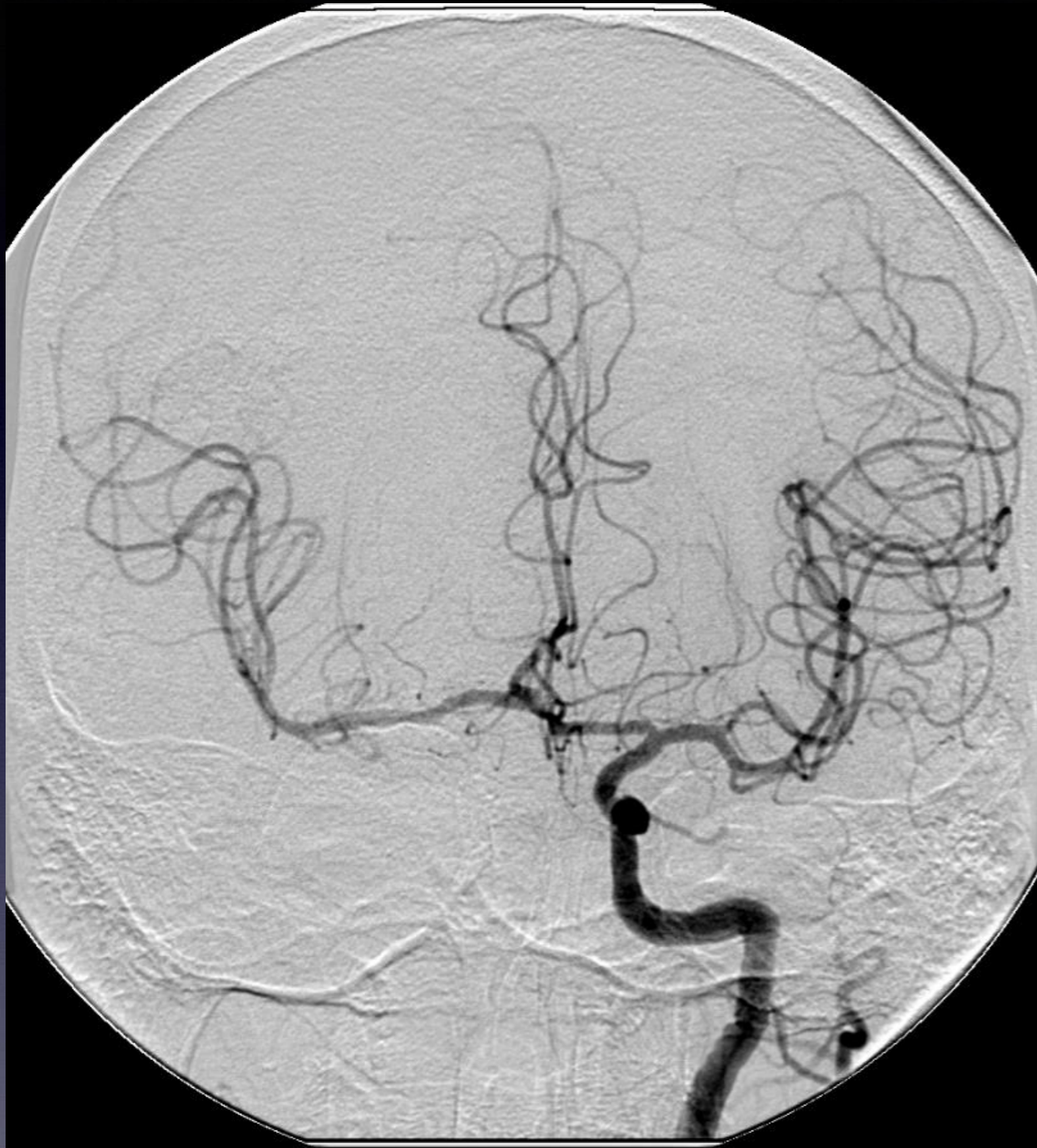
“String of beads” distribution in the deep WM, “deep watershed zone”  
Posterior cortical watershed zone (MCA/PCA)  
-> hypoperfusion  
*HEMODYNAMIC ETIOLOGY of the STROKE*



Right carotid artery

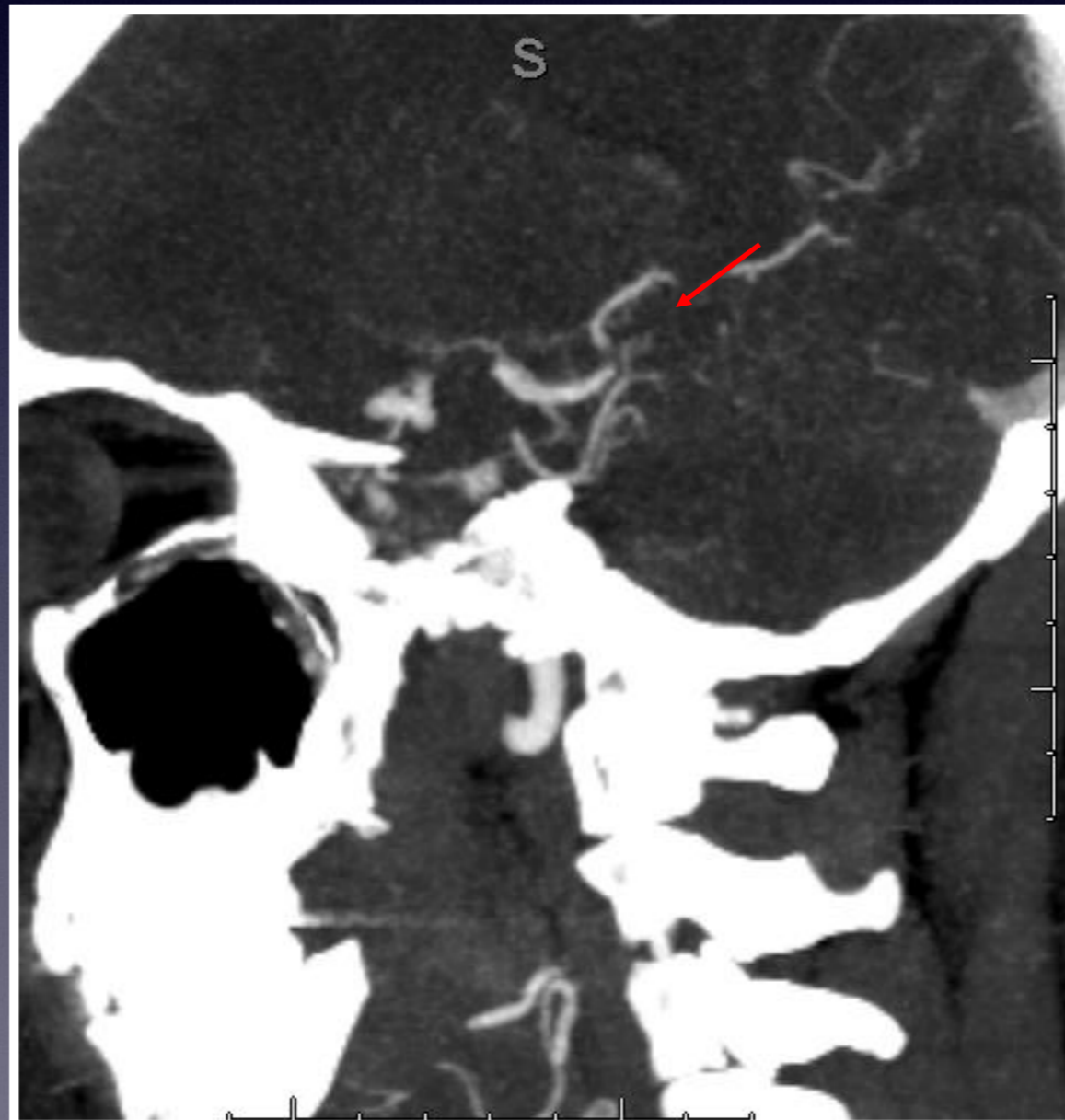
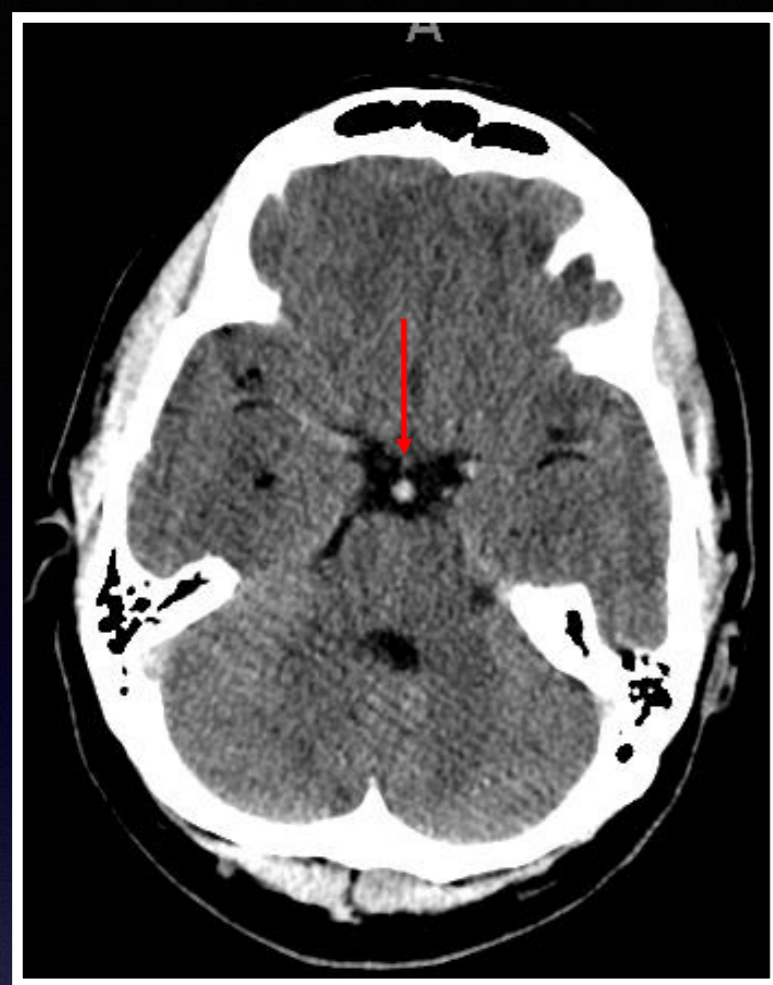


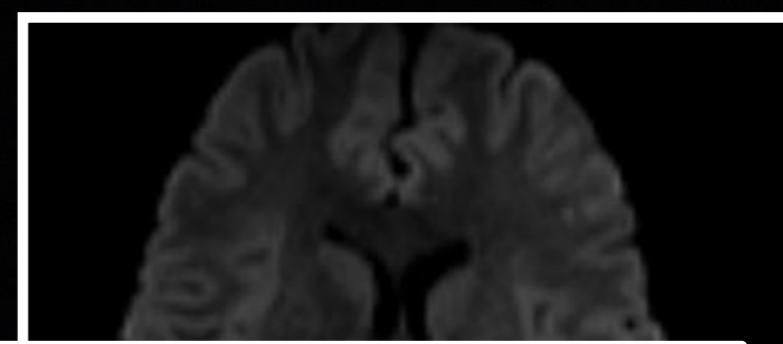
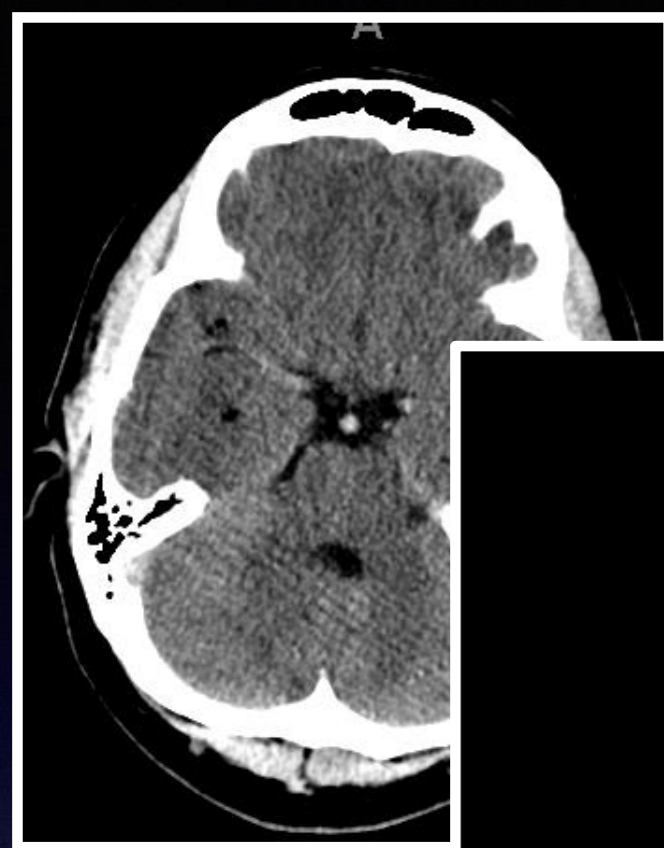
Left carotid artery



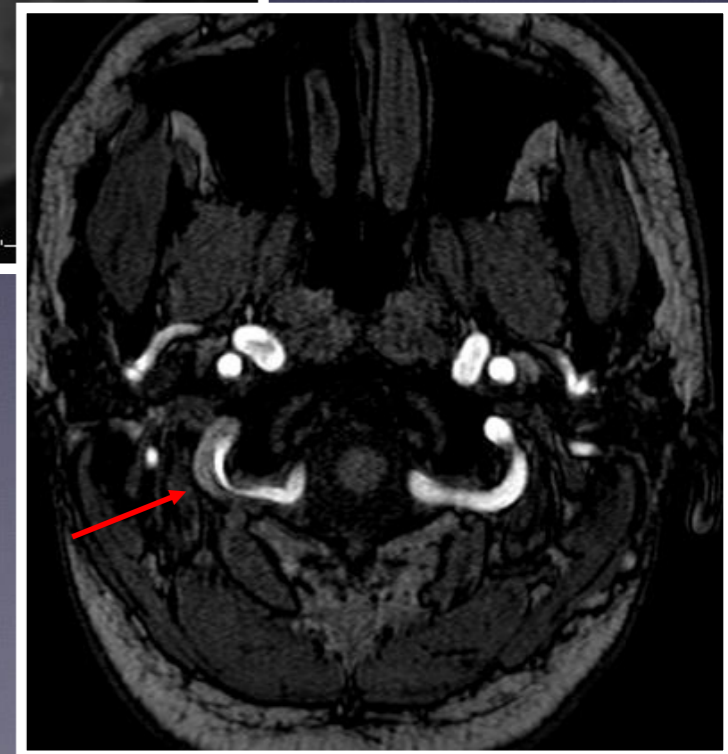
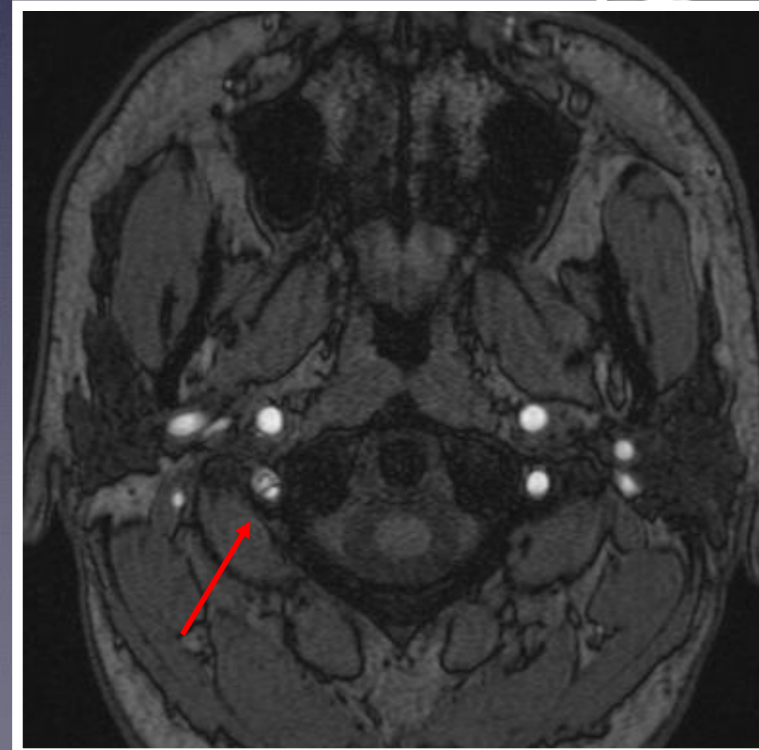
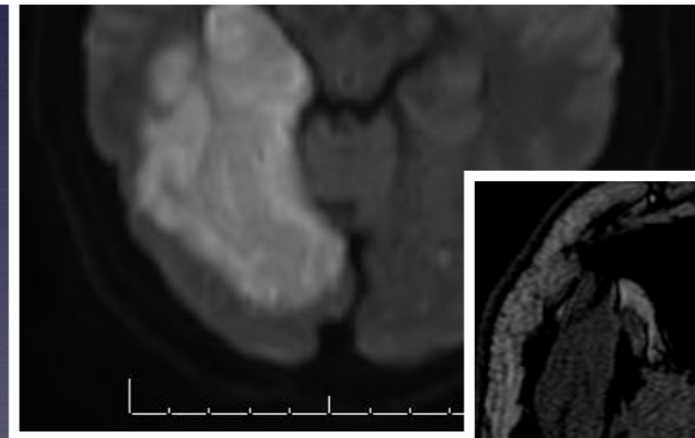
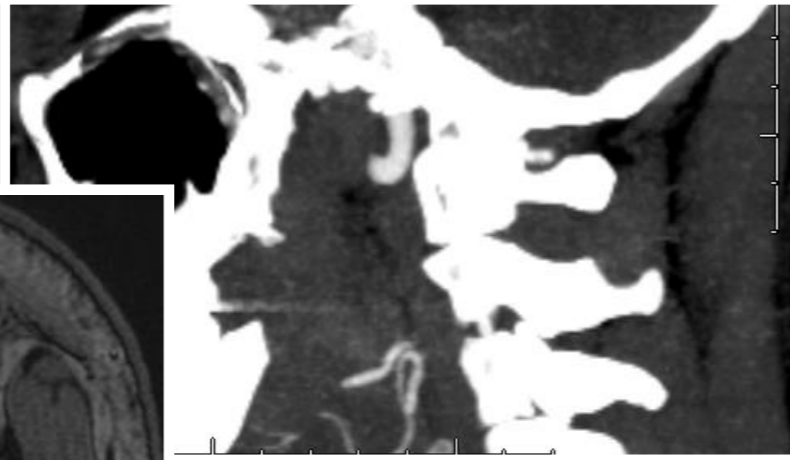
Left carotid artery

30 year old with neck pain followed by vertigo and suddenly became obtunded



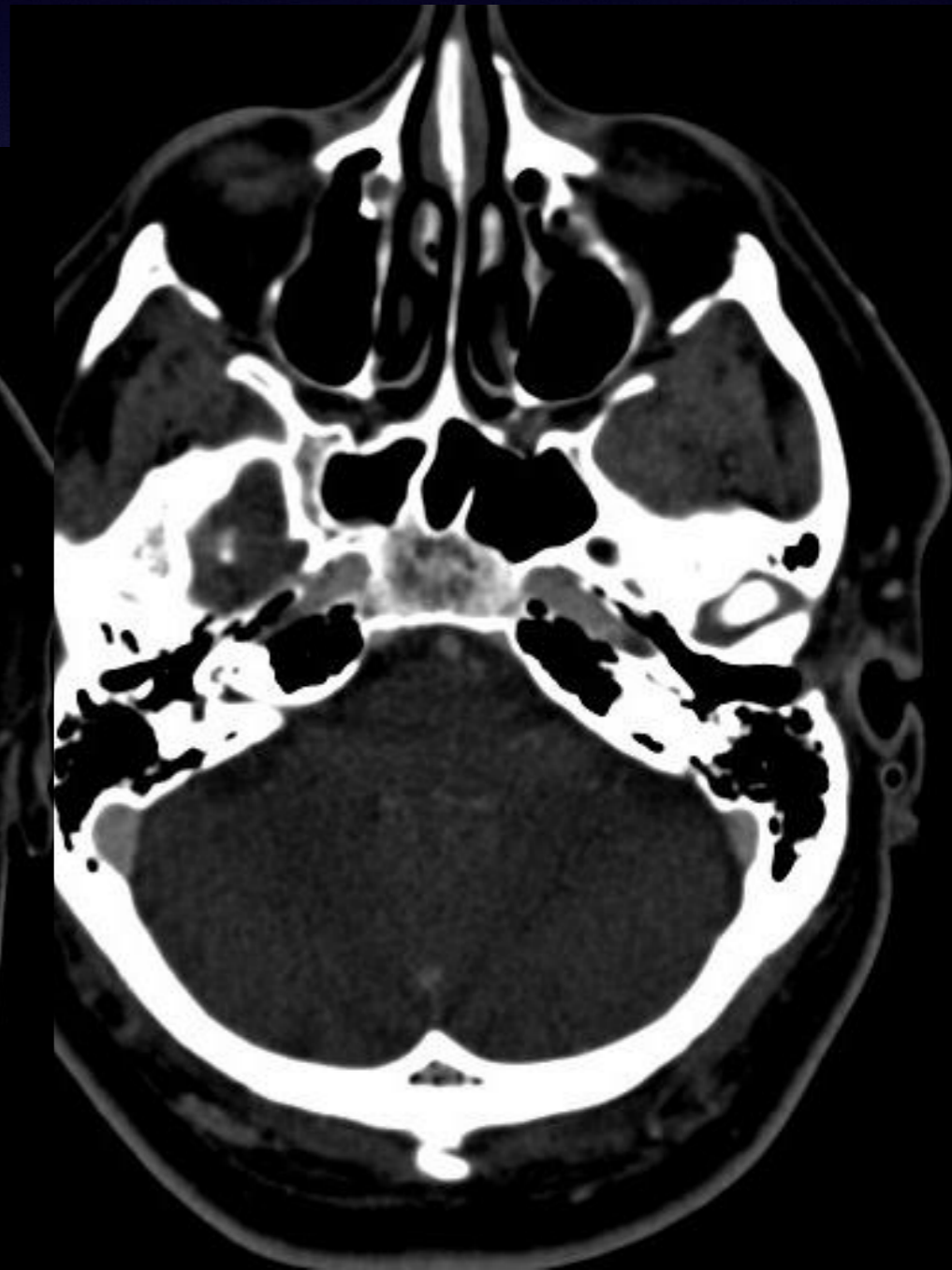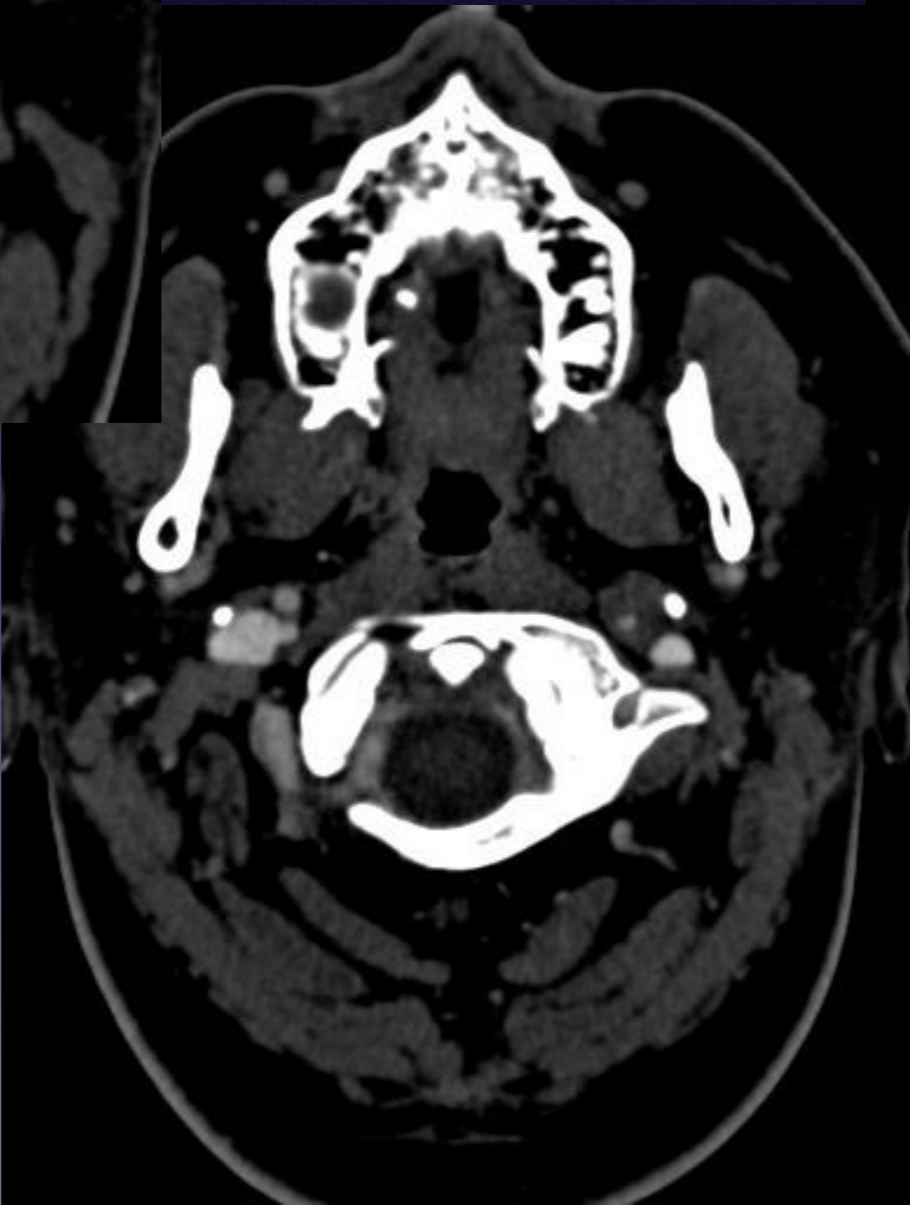
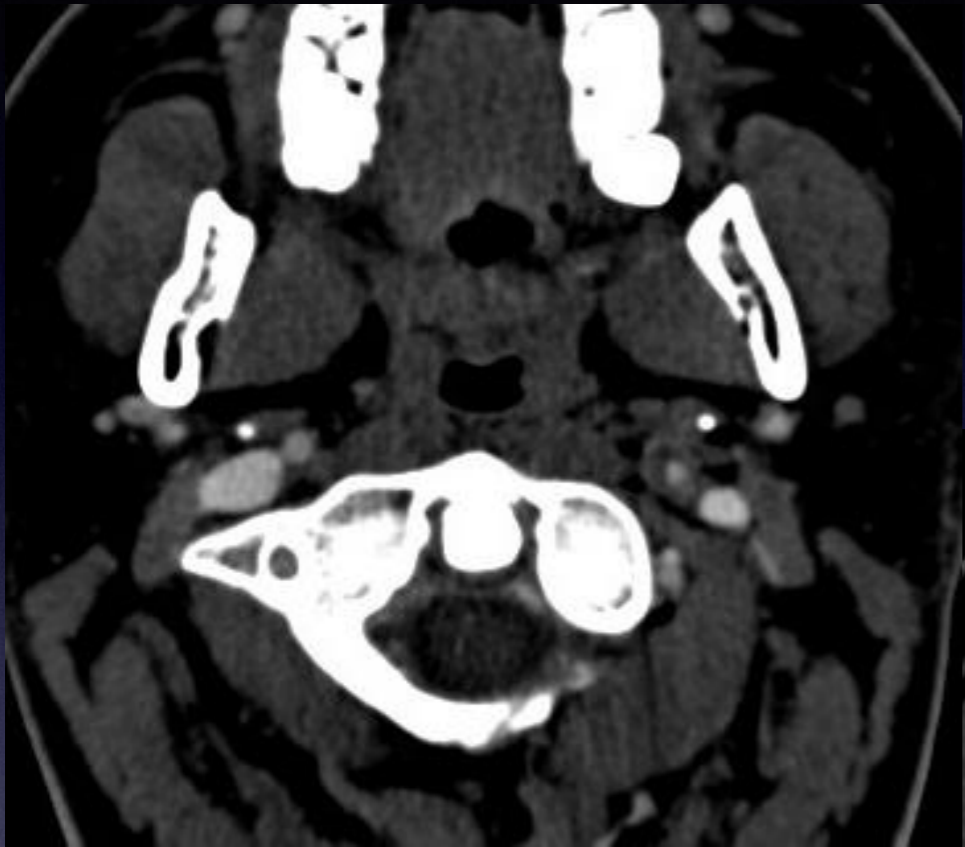


- ▣ **Arterial dissection**
  - ▣ High cervical ICA/VA
  - ▣ Extracranial, can extend intracranial
  - ▣ Mural hematoma, dissection flap, vessel expansion
  - ▣ Luminal narrowing, pseudoaneurysm
  - ▣ Hypoperfusion/emboli

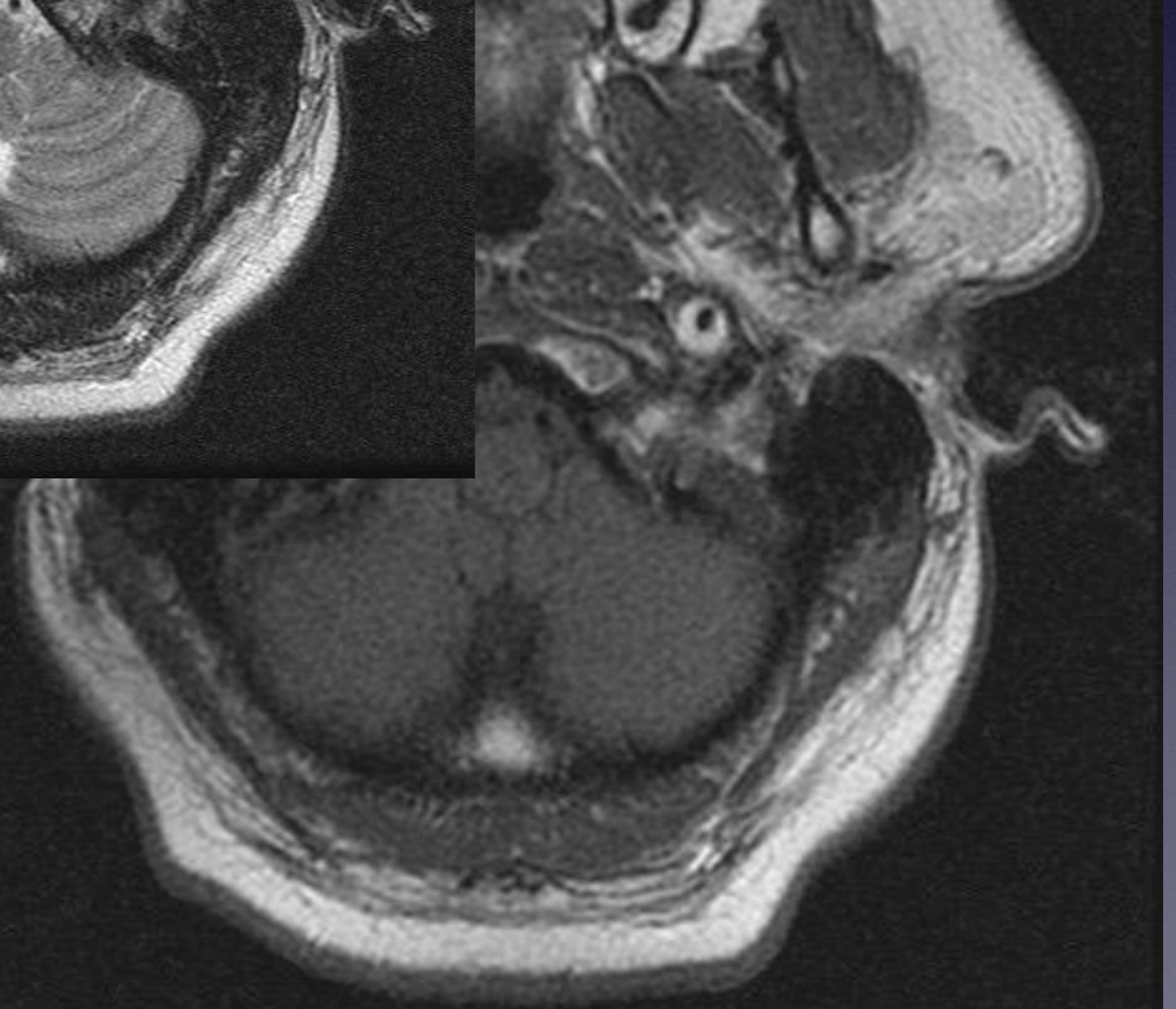
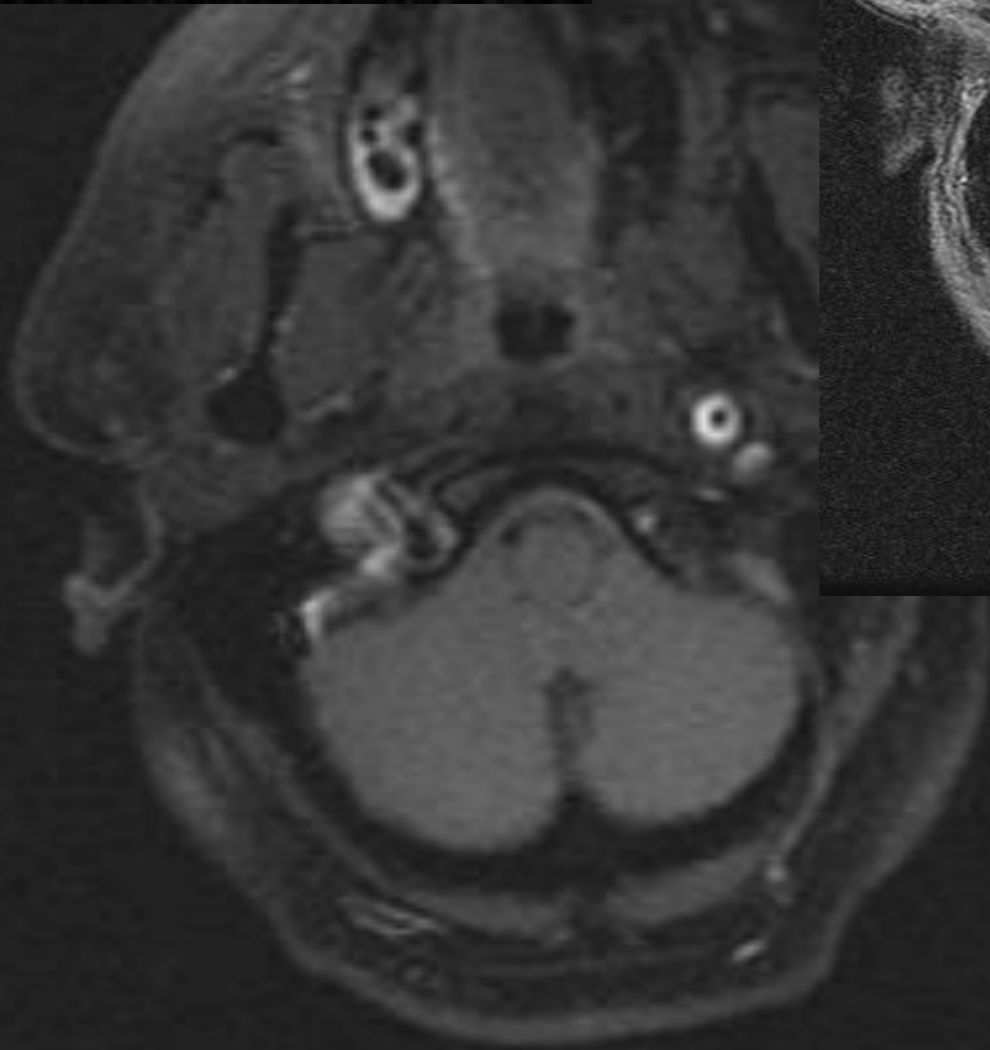
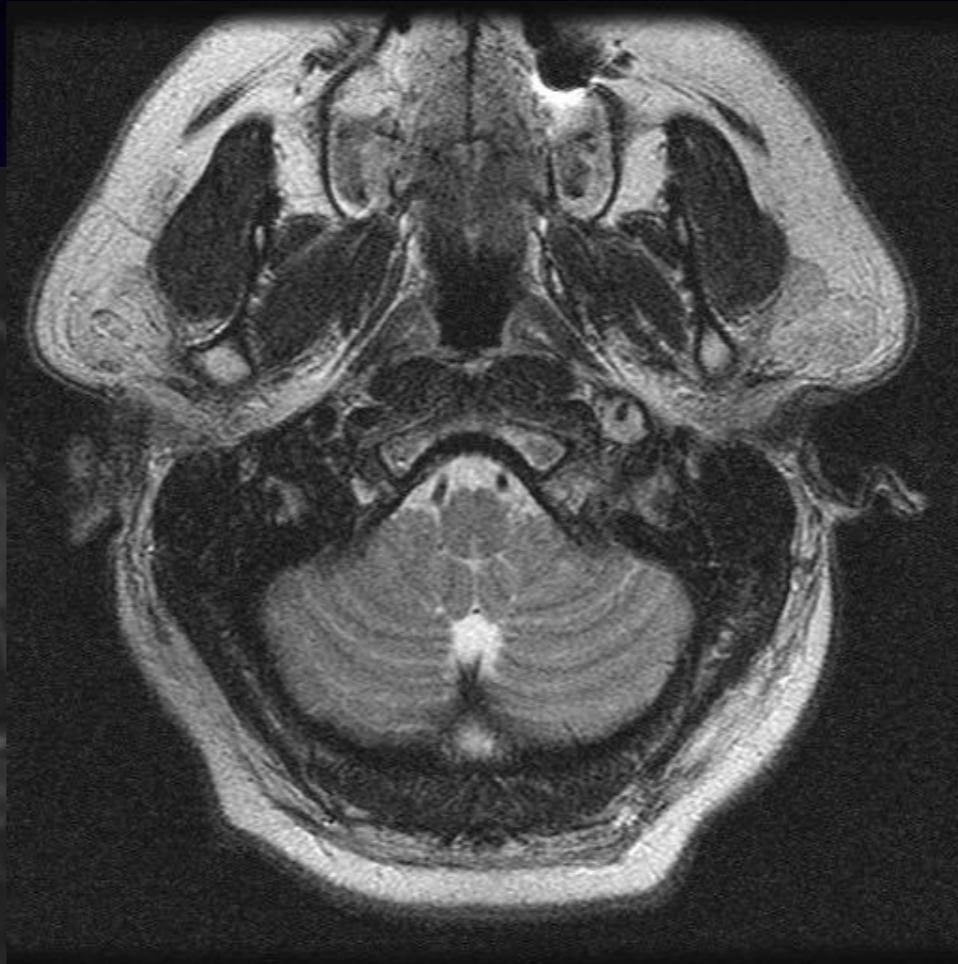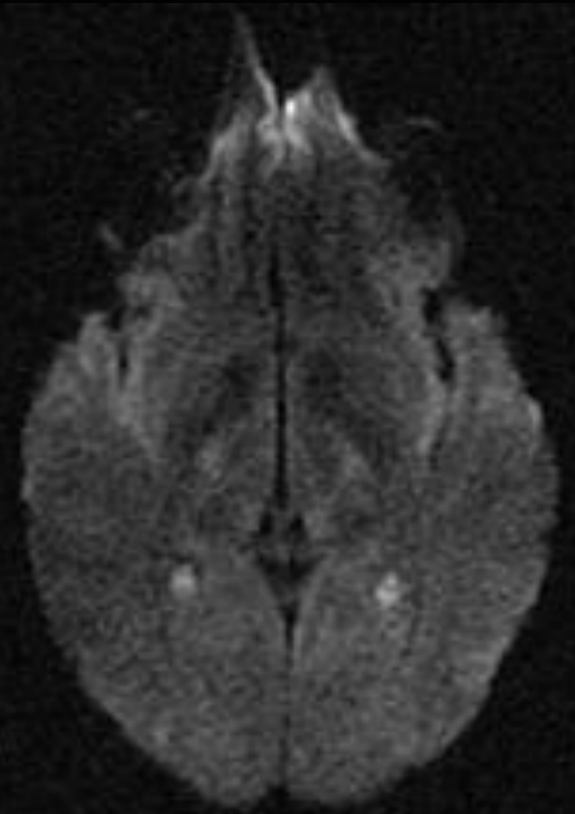

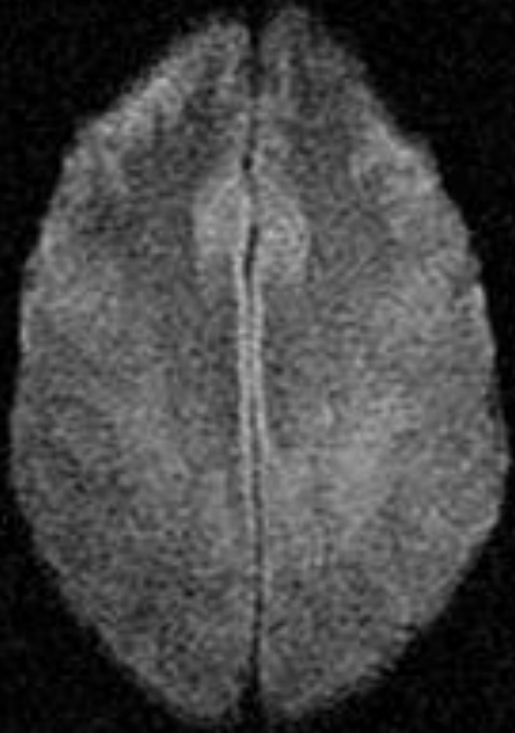


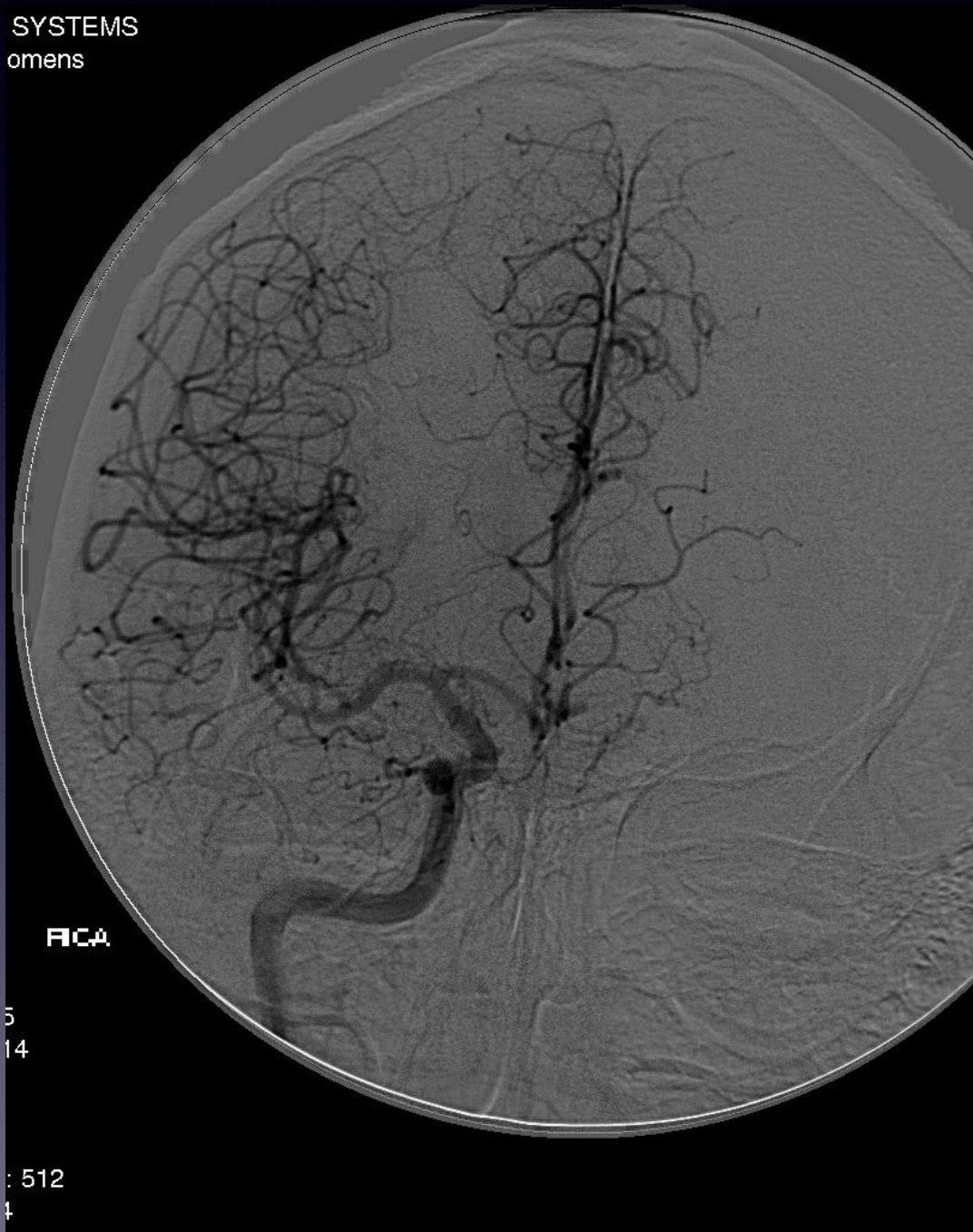Ασθενής 48 ετών με Horner αριστερά,  
αίσθημα ζάλης και κεφαλαλγία αριστερά



# MRI



SYSTEMS  
omens

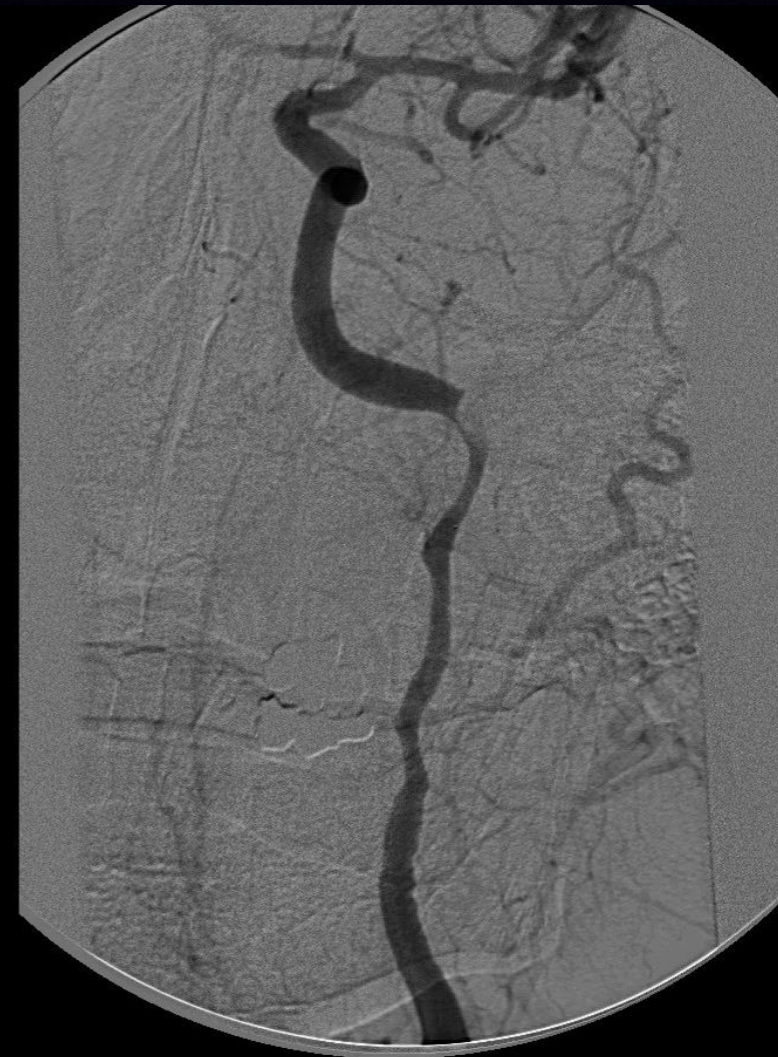

FICA

5  
14

: 512  
4

Digital subtraction angiography  
CG/KF



LICA

# 20003499  
M Aug 14 1960  
LICA

Mar 27 2006  
20:38:08

(Shut.)(Filt. 7)

FRNT  
Seq: 6  
FRAME = 10 / 16  
MASK = 1

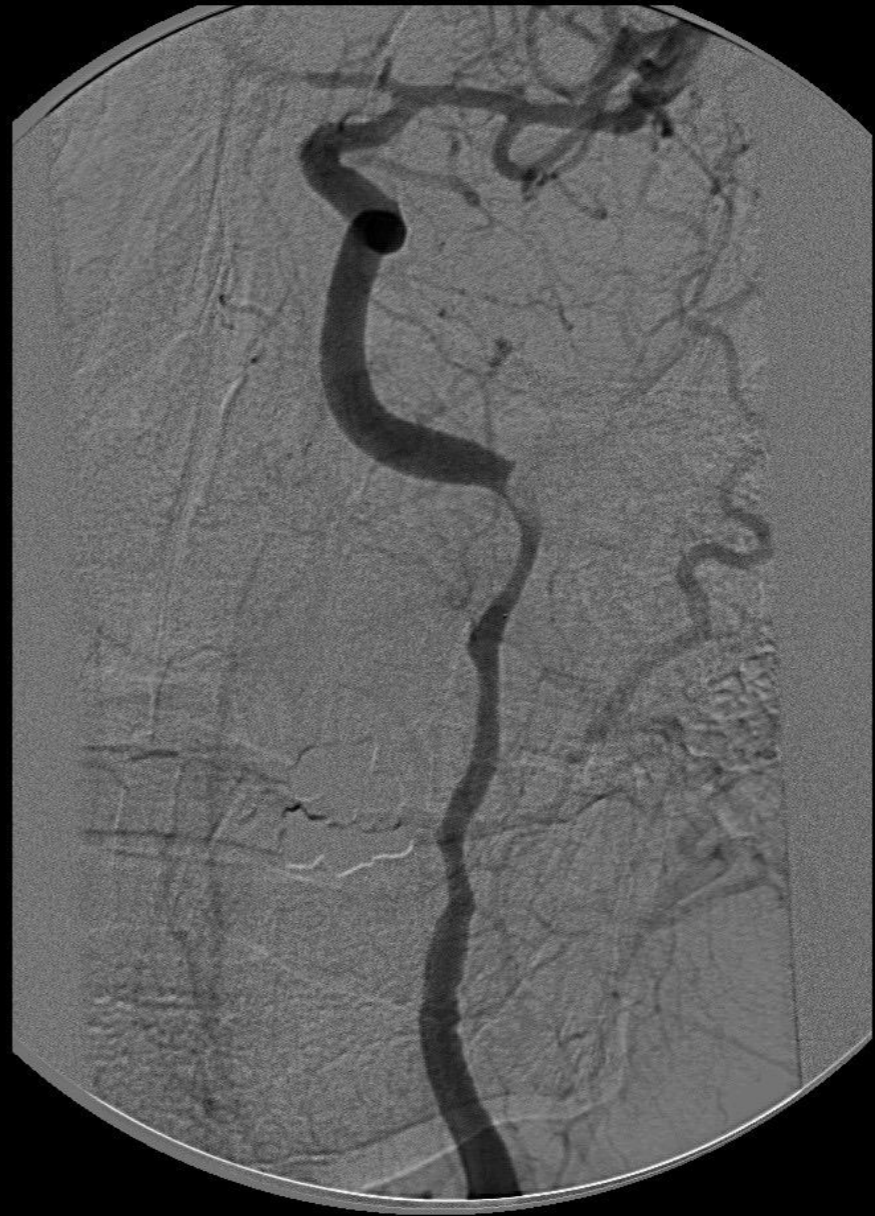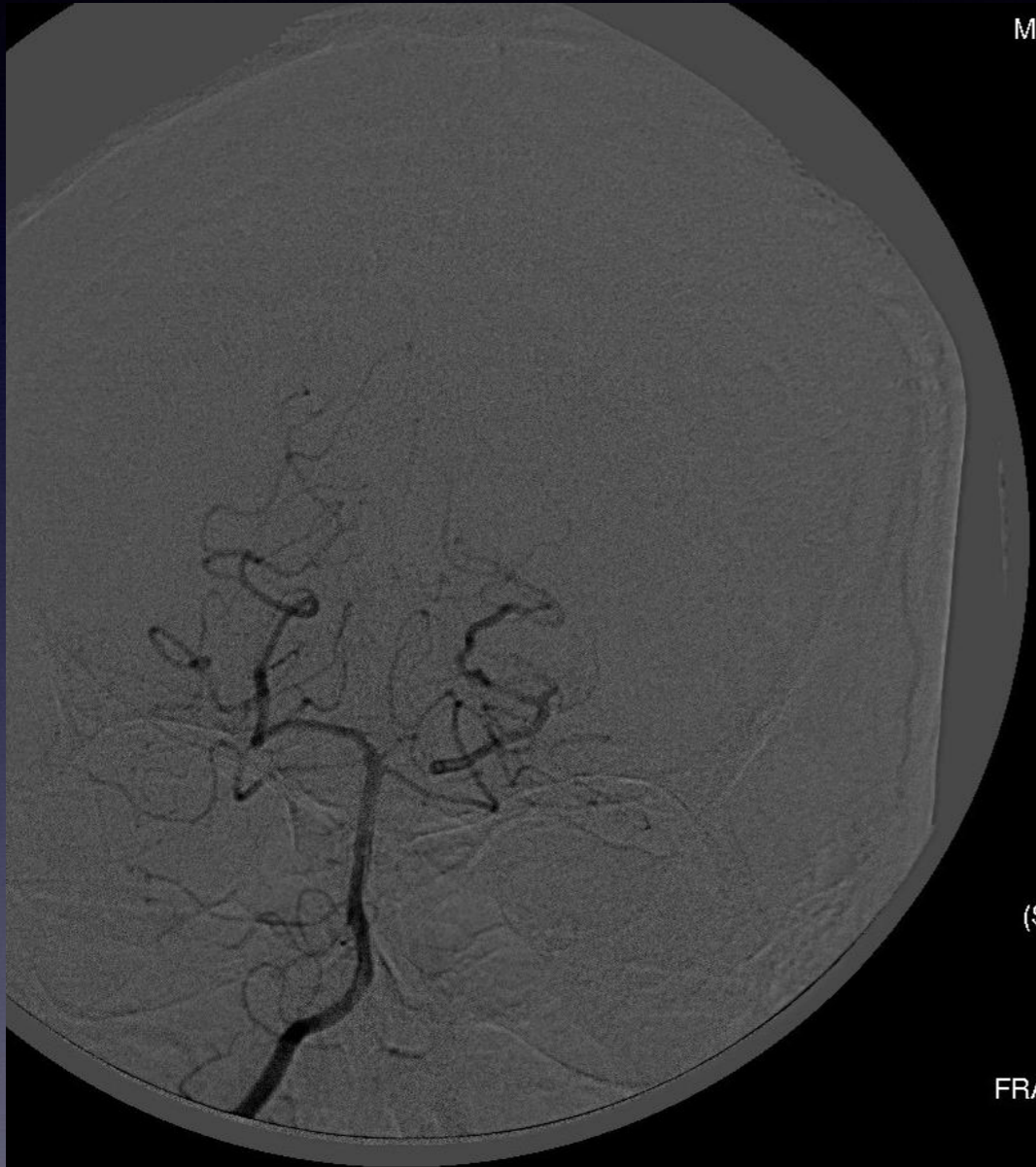depart. RAO: 5  
depart. CAU: 8  
depart. L: -2  
Mag = 1.00  
FL: ROT:  
WW: 1024WL: 512  
XA 1024x1024

M Aug 14 1960  
RT

Mar 2  
21

(Shut.)

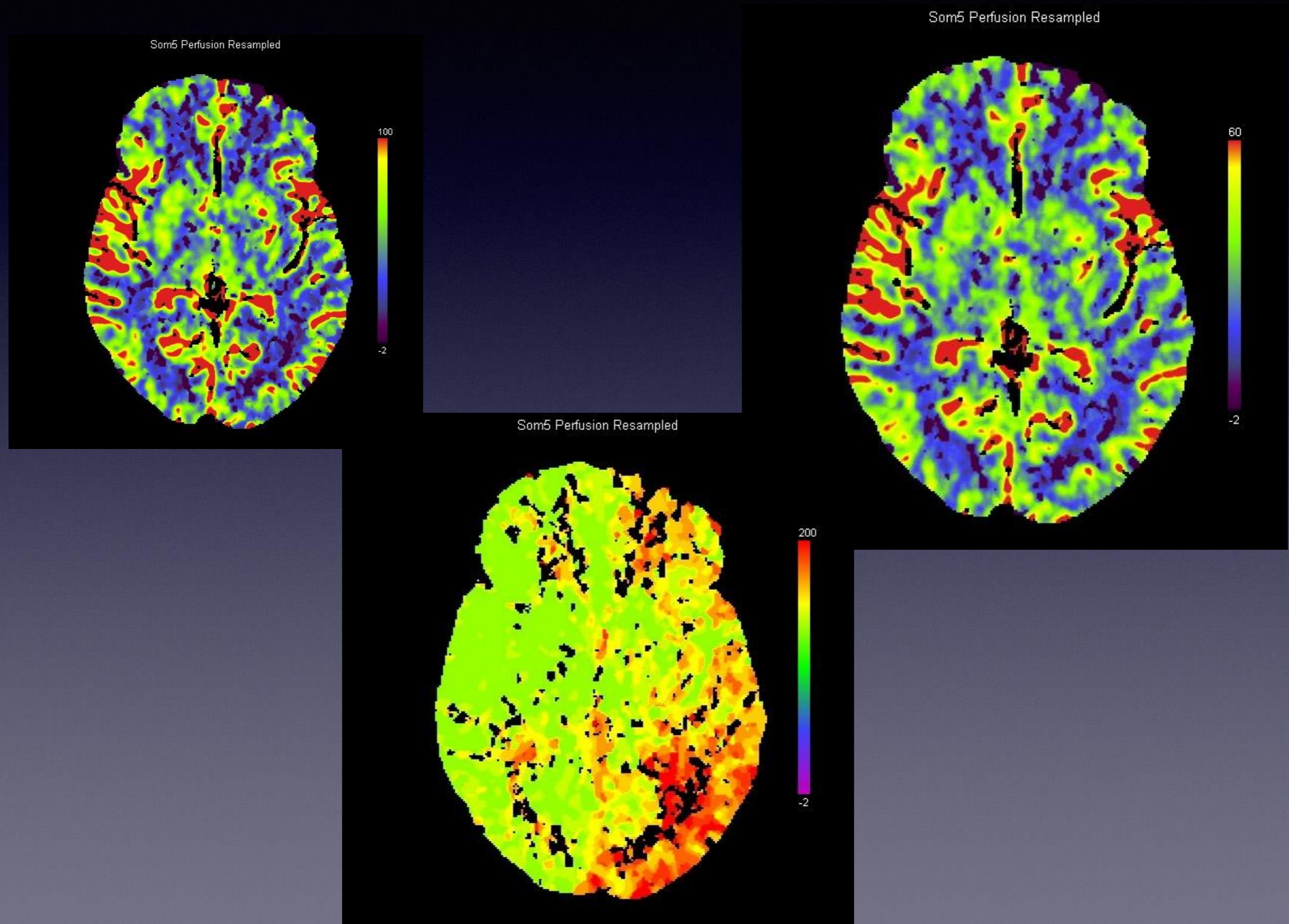
FRAME =  
MA:



LCA

E

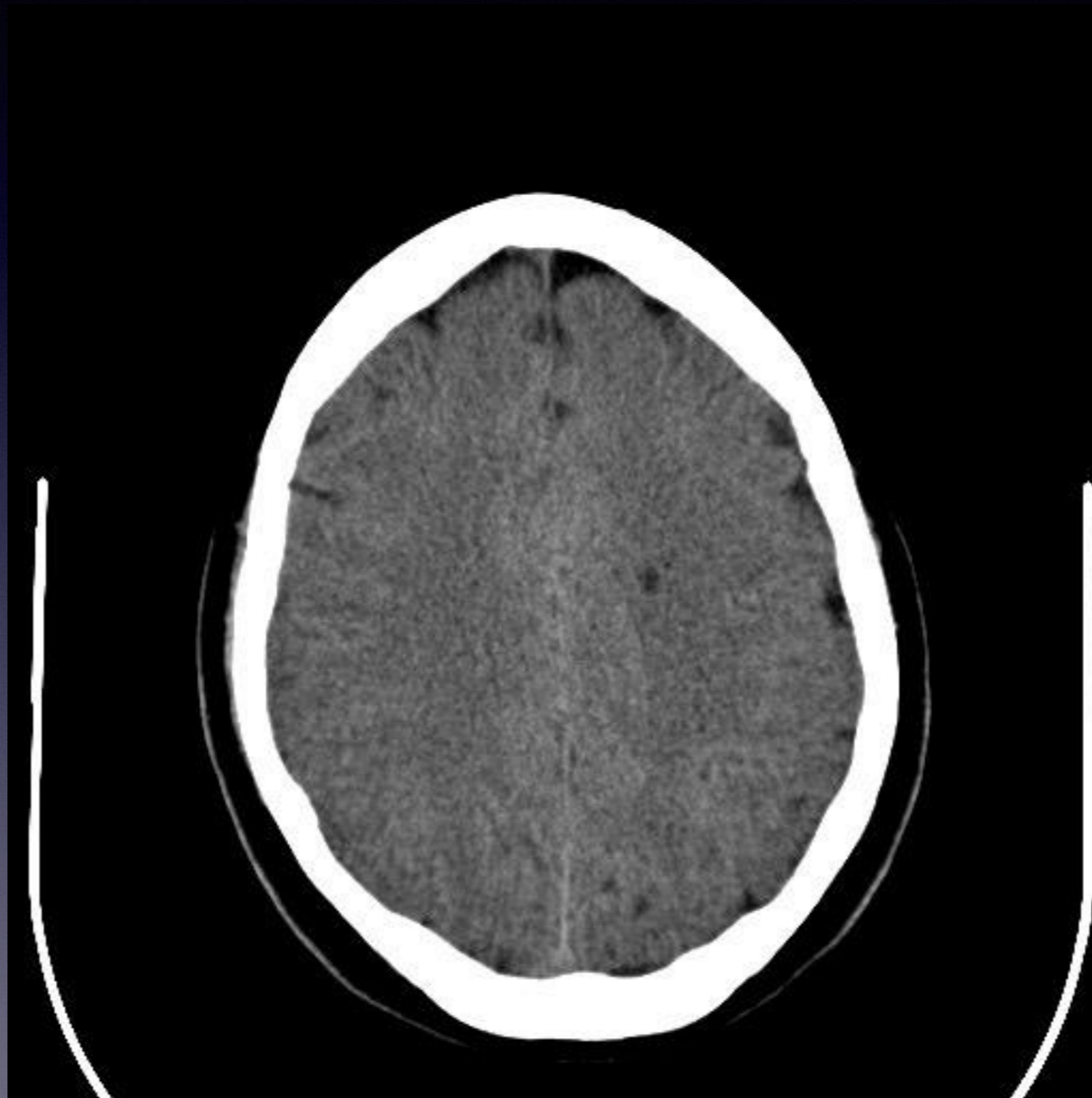# CBF CBV TTP



# Θεραπεία

- Αντιπηκτική αγωγή για 6 μήνες
- Ασυμπτωματικός

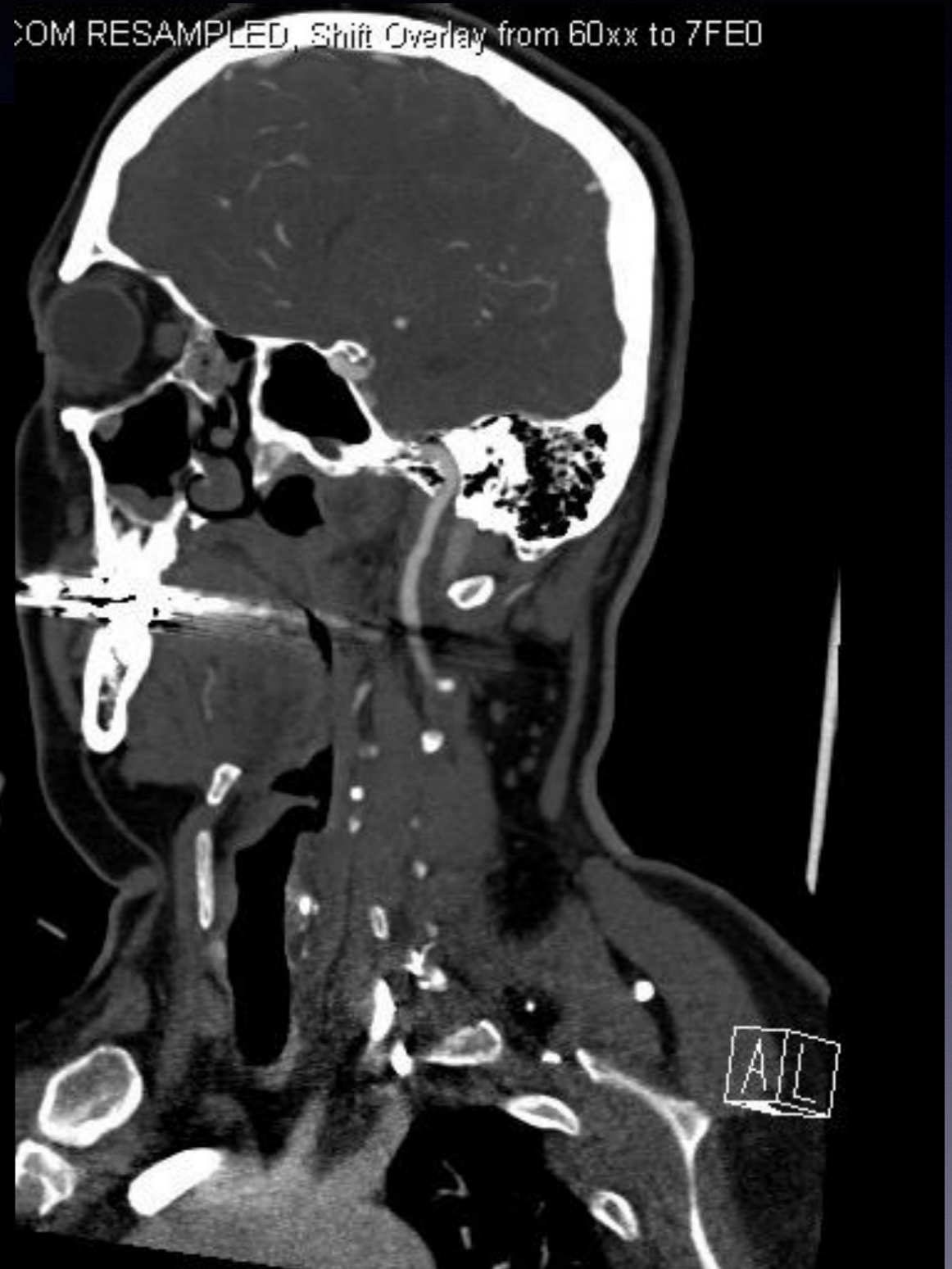
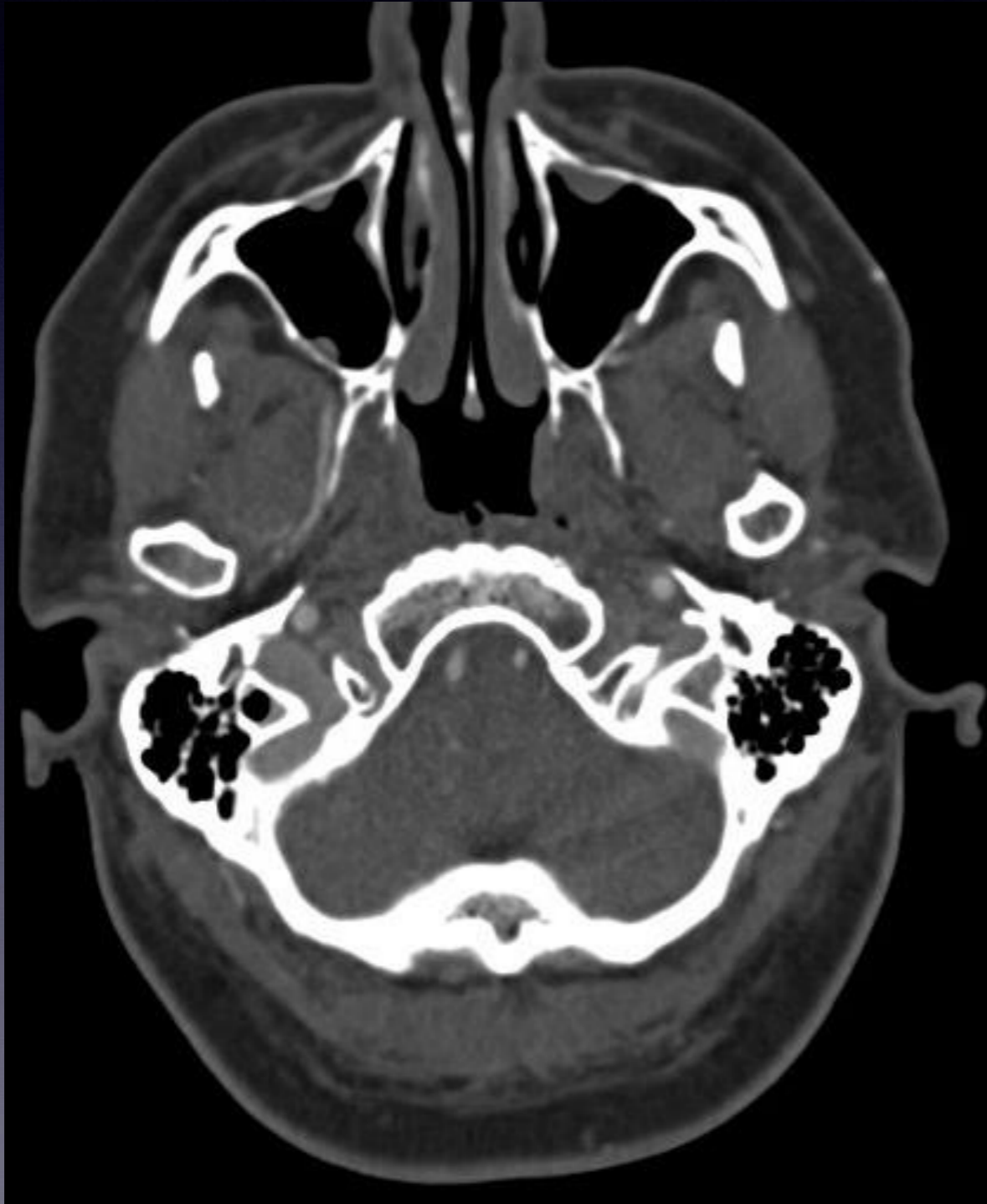# 3 MONTH FOLLOW UP CT





# Follow up 3 month

DOM RESAMPLED, Shift Overlay from 60xx to 7FE0



# Αιτιολογία και απεικόνιση της υπαραχνοειδούς αιμορραγίας

# Ανευρύσματα εγκεφάλου

- Ευθύνονται για το 72% των μη τραυματικών υπαραχνοειδών αιμορραγιών

# Αιμορραγικά απεικονιστικά πρότυπα

**TABLE I: Differential Diagnosis of Subarachnoid Hemorrhage by Pattern of Hemorrhage**

| Diffuse               | Perimesencephalic                          | Convexal                                      |
|-----------------------|--|---|
| Trauma                | Trauma                                     | Trauma  |
| Saccular aneurysm     | Nonaneurysmal perimesencephalic hemorrhage | Reversible cerebral vasoconstriction syndrome |
| Nonsaccular aneurysm  | Saccular aneurysm                          | Cerebral amyloid angiopathy                   |
| Arterial dissection   | Nonsaccular aneurysm                       | Posterior reversible encephalopathy syndrome  |
| Vascular malformation | Arterial dissection                        | Cerebral venous thrombosis                    |
| Tumor                 | Vascular malformation (consider spinal)    | Septic emboli, septic aneurysm                |
| Vasculitis            | Tumor (consider spinal)                    | Coagulopathy                                  |
|                       |  | Moyamoya disease                              |
|                       |  | Vascular malformation (superficial)           |
|                       |  | Tumor   |
|                       |  | Vasculitis                                    |

# CT

- Sensitivity SAH 95% 24hrs
- 80% 72 hrs
- 50% 1 week
- 30% 2 weeks
  
- Lumbar puncture: Xanthochromia 2 weeks in 100%, 3-7 weeks in 70% of patients

# Fisher grading scale for SAH

| Group | Subarachnoid blood   | Risk of vasospasm |
|-------|--|-------------------|
| 1     | No blood   | Low               |
| 2     | Diffuse or vertical layers<br><1 mm                                      | Only moderate     |
| 3     | Localized clot and/or vertical<br>layer > 1 mm                           | High              |
| 4     | Intracerebral or intraventricular<br>clot with only diffuse or<br>no SAH |                   |

# CT angiography-Aneurysm detection

- Sensitivity 99%, Specificity 95.2%, Accuracy 98.3% (Wintermark et al, 2003)
- Απόφαση για τρόπο αντιμετώπισης
- Ακτινοβολία
- Γρήγορη μέθοδος απεικόνισης σε αντίθεση με τη μαγνητική αγγειογραφία(no motion artifact)

# Ψηφιακή αγγειογραφία εγκεφάλου

- Εξαιρετική χωρική διακριτική ικανότητα (spatial resolution)
- Gold standard for cerebral aneurysm detection
- Δυναμική μελέτη



# Ψηφιακή αγγειογραφία εγκεφάλου

- Ακτινοβολία
- Επεμβατική μέθοδος( μικρός κίνδυνος εγκεφαλικού, αγγειακής βλάβης, αιμορραγίας)

# Σακκοειδή ανευρύσματα - Κατανομή

- Πρόσθια αναστομωτική 30-35%
- 15% σπονδυλοβασικό σύστημα
- Οπίσθια αναστομωτική/ έσω καρωτίδα 30%
- Μέση εγκεφαλική 20%

3D2  
BrighamandWomens KIM  
Se: 5

SP

ANDERSON MCJAMES  
F 20865606

Mar 27 2006  
12:48

Volume Rendering No cut

DFOV 3.2 cm  
301/2

CG/KF

5.8 mm (2D)

4.4 mm (2D)

3.8 mm (2D)

5.1 mm (2D)

Angles

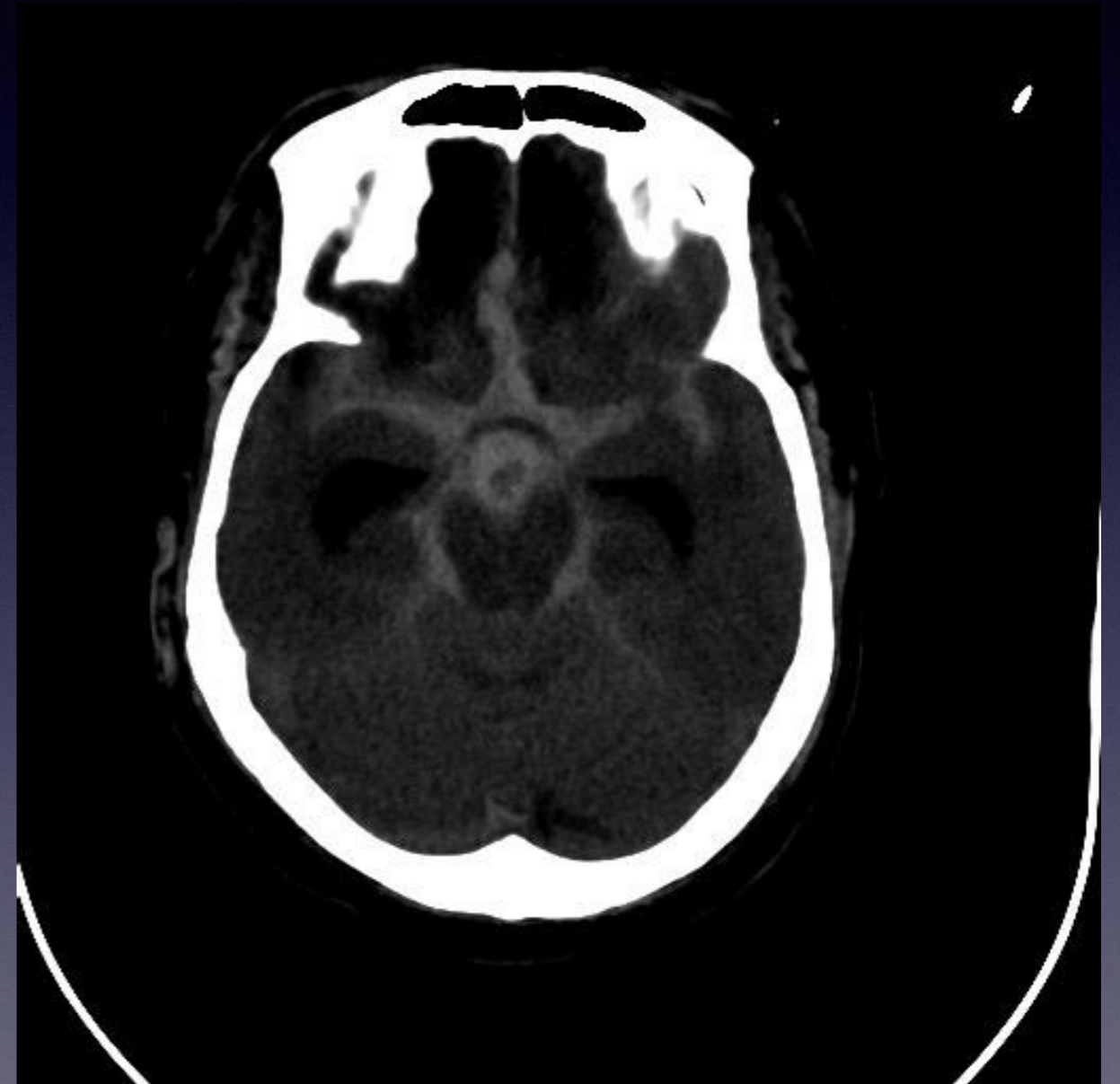
0 L 0 LAO 7 CRA

No VOI

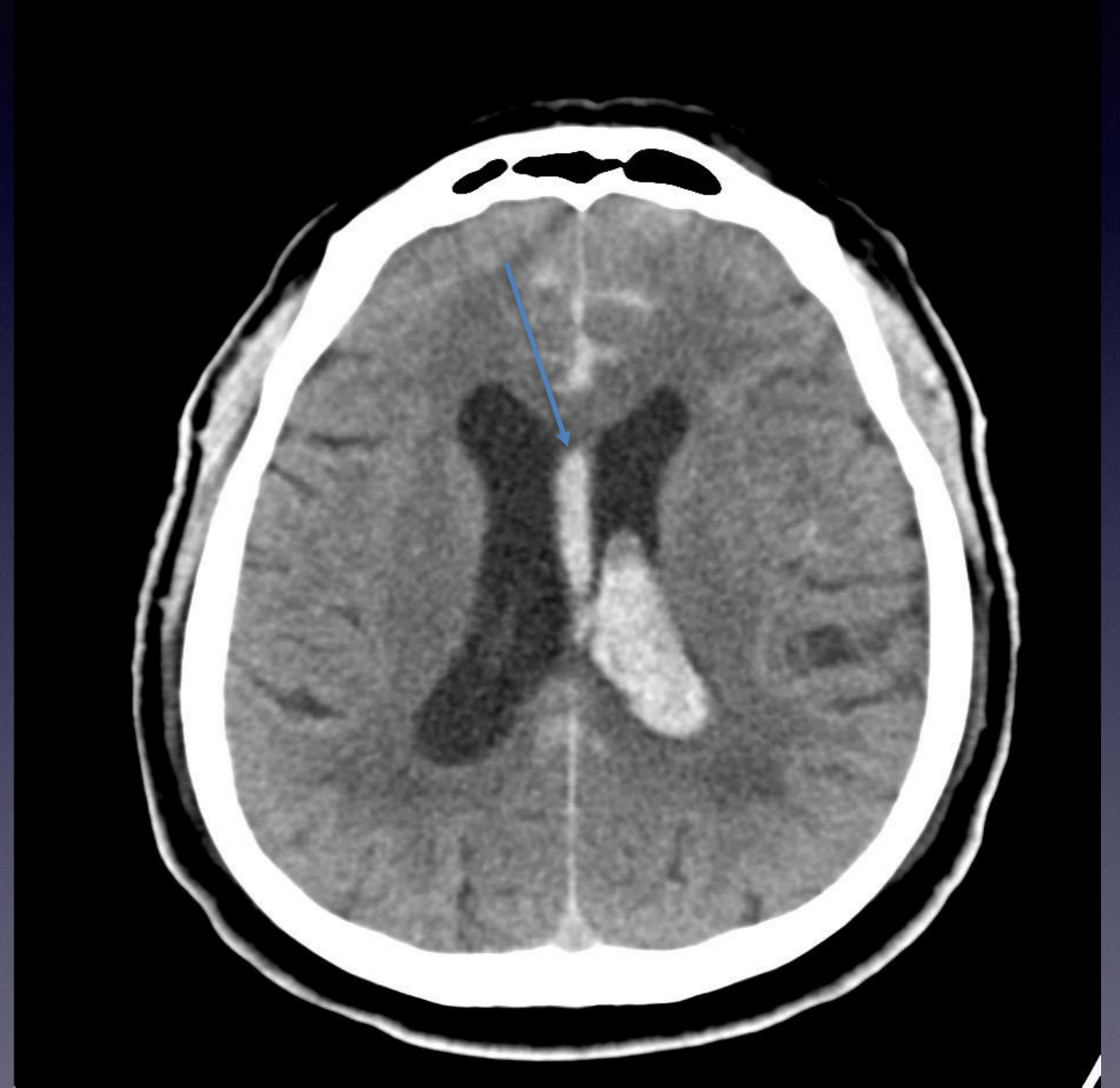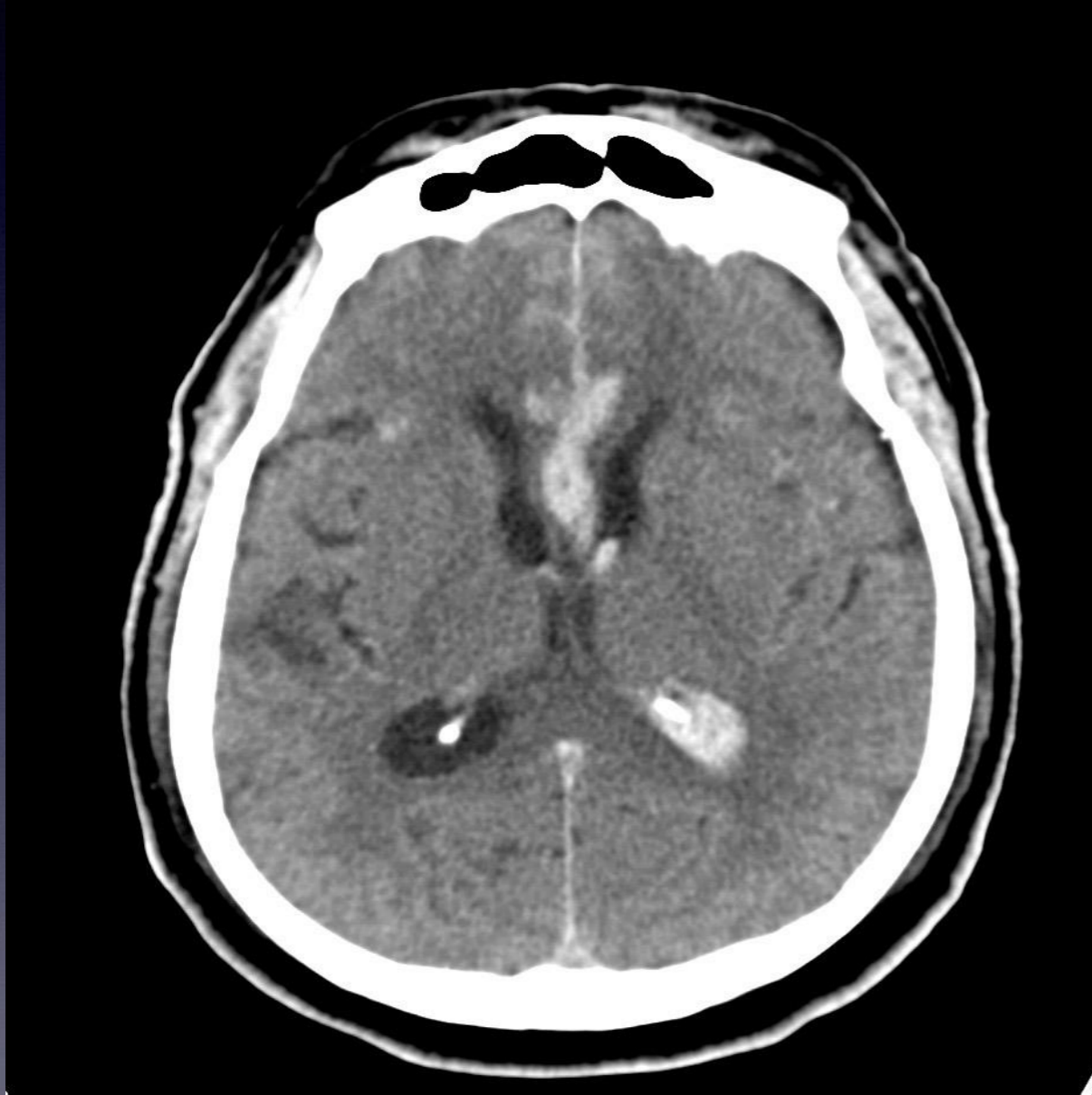
Voxel size: 0.3 mm

W = 3646 L = 1960

IA



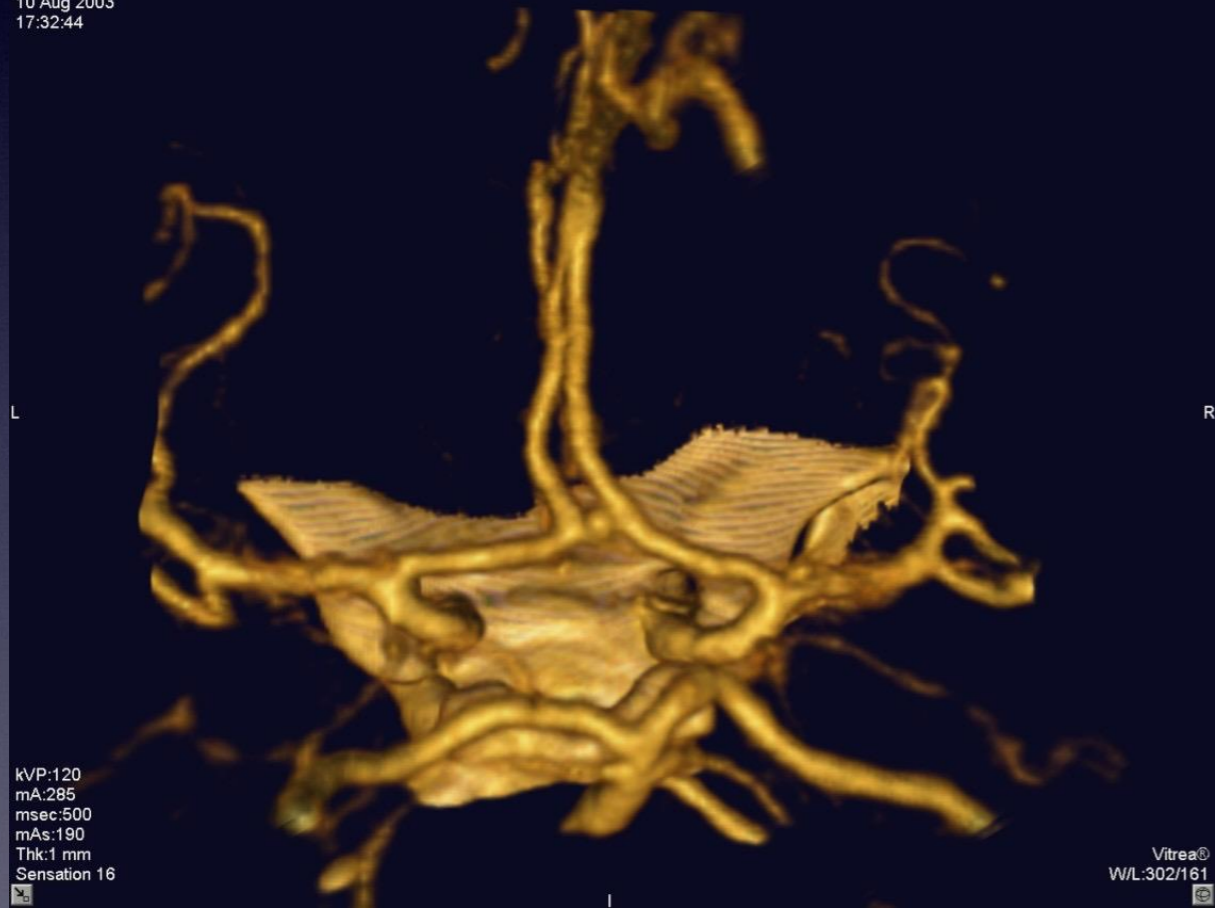
# Headache



NIEVES EFRAIN 59M  
18677138  
Age:59 years  
M  
10 Aug 2003  
17:32:44

S

BrighamandWomensHospital  
CT  
Head\*02 CTA HEAD ONLY



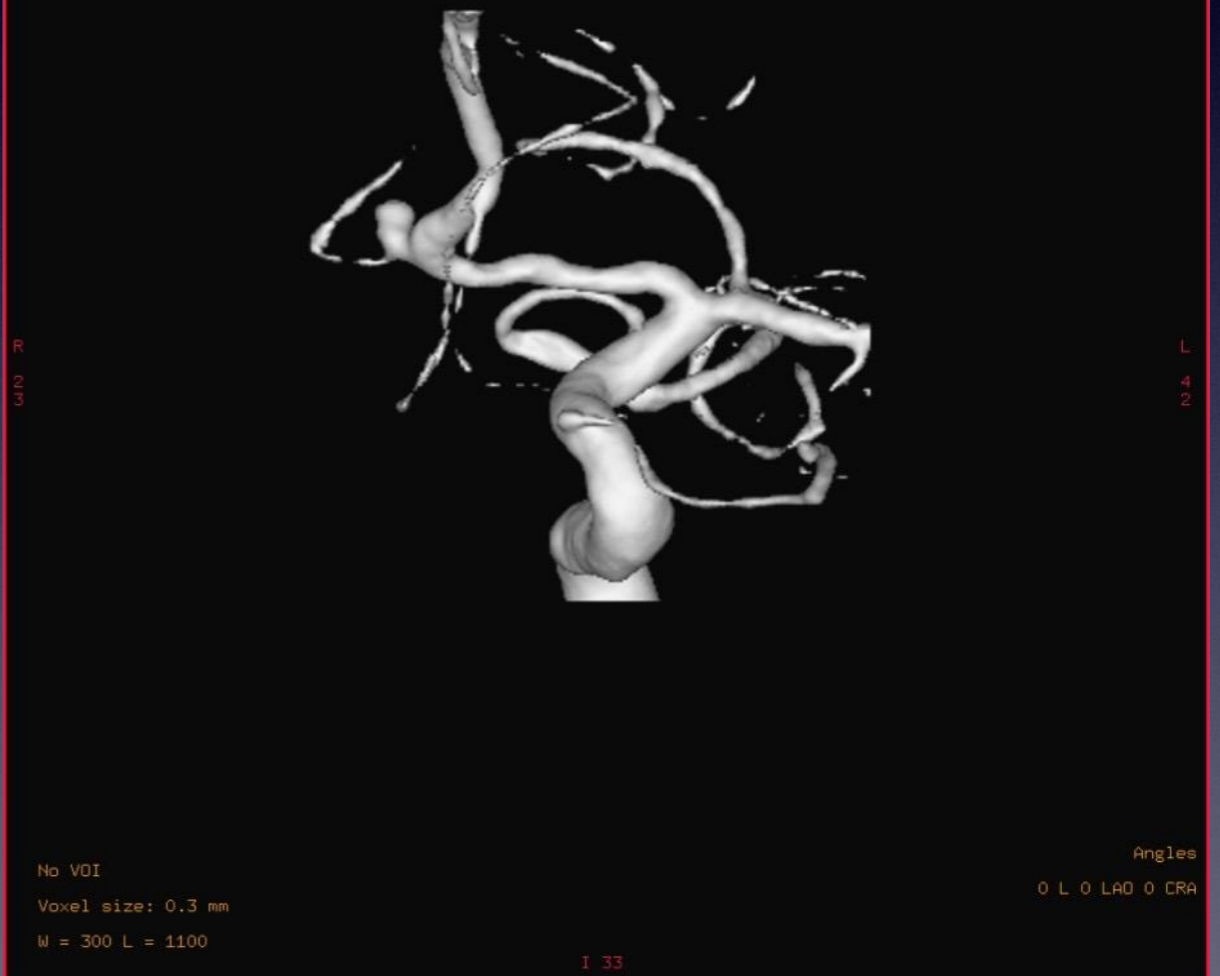3D4  
BrighamandWomens FRIEDLANDER  
Se: 8

S 32

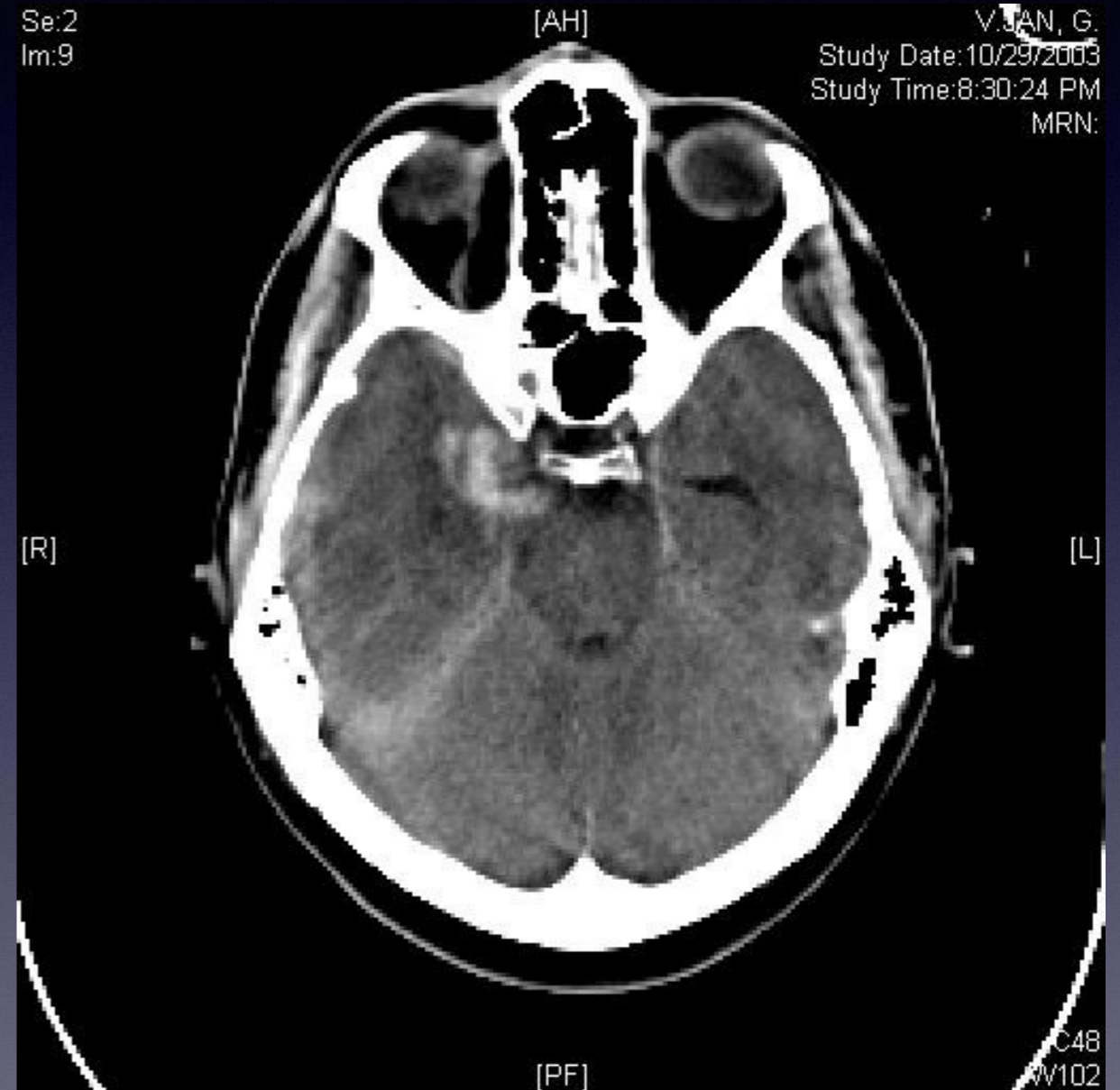
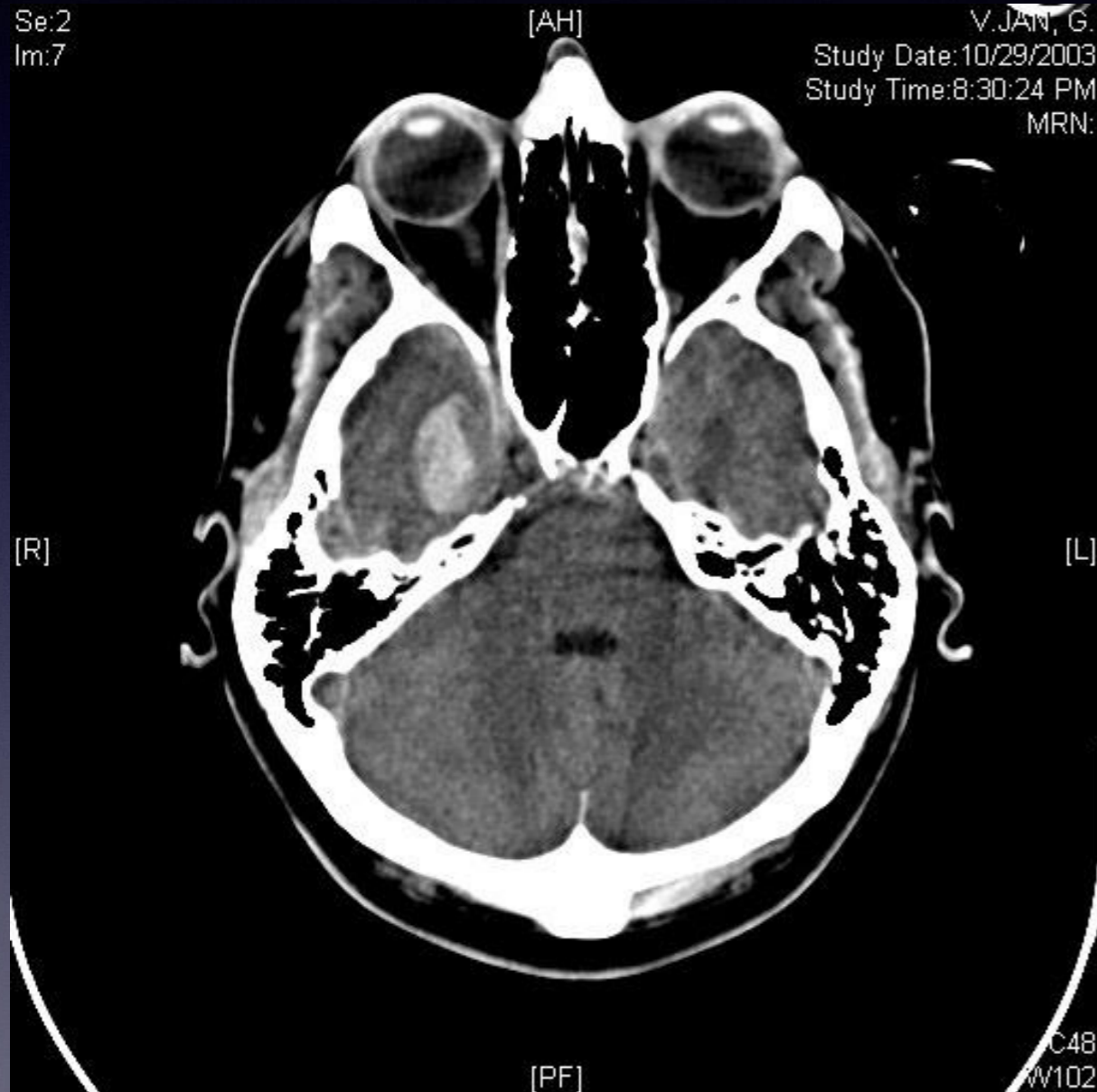
NIEVES EFRAIN  
M

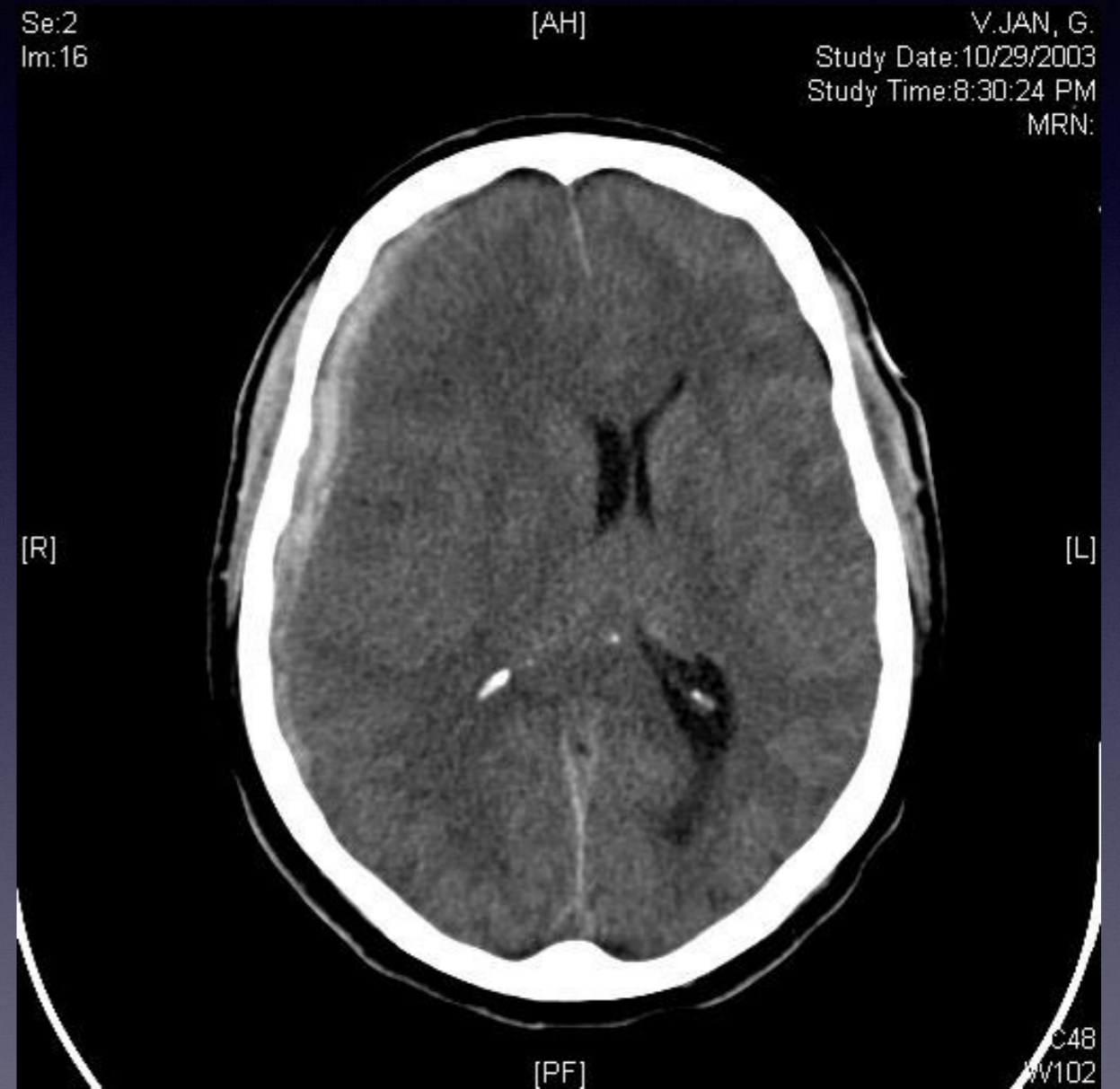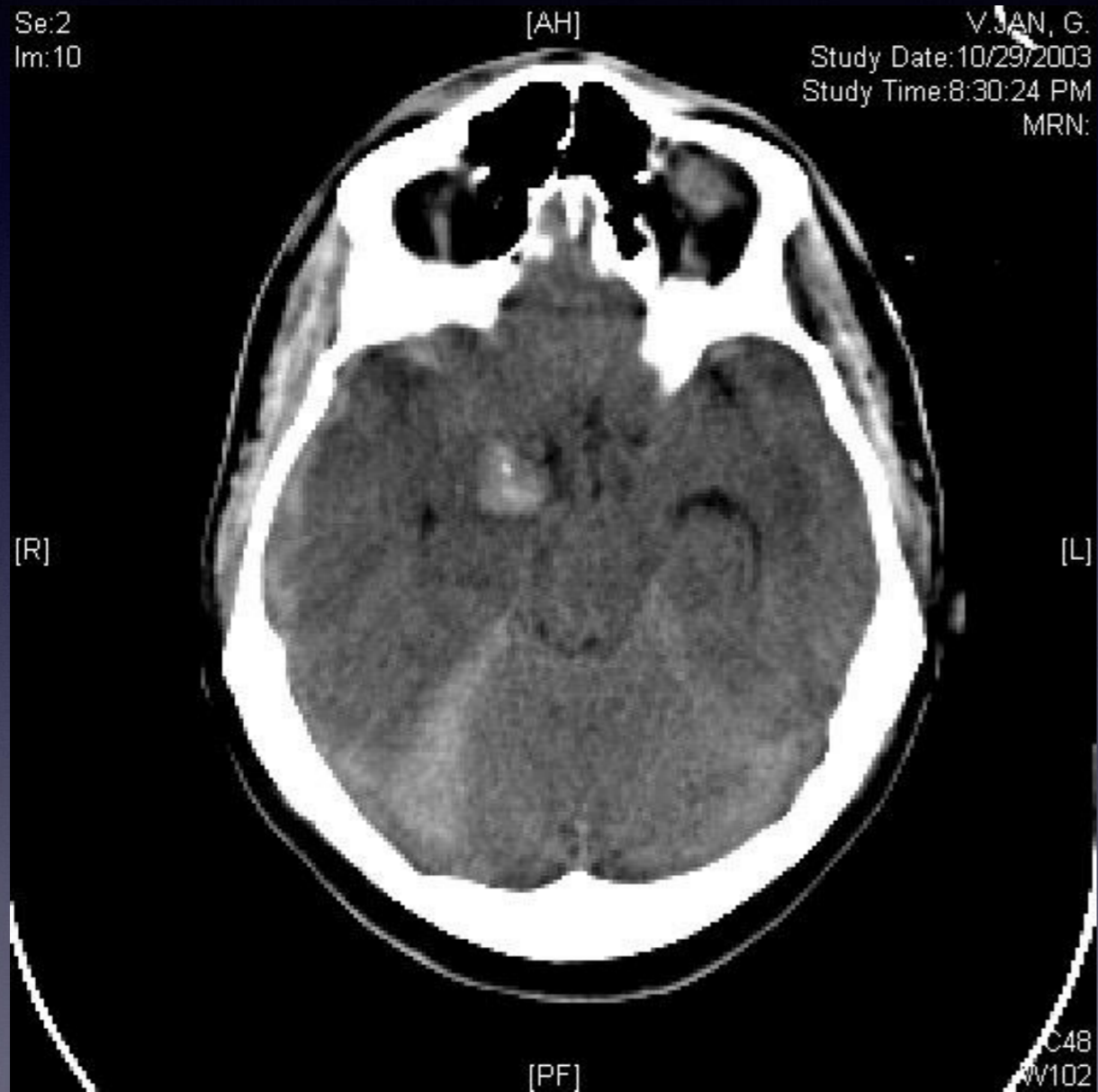Aug 11 2003  
10:03

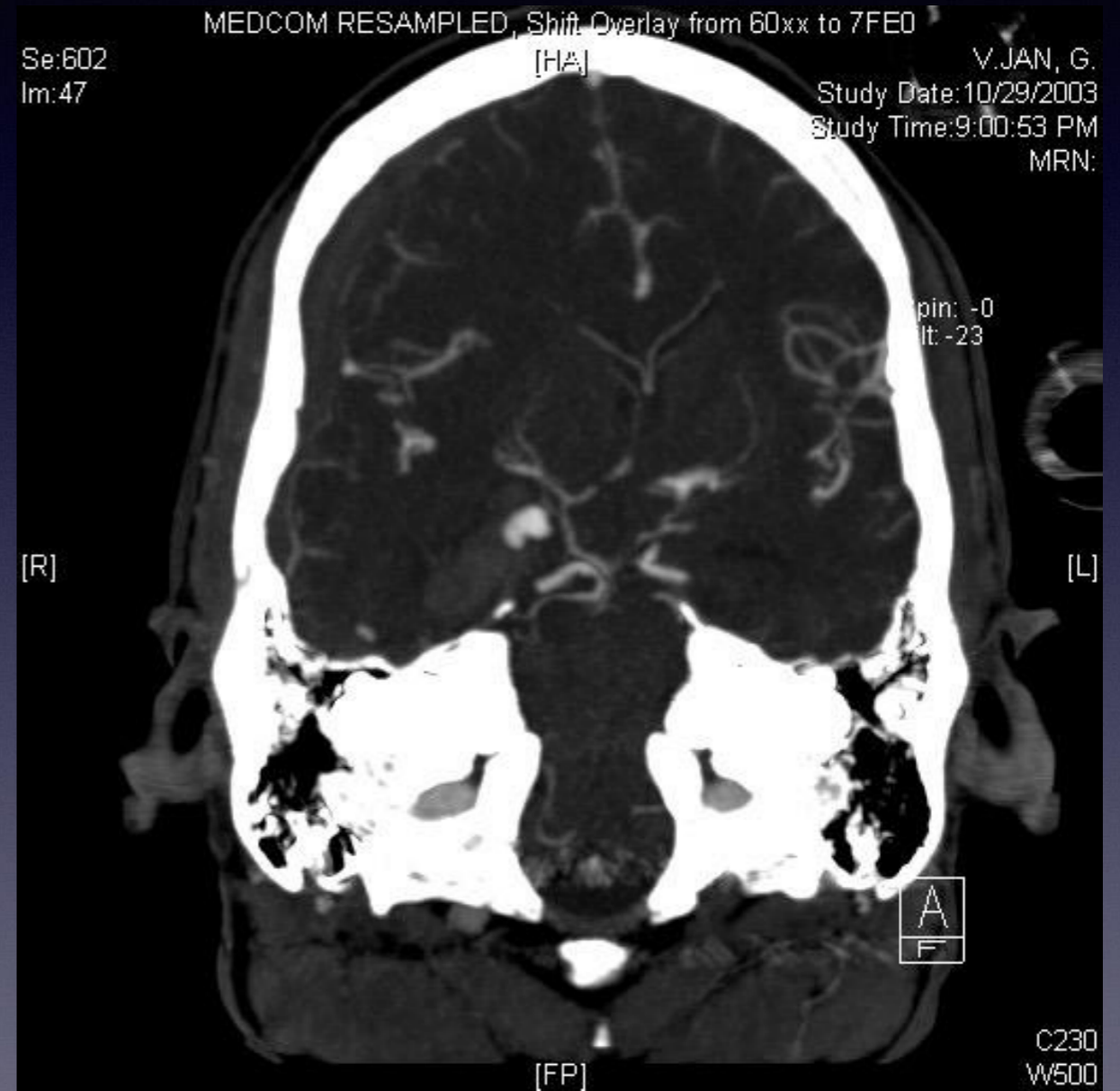
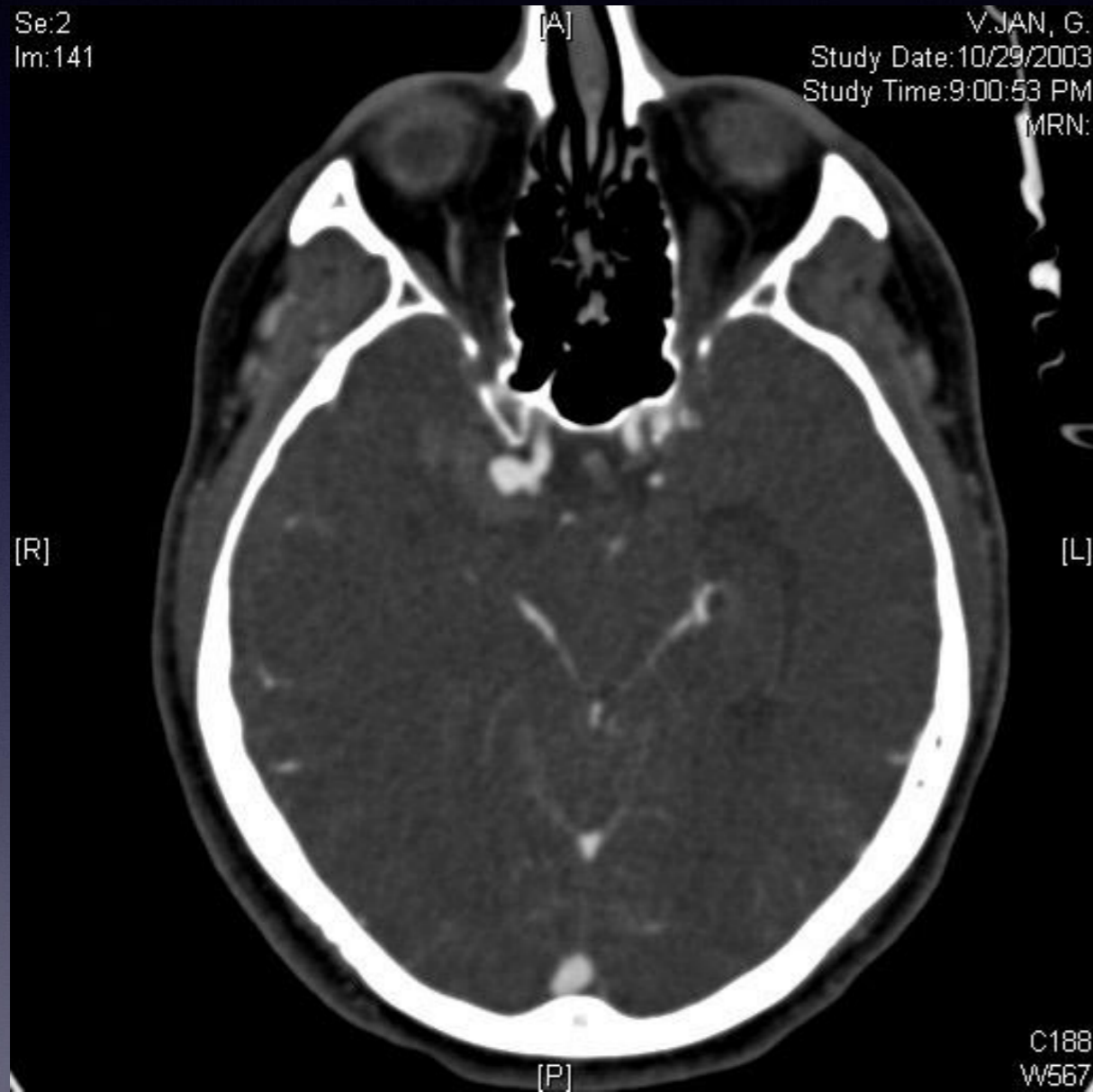
Volume Rendering No cut  
DFOV 6.5 cm  
8/0



# SAH HH 3

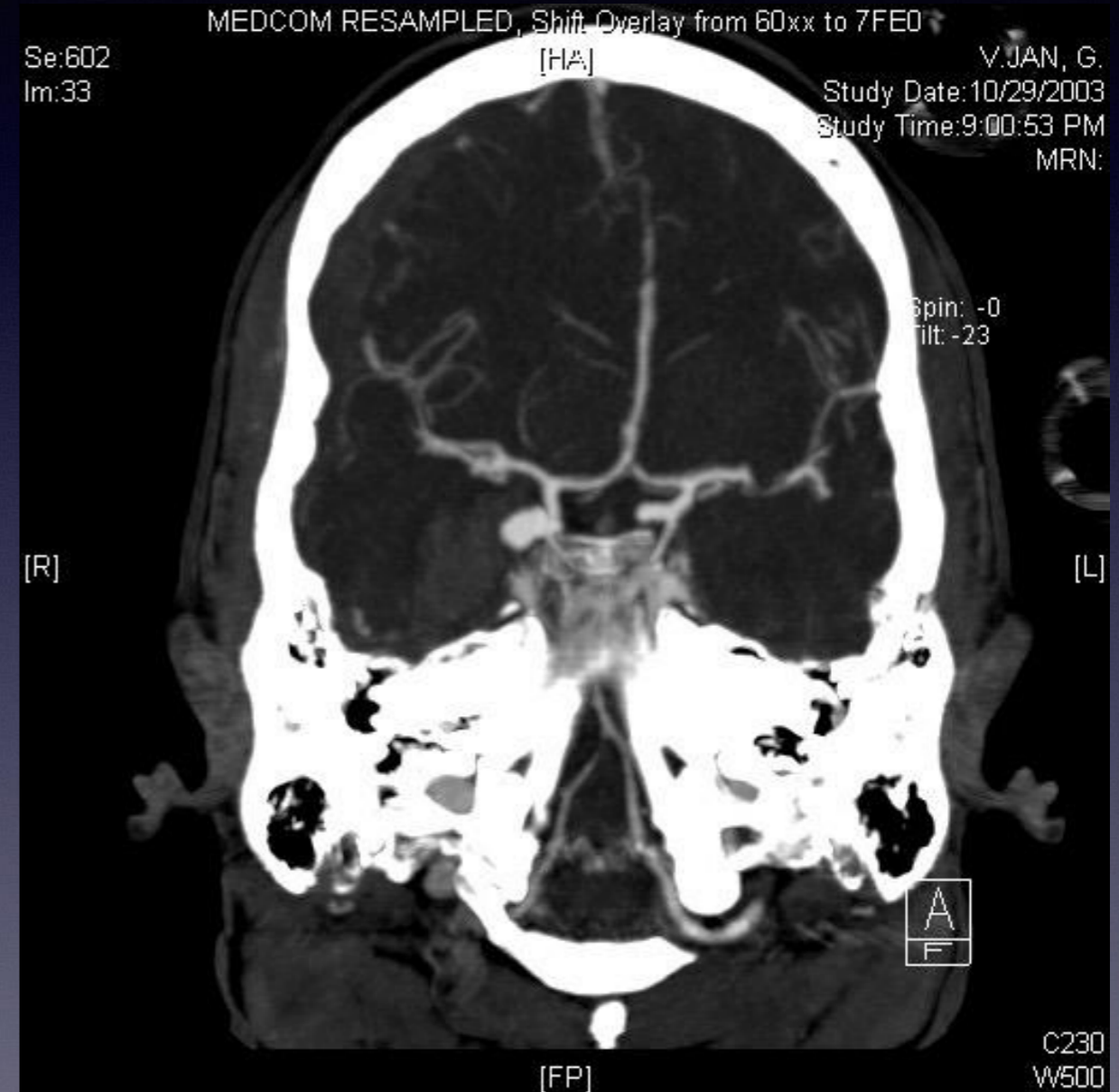
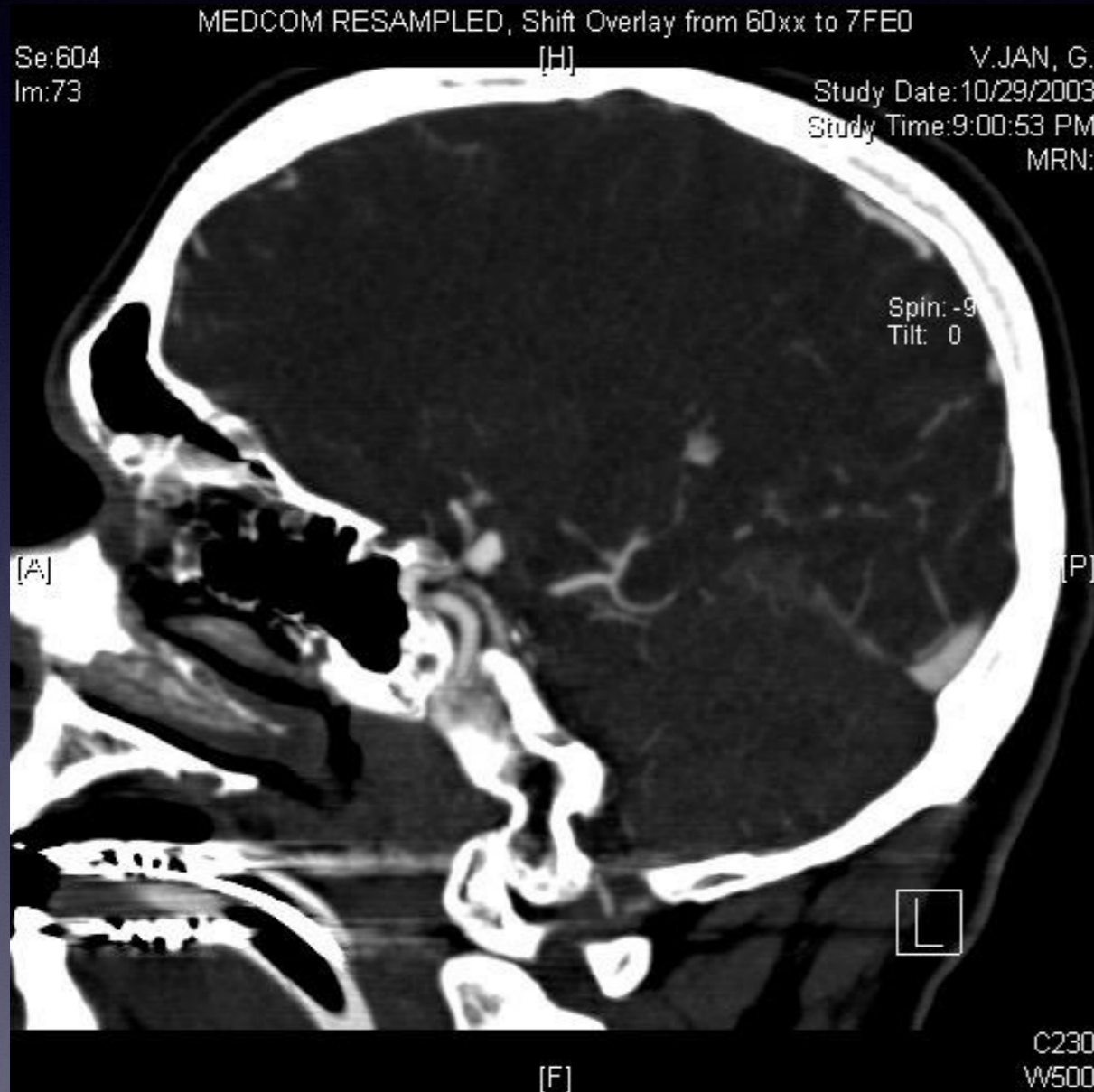






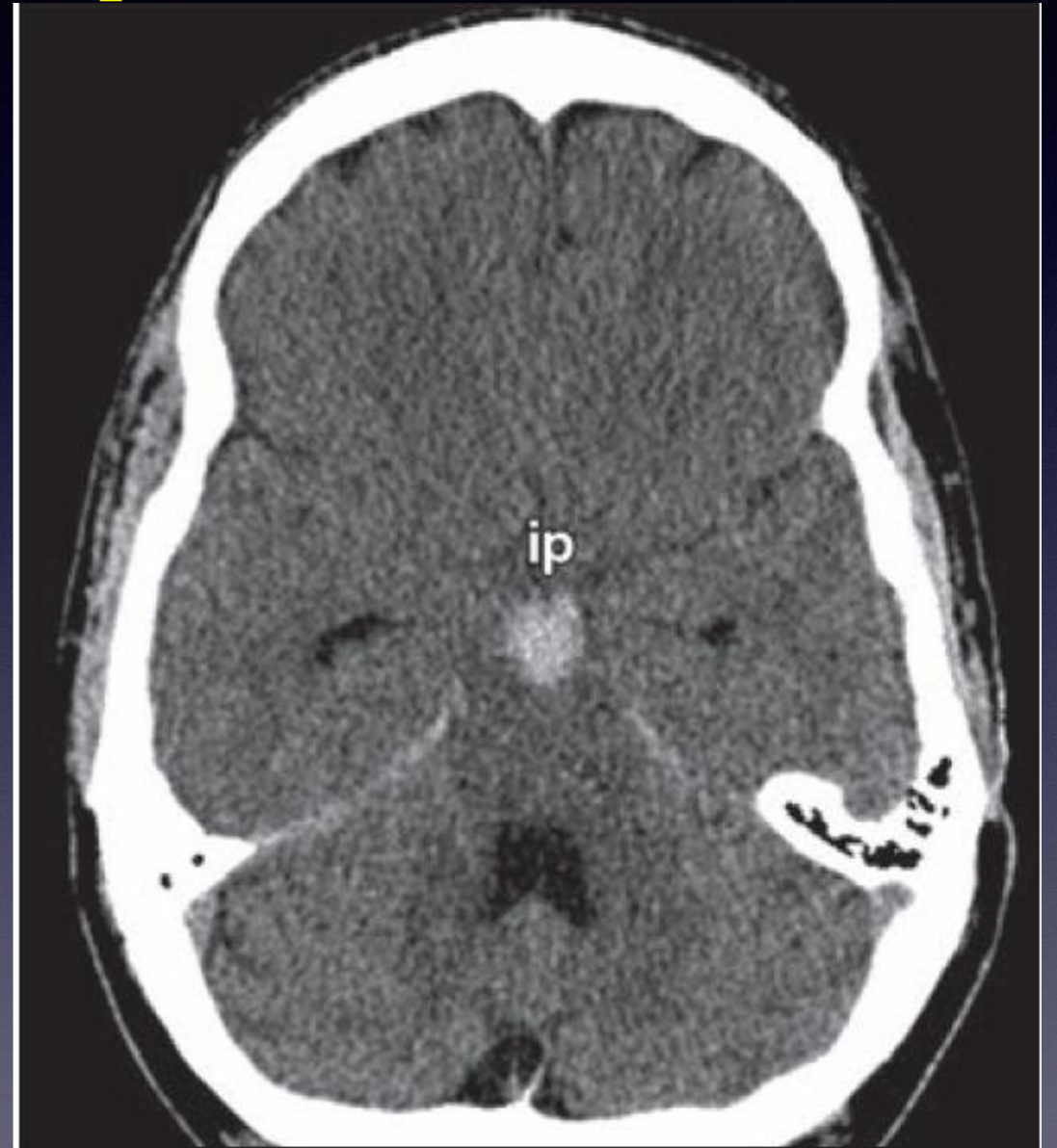


# Lateral variant PICOM aneurysm



# Περιμεσεγκεφαλική αιμορραγία

- 10% των ΥΑ
- Καλοήθους κλινική πορεία



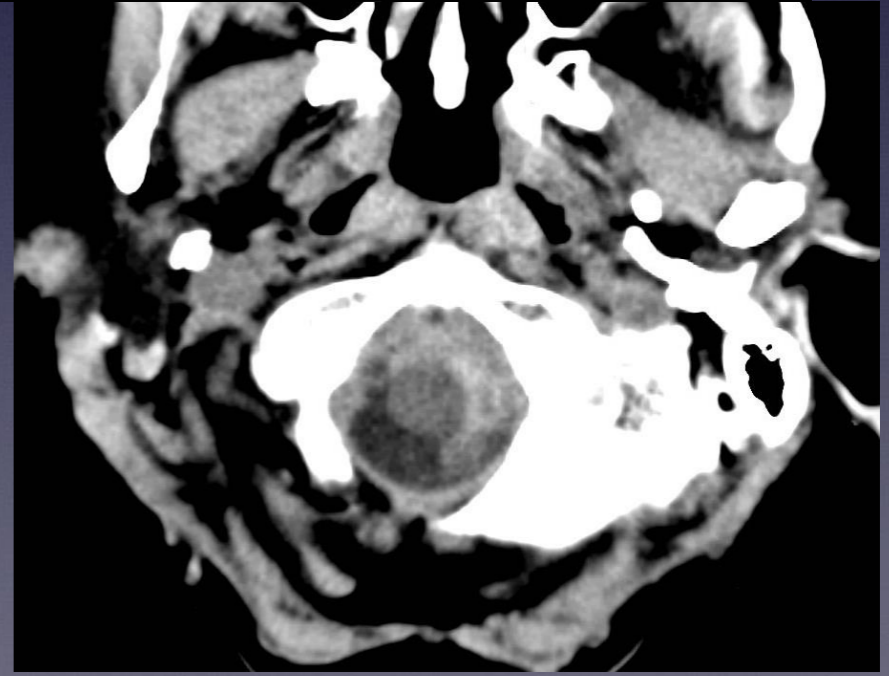
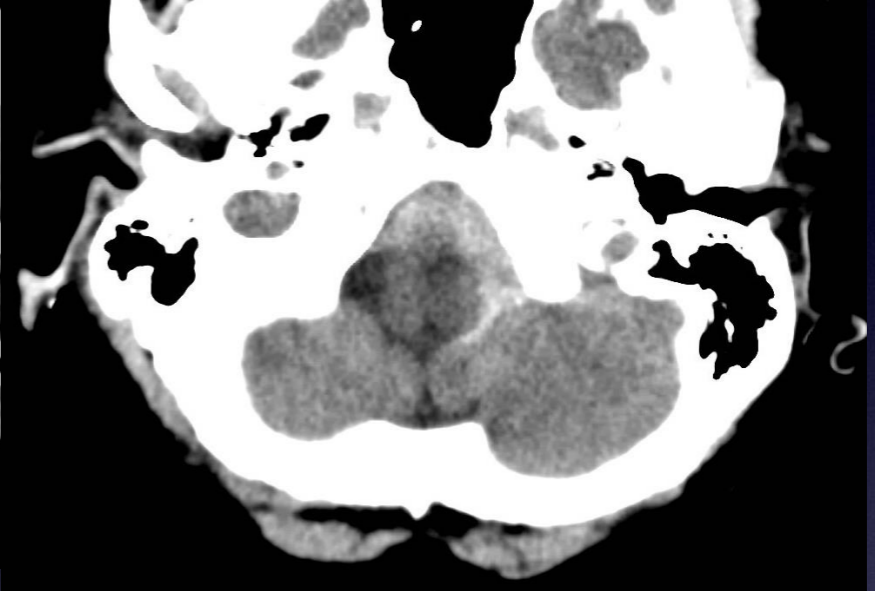
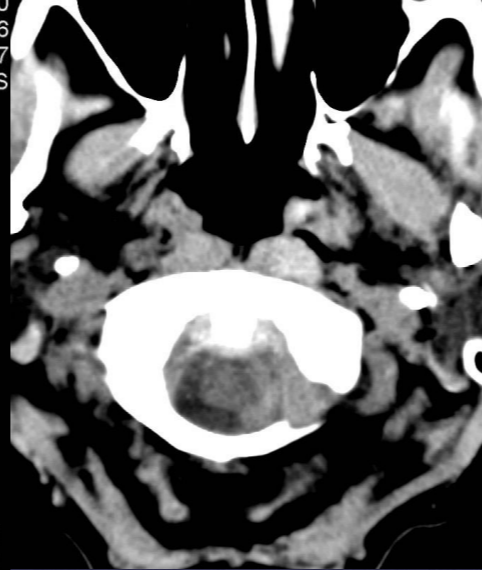
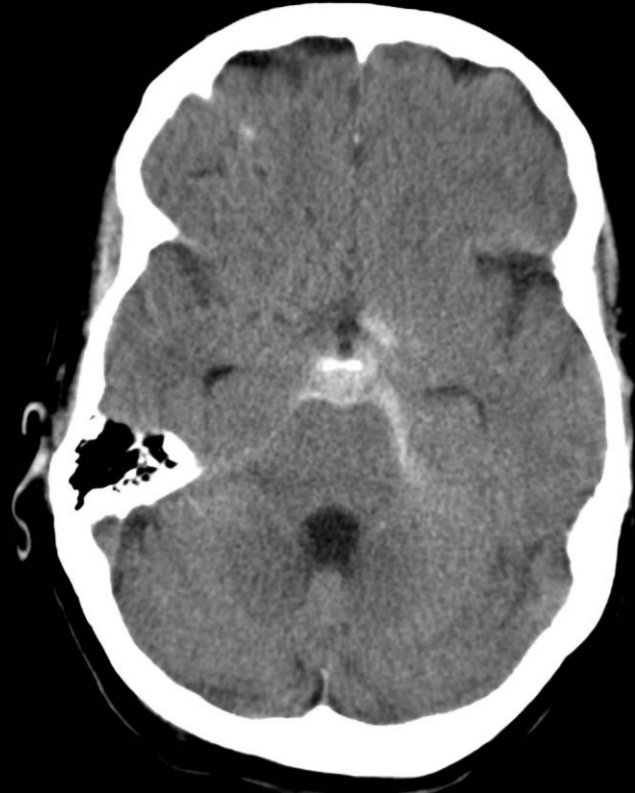ANDERSON, MABLETON, 0707  
DOB: 04/16/1930  
MRN: 1524166  
A# 172296426  
SE: 2  
IM: 9  
595.3  
172mm

ROECCT1  
10:40:00  
11/03/2006  
Im tm: 10:37:07  
HFS

AS

R  
1  
1  
4

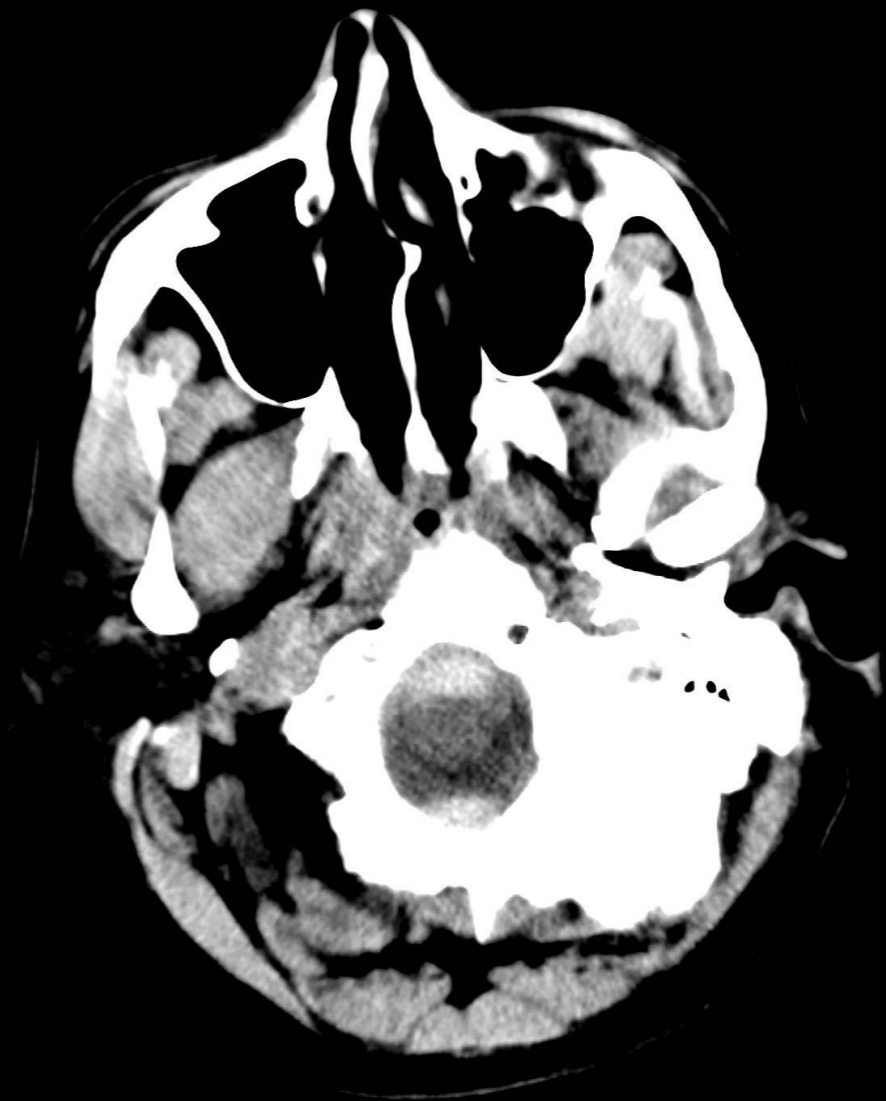
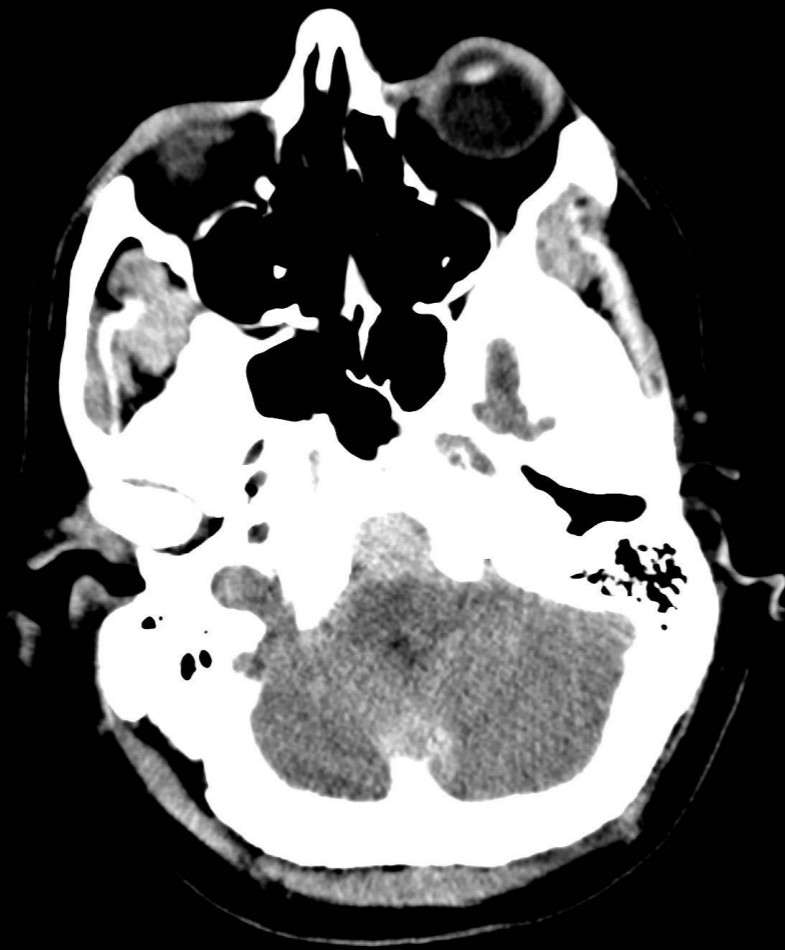L  
1  
1  
5



# 52 yr old male with SAH

4

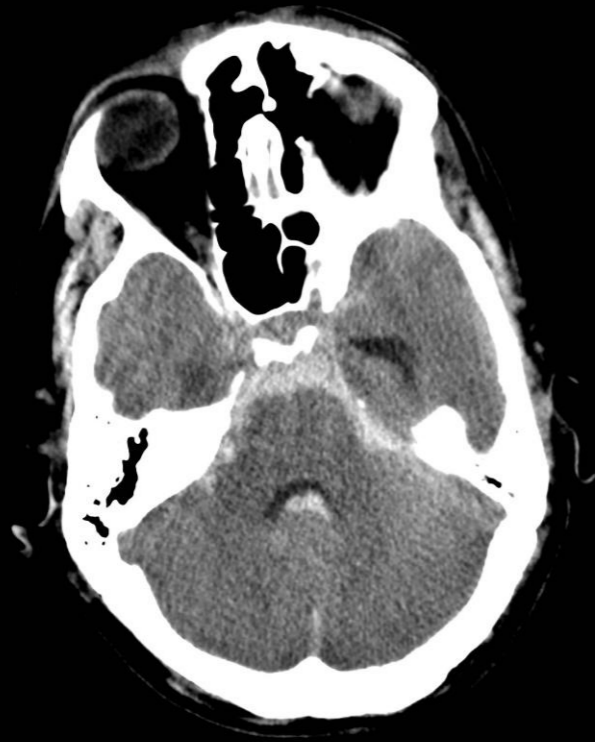6



W 80 : L 35

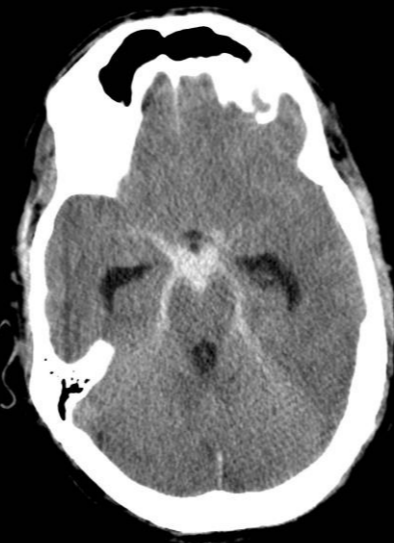W 80 : L 35

9



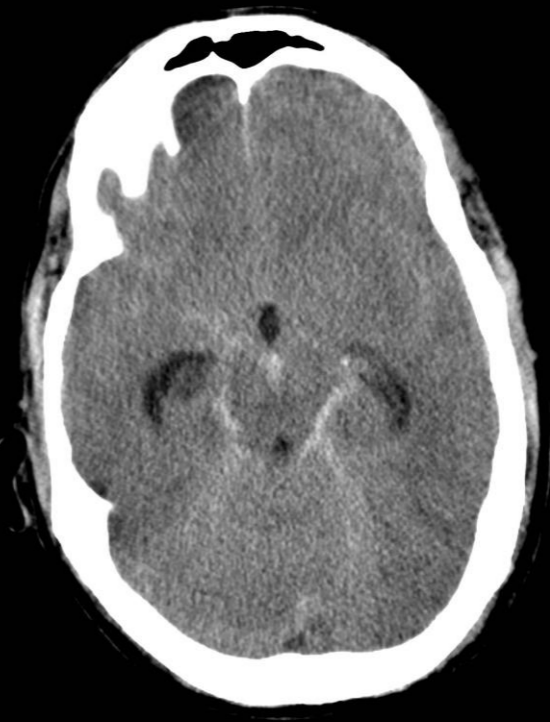
W 80 : L 35

11



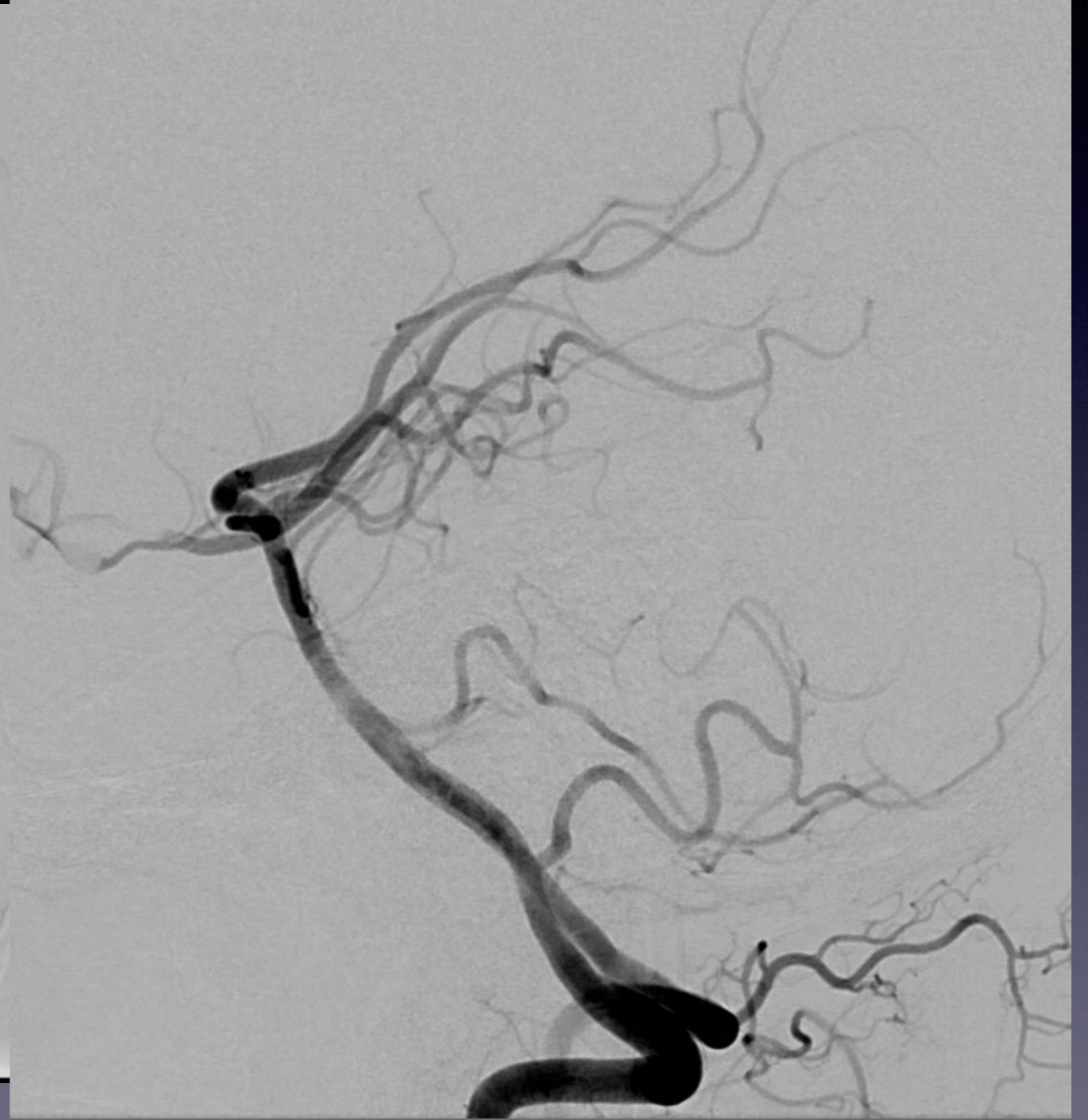
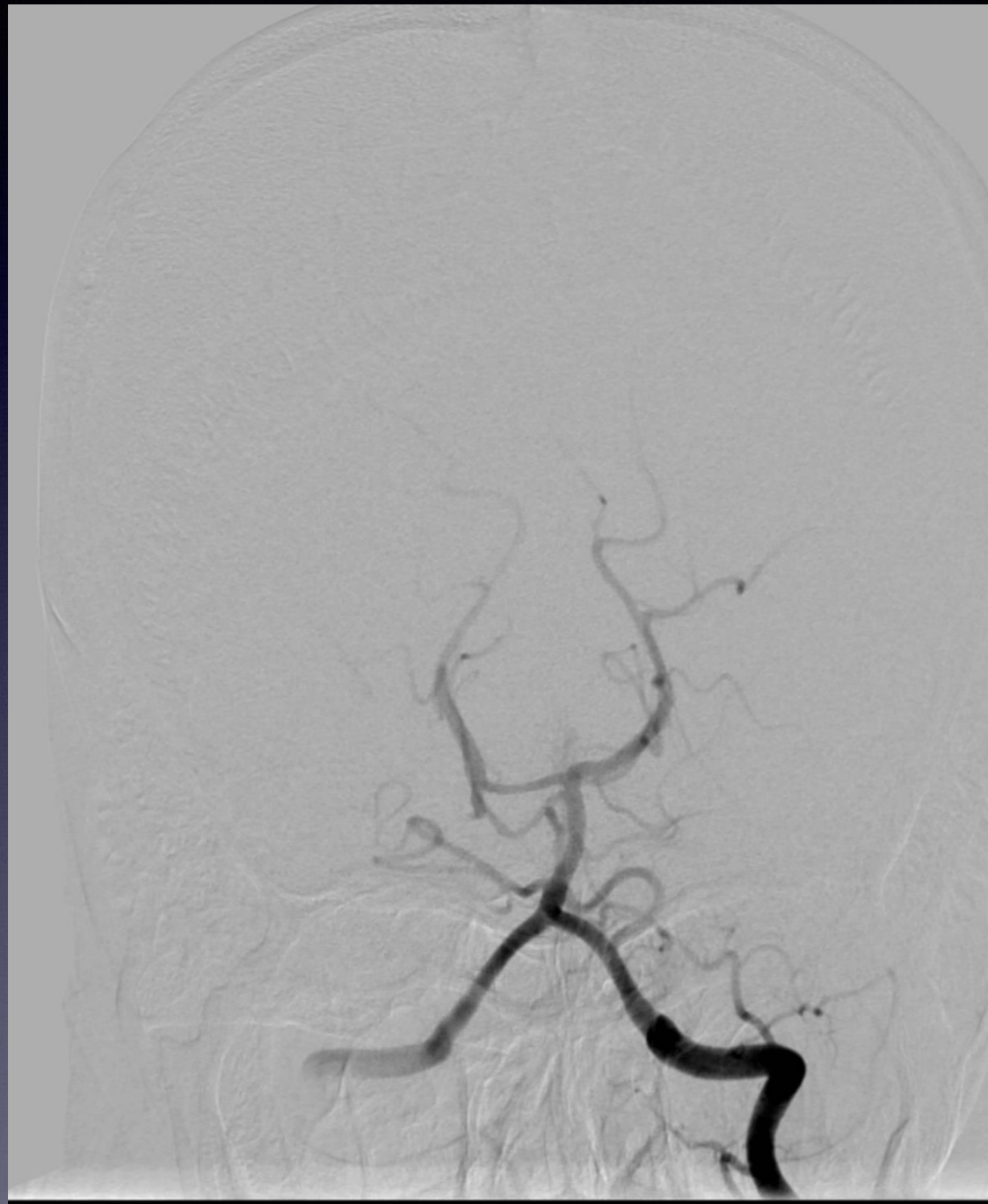W 80 : L 35

12



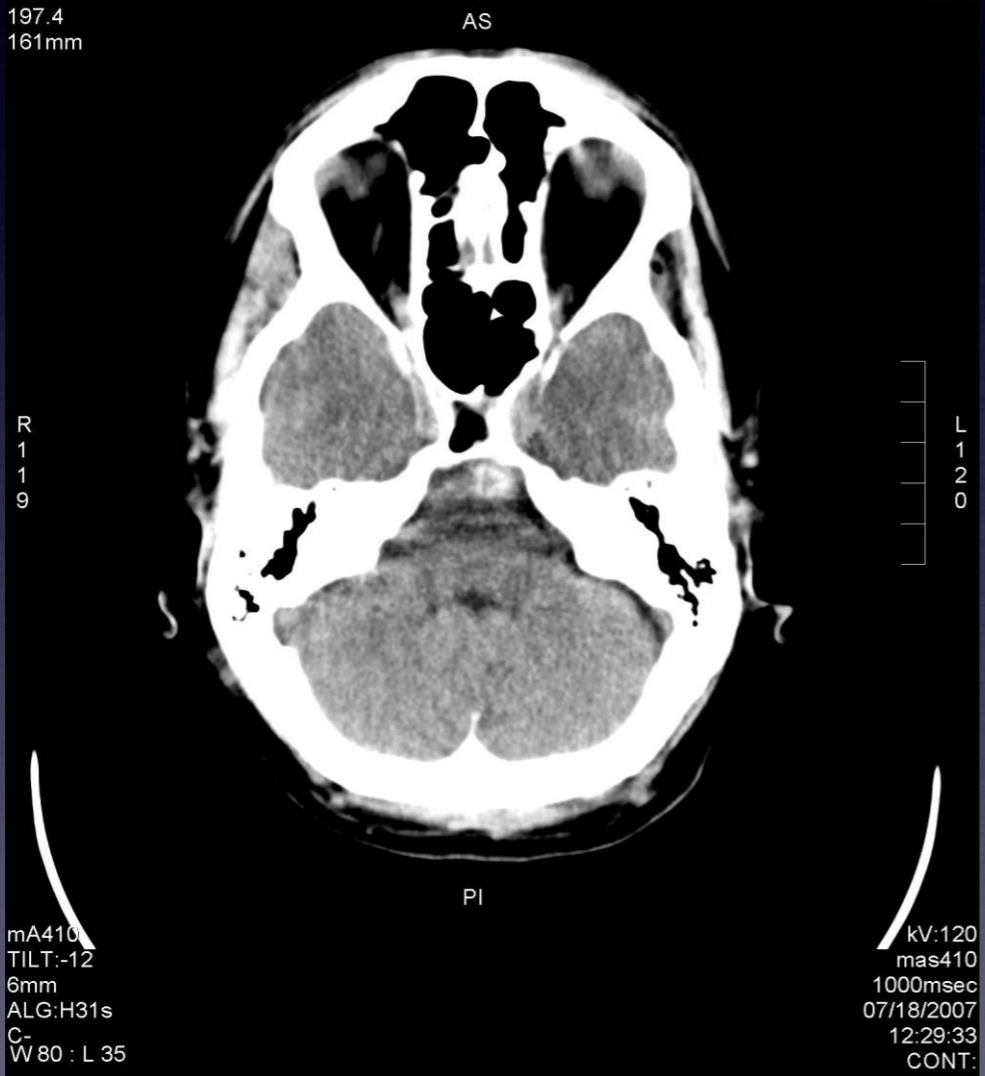W 80 : L 35

# INITIAL NEGATIVE ANGIO



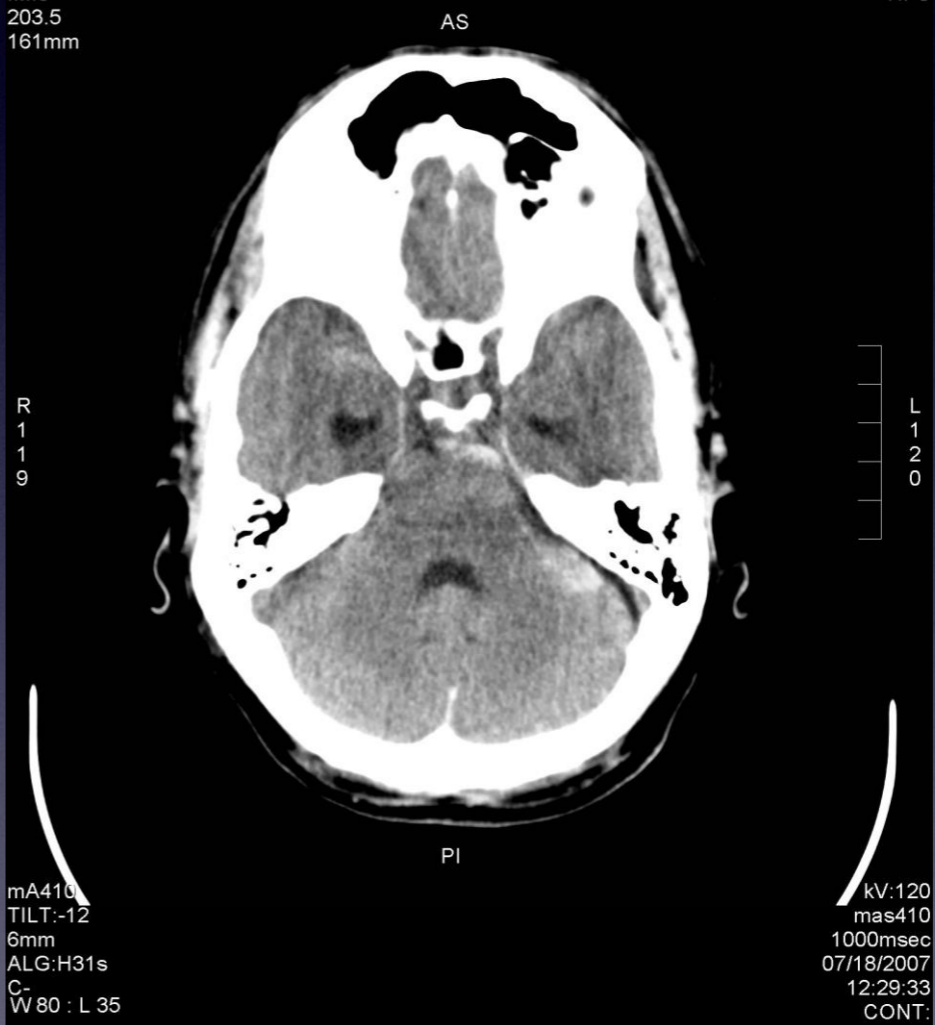
GLOWACZ, GREGG D, 051Y M  
DOB: 12/30/1955  
MRN: 1625167  
A# 197304531  
SE: 2  
IM: 7  
197.4  
161mm

WBH-RO  
ROI PCT2  
12:24:49  
07/18/2007  
Im tm: 12:29:33  
HFS

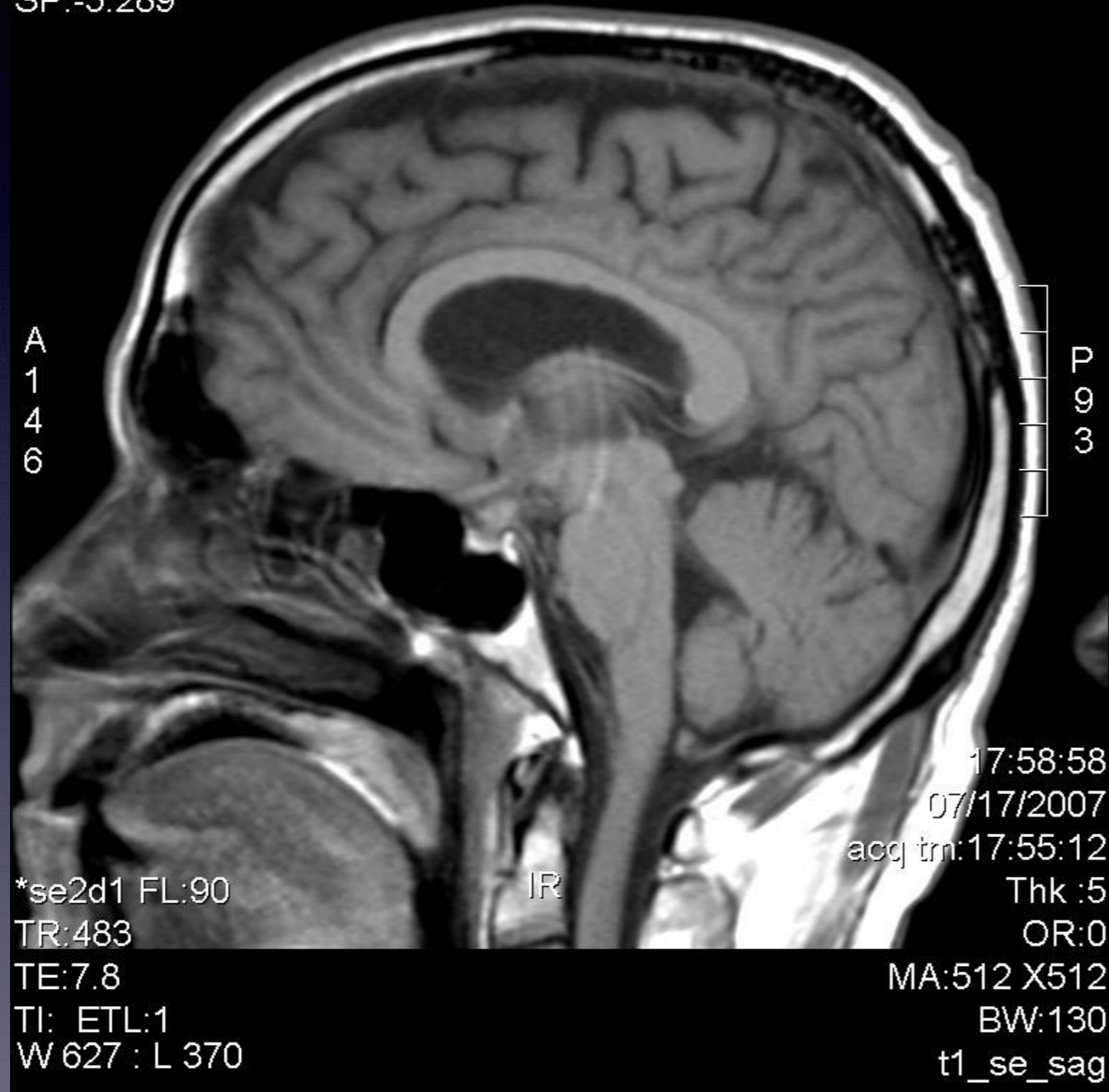


GLOWACZ, GREGG D, 051Y M  
DOB: 12/30/1955  
MRN: 1625167  
A# 197304531  
SE: 2  
IM: 8  
203.5  
161mm

WBH-RO  
ROI PCT2  
12:24:49  
07/18/2007  
Im tm: 12:29:33  
HFS



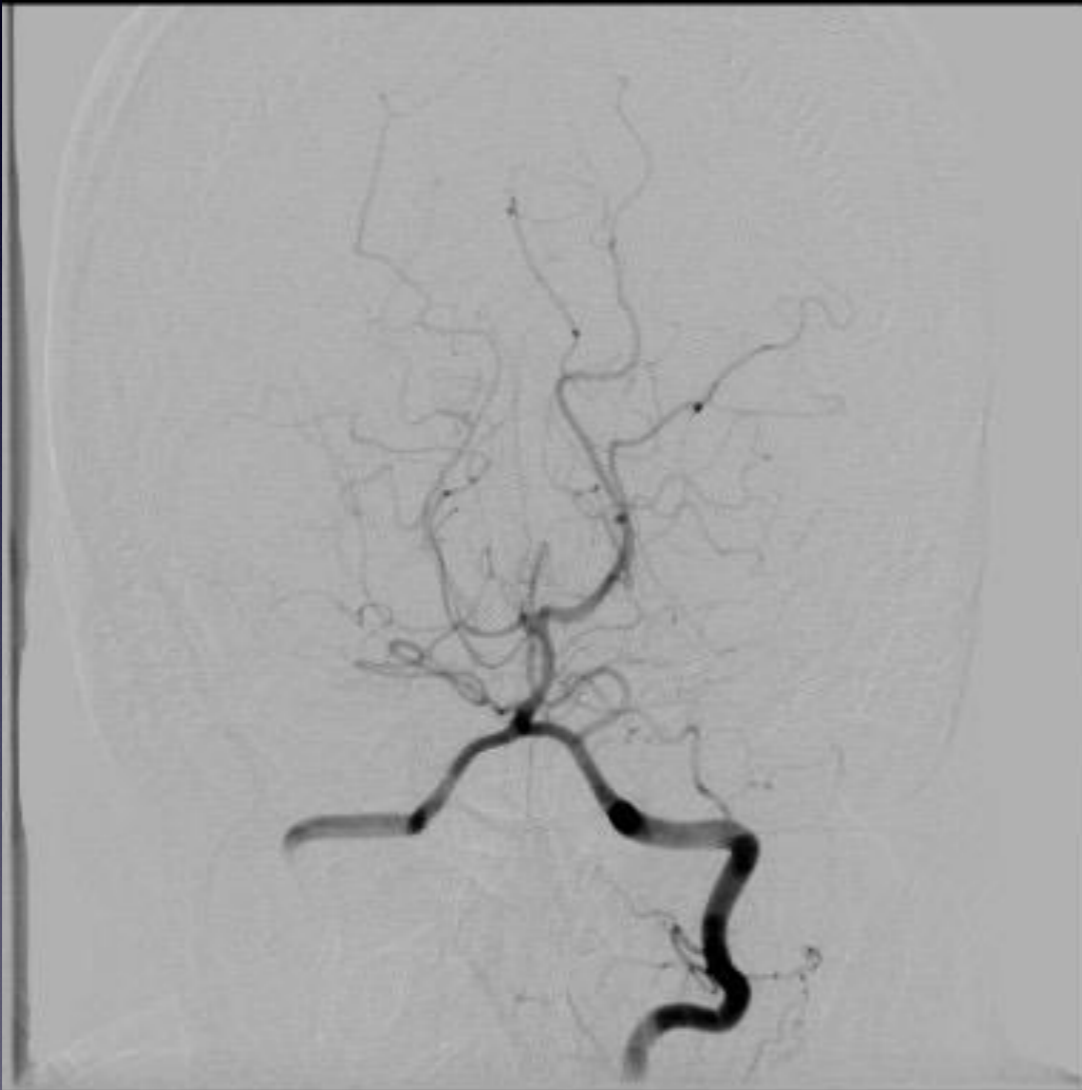GLOWACZ,GREGG D 051Y M William Beaumont Hospital MR3  
DOB:12/30/1955 ROIPMR3A  
1625167 07/17/2007  
A#197435305 17:47:59  
SE:3 SL HFS  
IM:11  
SP:-5.289





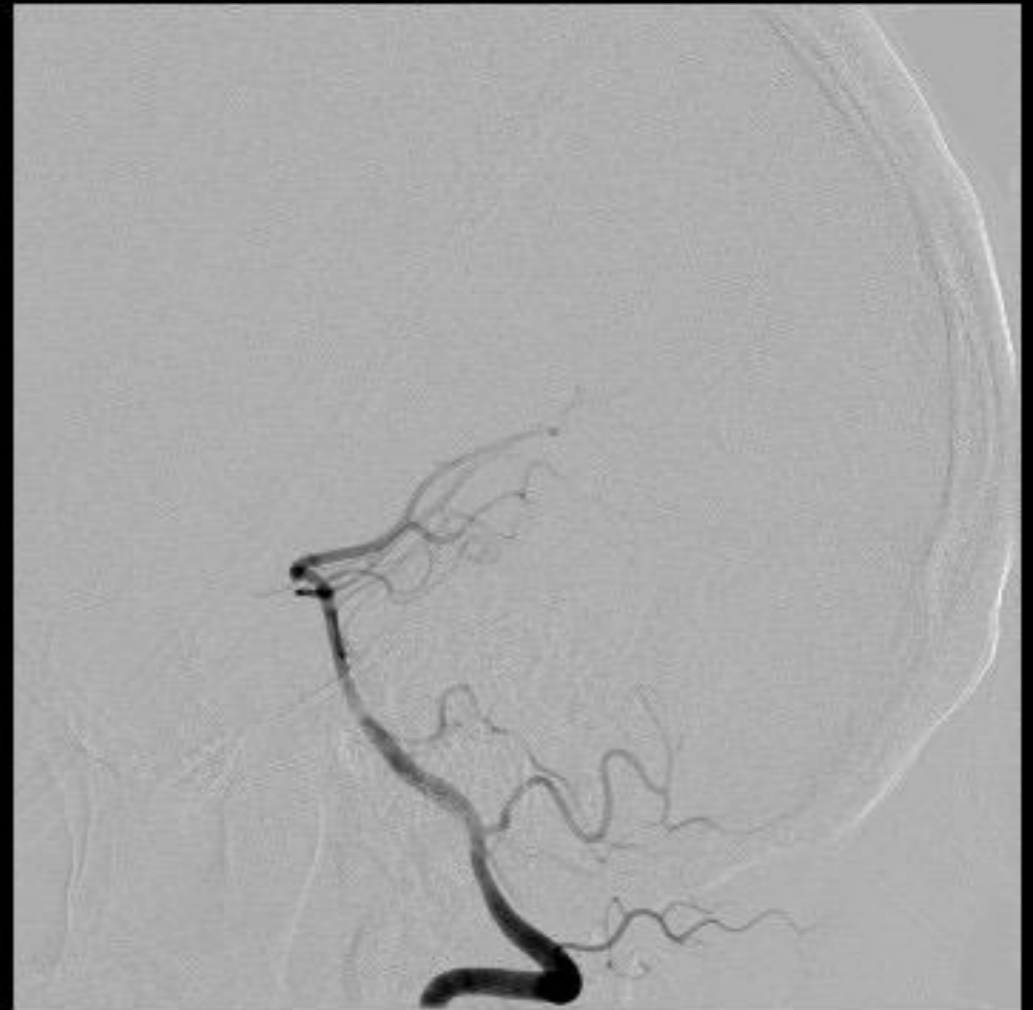# Second angio negative

15



W 4096 : L 2048

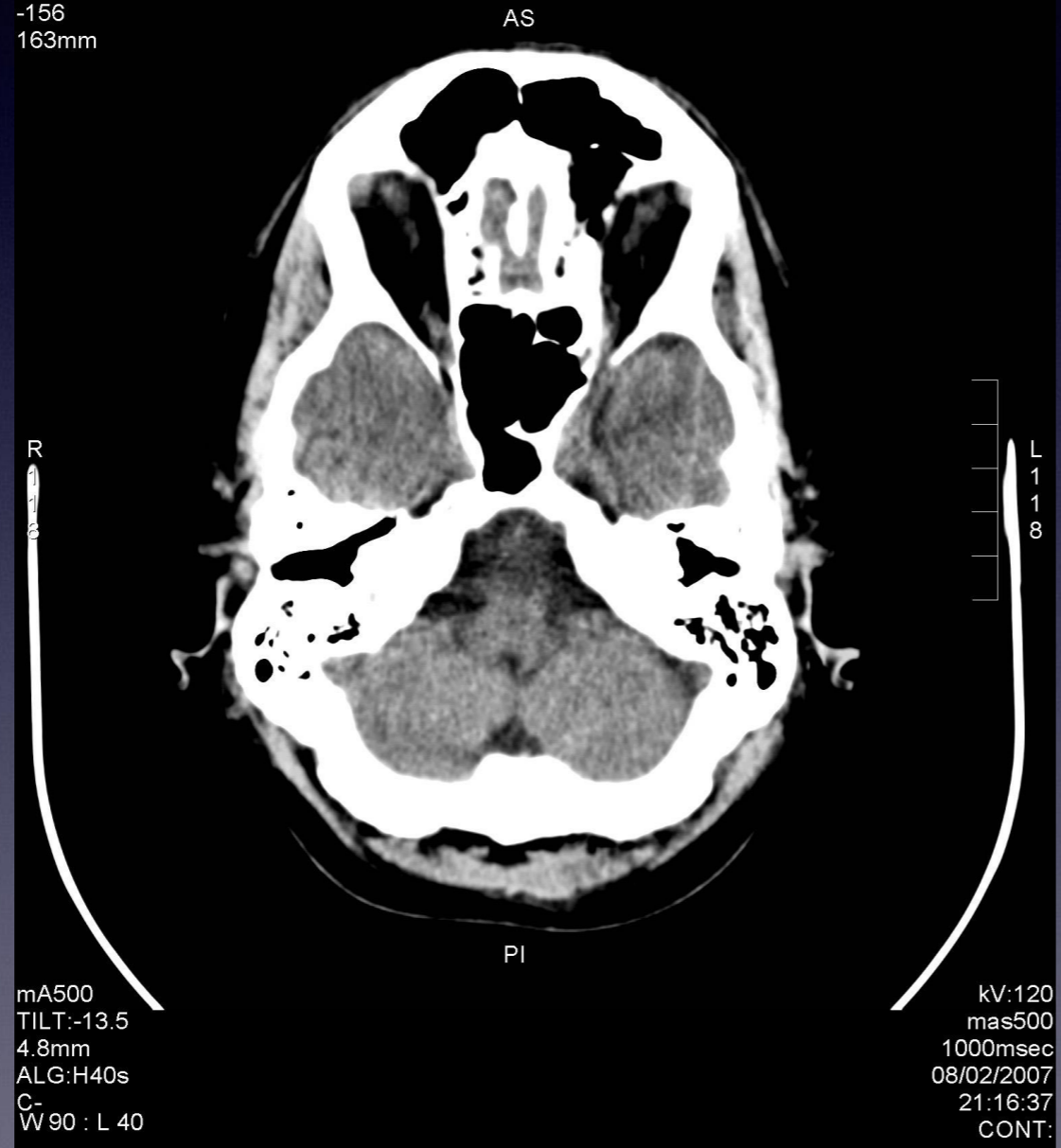
13



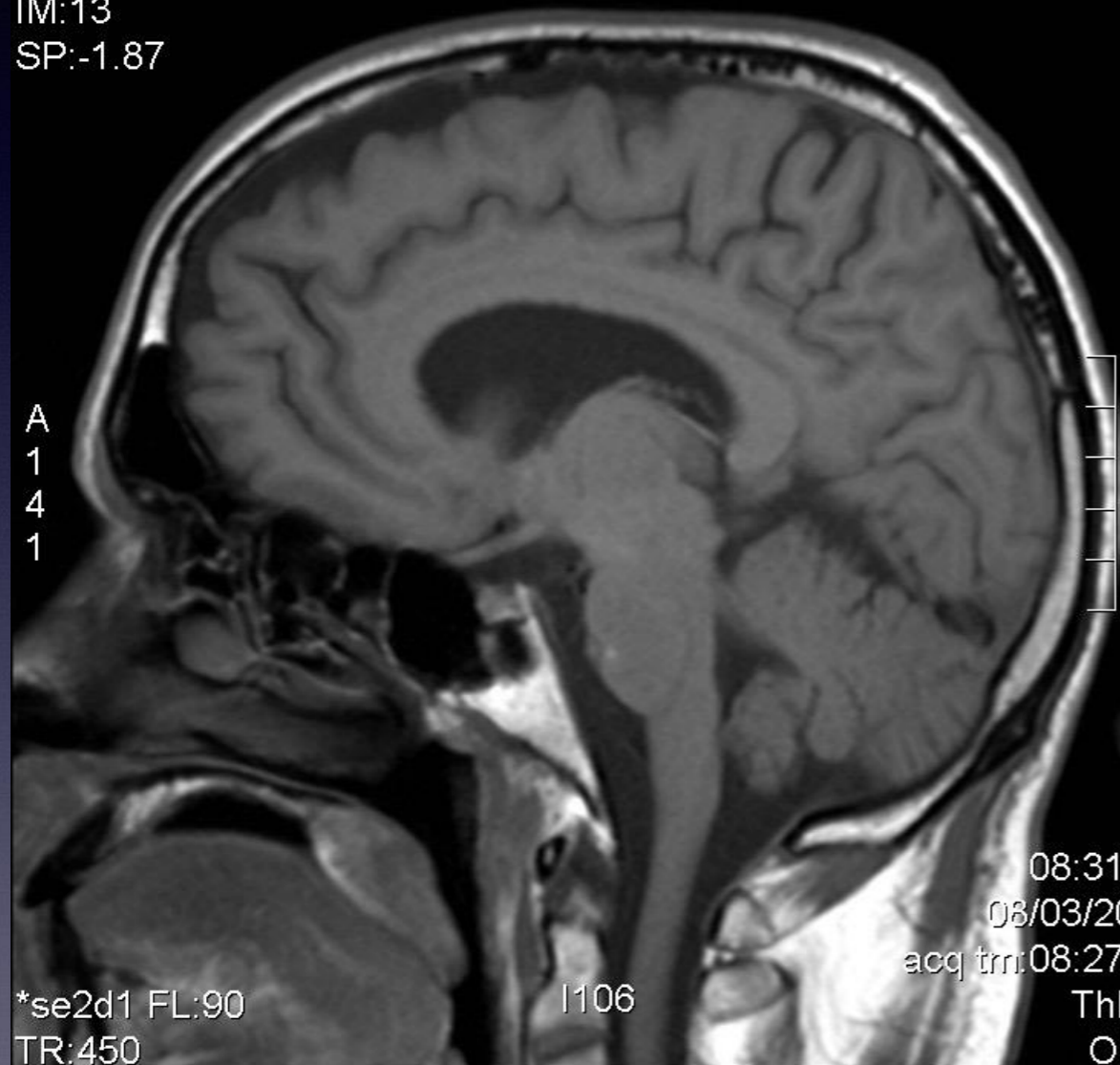
W 4096 : L 2048

GLOWACZ, GREGG D, 051Y M  
DOB: 12/30/1955  
MRN: 1625167  
A# 198916944  
SE: 2  
IM: 8  
-156  
163mm

WBH-RO  
ROECCT2  
21:09:05  
08/02/2007  
Im tm: 21:16:37  
HFS



GLOWACZ,GREGG D 051Y M William Beaumont Hospital MR3  
DOB:12/30/1955 ROIPMR3  
1625167 08/03/2007  
A#198922909 08:19:11  
SE:3 S123 HF  
IM:13  
SP:-1.87

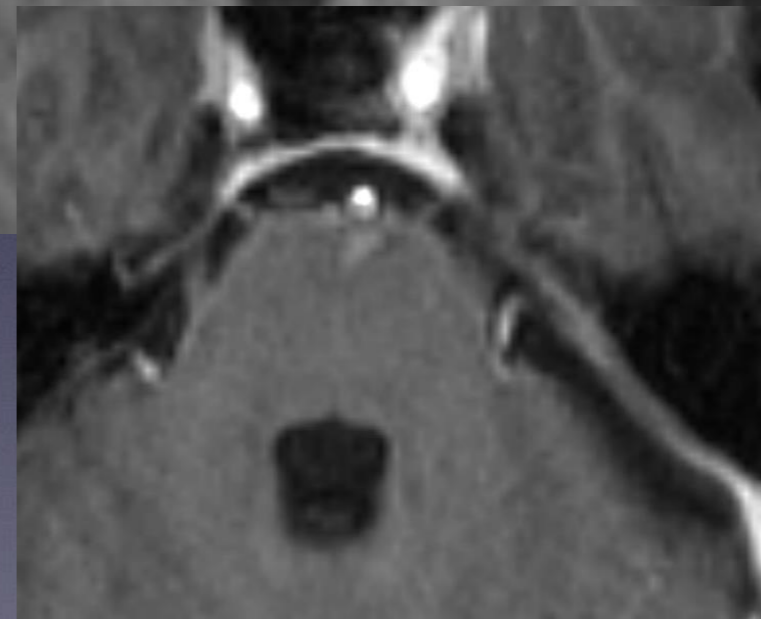
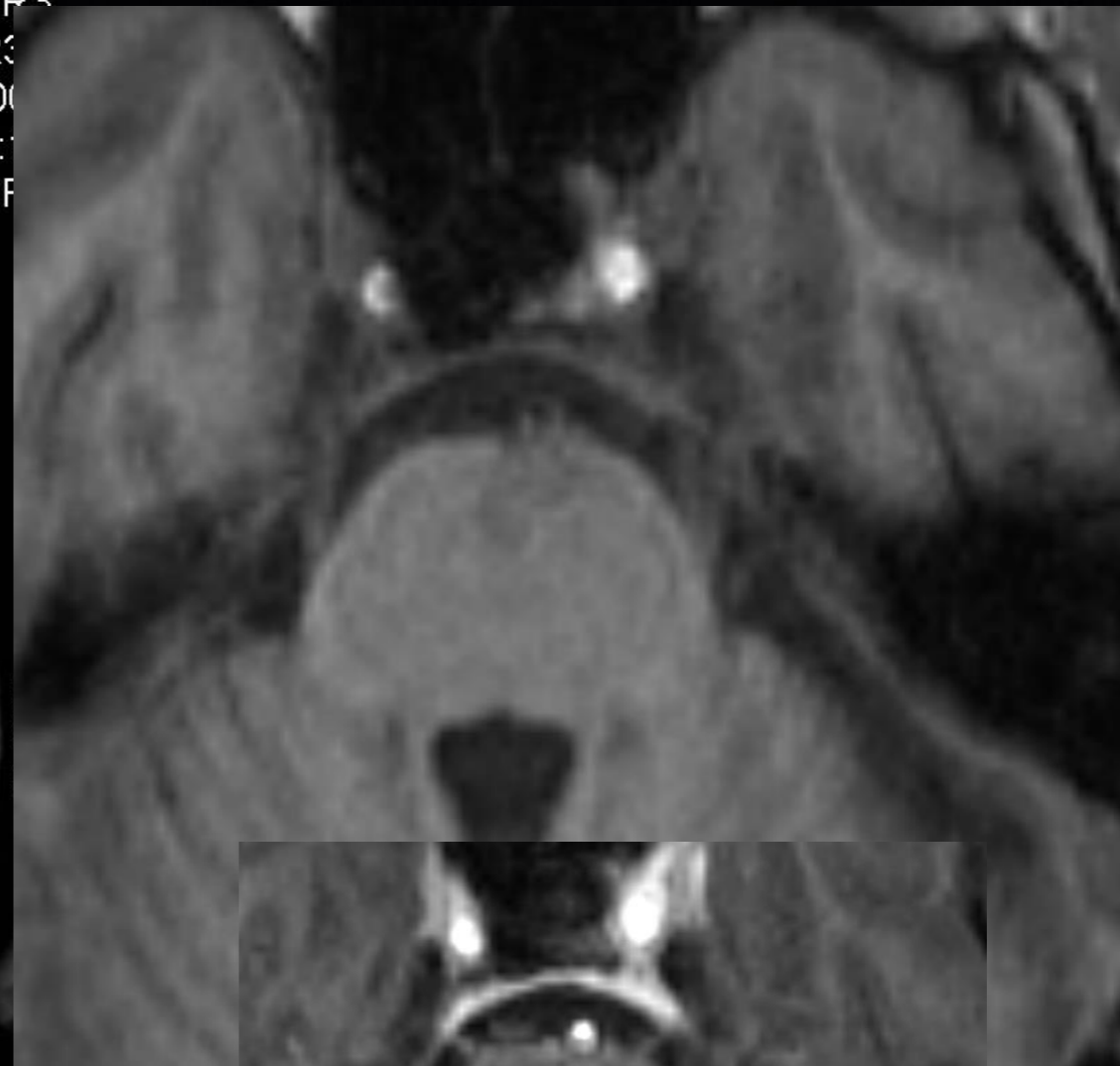


A  
1  
4  
1

\*se2d1 FL:90  
TR:450  
TE:7.8  
TI: ETL:1  
W 725 : L 368

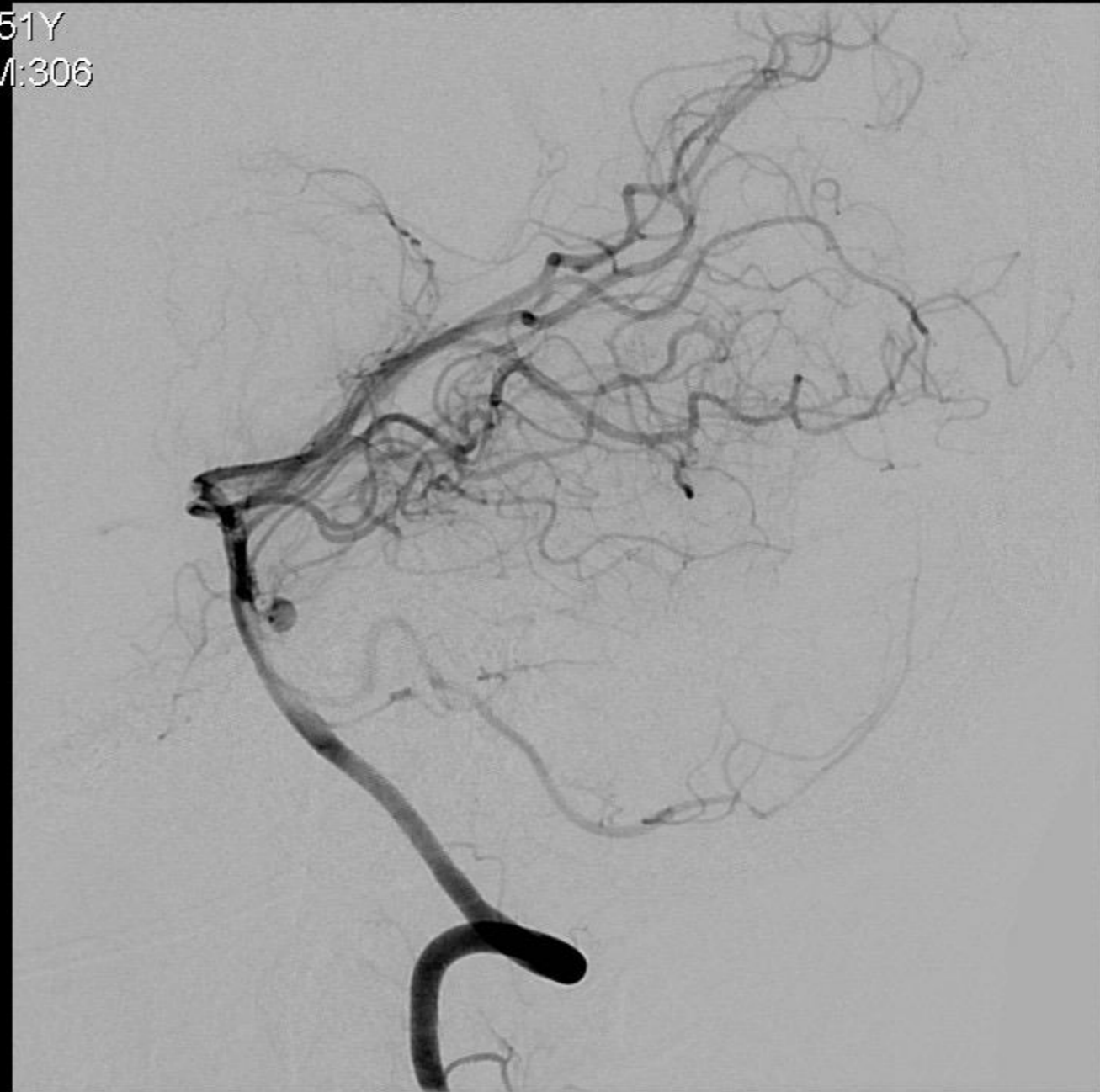I106

08:31:05  
08/03/2007  
acq trn:08:27:35  
Thk :5  
OR:0  
MA:512 X512  
BW:130  
t1\_se\_sag



GLOWACZ,GREGG D M  
ACCES#200165664  
1625167  
12/30/1955  
051Y  
IM:306

Wm Beaumont Hosp./9D70F0/  
SYS#@MIXEDXA  
08/22/2007  
09:44:19



08/22/2007  
W 4096 : L 2048

SM  
Rt Vertebral  
ARTERIOGRAM

GLOWACZ,GREGG D M  
ACCES#200165664  
1625167

Wm Beaumont Hosp./9D70F0/  
SYS#@MIXEDXA  
08/22/2007

12/30/1955

09:44:19

051Y

IM:1

GLOWACZ,GREGG D M  
ACCES#200165664  
1625167

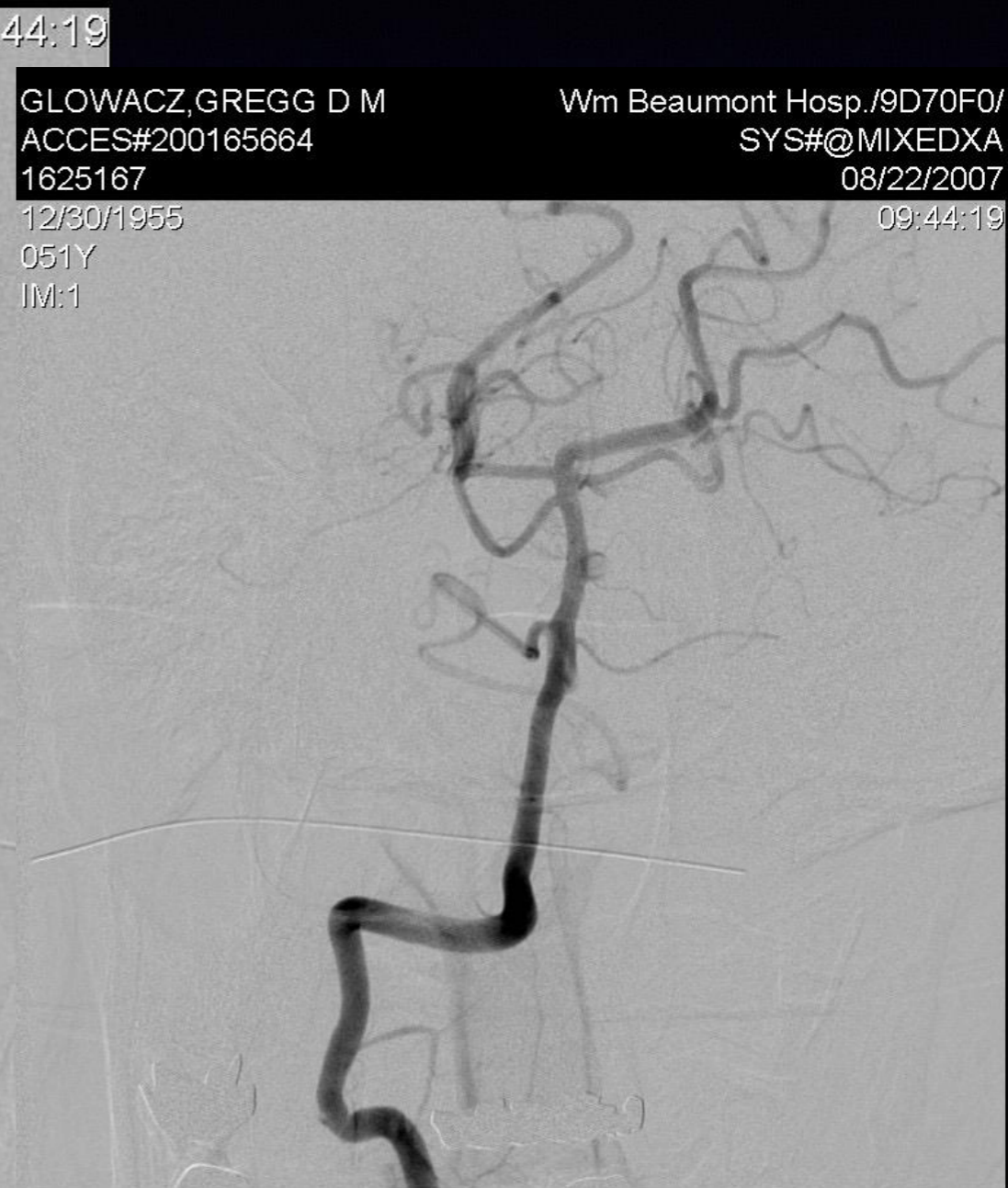
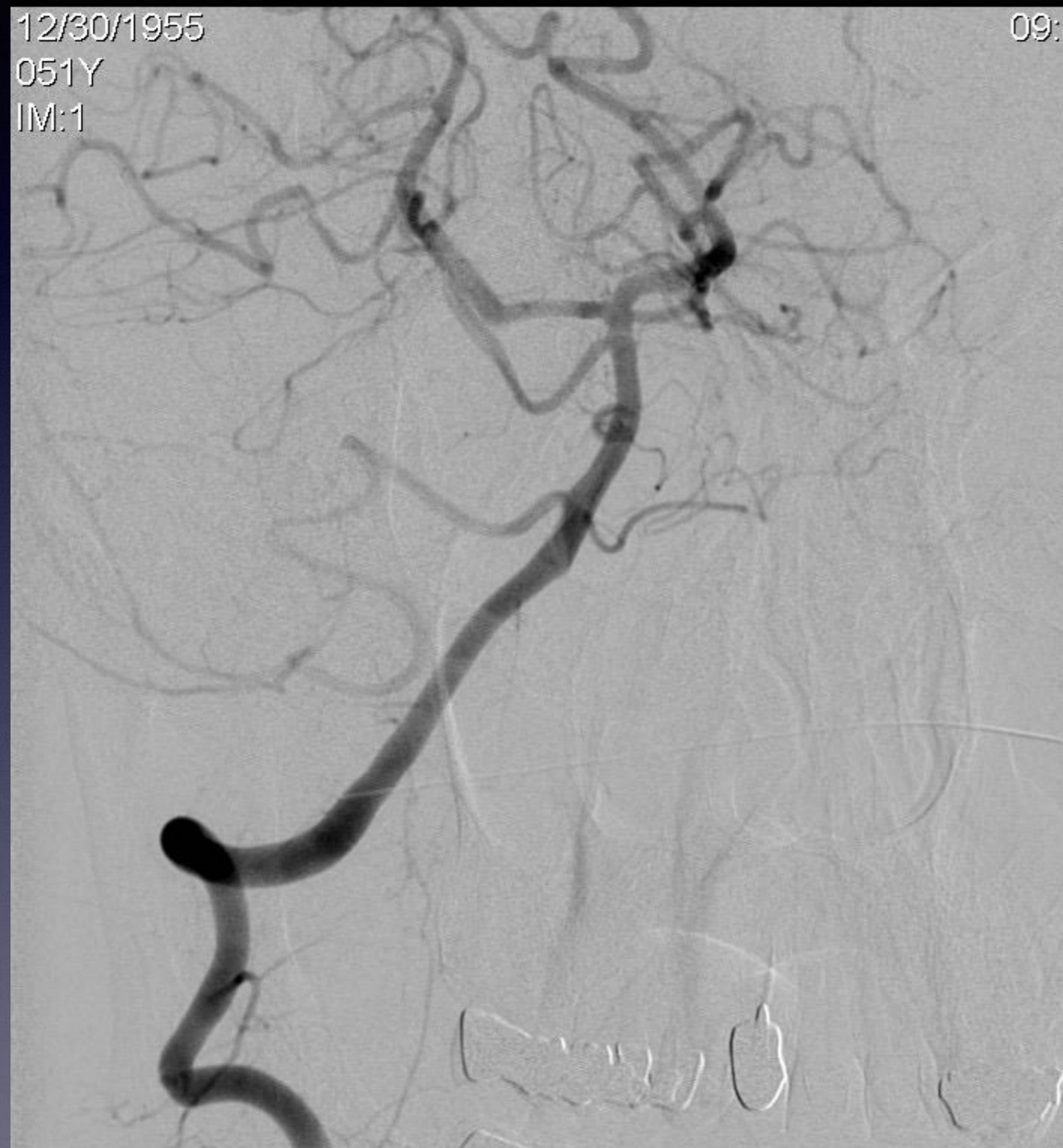Wm Beaumont Hosp./9D70F0/  
SYS#@MIXEDXA  
08/22/2007

12/30/1955

09:44:19

051Y

IM:1



08/22/2007  
W 4096 : L 2048

Rt Vertebral  
ARTERIOGRAM

08/22/2007  
W 4096 : L 2048

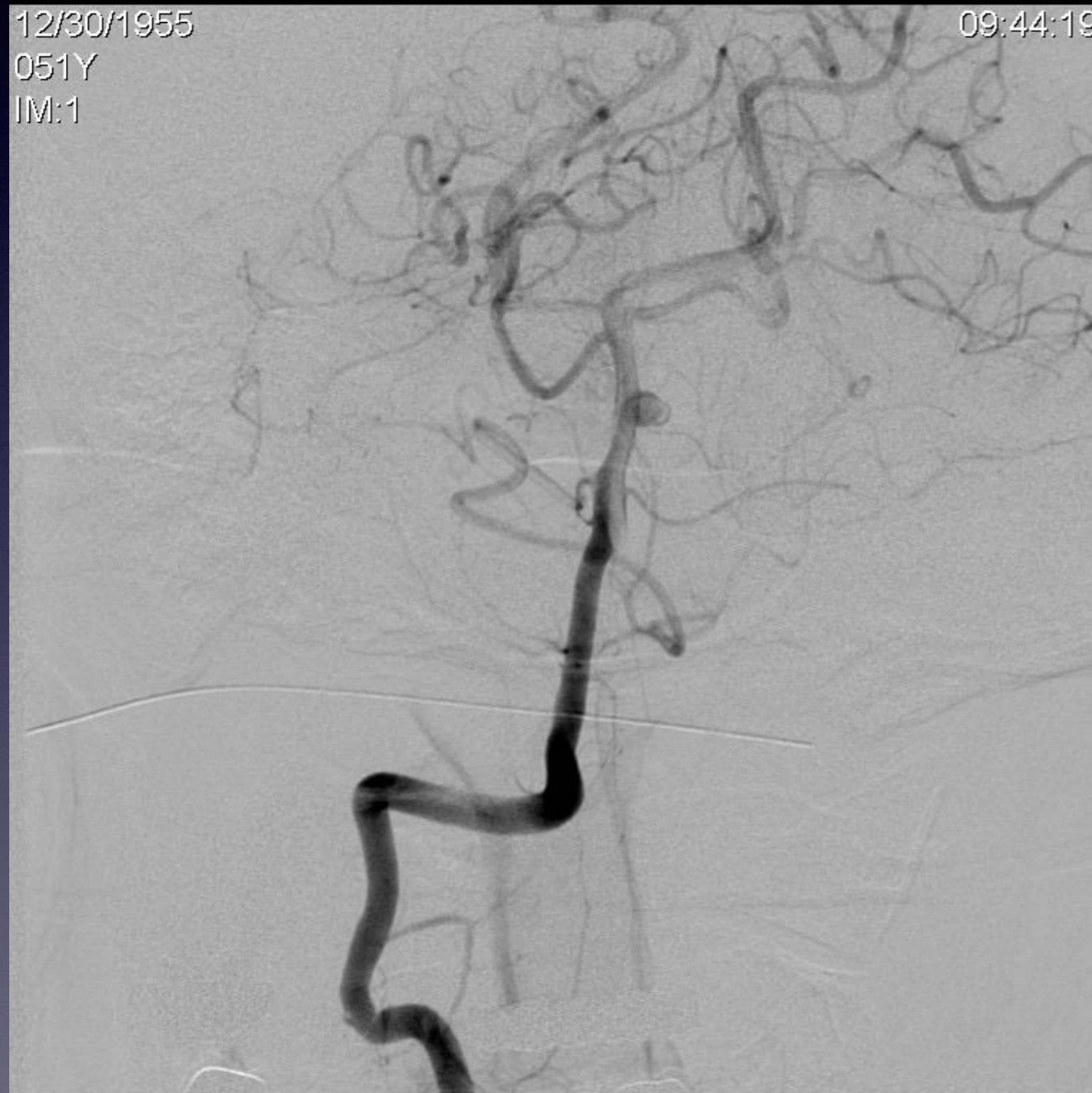Rt Vertebral  
ARTERIOGRAM

GLOWACZ,GREGG D M  
ACCES#200165664  
1625167

Wm Beaumont Hosp./9D70F0/  
SYS#@MIXEDXA  
08/22/2007

12/30/1955  
051Y  
IM:1

09:44:19



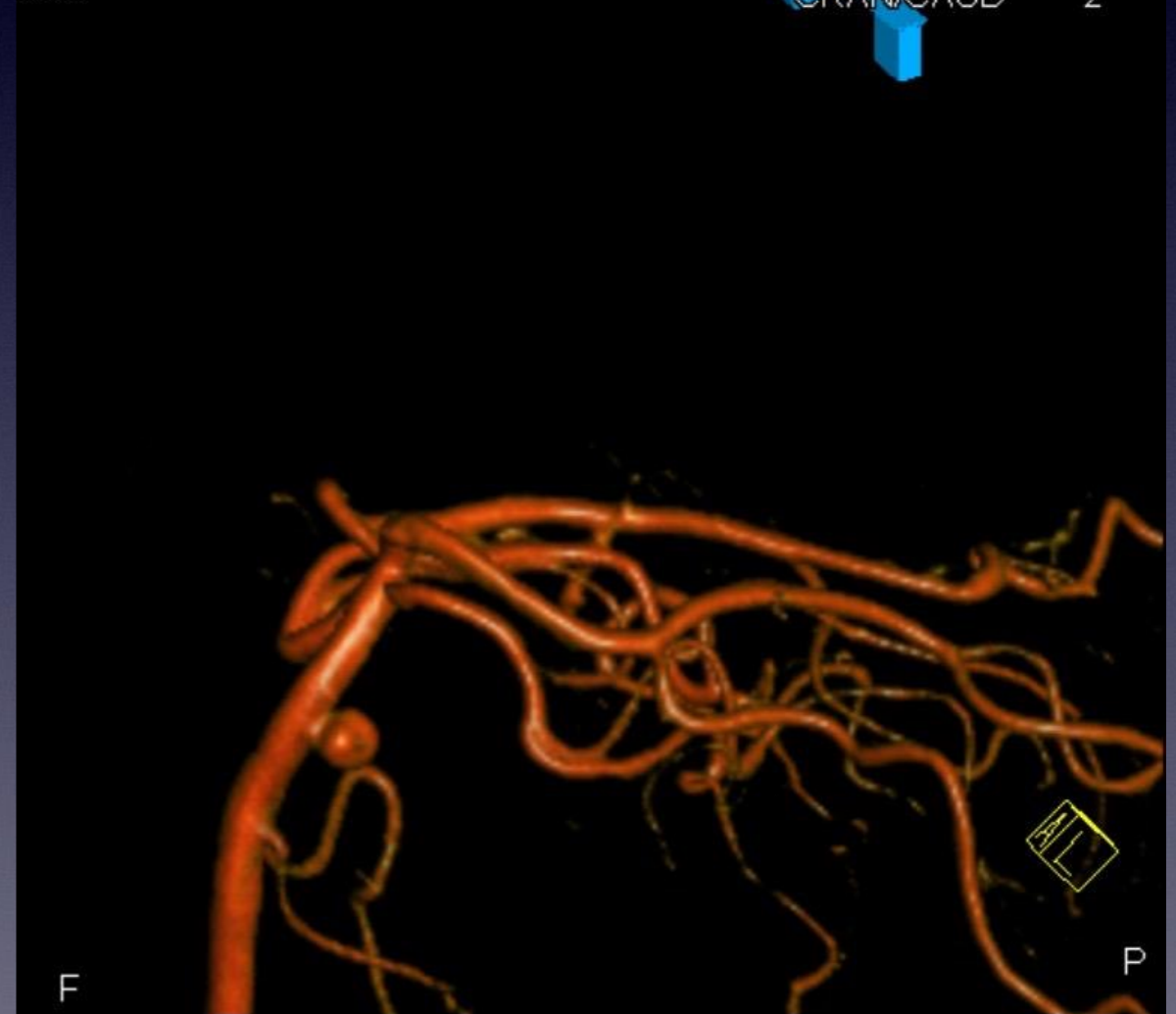
08/22/2007  
W 4096 : L 2048

Rt Vertebral  
ARTERIOGRAM

GLOWACZ,GREGG D M  
ACCES#200165664  
1625167  
12/30/1955  
051Y  
IM:1

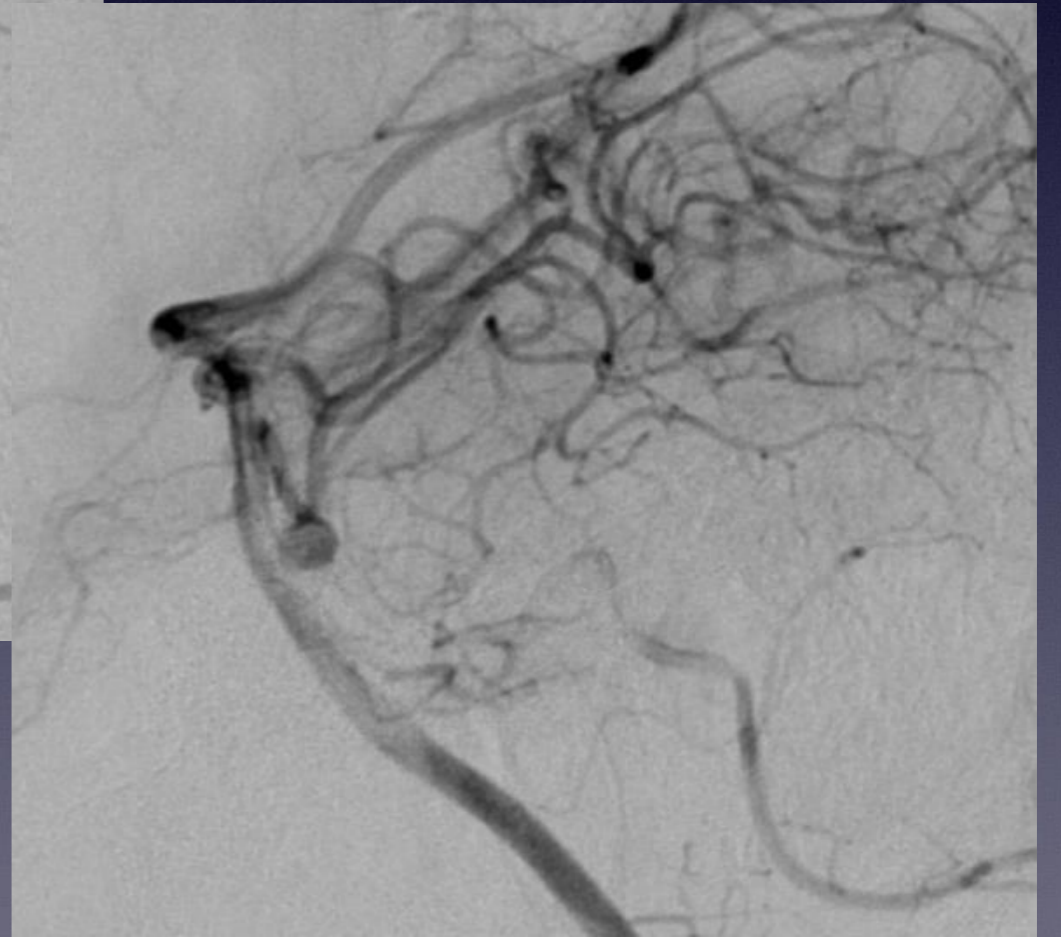
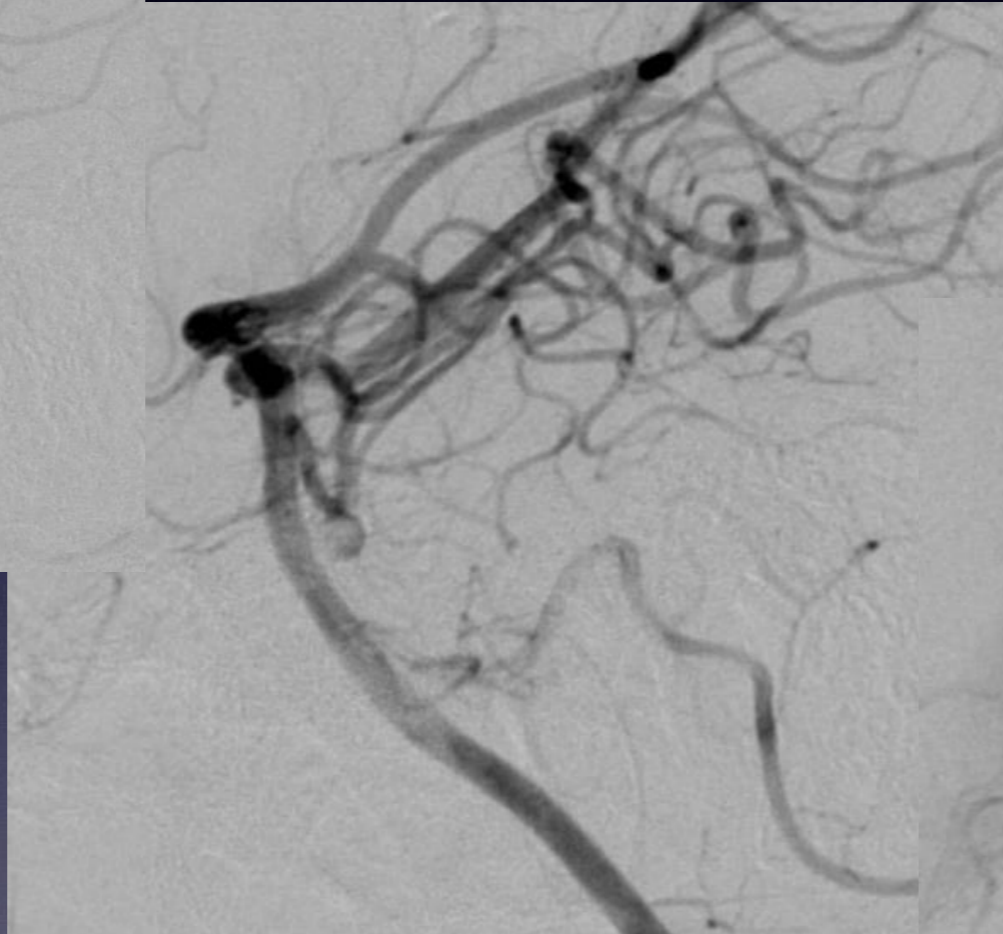
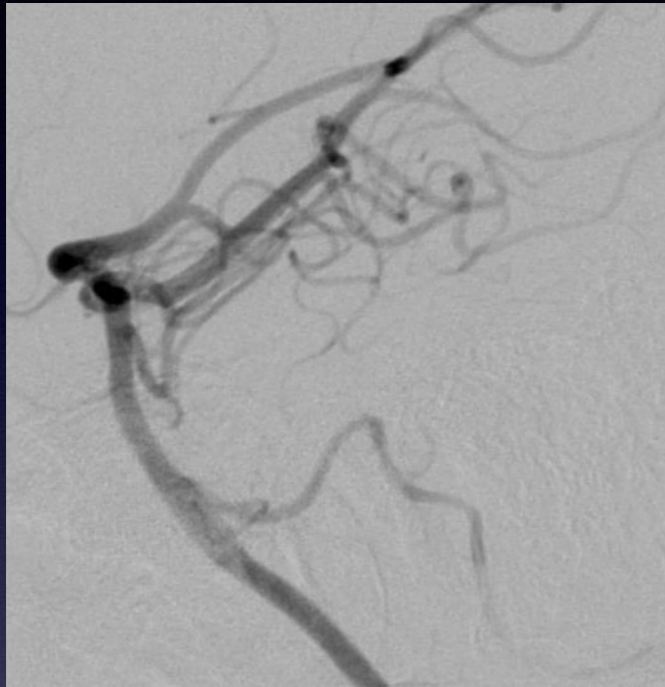Wm Beaumont Hosp./9D70F0/  
SYS#@MIXEDXA  
08/22/2007  
09:44:19

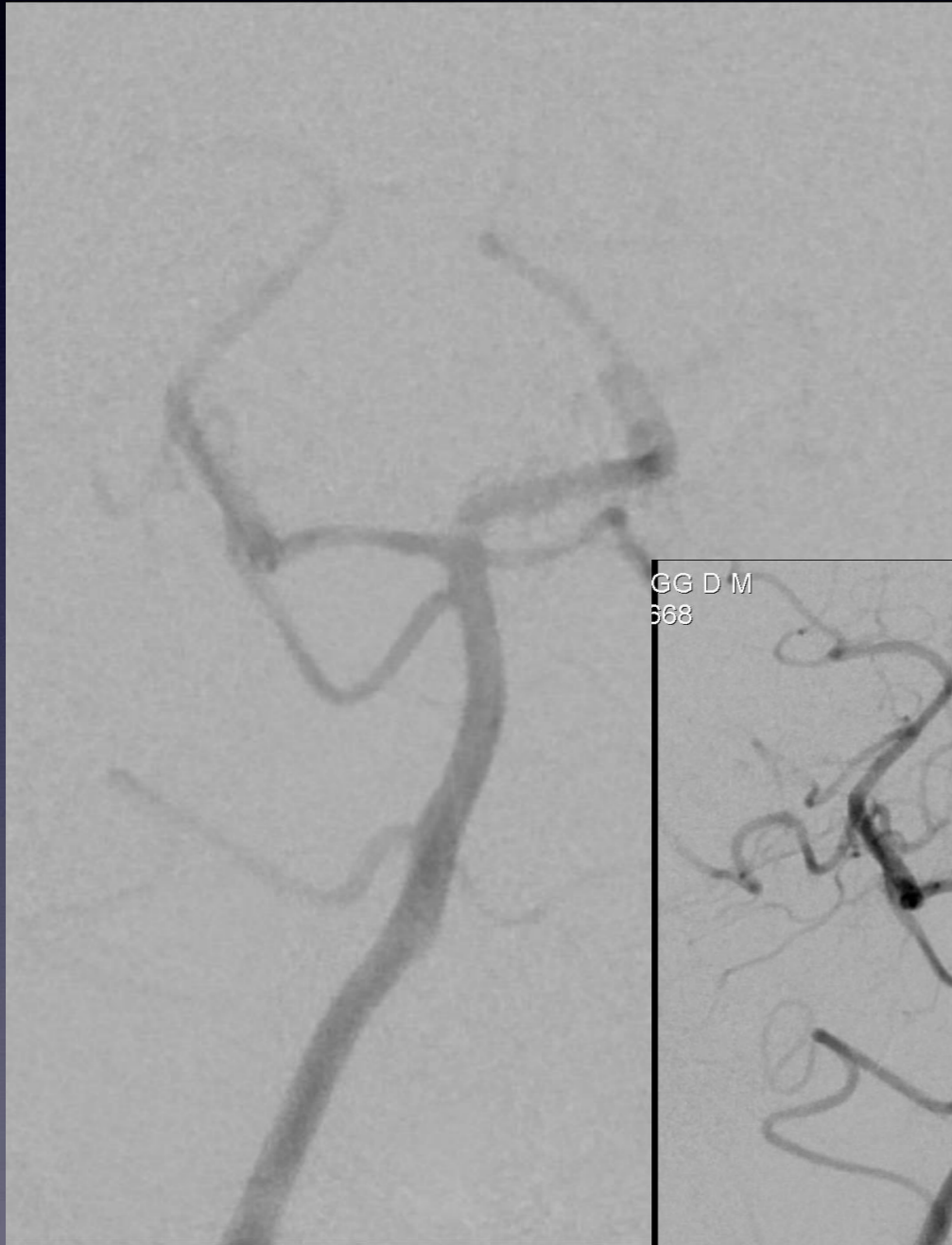LAO/RAO 71  
CRAN/CAUD 2



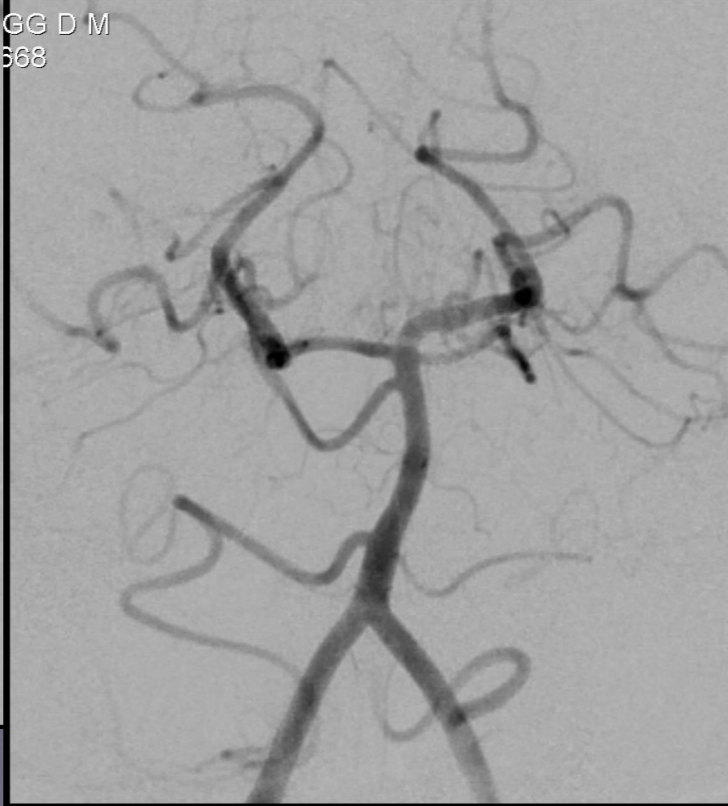08/22/2007  
W 249 : L 125

<VRT Collection>  
ARTERIOGRAM

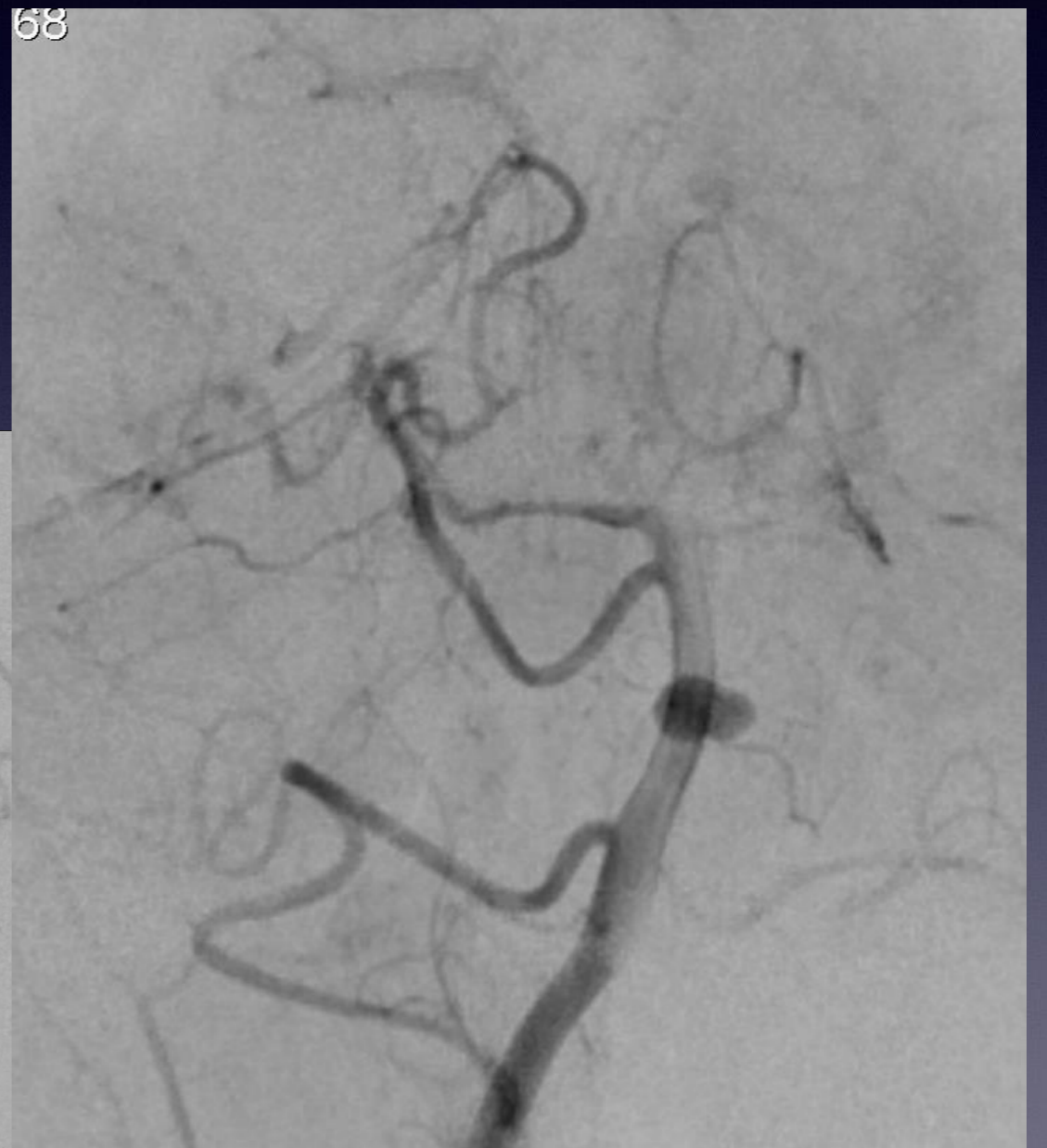



GG D M  
568



68



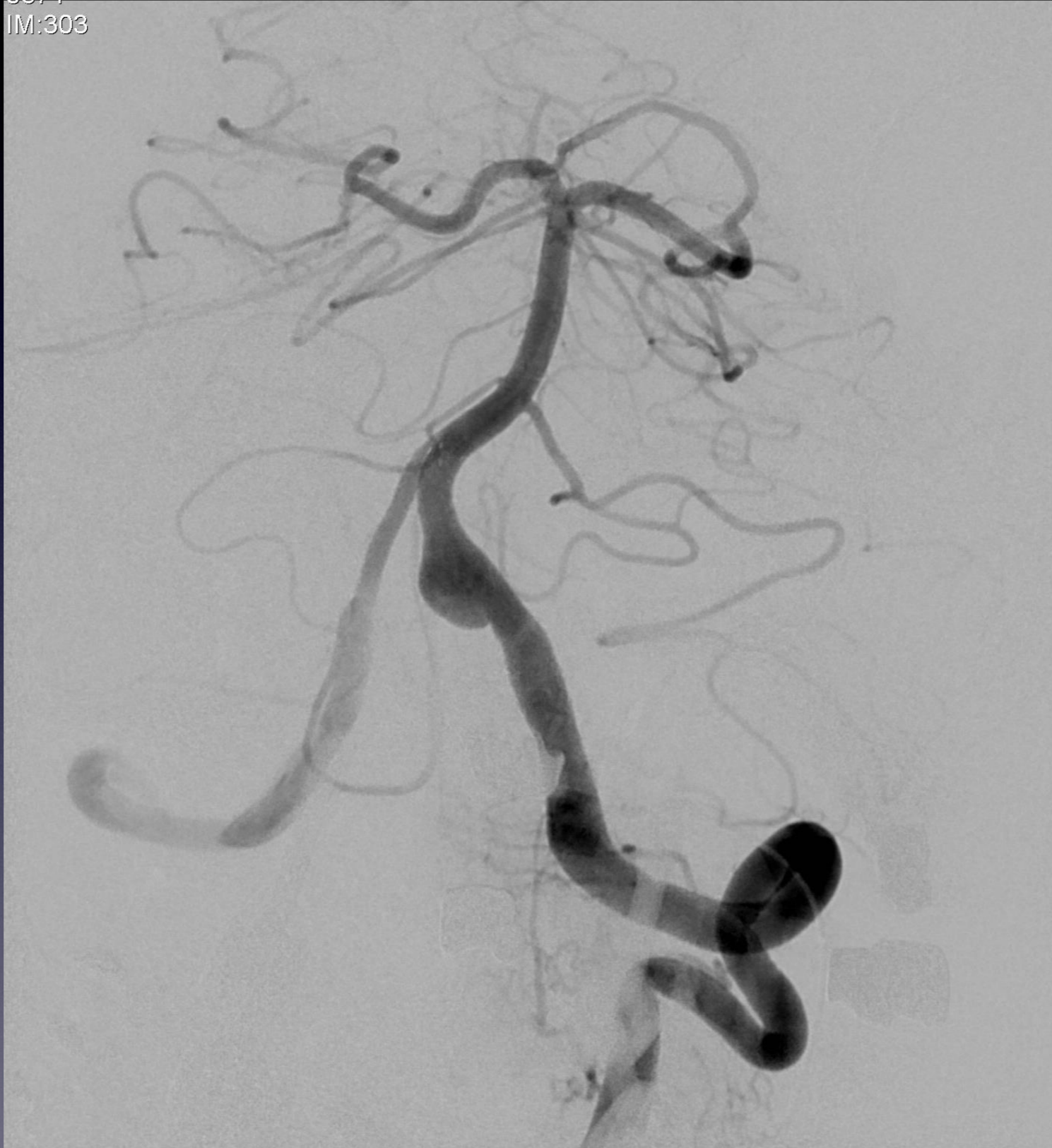

# Διαχωριστικά ανευρύσματα

- Σπάνια αιτία υπαραχνοειδούς αιμορραγίας
- 4.5% of autopsy SAH cases (Sakaki et al 1991)
- Importance of serial imaging

2241221  
12/21/1938  
067Y  
IM:303

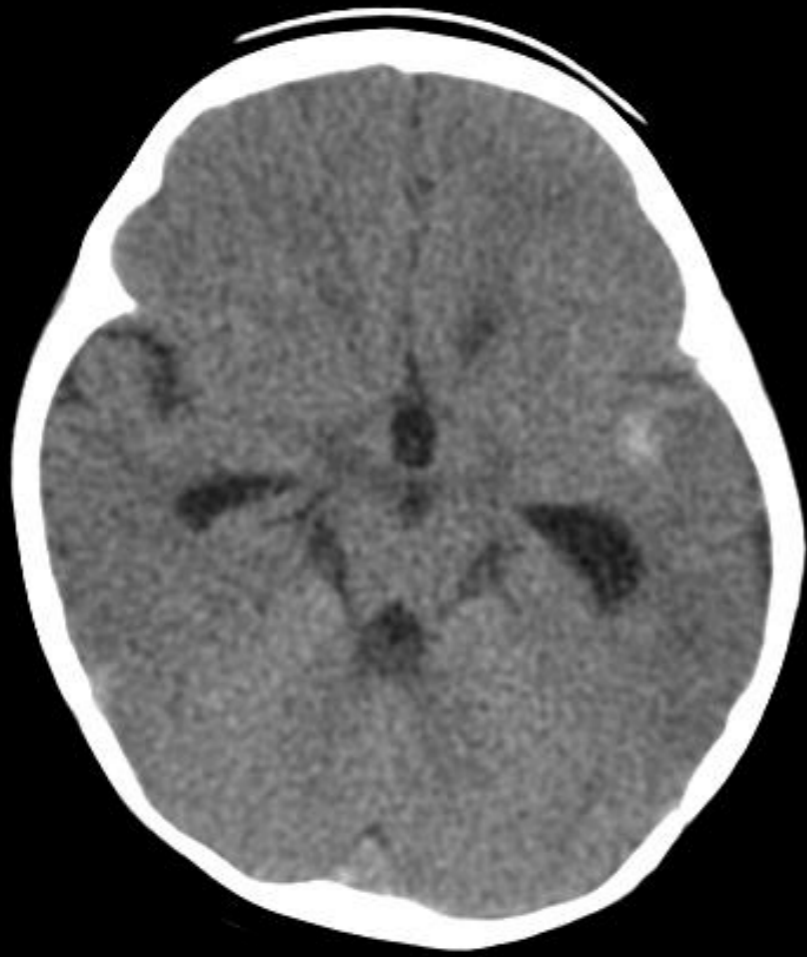117  
1



Infant with aneurysm

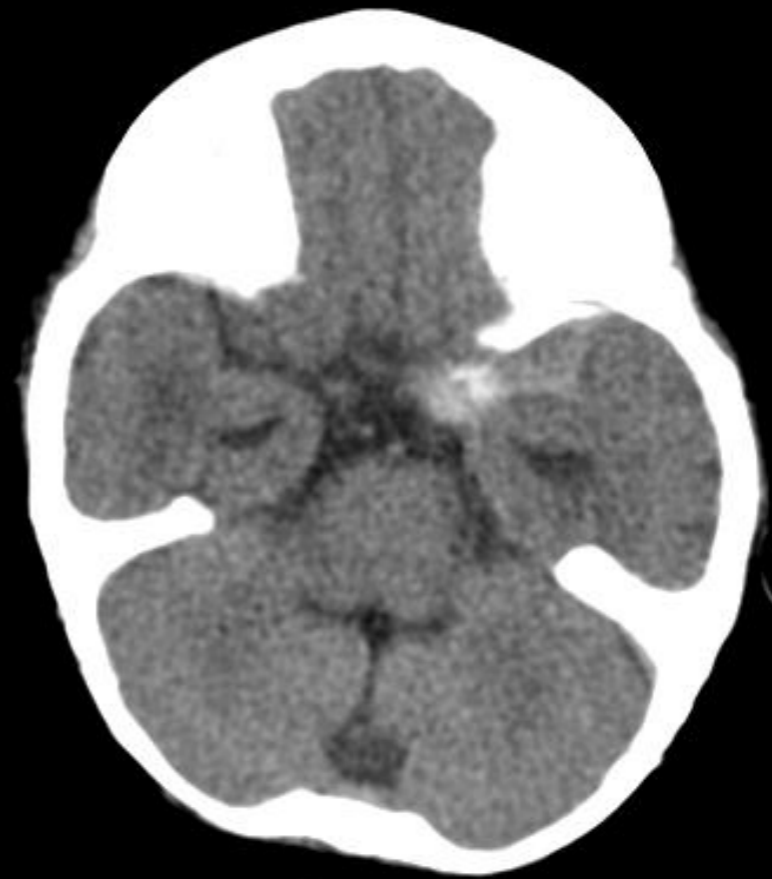- The child was premature baby delivered by C-section 26 week gestation . The pregnancy was diagnosed 2 weeks prior to C-section on abdominal XRay performed for hip pain. The child was exposed tp chemotherapy with 3 cycles of (Toxol,cyclophosphamide, adriamycin) due to maternal breast cancer.
- At birth the child weight was 745 grams and was noted to have low set ears, absent left thumb and small right thumb.
- A VSD was noted which was successfully closed at 4 months of age.

# 7 month old



Page: 6 of 20

IM: 6 SE: 2



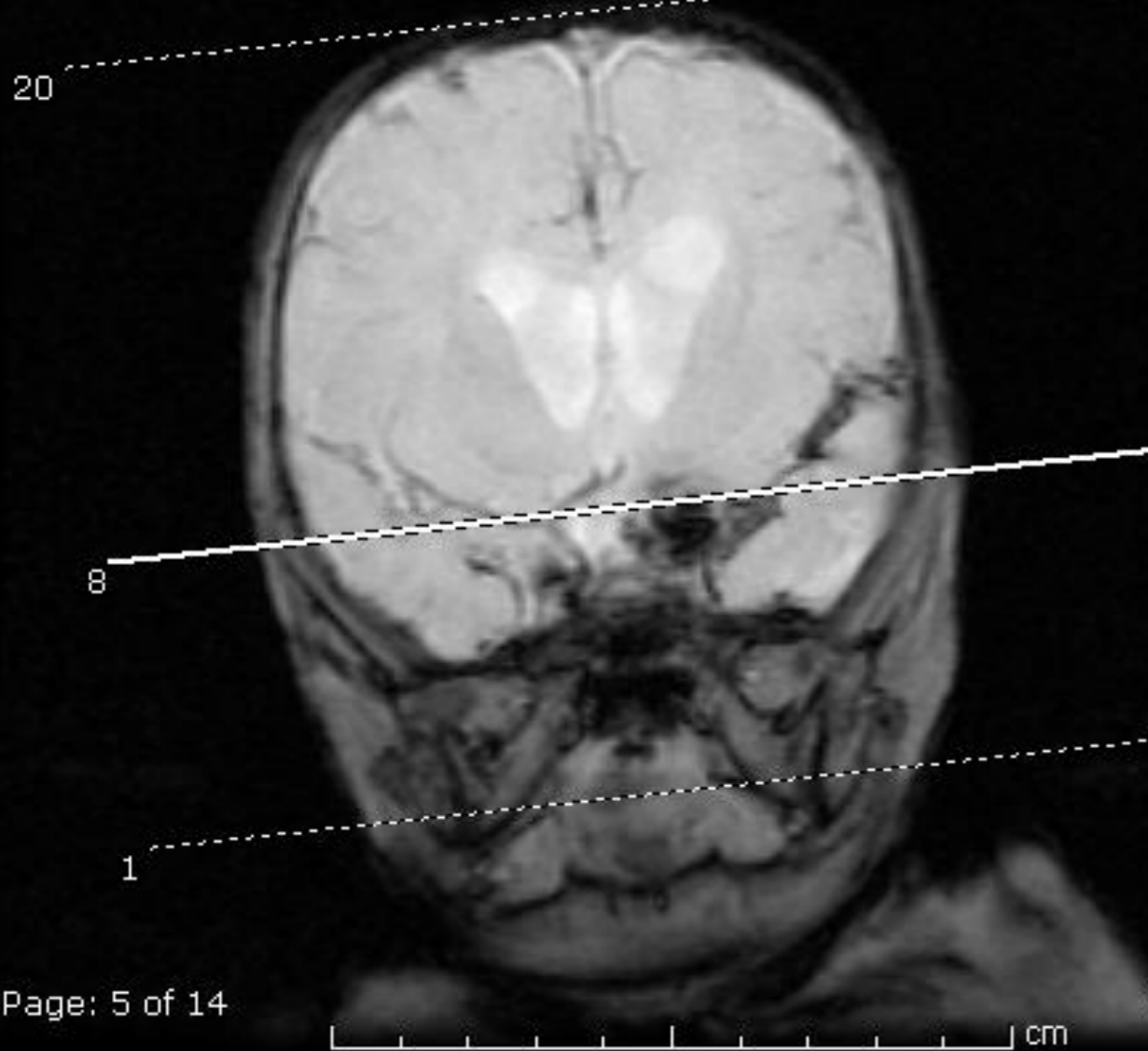
Page: 4 of 20

IM: 4 SE: 2

Normandeau, Emma  
4057596  
1/14/2005  
7 MONTH  
F

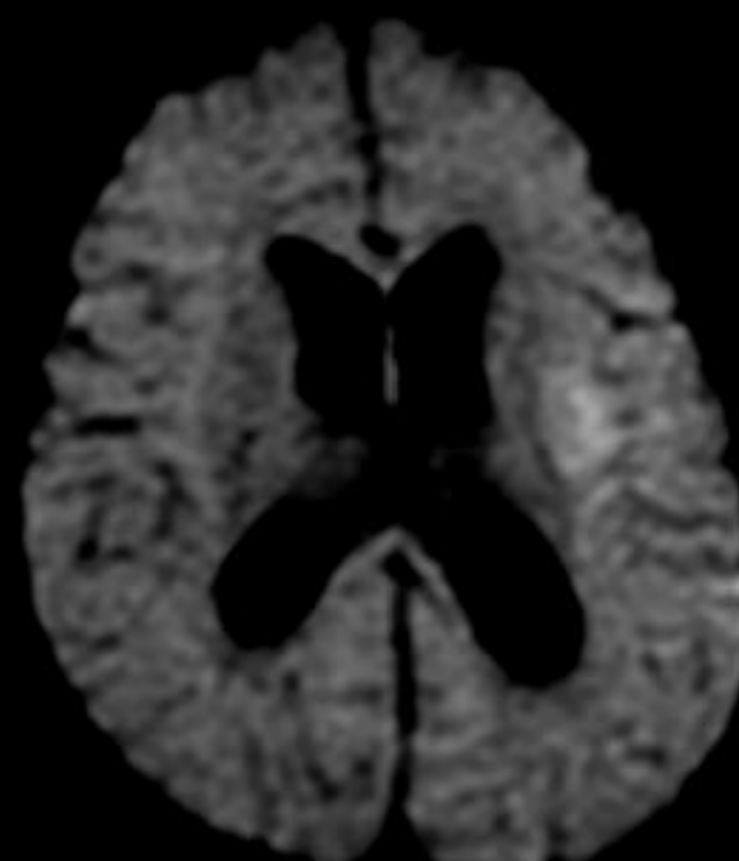
A Dartmouth Hitchcock Med Center  
OUTSIDE MRI IMAGES ON PACS  
HD DWI Ax  
8/23/2005 6:49:42 PM  
10150739

LOC: 28.12  
THK: 5 SP: 5  
HFS



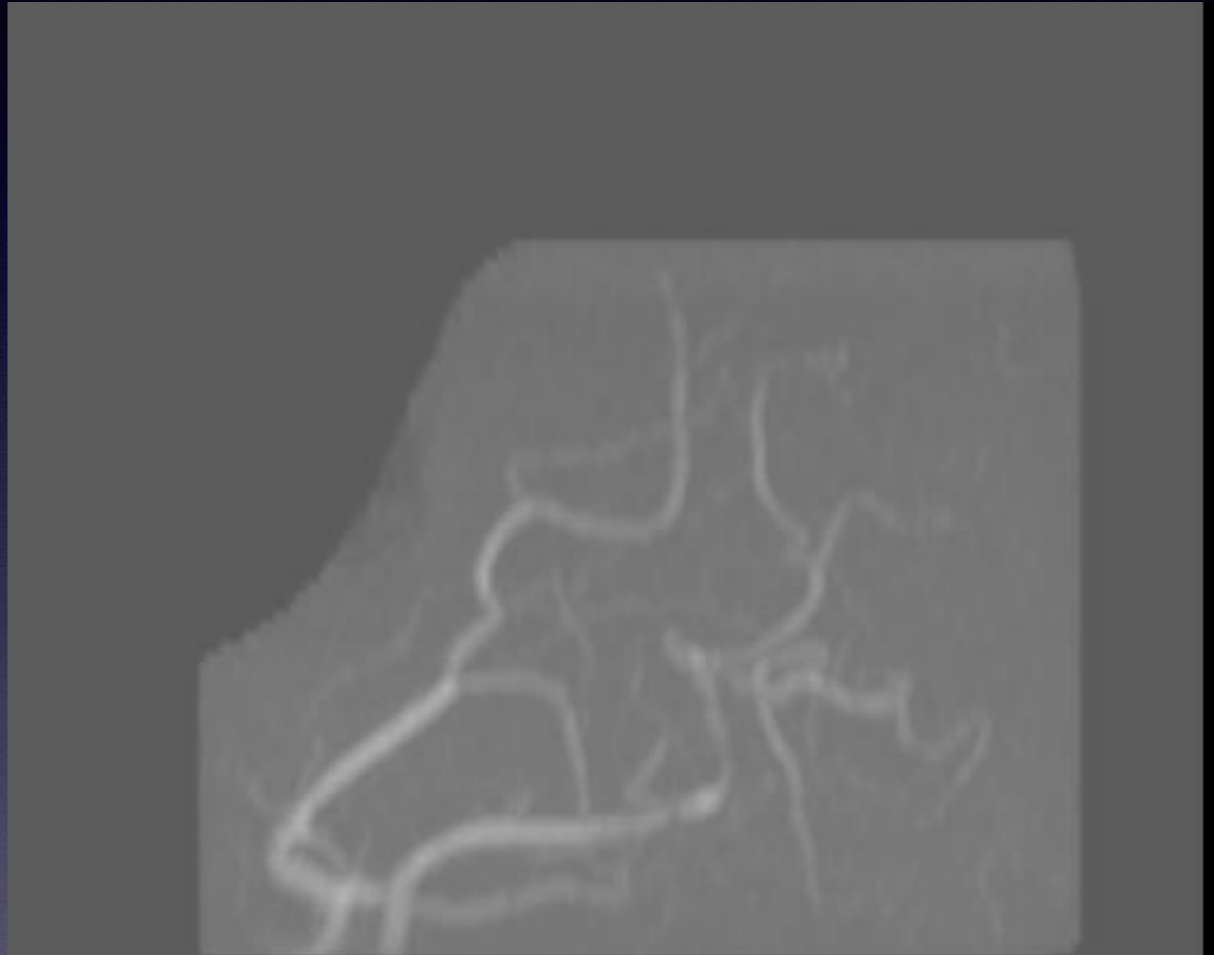
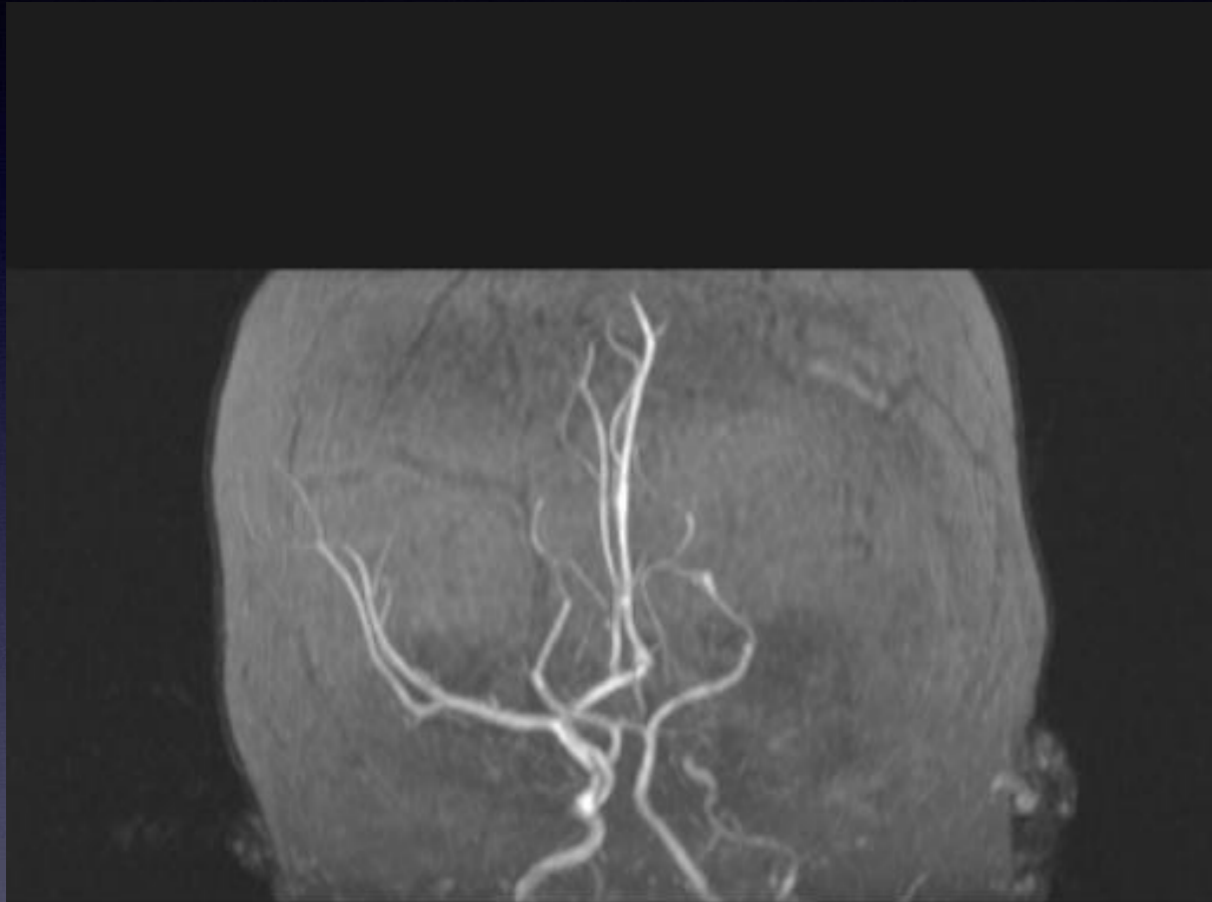HEAD  
EC: 1  
EP\RM  
FA: 90  
TR: 10000  
TE: 115.90

Page: 14 of 46



Z: 2  
C: 558  
W: 570

IM: 14 SE: 3



1/14/2005  
8 MONTH  
F

R

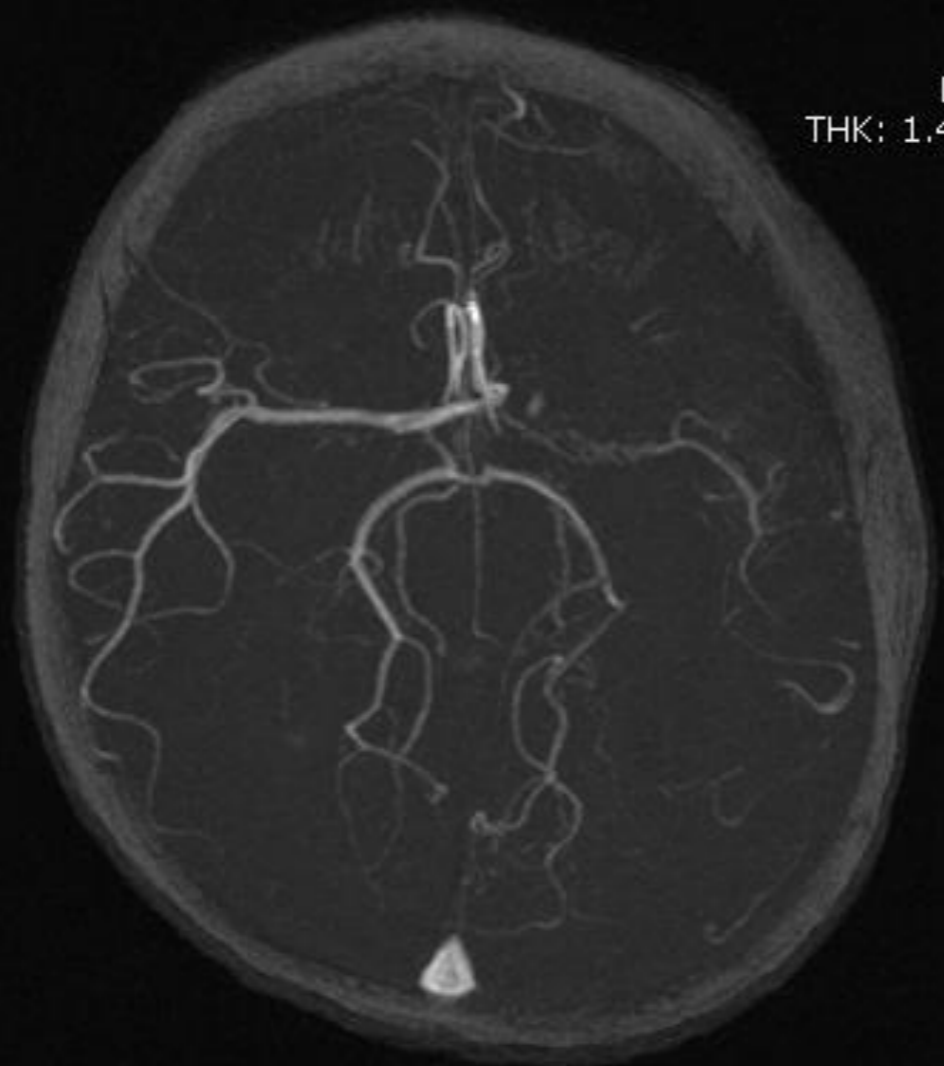
HEAD  
EC: 1  
GR  
FA: 20  
TR: 36  
TE: 6.90

Page: 1 of 92

A

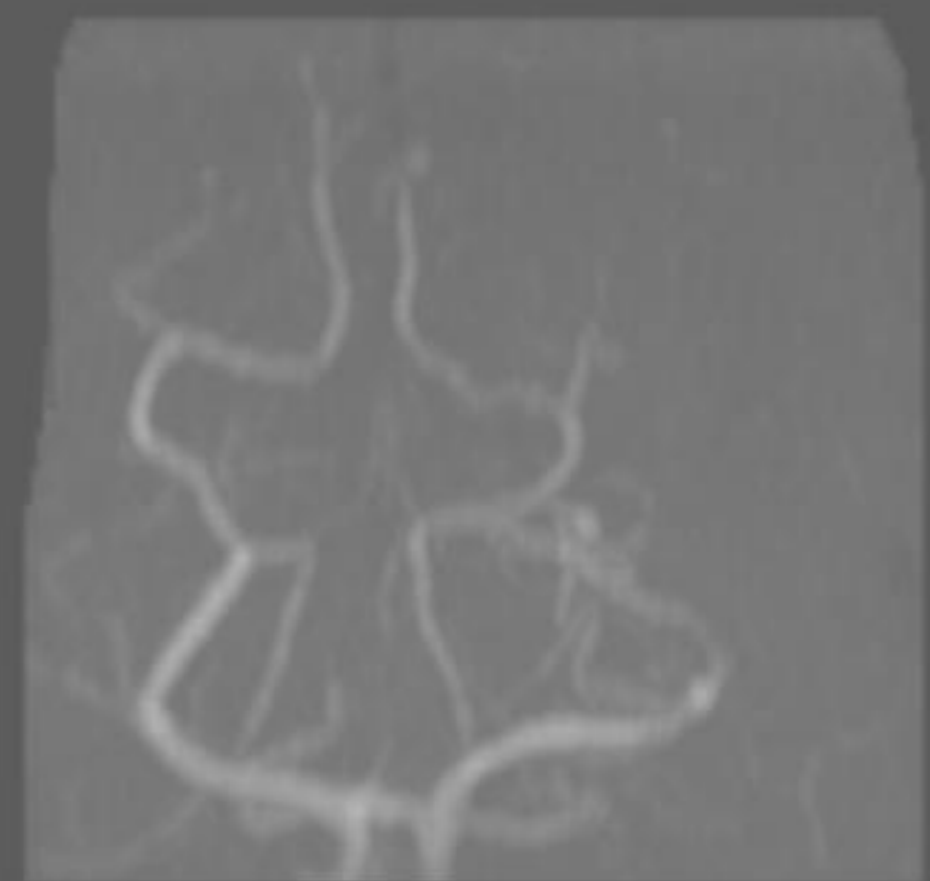
OUTSIDE MRI IMAGES

9/27/2005 3:  
1  
LC  
THK: 1.40



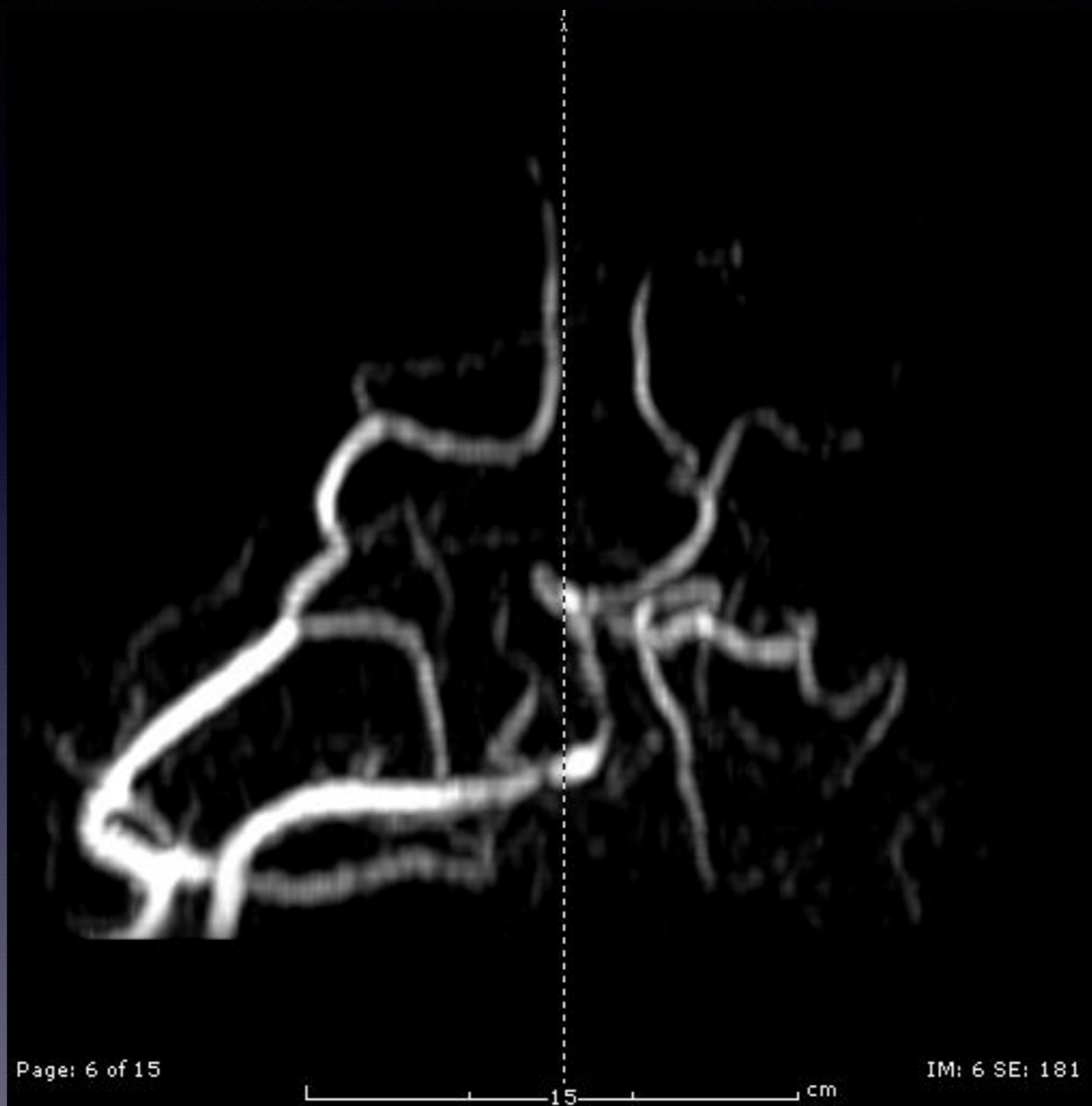
P

IM Page: 9 of 15

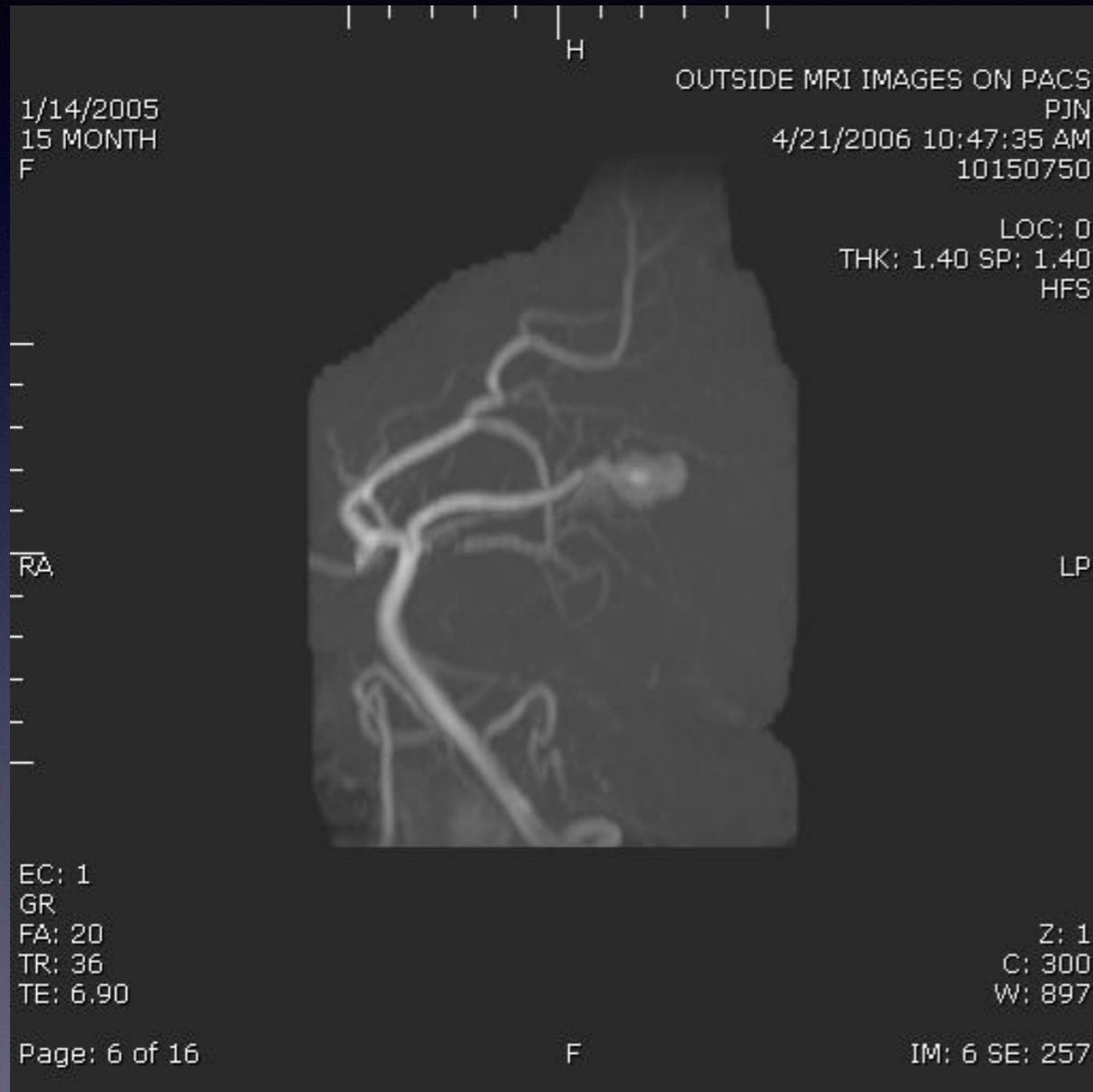

IM: 9 SE: 181





# 13 month



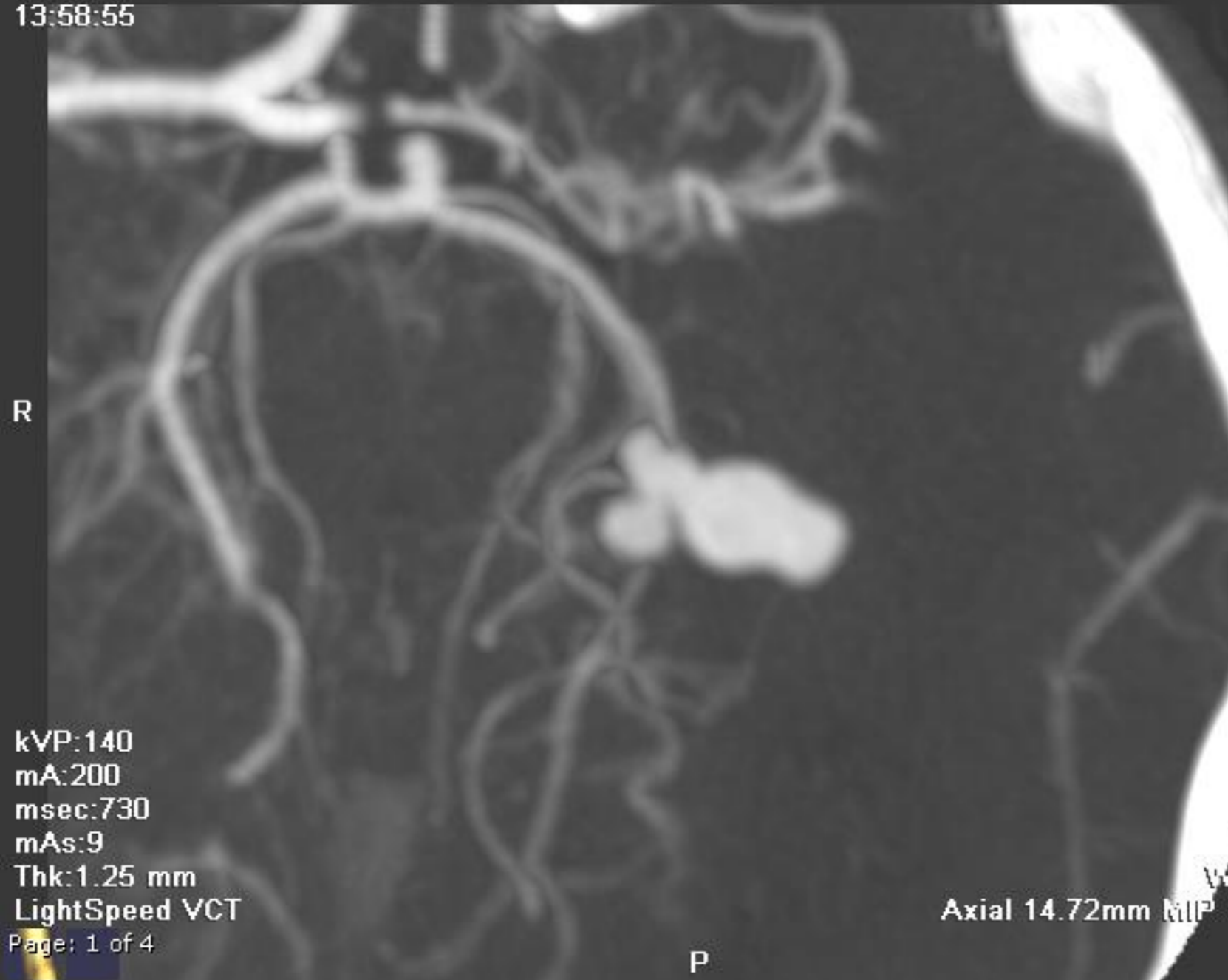
Age: 15 months

F

02 May 2006

13:58:55

CT Circle o



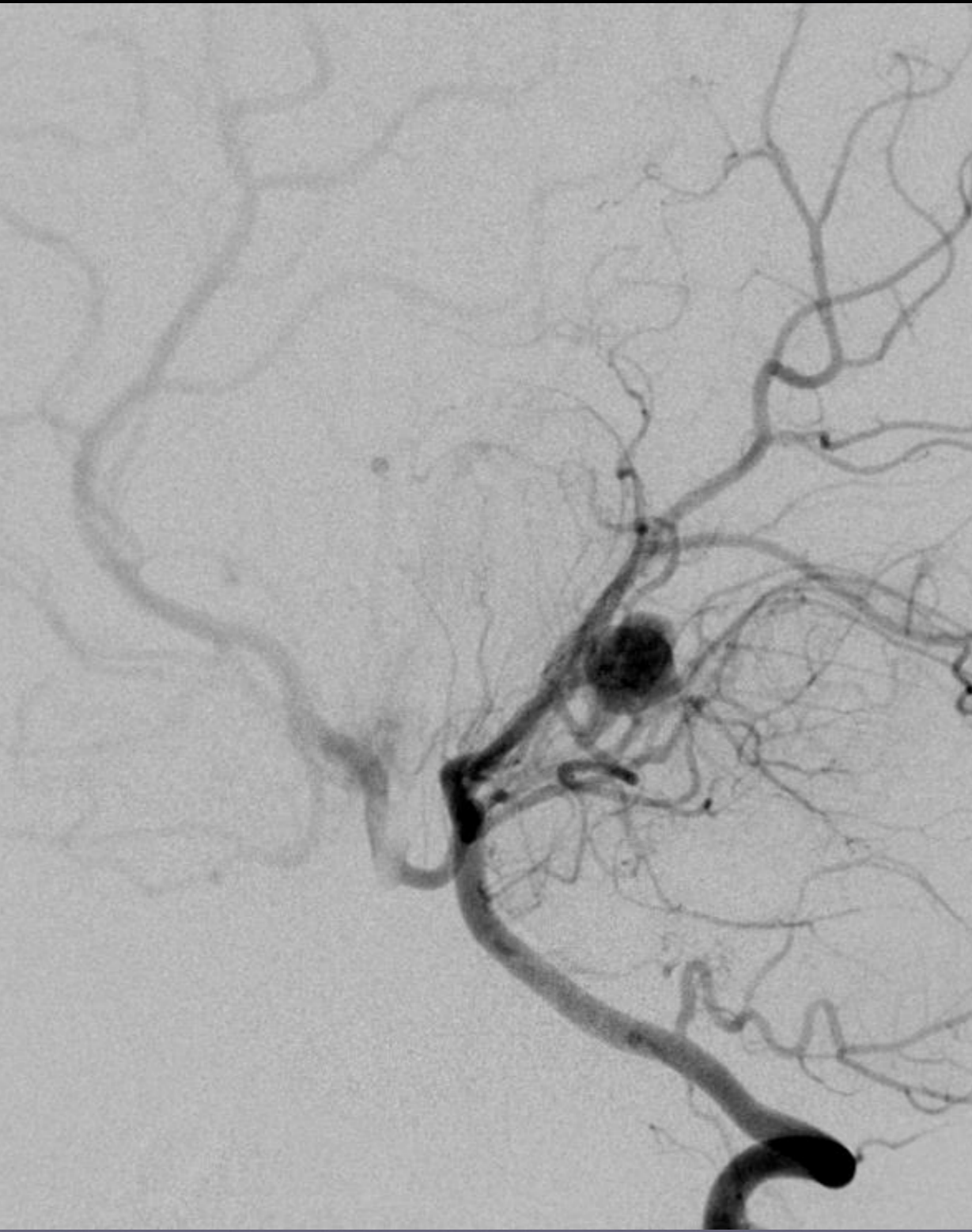
R

kVP: 140  
mA: 200  
msec: 730  
mAs: 9  
Thk: 1.25 mm  
LightSpeed VCT

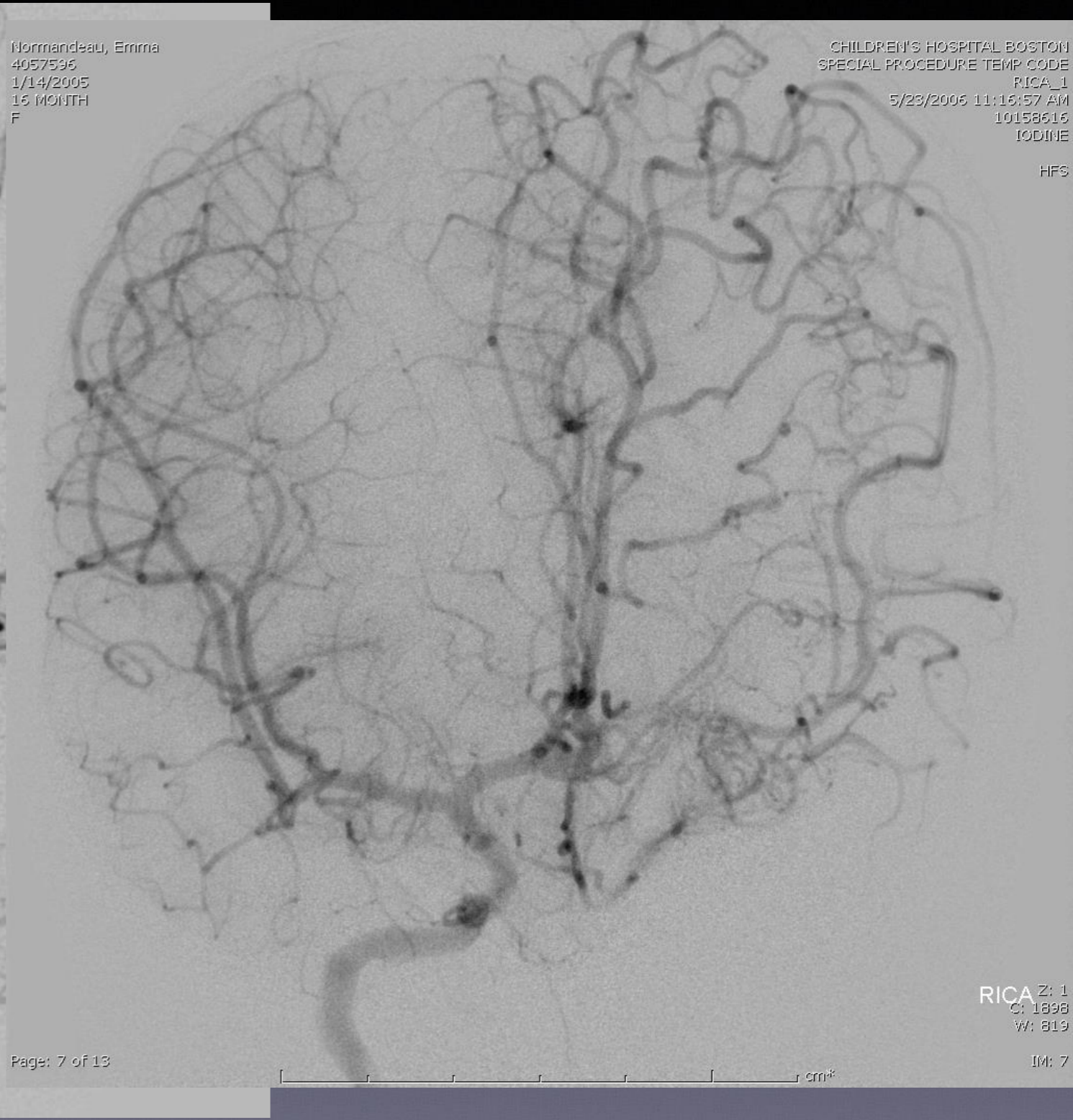
Page: 1 of 4

Axial 14.72mm MIP S

P



Normandeau, Emma  
4057596  
1/14/2005  
16 MONTH  
F



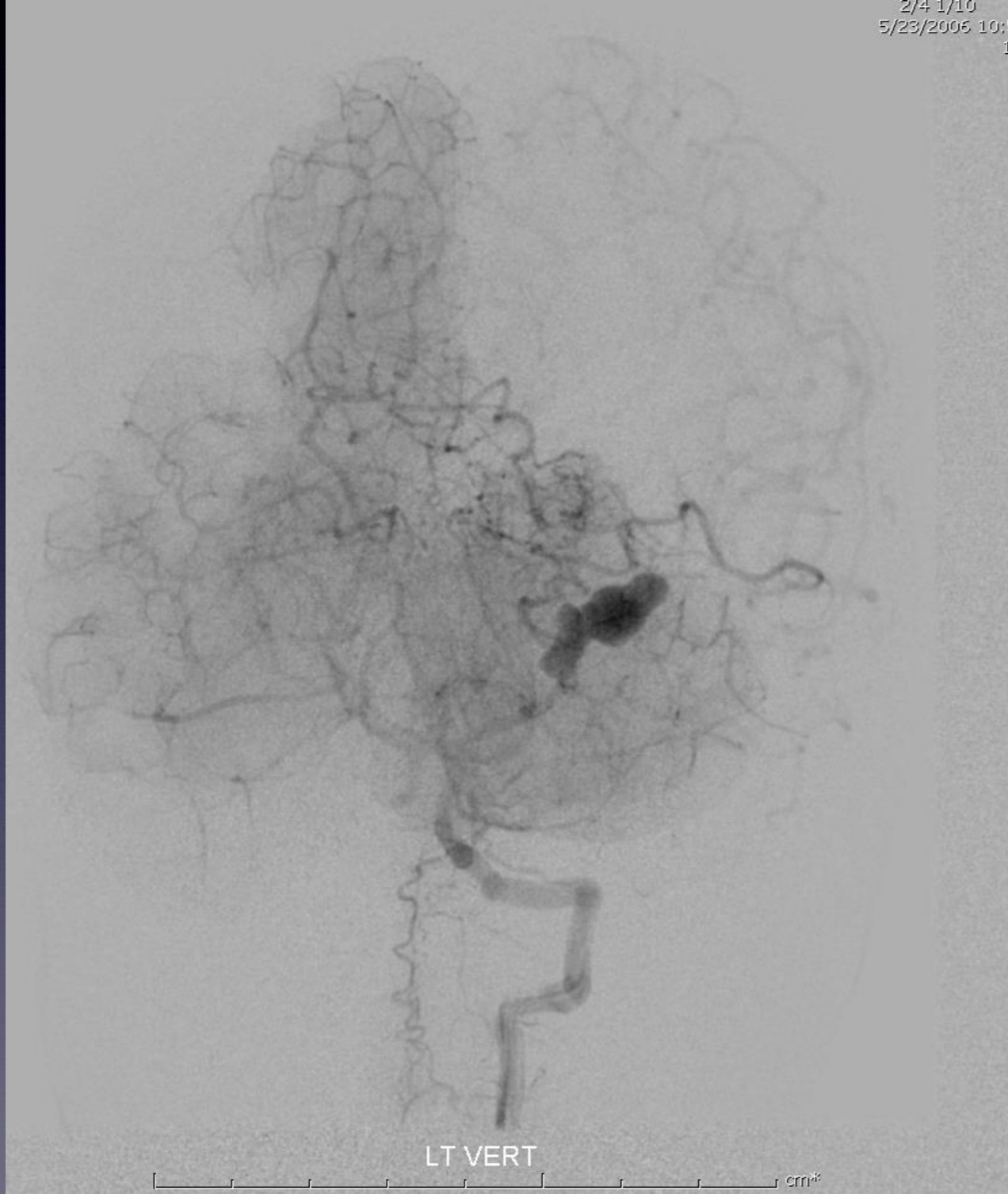
CHILDREN'S HOSPITAL BOSTON  
SPECIAL PROCEDURE TEMP CODE  
RICA\_1  
5/23/2006 11:16:57 AM  
10158616  
IODINE

HFS

RICA Z: 1  
C: 1898  
W: 819

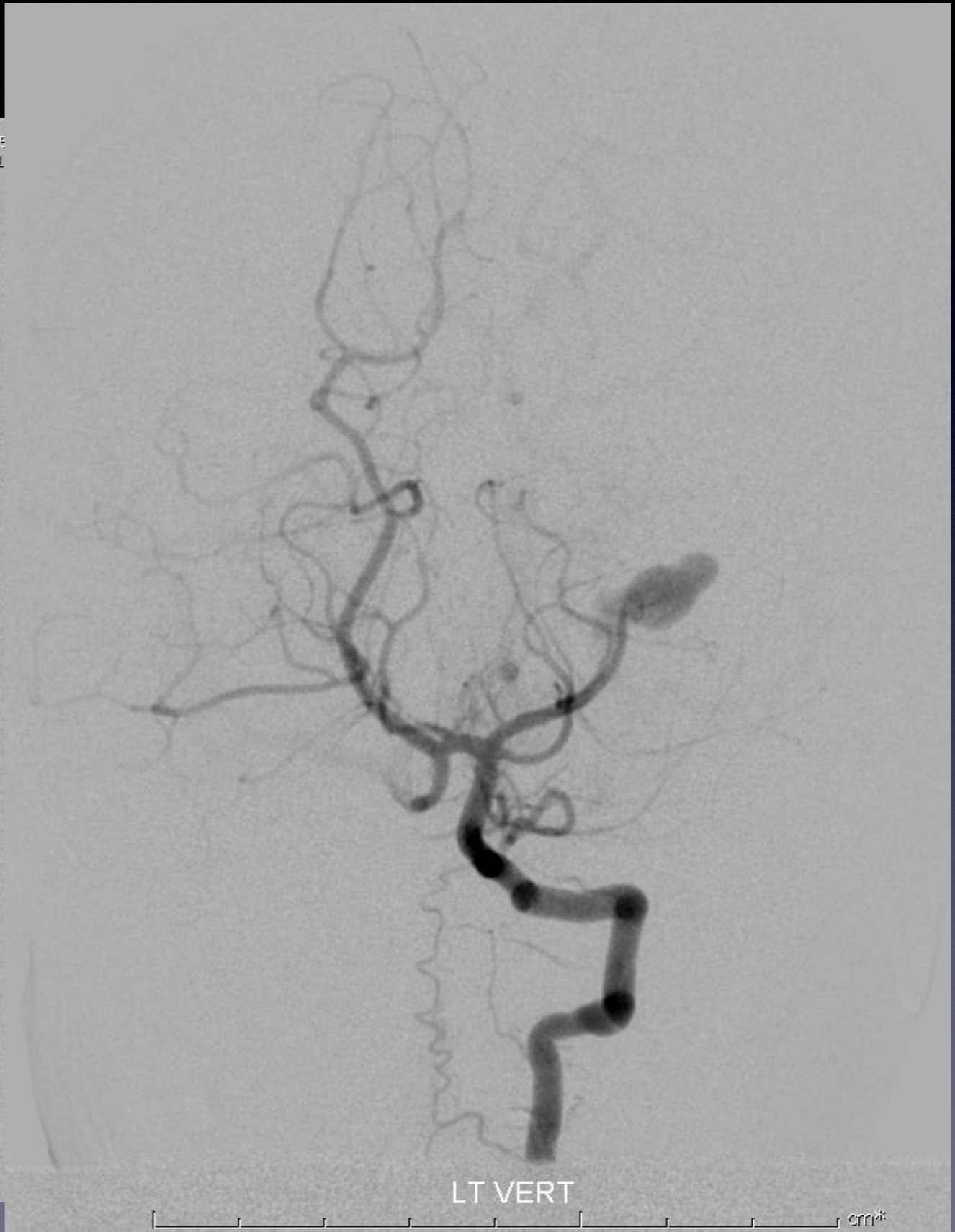cm\*

2/4 1/10  
5/23/2006 10:5  
1



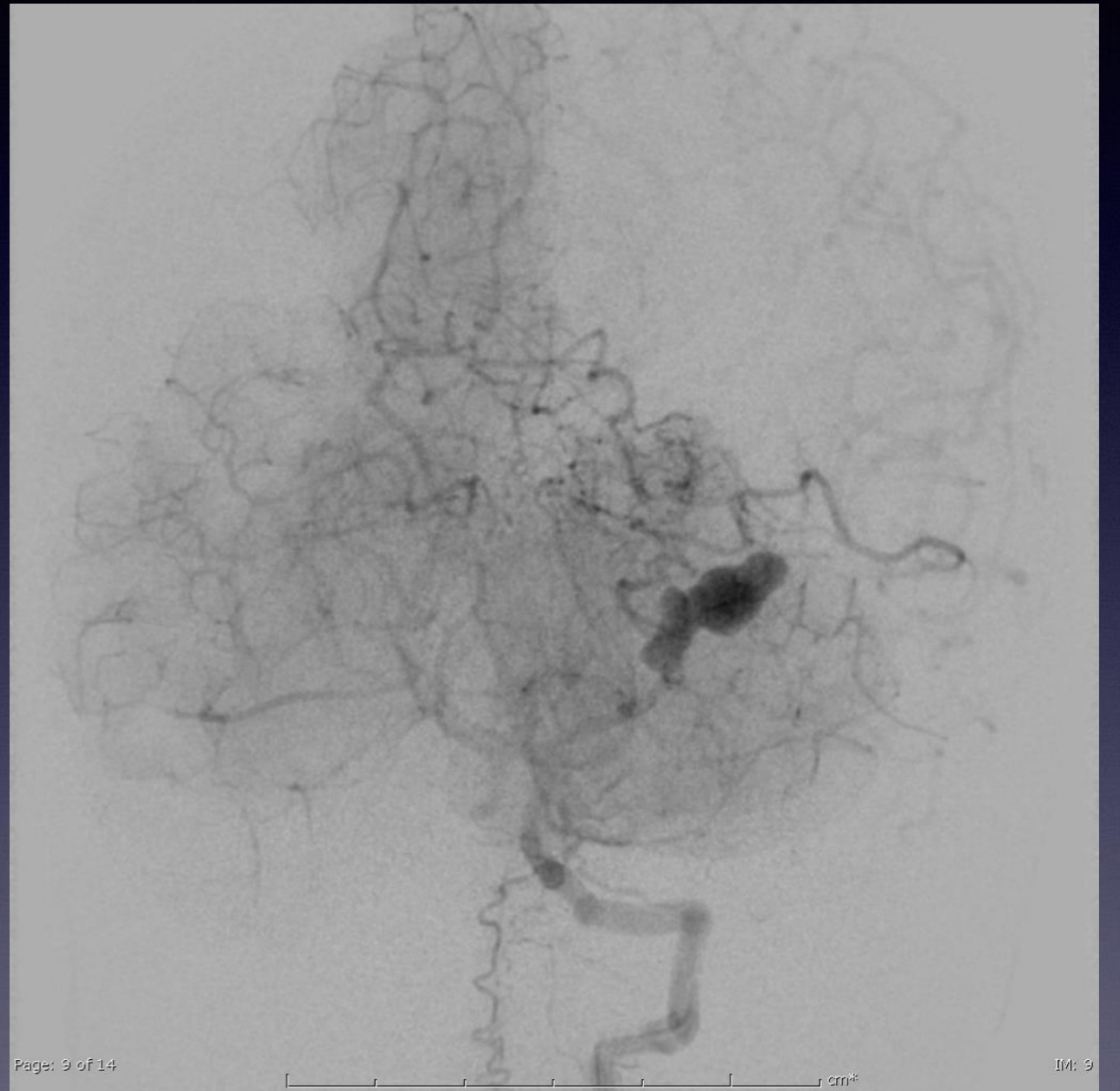
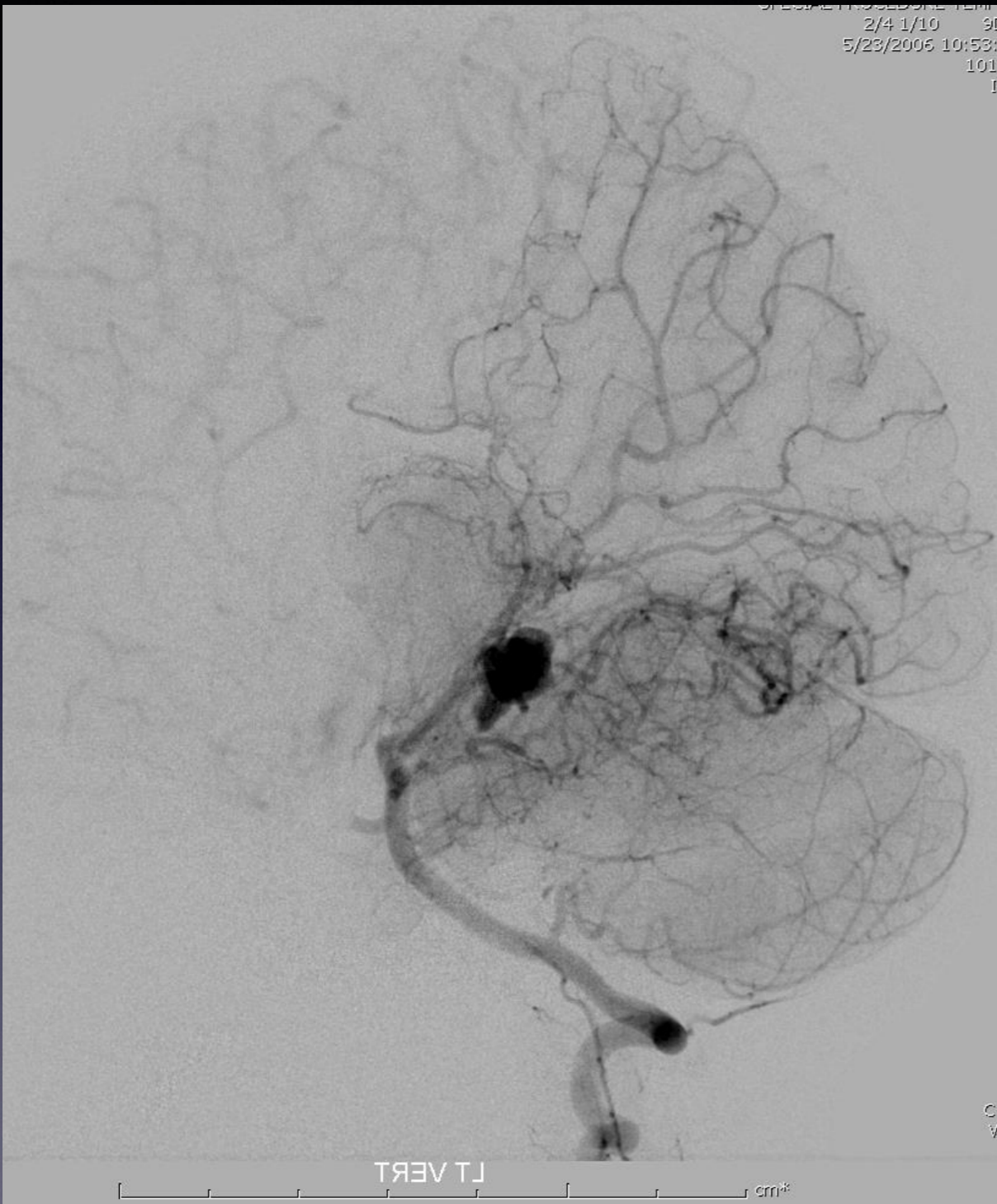
LT VERT

cm\*

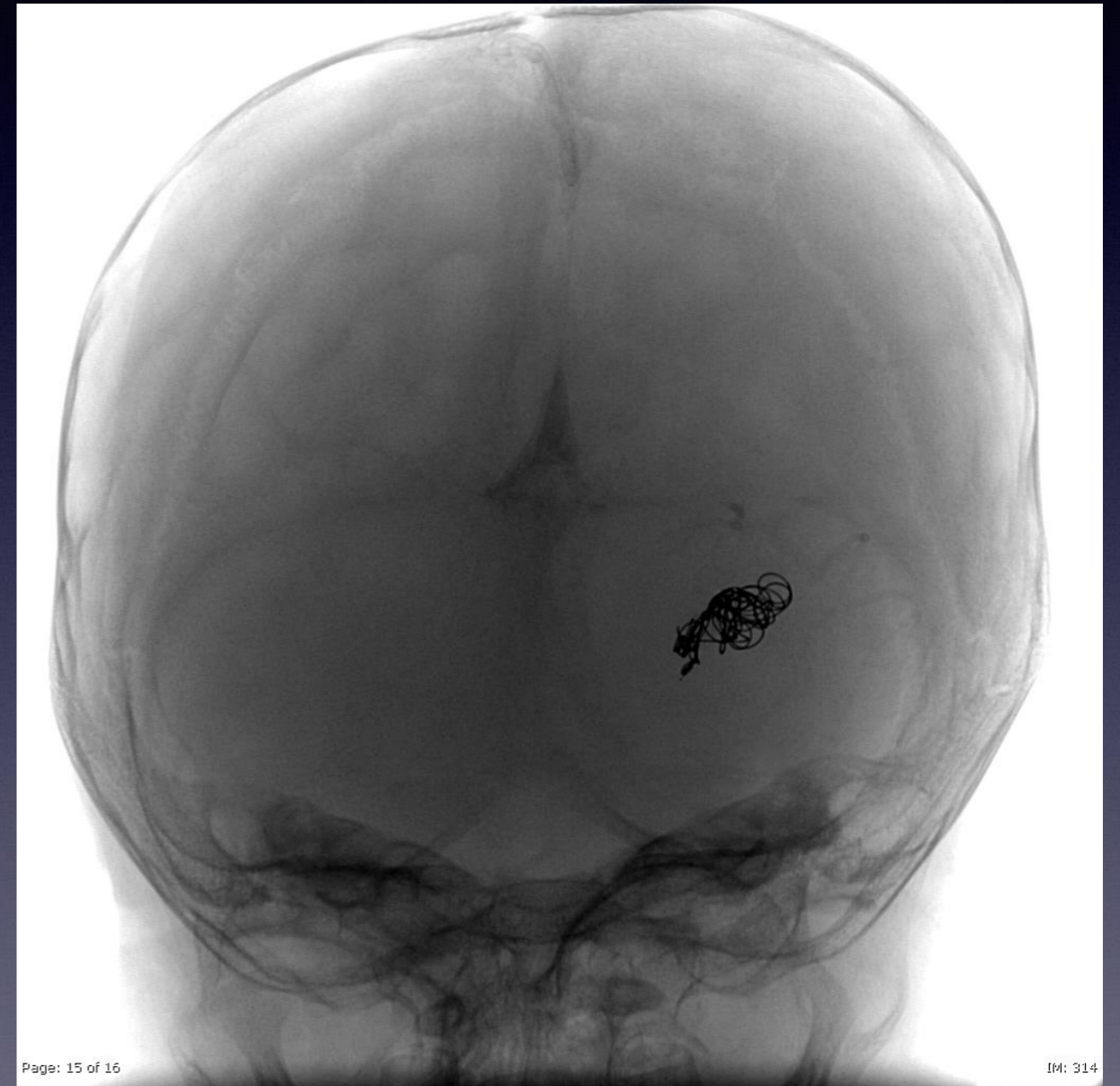
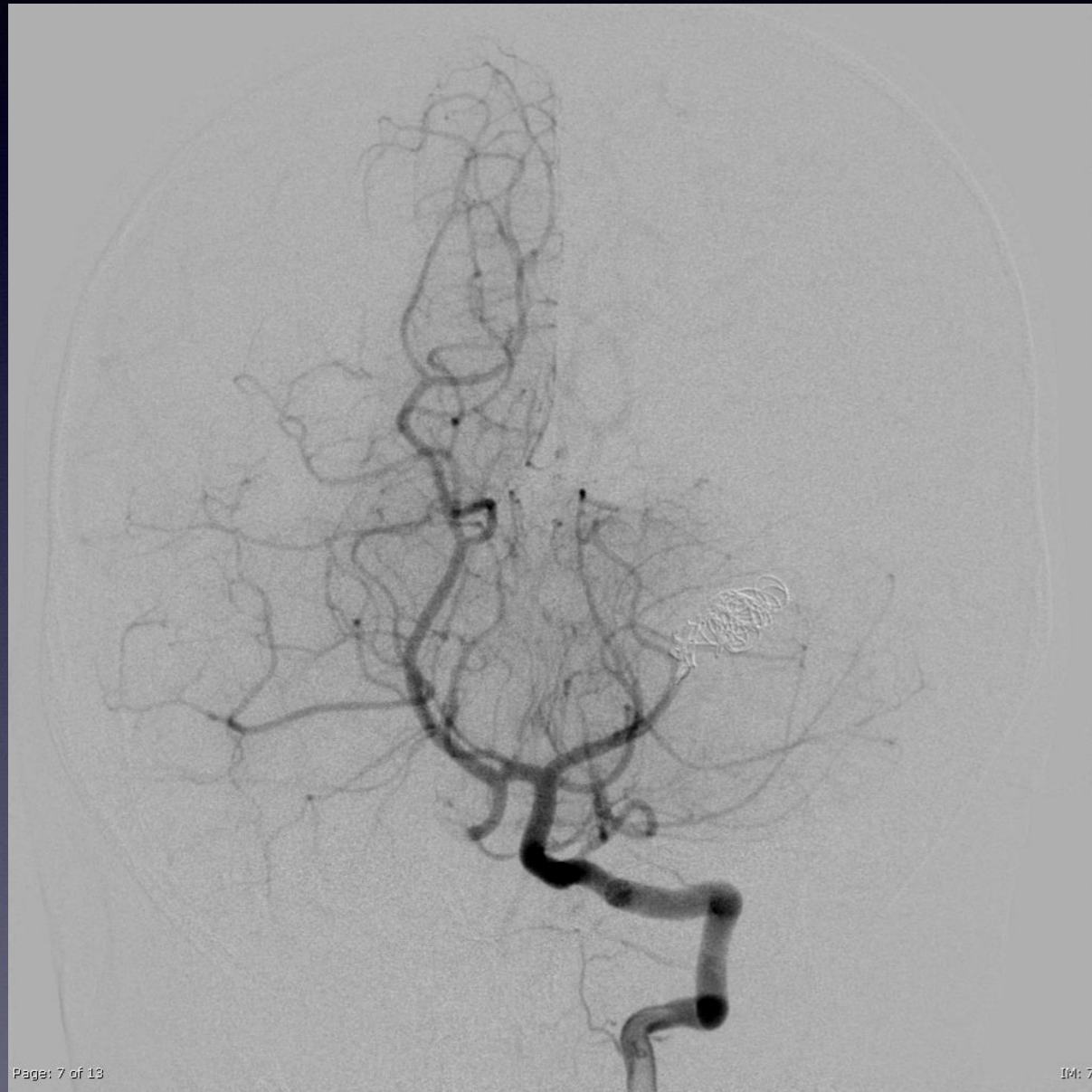


LT VERT

cm\*

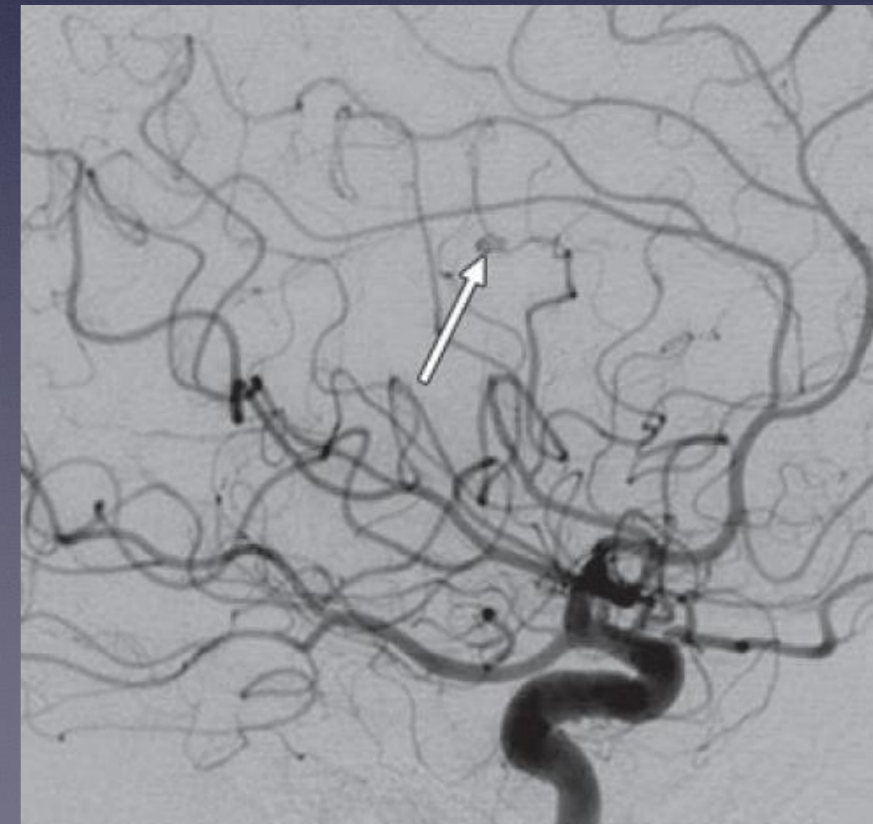


# Post coiling

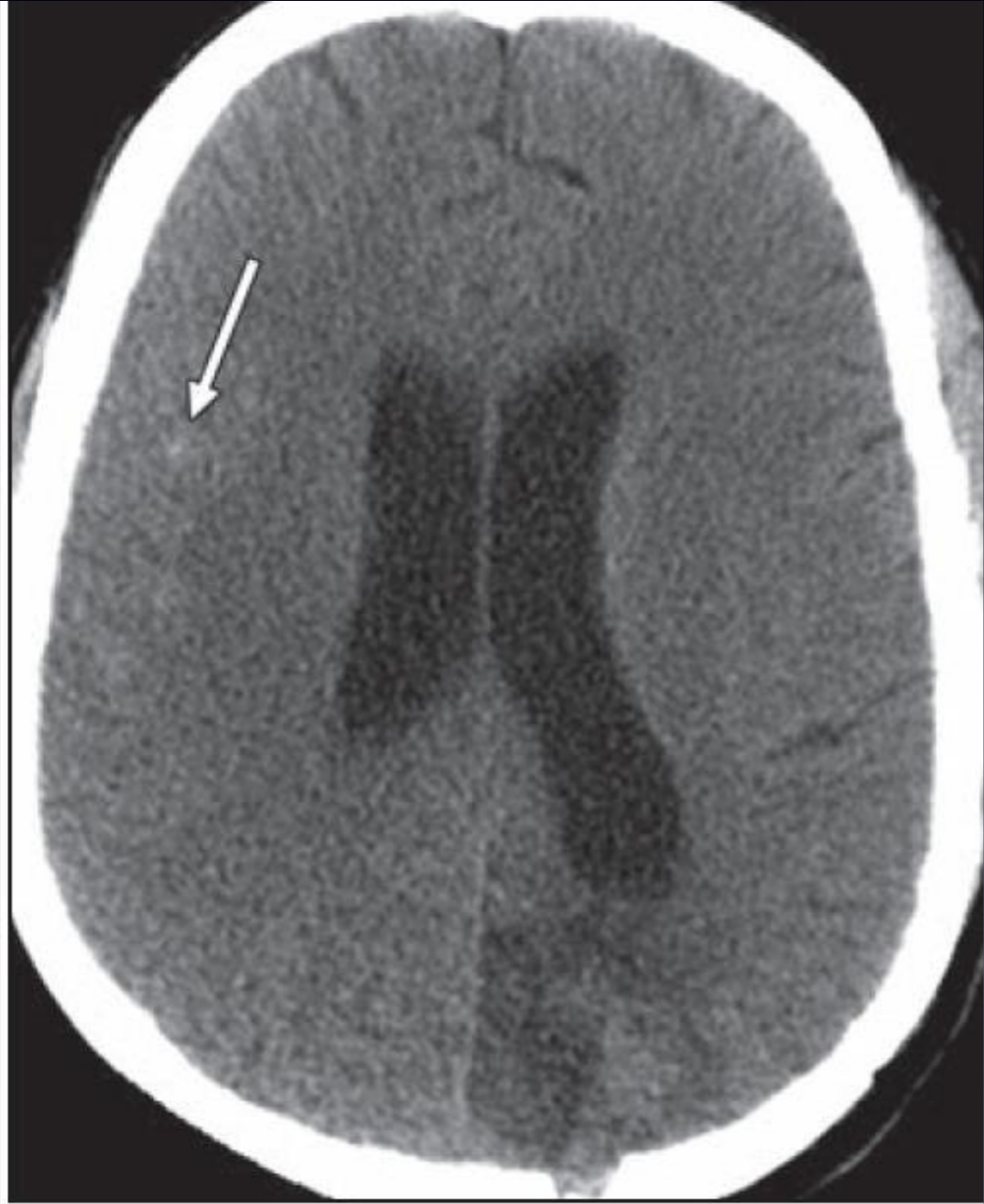

# Septic (Mycotic) aneurysm

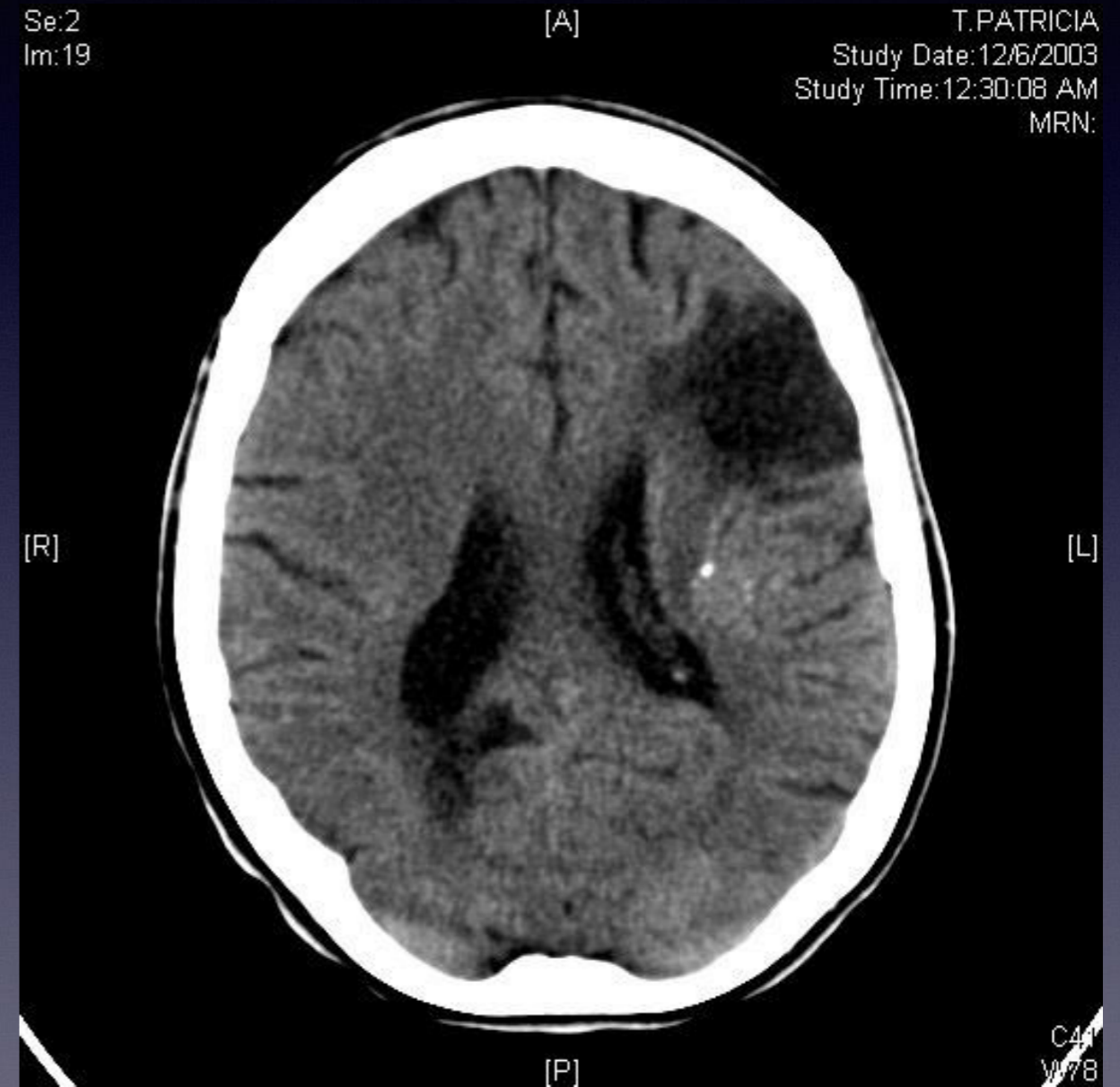
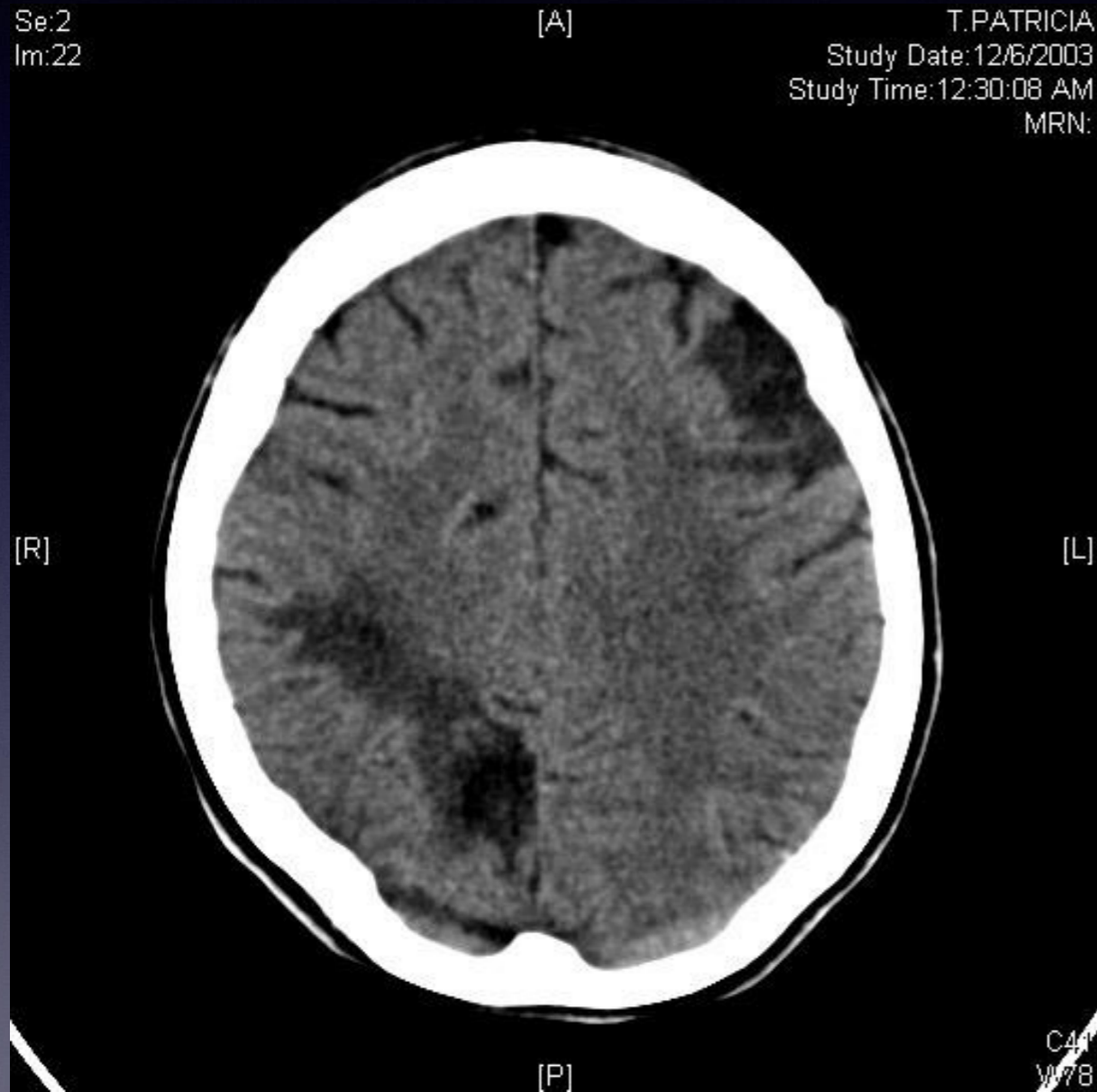
- 2% των ανευρυσμάτων
- Ενδοκαρδίτιδα (5%)
- Μηνιγγίτιδα
- Κυτταρίτιδα οφθαλμικού κόγχου
- Λοίμωξη σηραγγώδους κόλπου







# Endocarditis

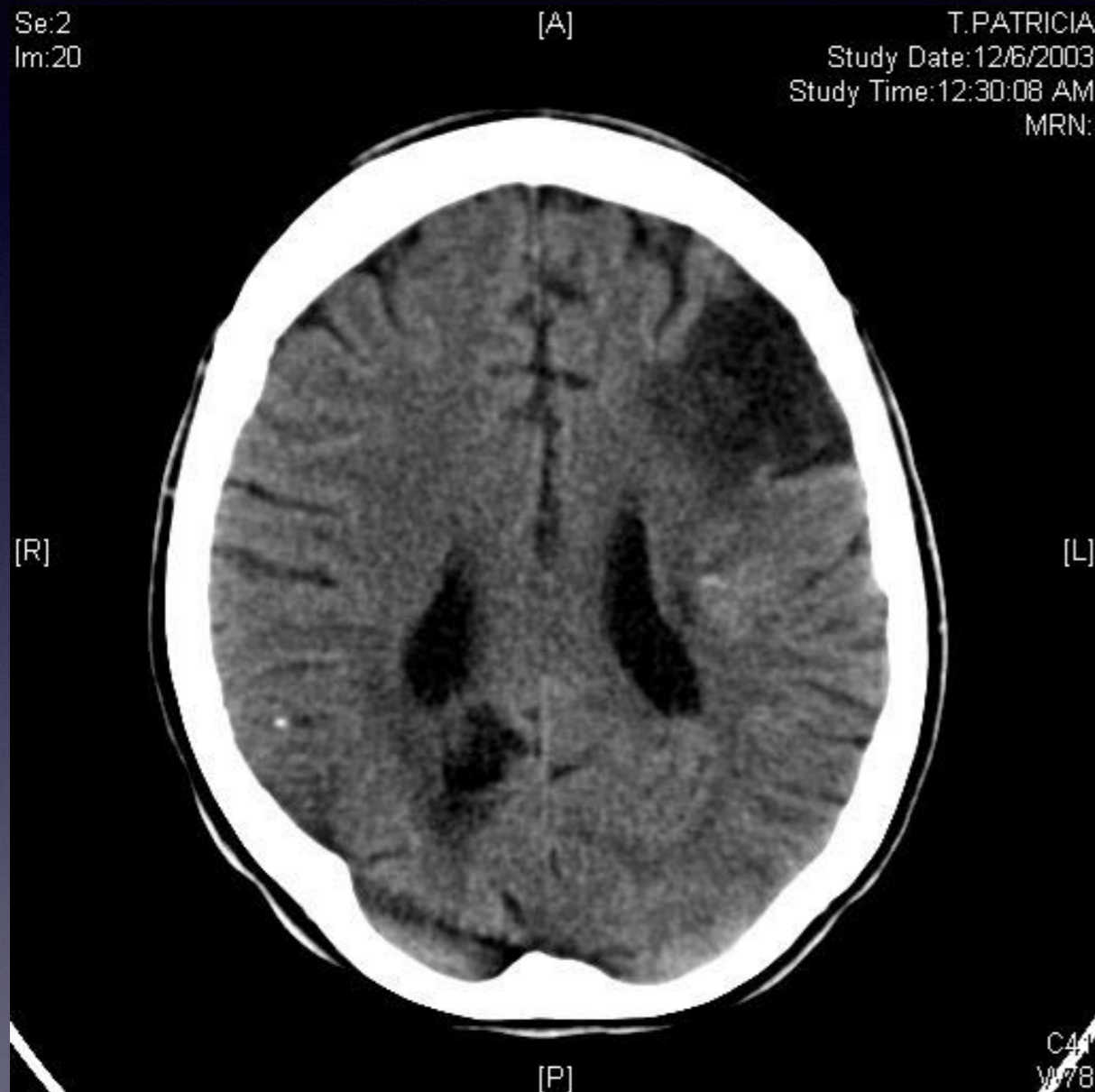

Se:2  
Im:20

[A]

T.PATRICIA  
Study Date:12/6/2003  
Study Time:12:30:08 AM  
MRN:

[R]



[P]

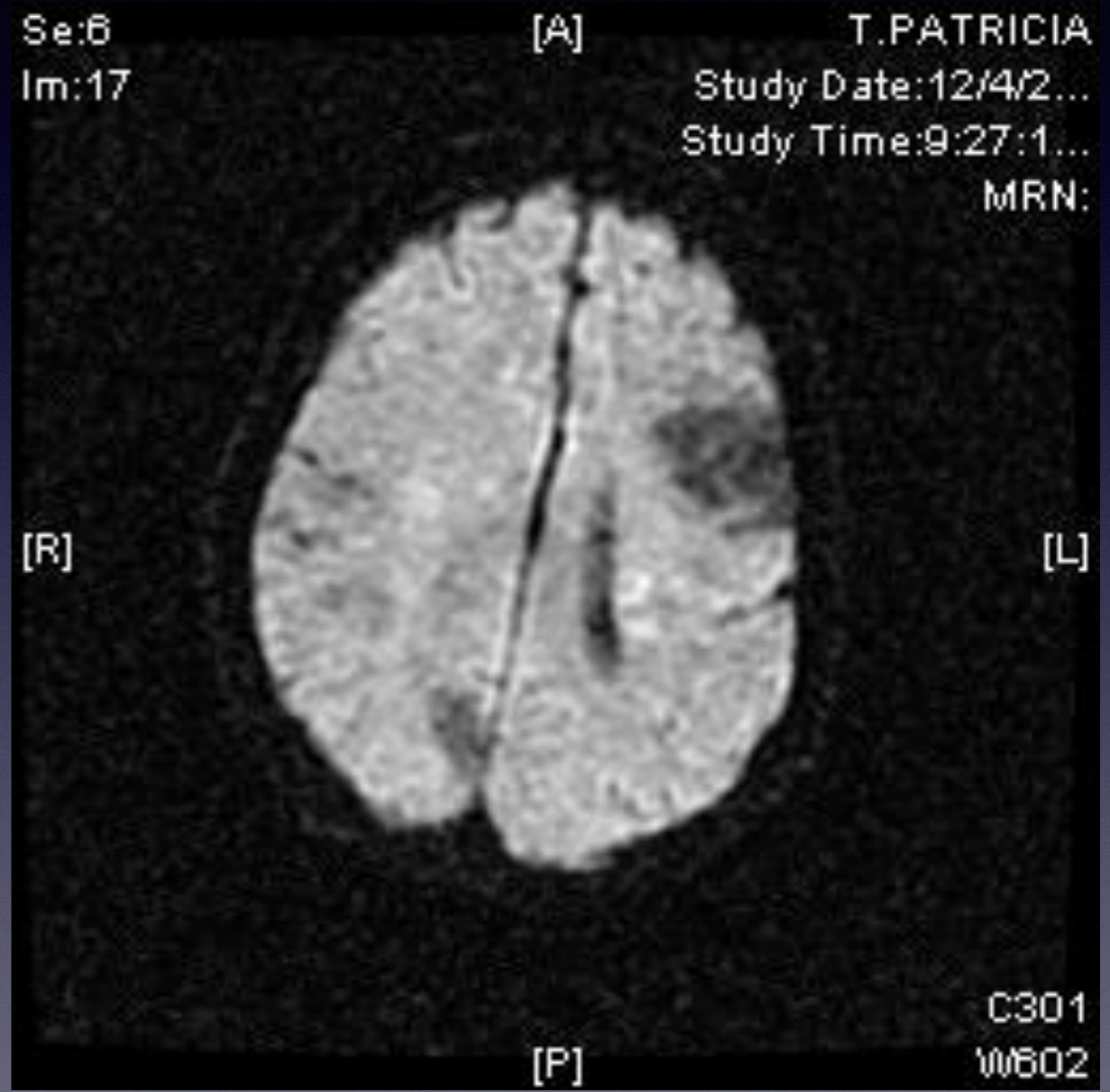
C41  
W78

Se:6  
Im:17

[A]

T.PATRICIA  
Study Date:12/4/2...  
Study Time:9:27:1...  
MRN:

[R]



[P]

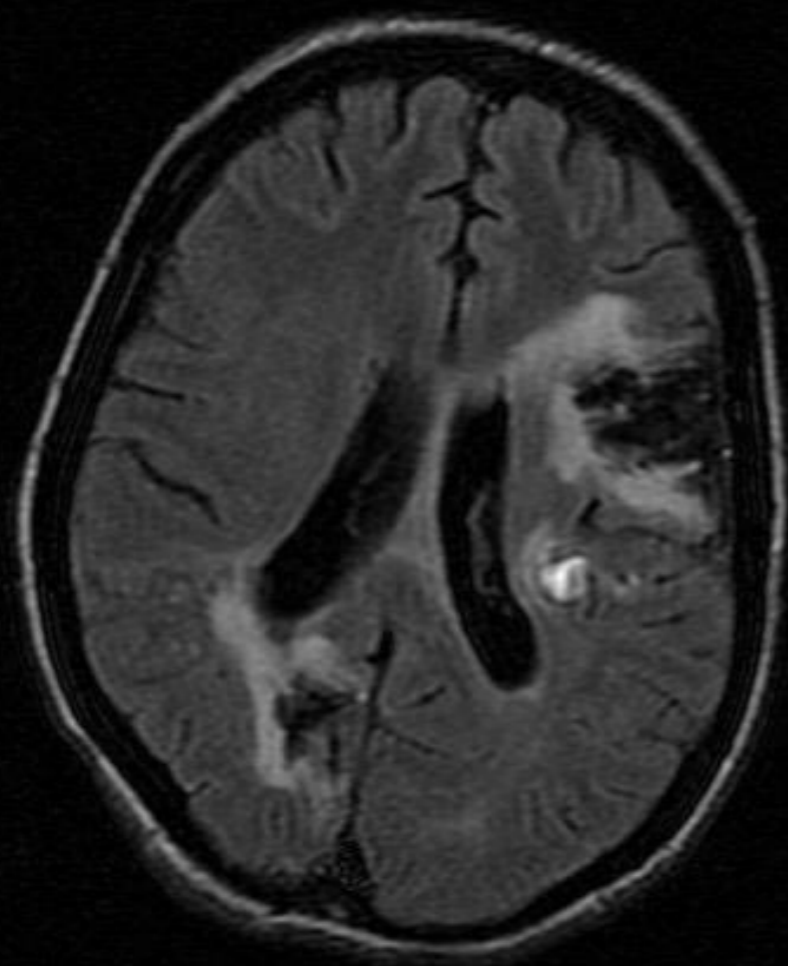
C301  
W602

Se:5  
Im:15

[A]

T.PATRICIA  
Study Date:12/4/2003  
Study Time:9:27:18 PM  
MRN:

[R]



[L]

[P]

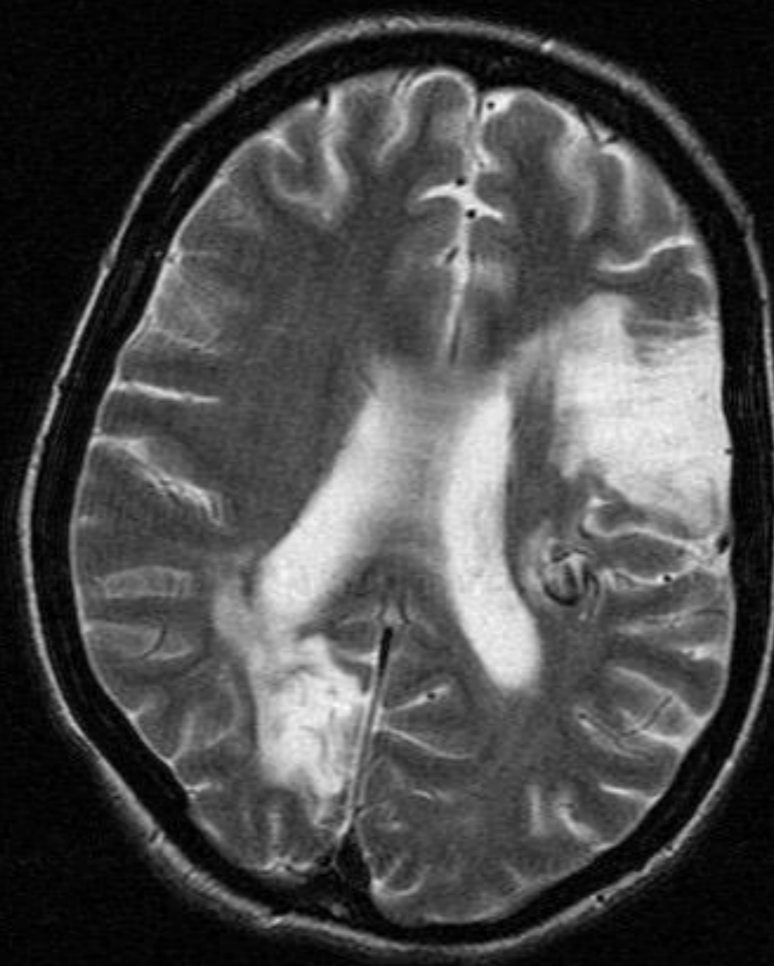C435  
W870

Se:3  
Im:15

[A]

T.PATRICIA  
Study Date:12/4/2003  
Study Time:9:27:18 PM  
MRN:

[R]



[L]

[P]

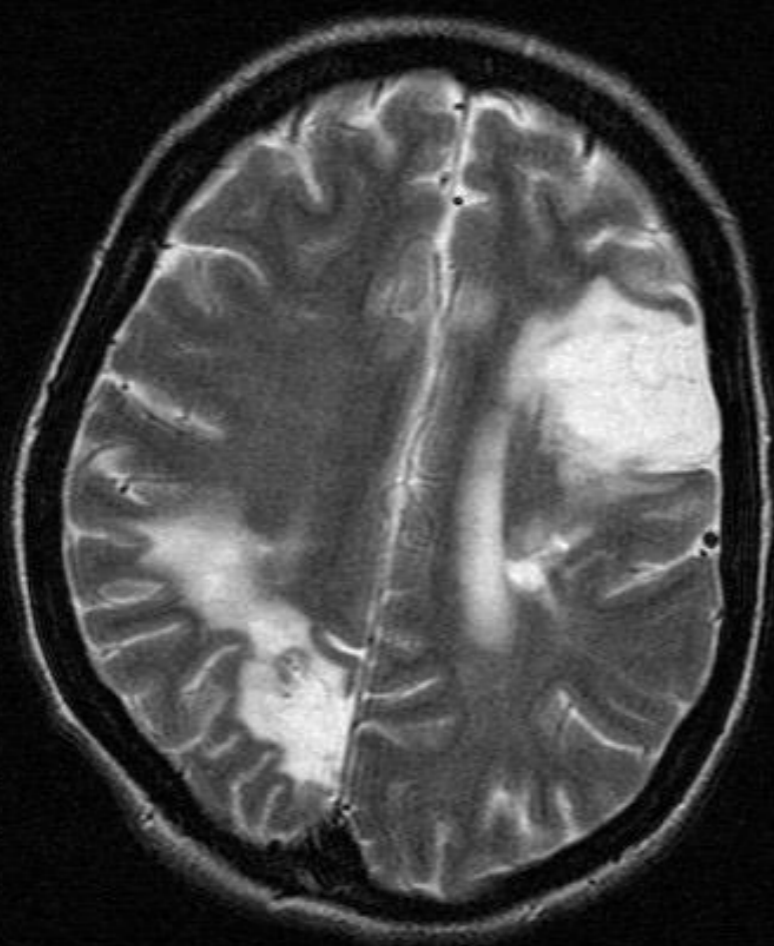
C491  
W982

Se:3  
Im:16

[A]

T.PATRICIA  
Study Date:12/4/2003  
Study Time:9:27:18 PM  
MRN:

[R]



[L]

[P]

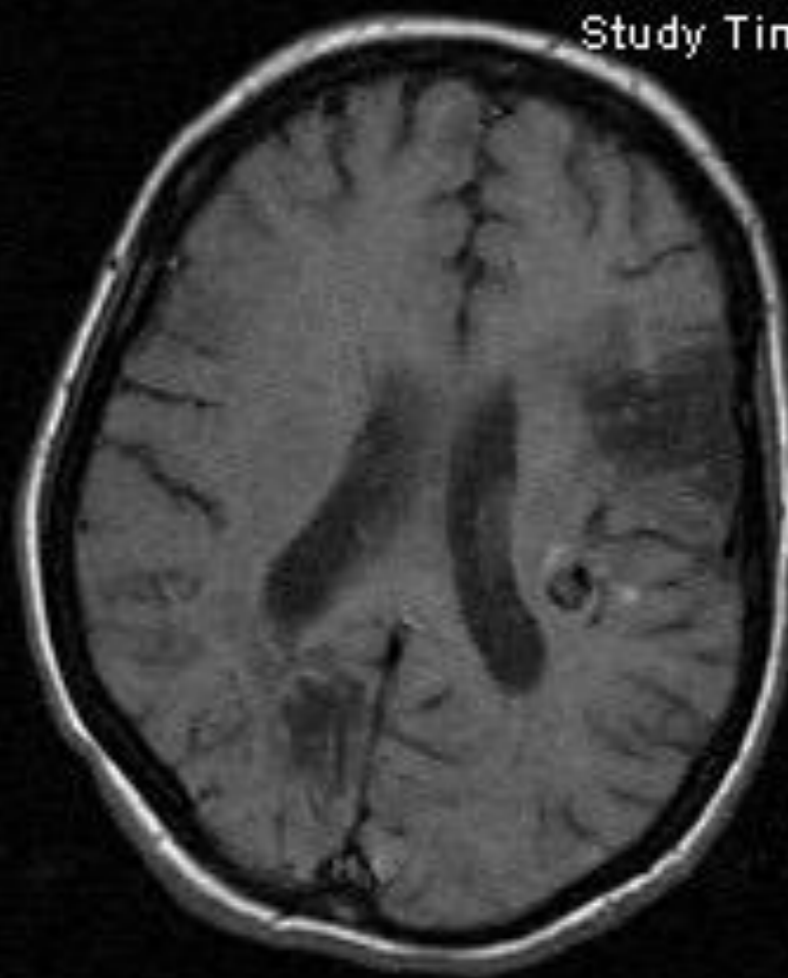
C484  
W969

Se:7  
Im:15

[A]

T.PATRICIA  
Study Date:12/4/2...  
Study Time:9:27:1...  
MRN:

[R]



[L]

[P]

C391  
W783

Se:8  
Im:15

[A]

T.PATRICIA

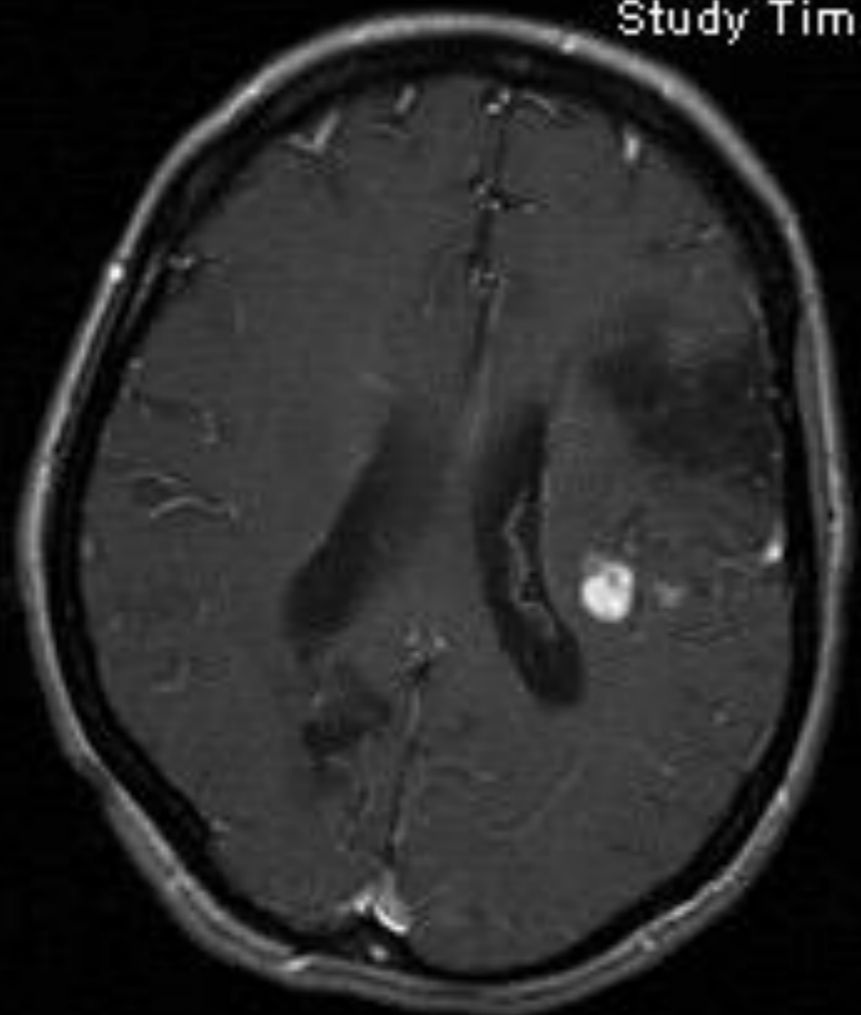
Study Date:12/4/2...

Study Time:9:27:1...

MRN:

[R]

[L]



C710

W1420

15 GAD

[P]

Se:8  
Im:16

[A]

T.PATRICIA

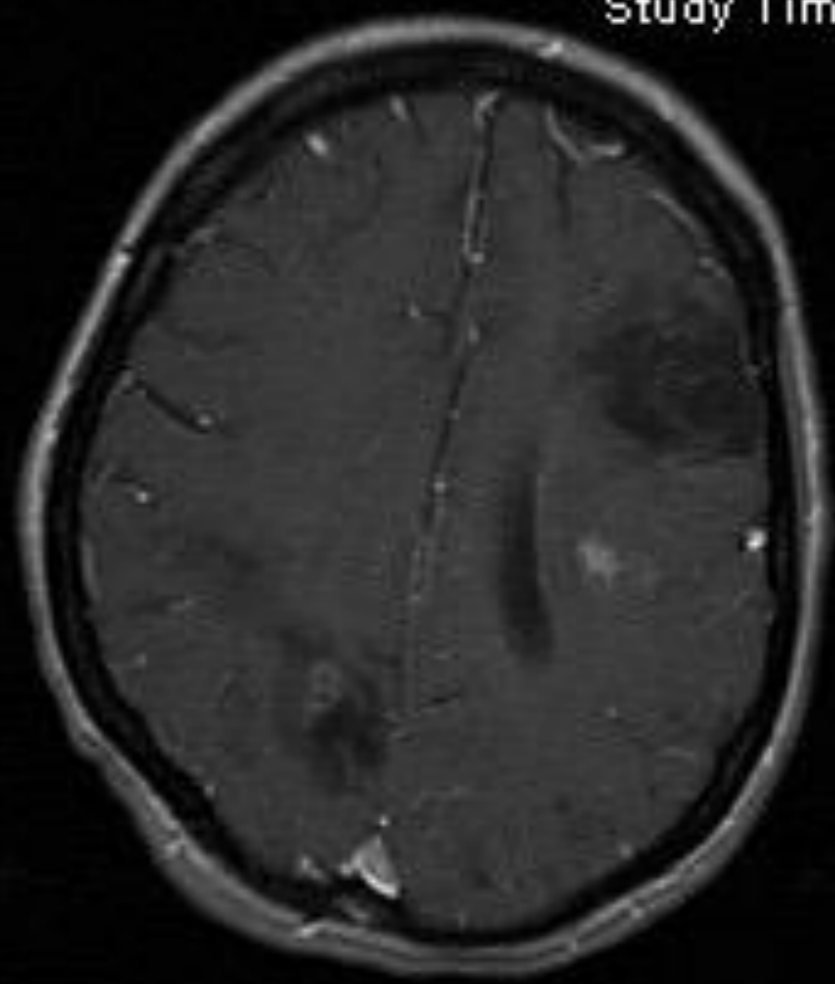
Study Date:12/4/2...

Study Time:9:27:1...

MRN:

[R]

[L]



C755

W1511

15 GAD

[P]

Se:1  
Im:6

[H]

T.PATRICIA

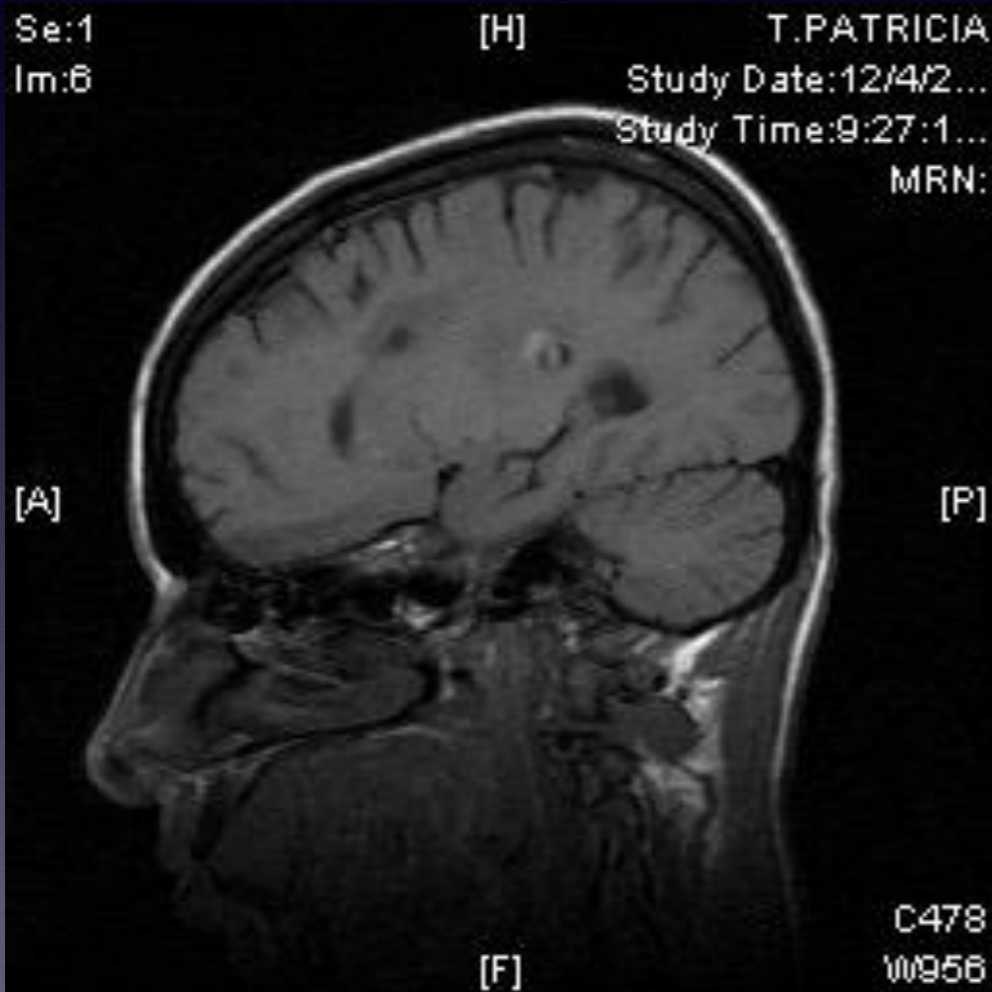
Study Date:12/4/2...

Study Time:9:27:1...

MRN:

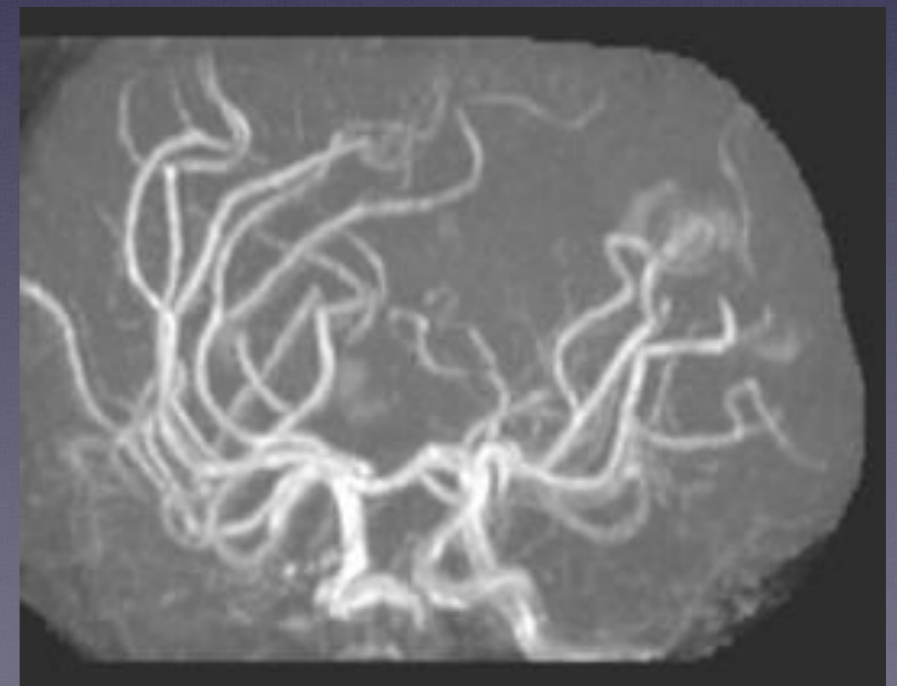
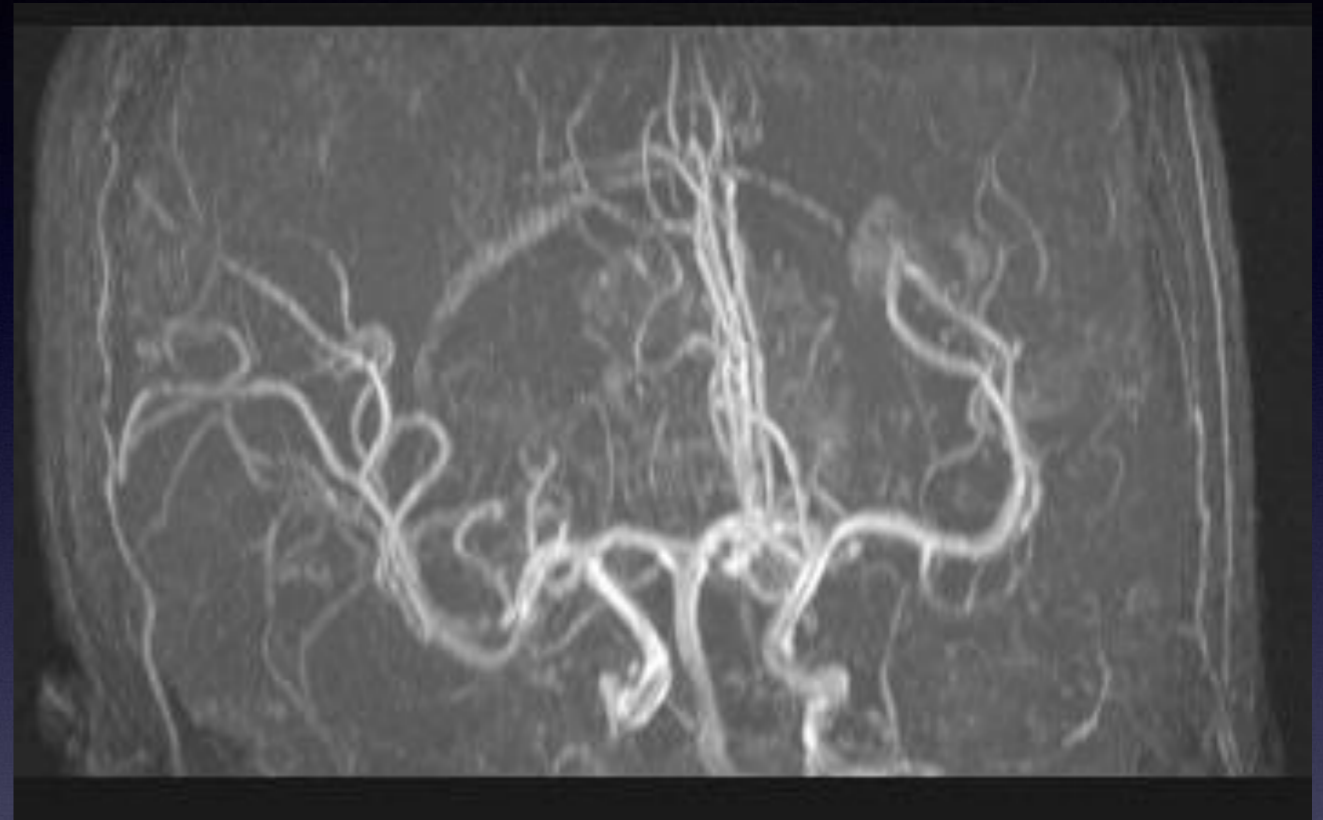[A]

[P]



[F]

C478  
W956

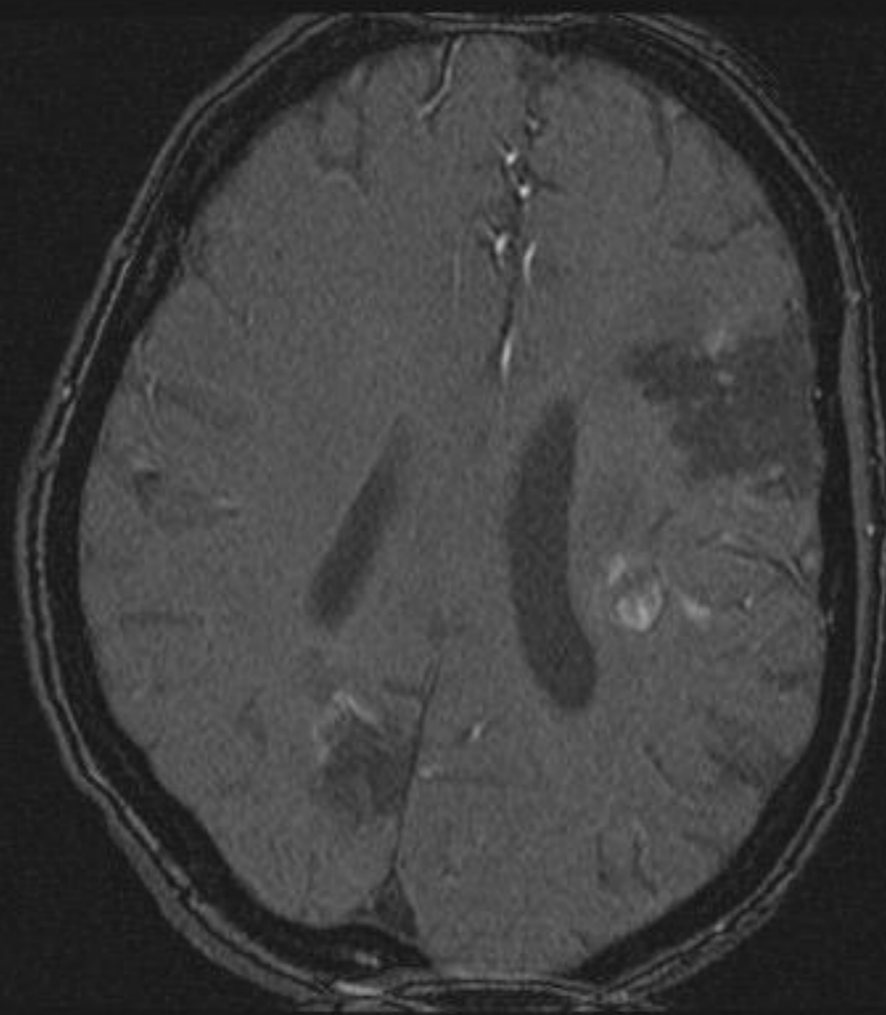


Se:2  
Im:104

[A]

T. PATRICIA  
Study Date:12/4/2003  
Study Time:9:27:18 PM  
MRN:

[R]

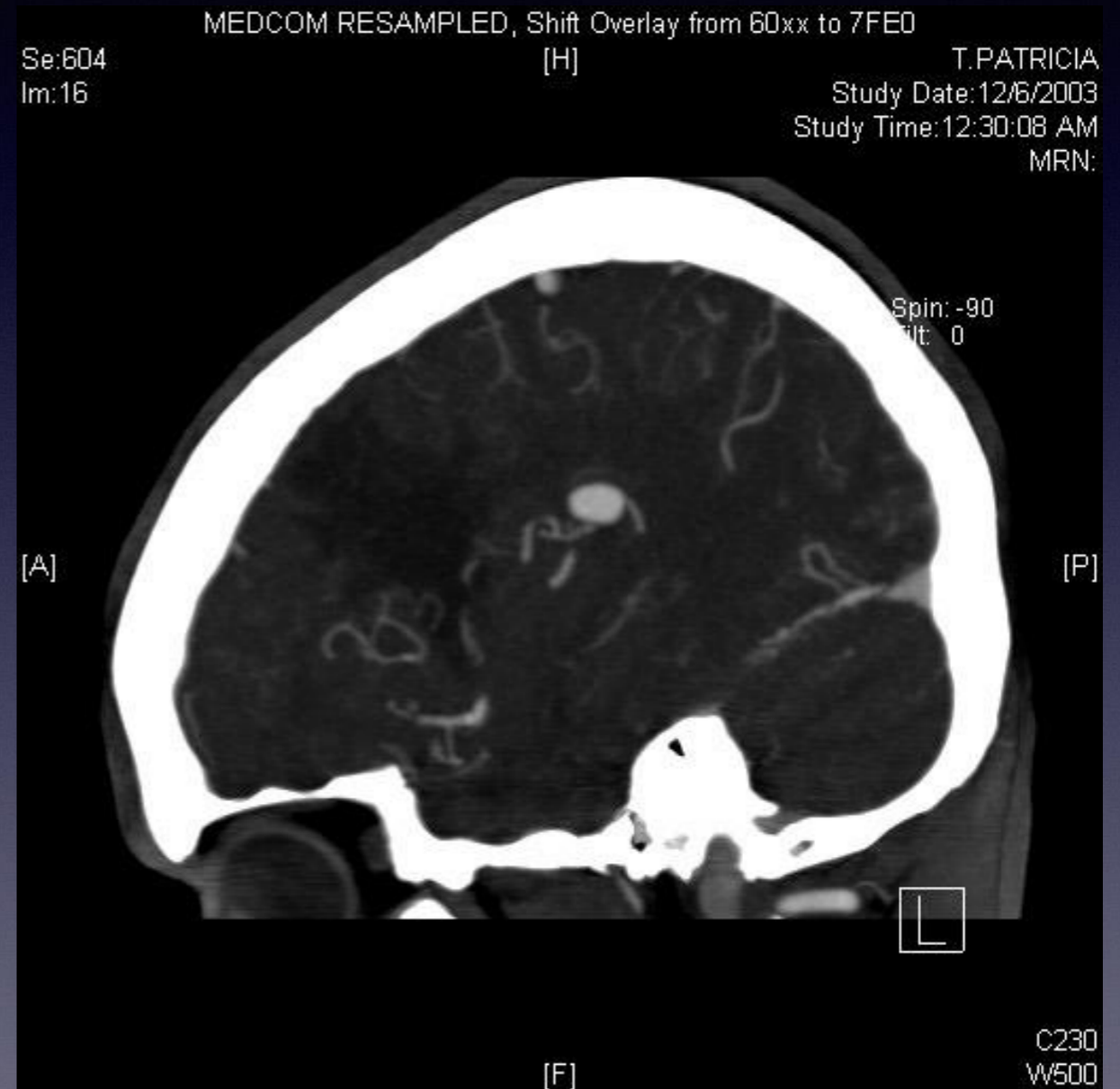
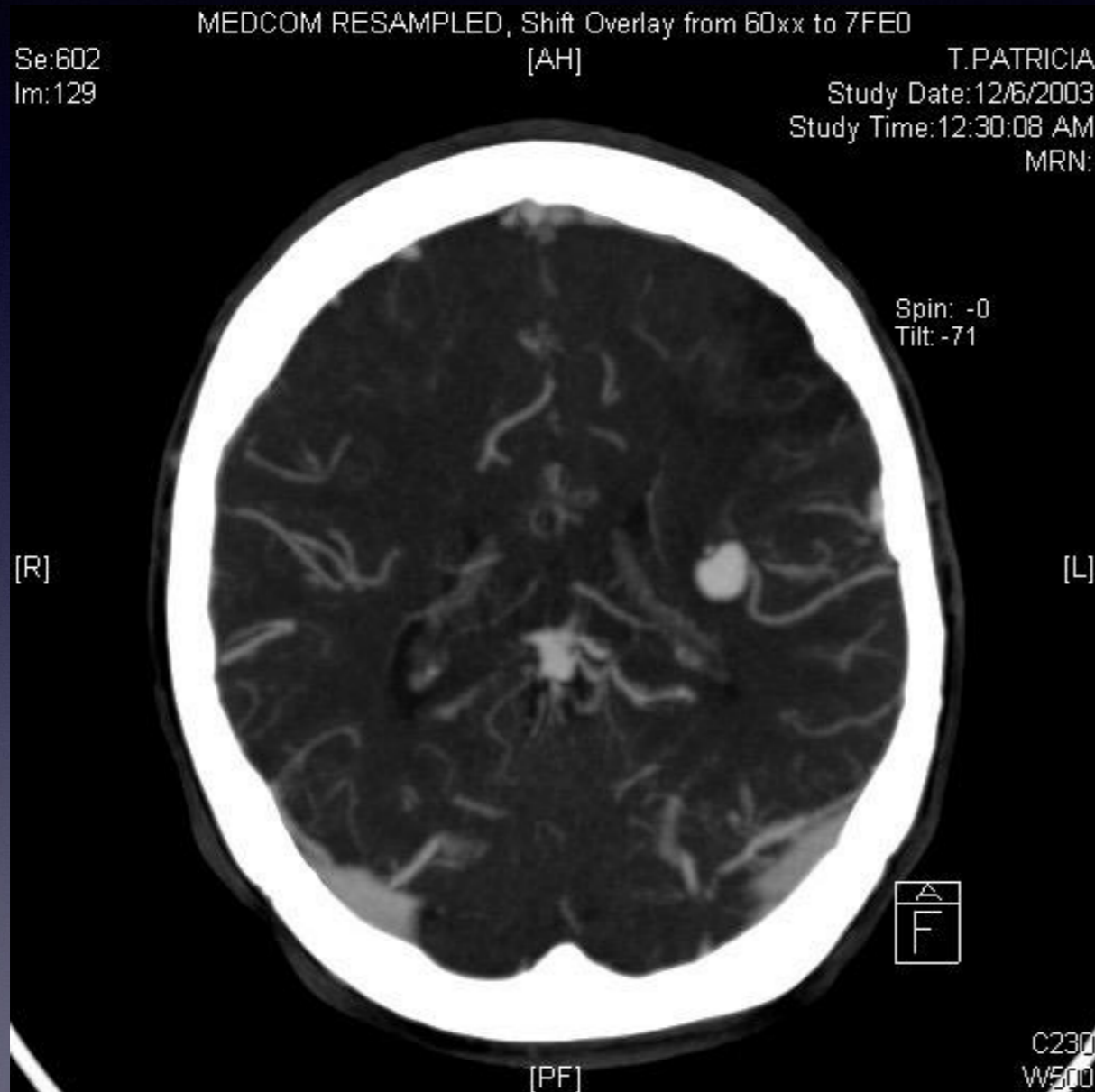


[L]

[P]

C218  
W546





# Μαγνητική τομογραφία

- Αρνητική ψηφιακή αγγειογραφία > Ανίχνευση θρομβωμένου ανεύρυσματος, άλλης αιτίας αιμορραγίας
- Αυχενική μοίρα ΣΣ > όγκος, ΑΦΔ

Neuro  
Ex: 28012005174021

Se: 1/8  
Im: 12/158

BETH ISRAEL DEACONESS HO  
BENNETT  
F  
Acc:  
200  
Stdy Tm: 17:4

W:255 L:127

1.5T mr4  
Ex: 1  
ROUTINE\_HEAD/T1W\_SAG  
Se: 2/16  
Im: 14/18  
Seq: R1.6 (000)

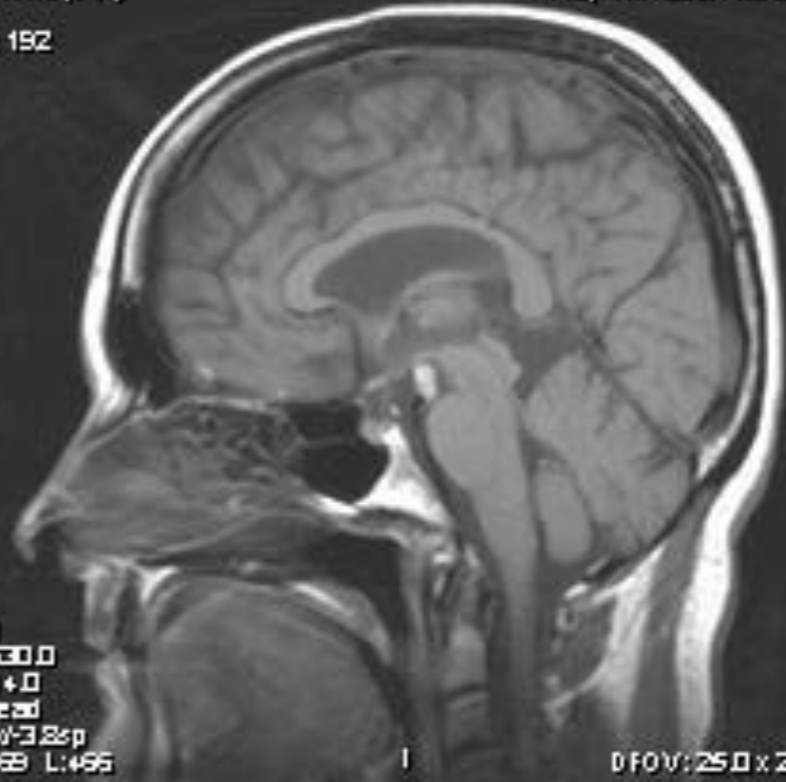S

BIDMC #4  
BENNETT/EILEEN  
047Y F 2081296  
Acc: 3635743  
2005 Jan 29  
Acq Tm: 09:57:09.040000

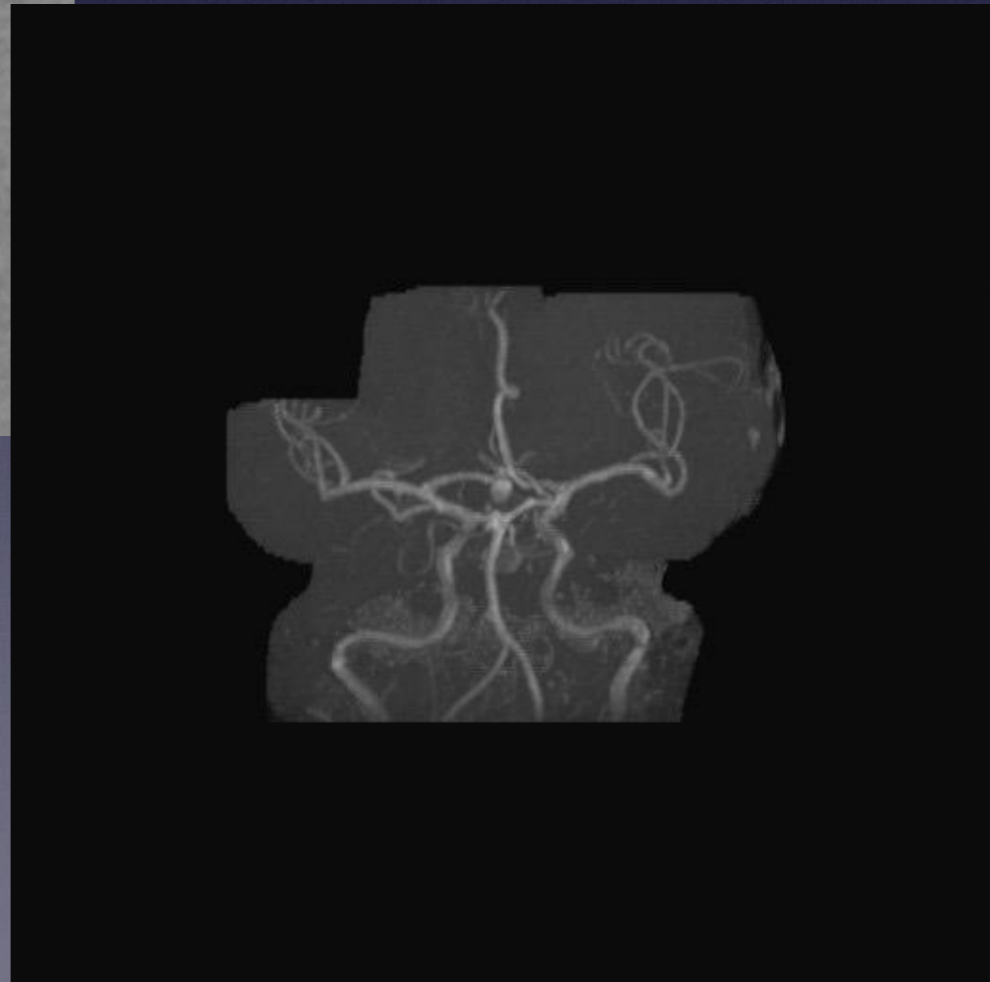512 x 192

A

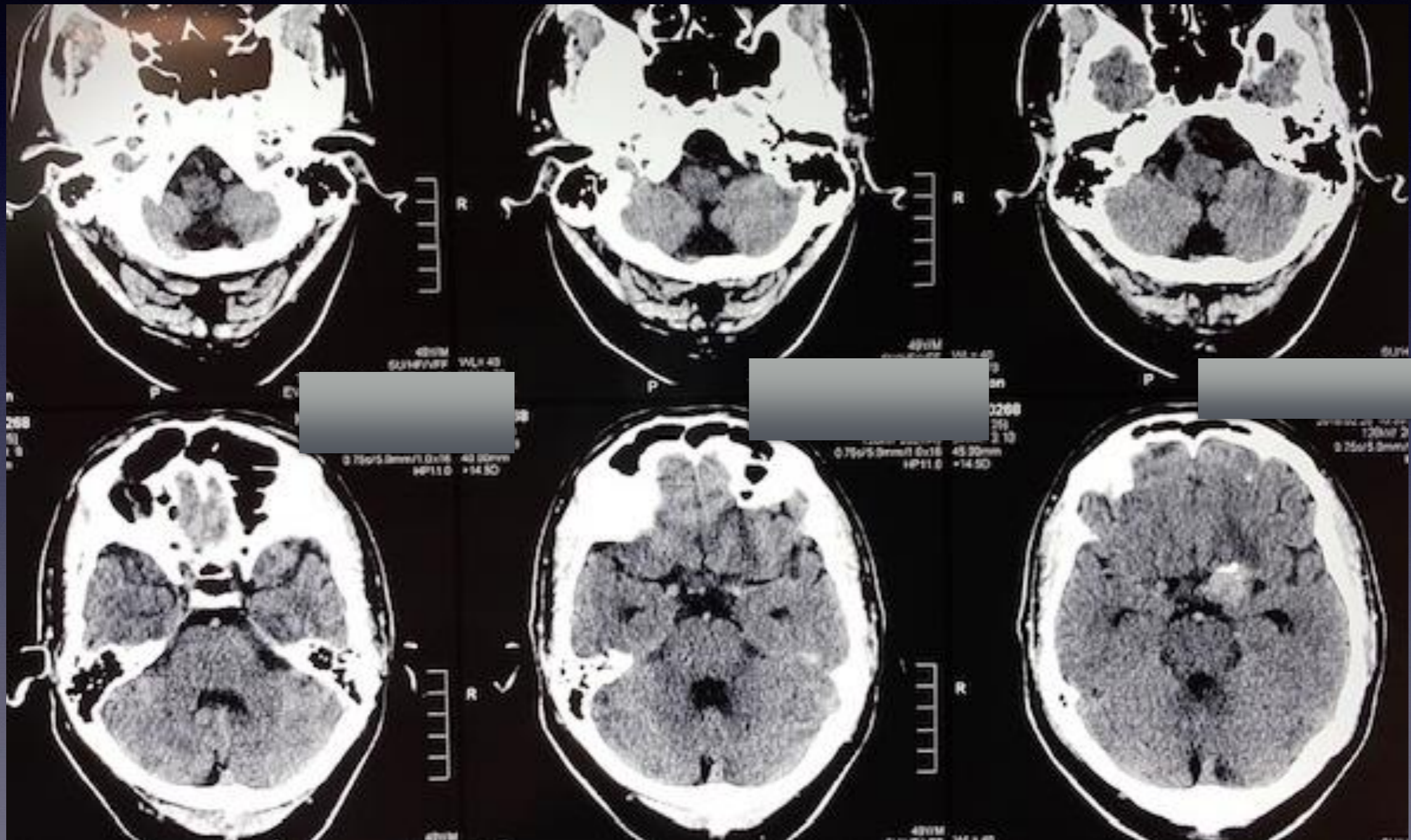
ET: 1  
TR: 630.0  
TE: 14.0  
CP Head  
5.0FW-3.8sp  
W:1468 L:466

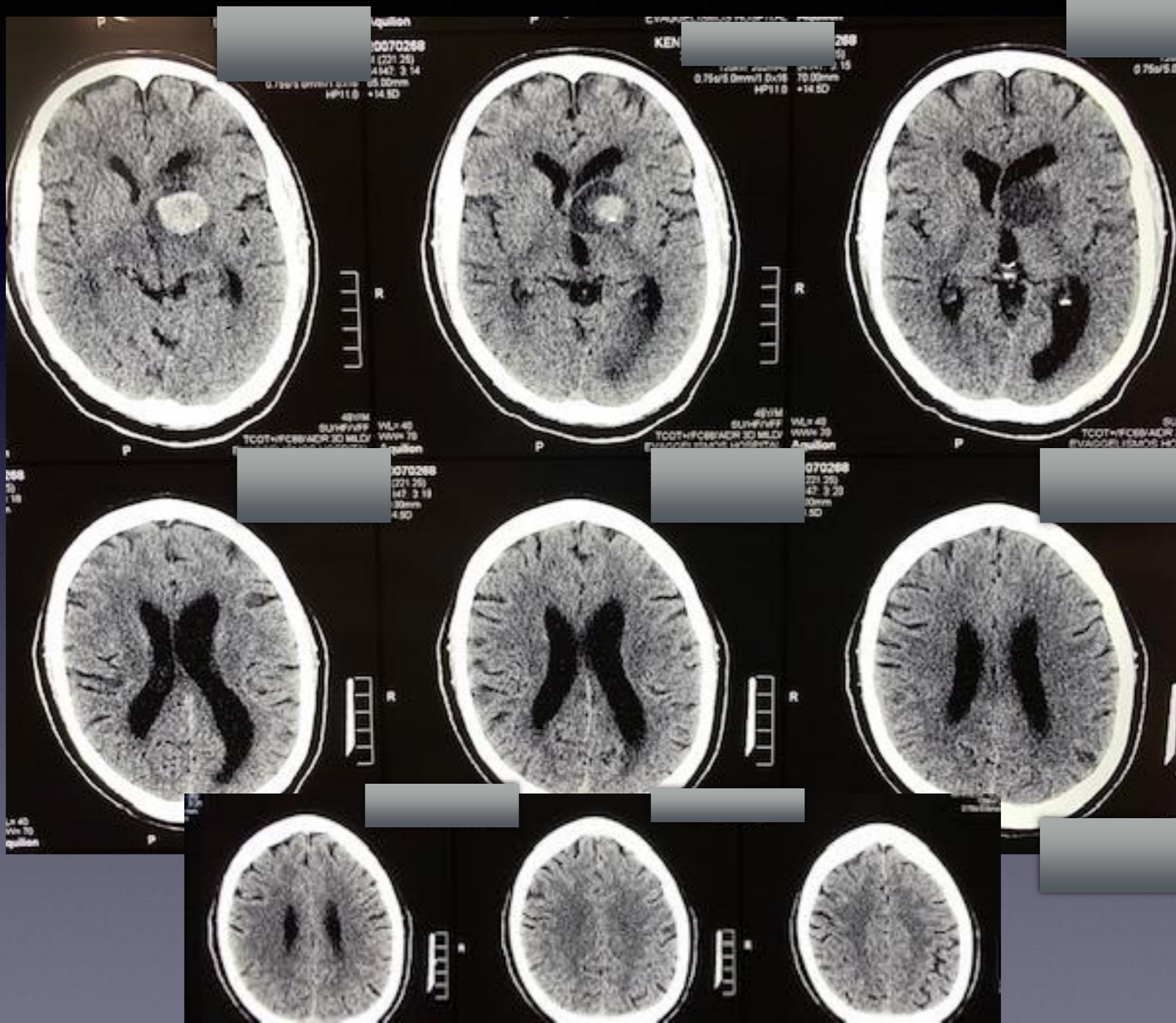


DFOV: 25.0 x 25.0cm

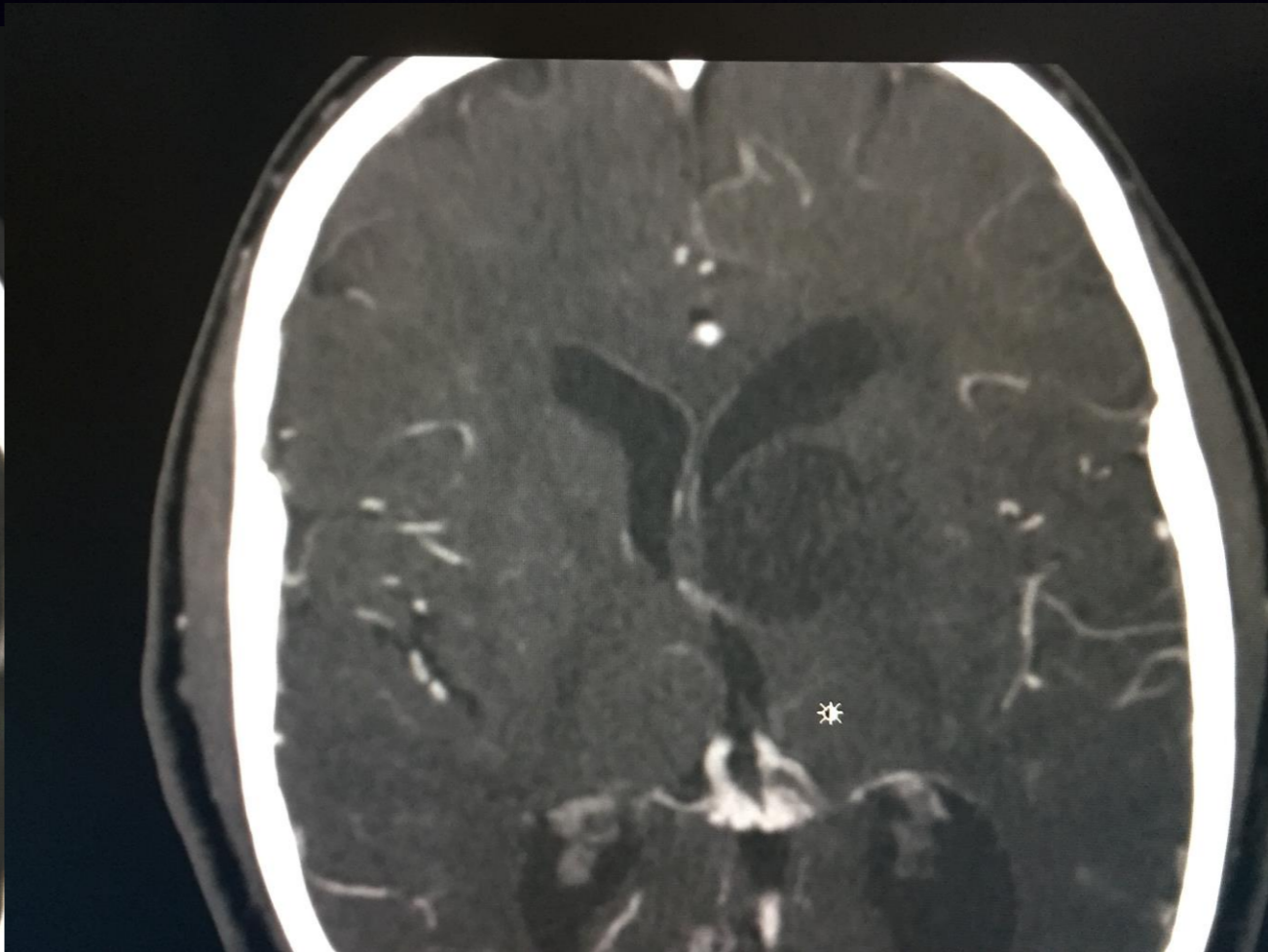
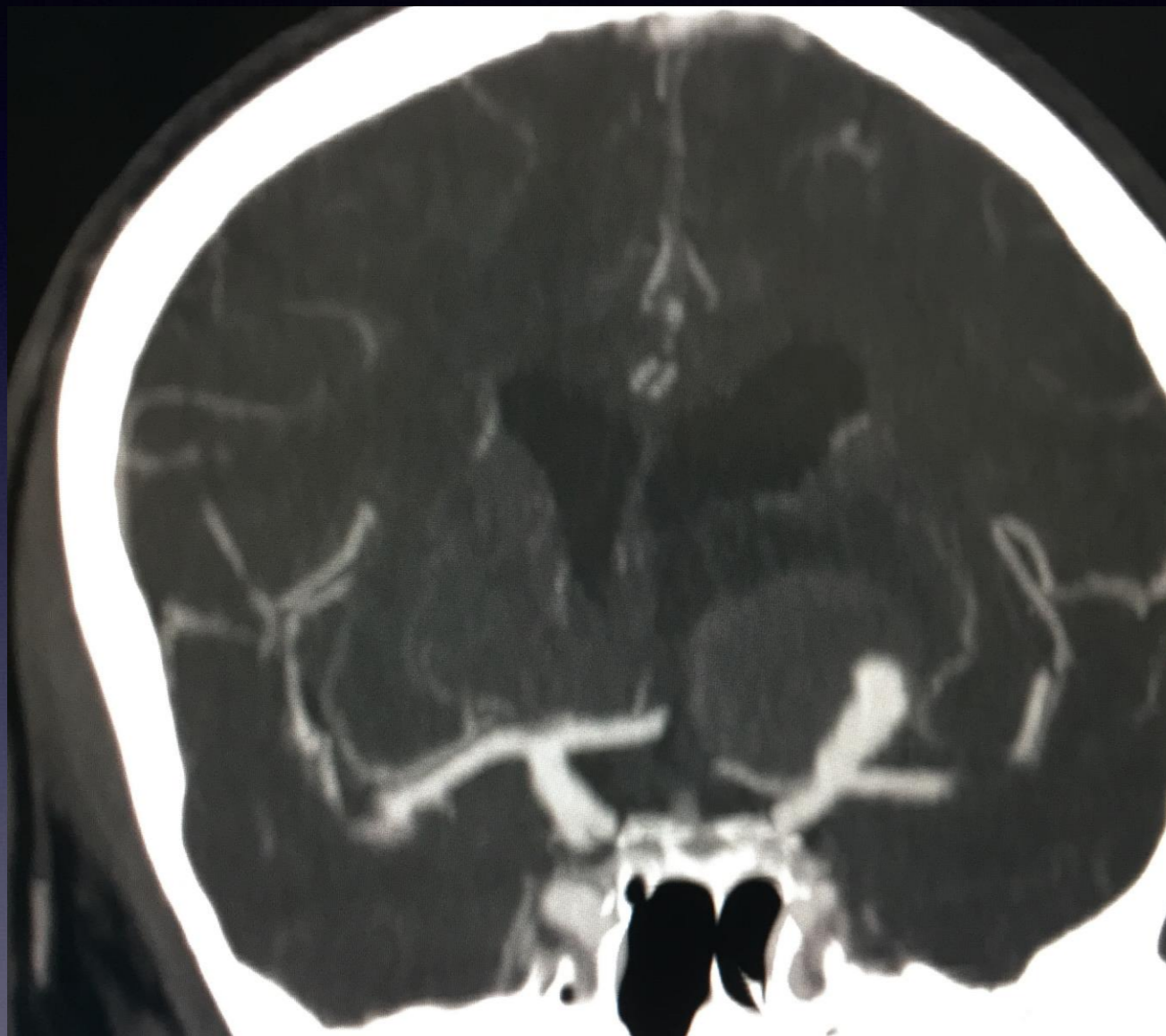


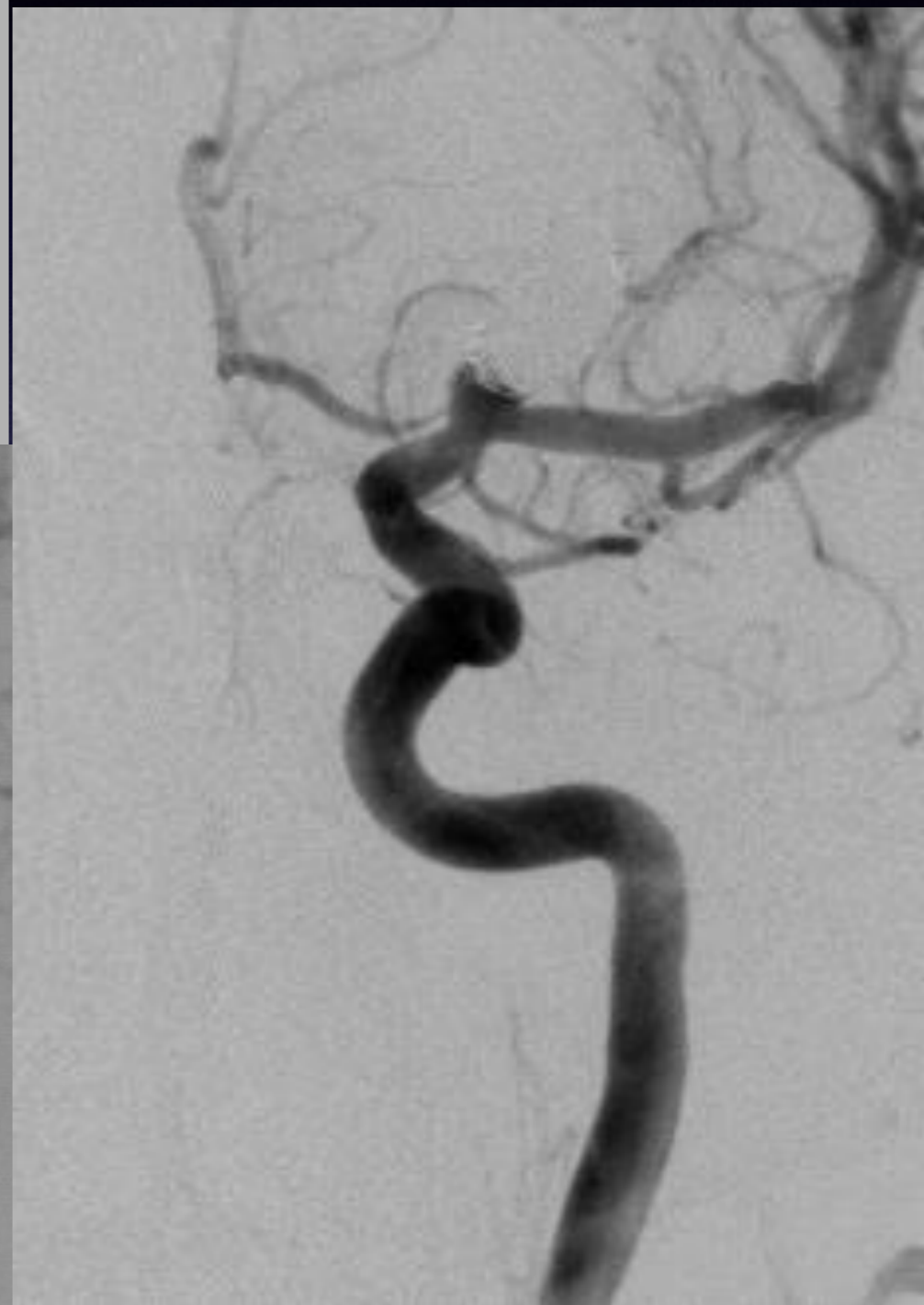
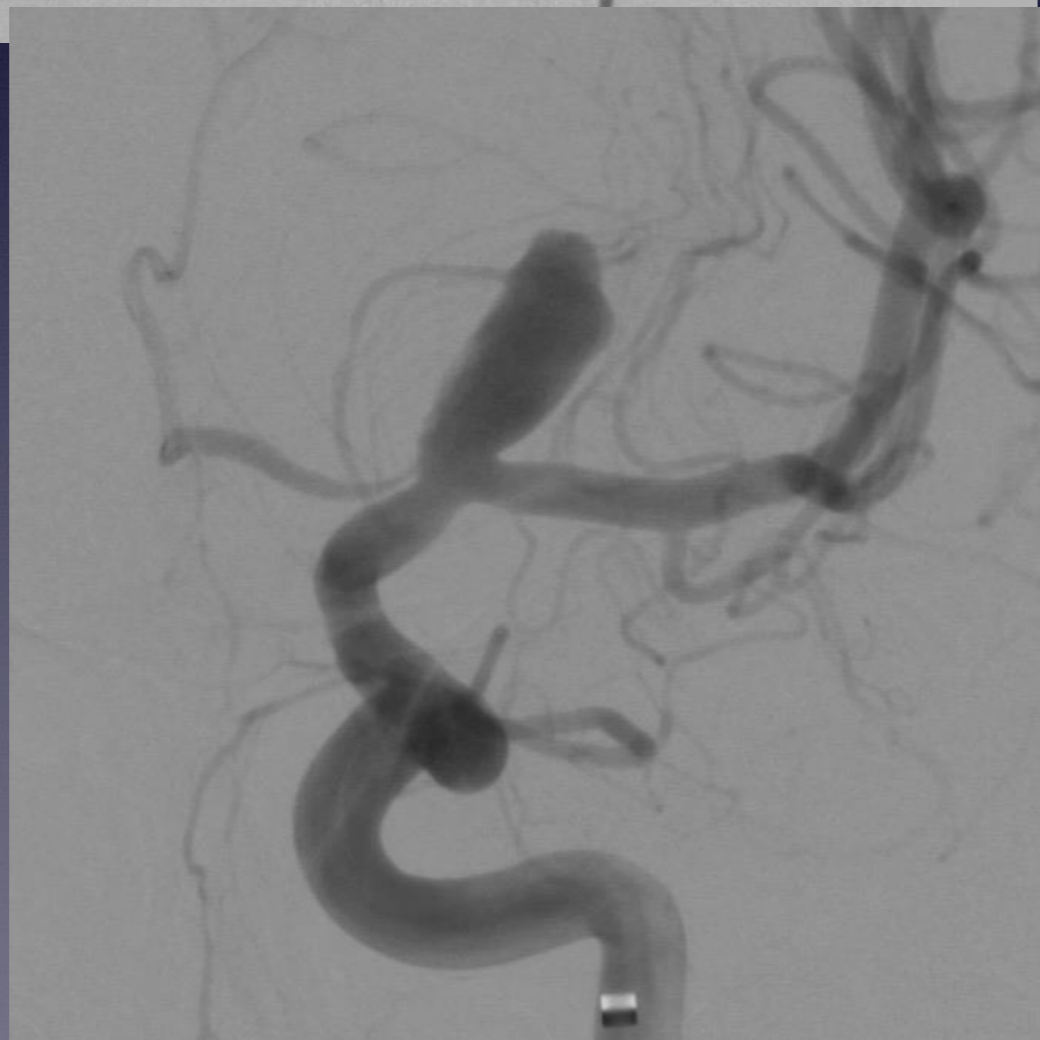
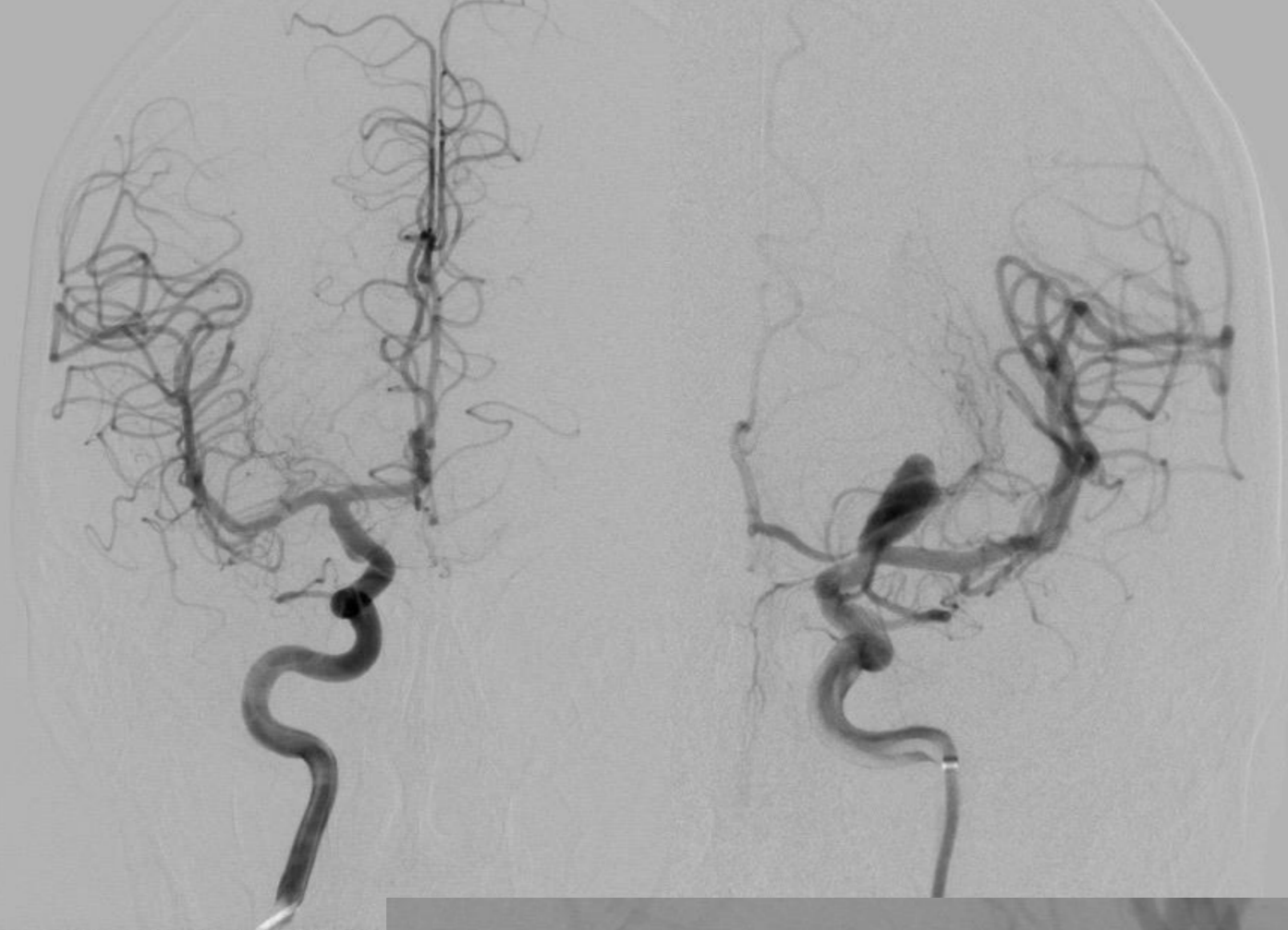
# 48 year old man with headaches and acute onset of right sided numbness and right facial nerve palsy



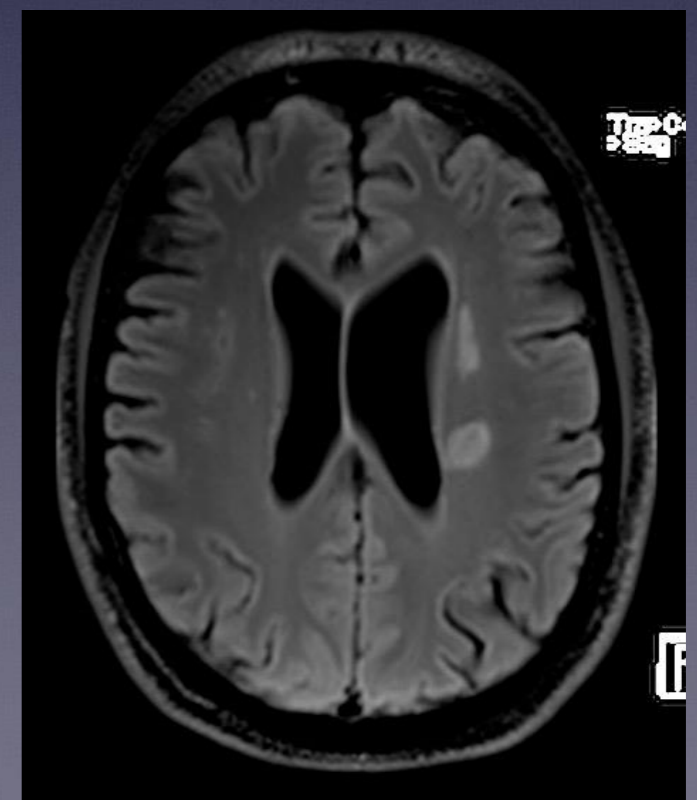
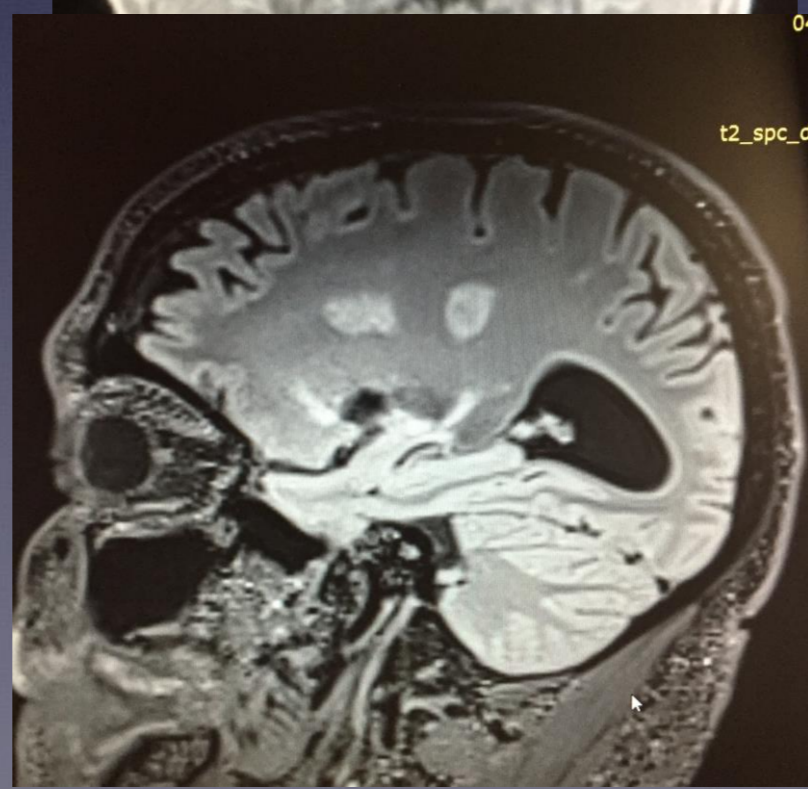
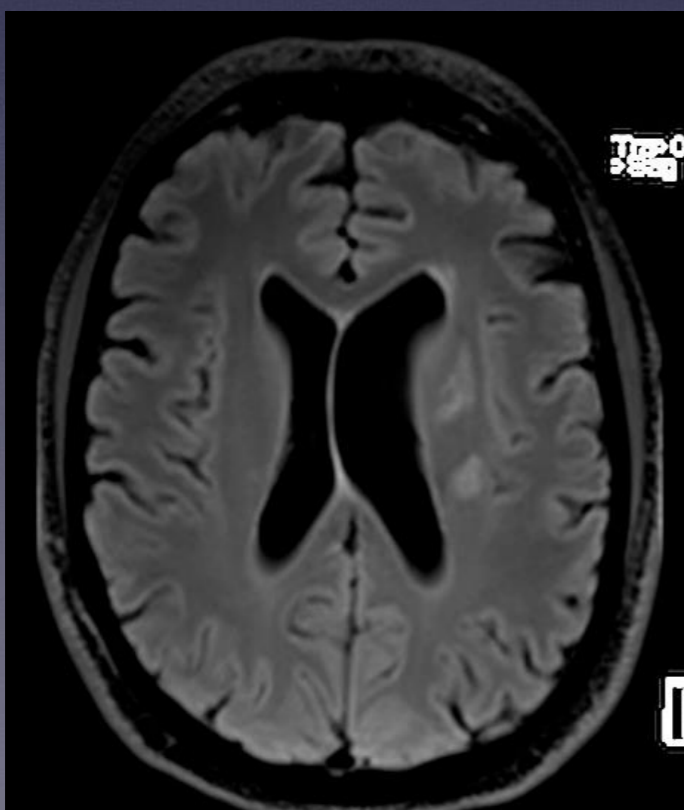
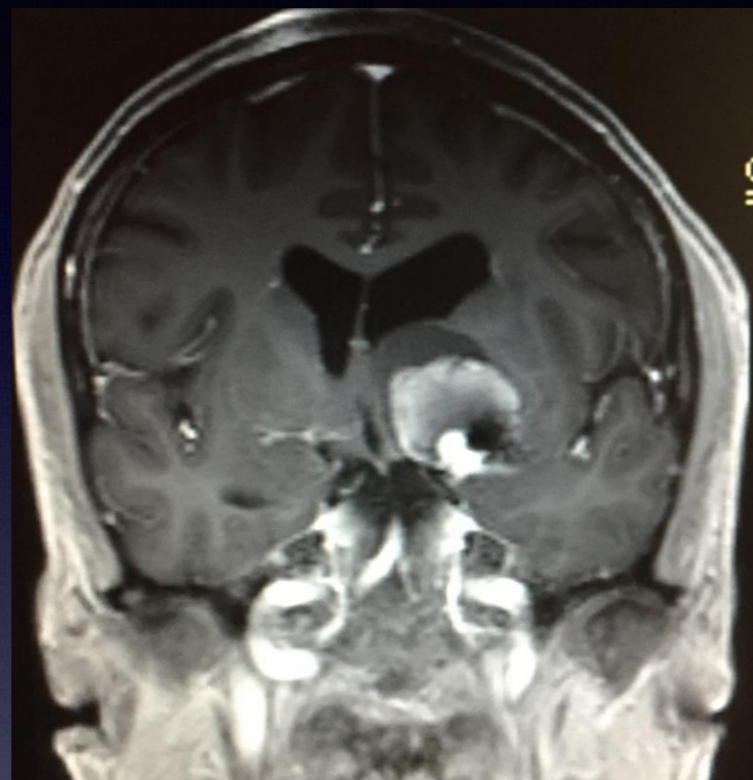

# 48 year old man with headaches and acute onset of right sided weakness

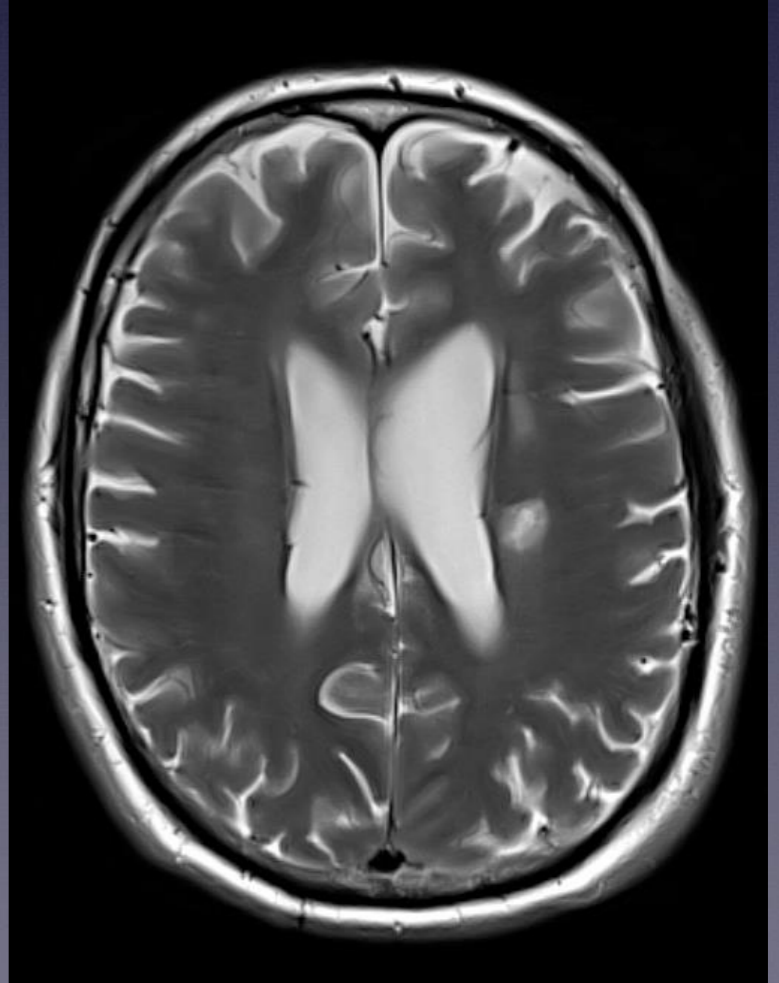
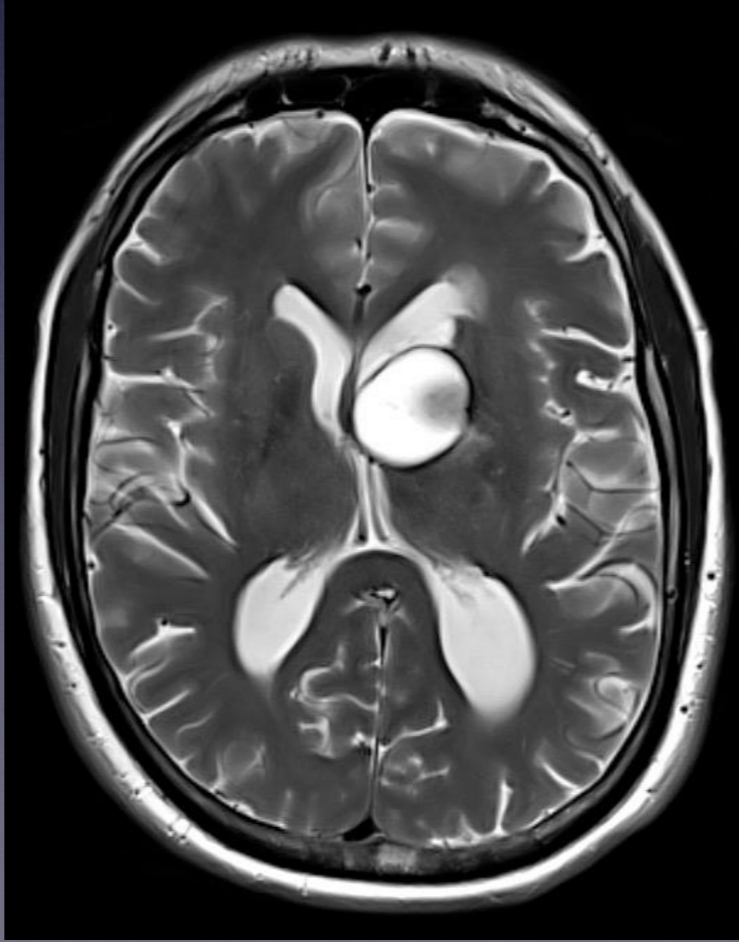
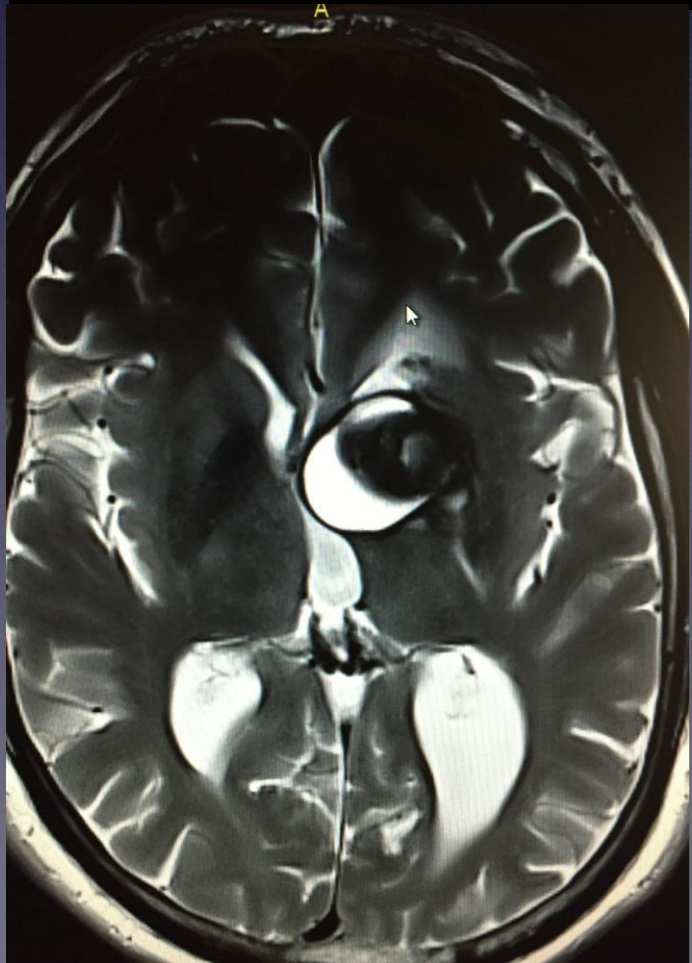
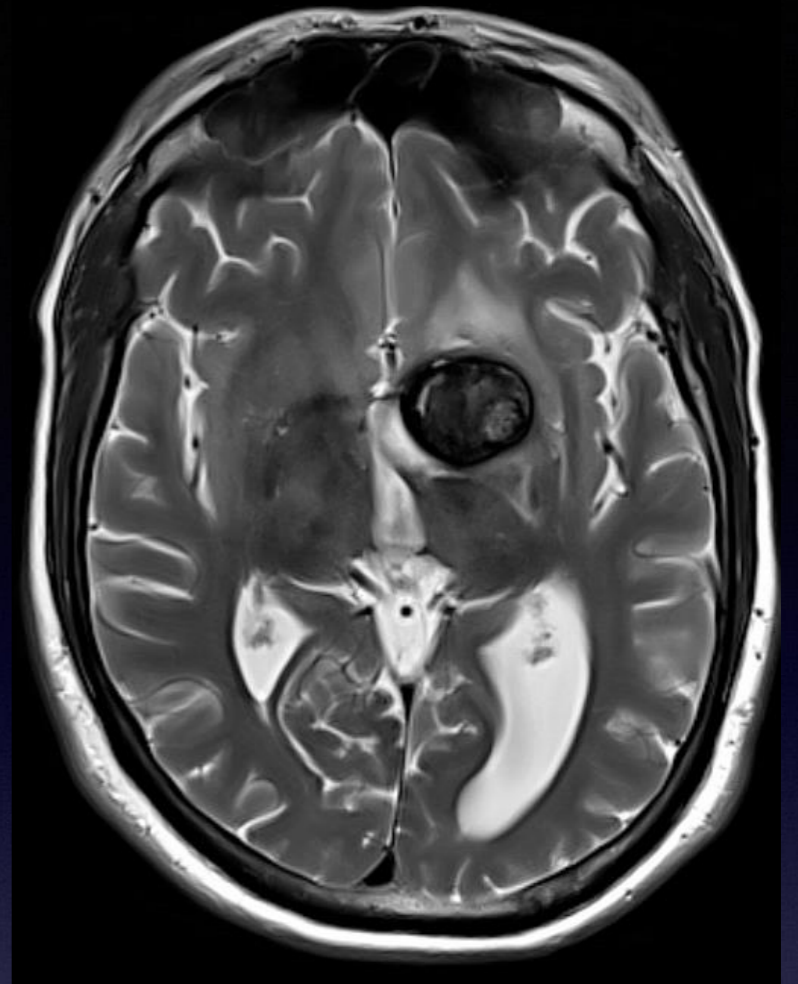
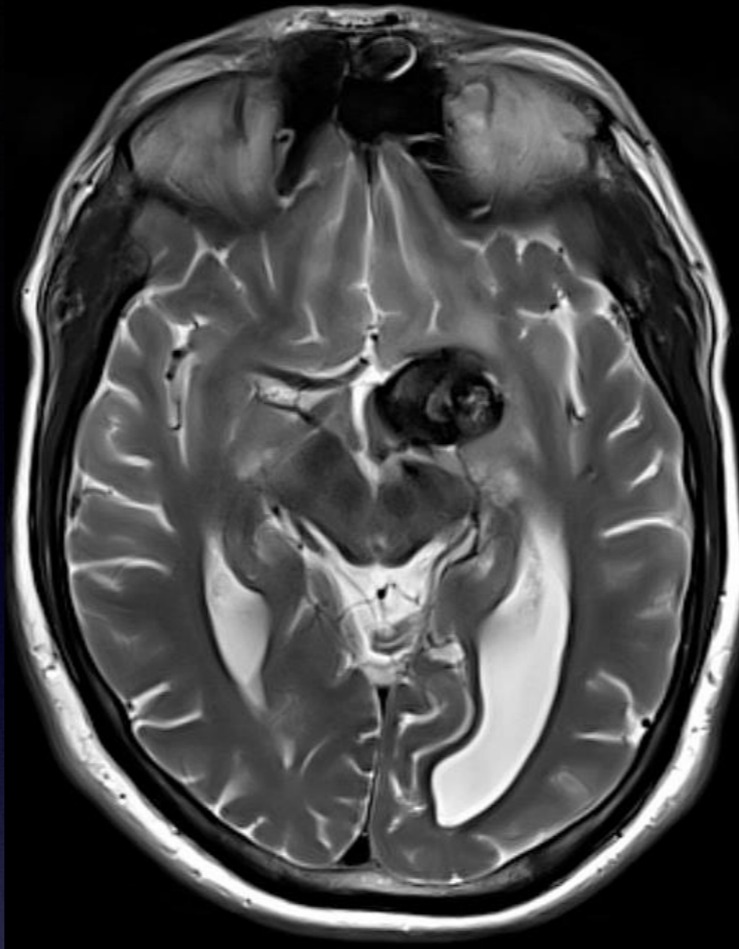
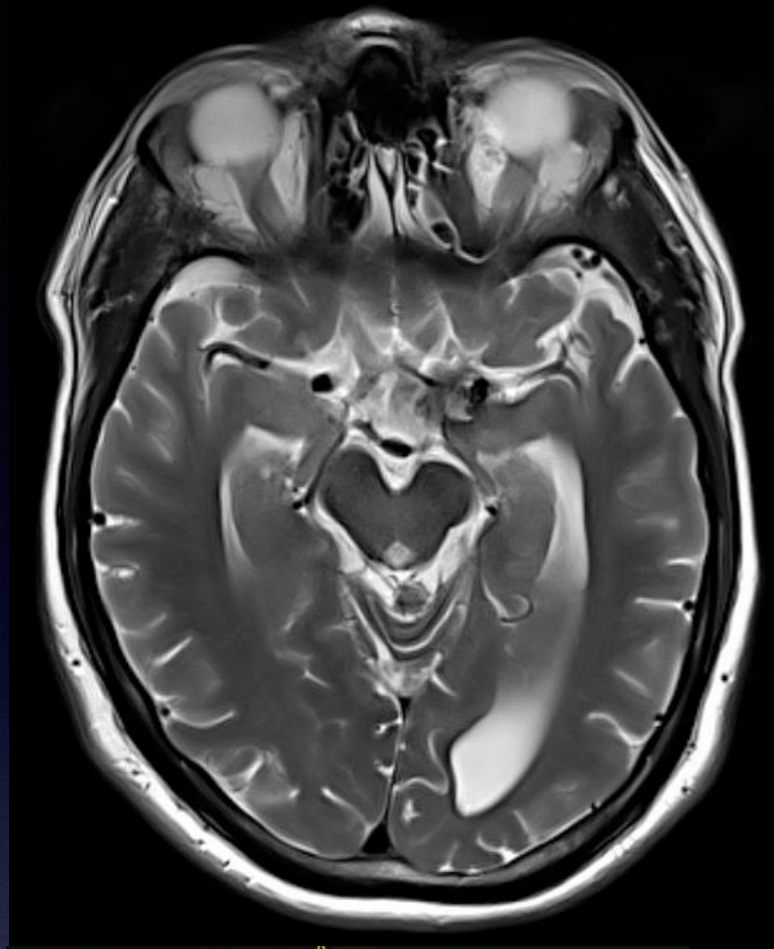


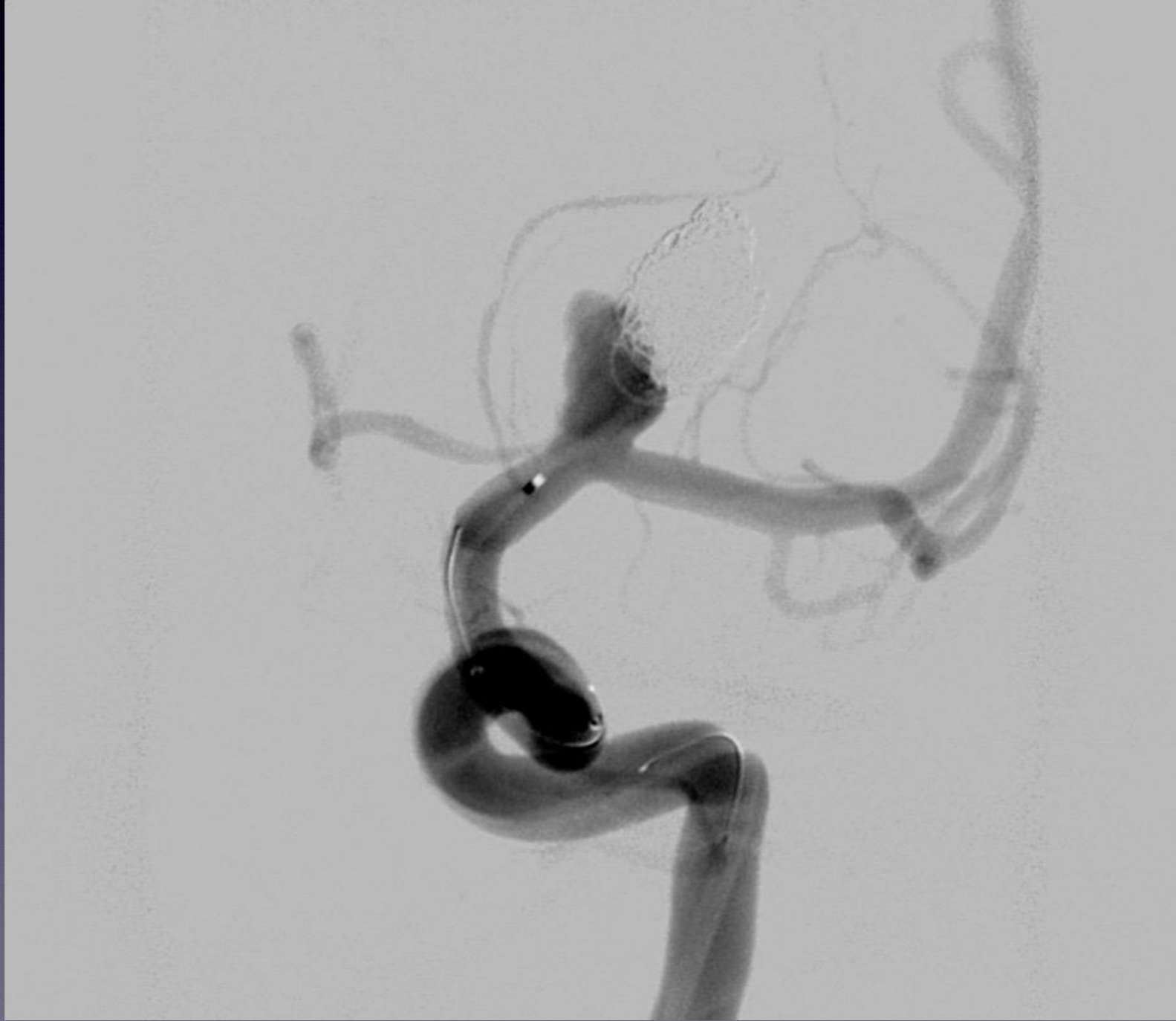

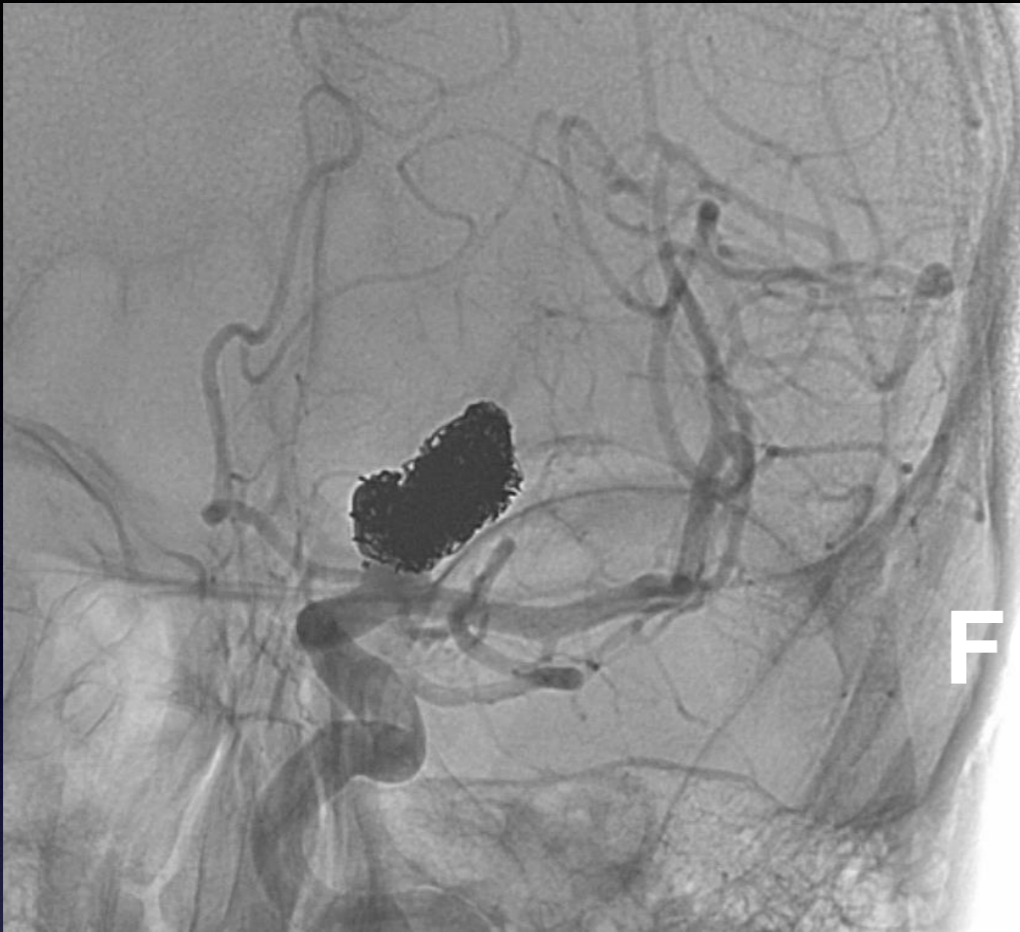
# MRI 6 weeks after presentation and coiling



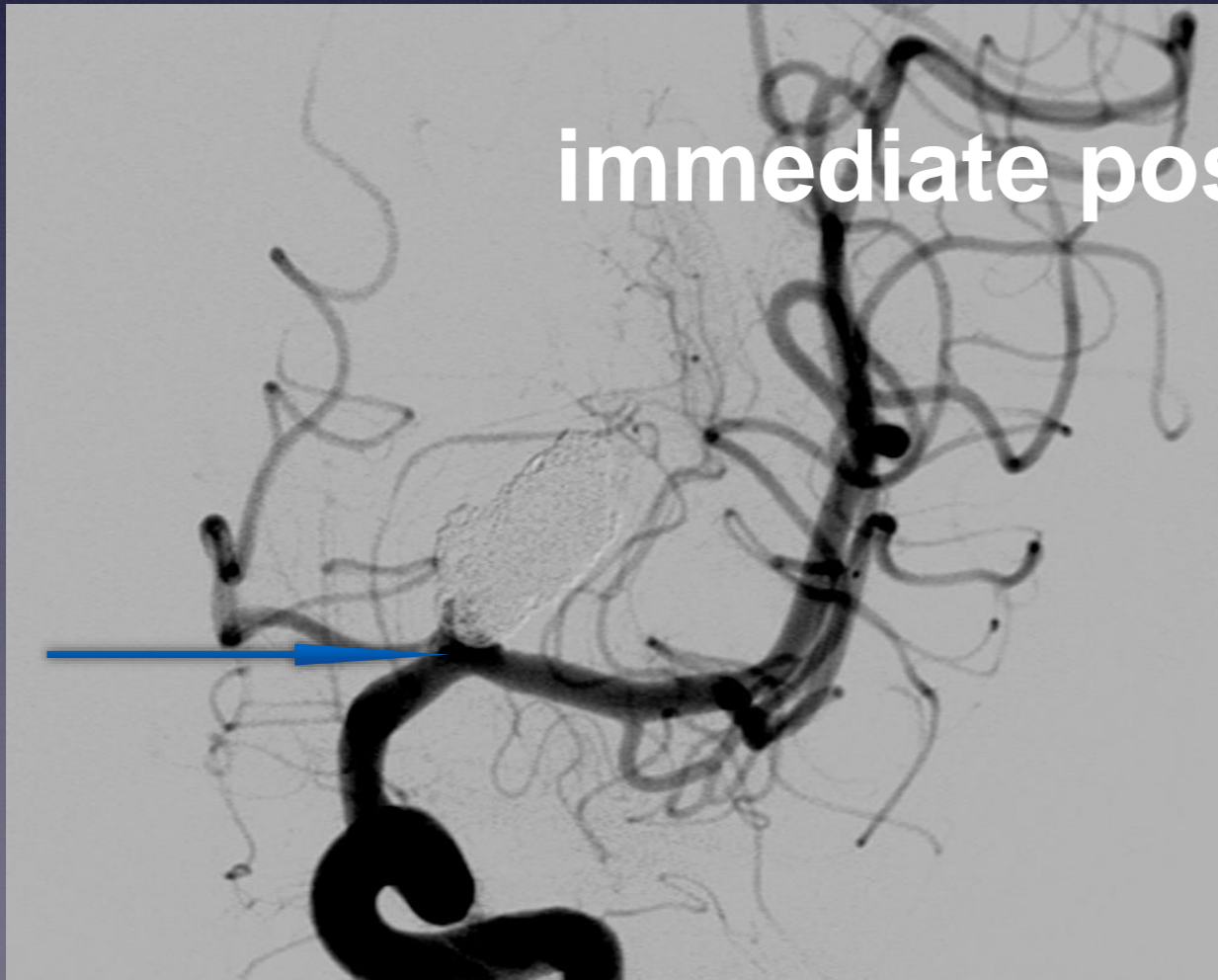
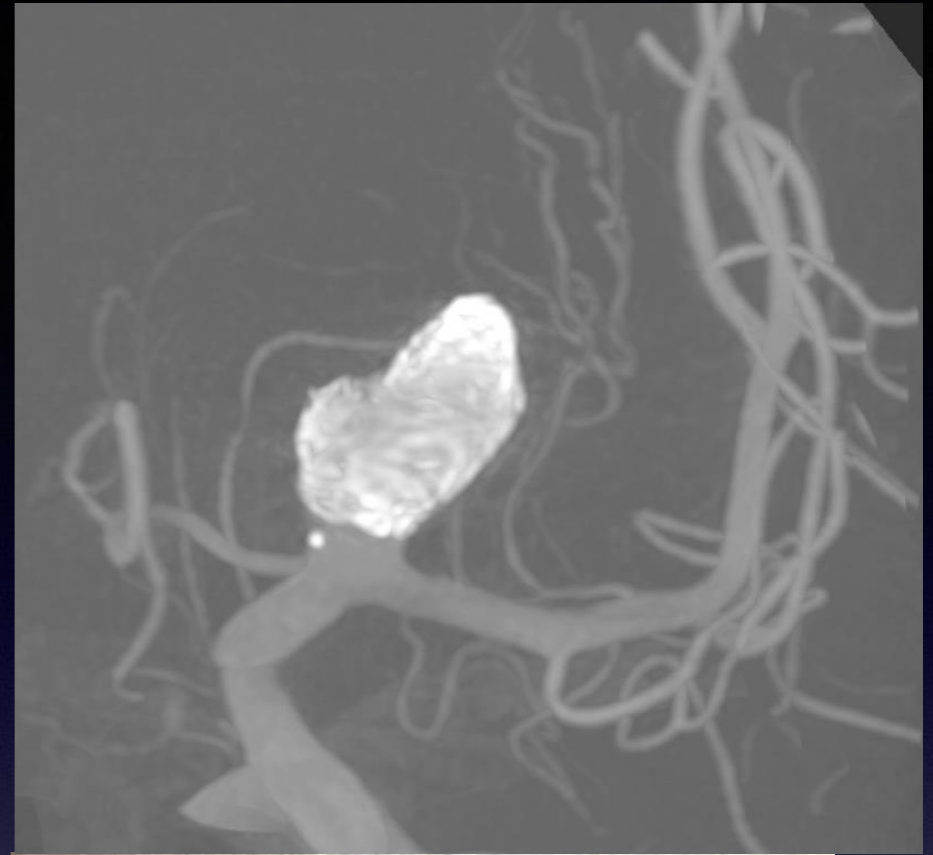




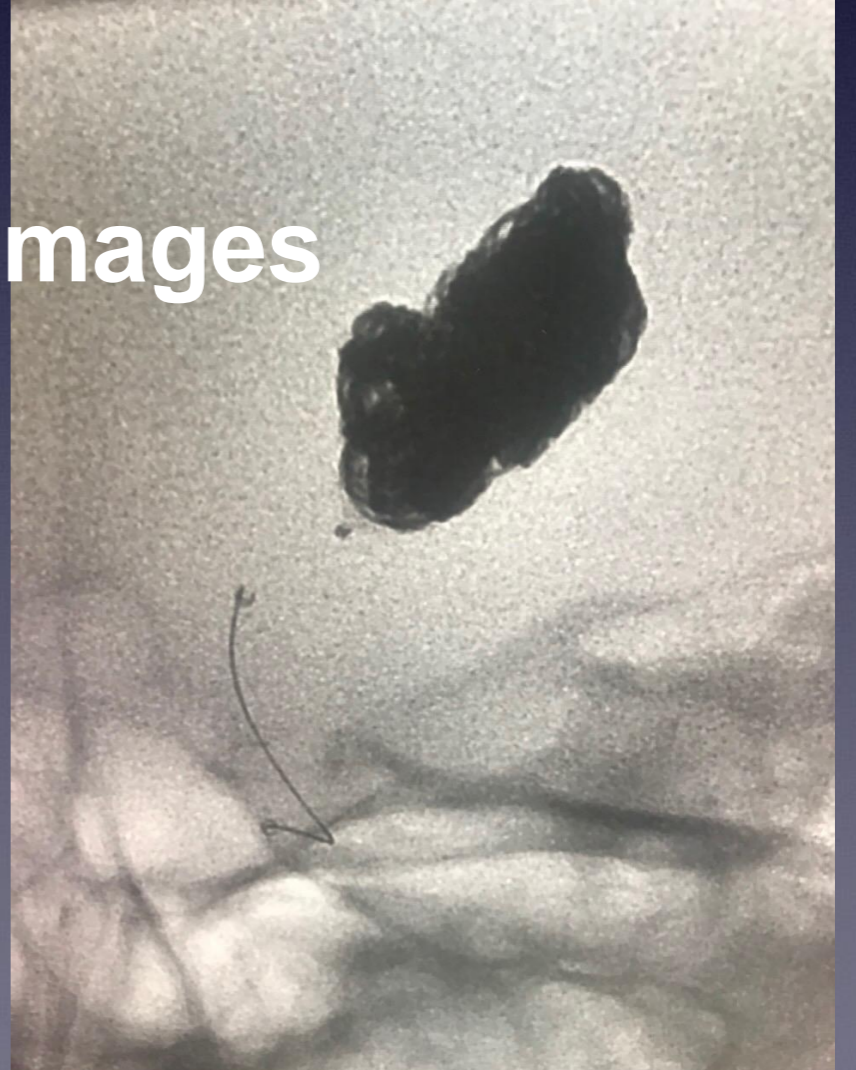

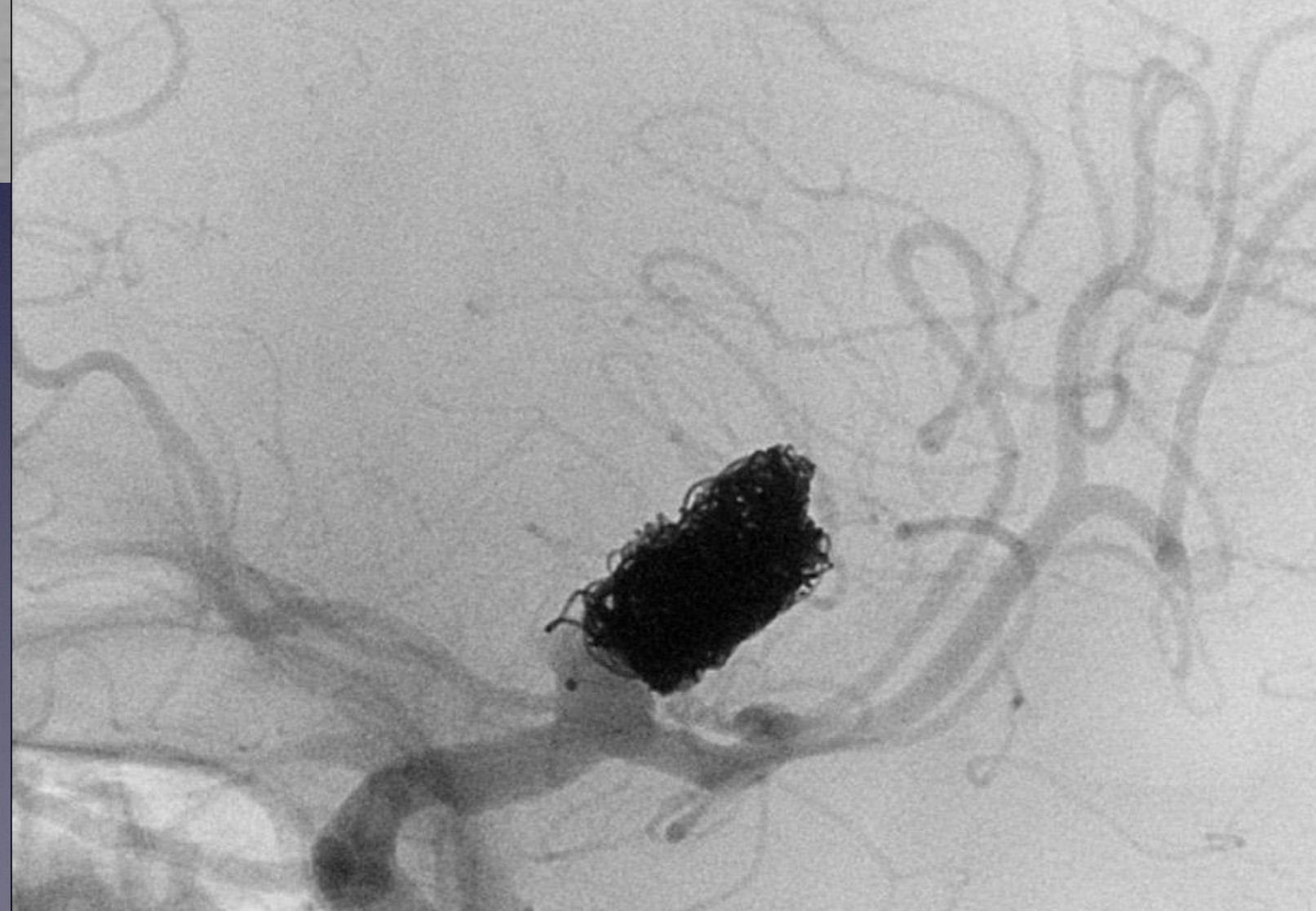
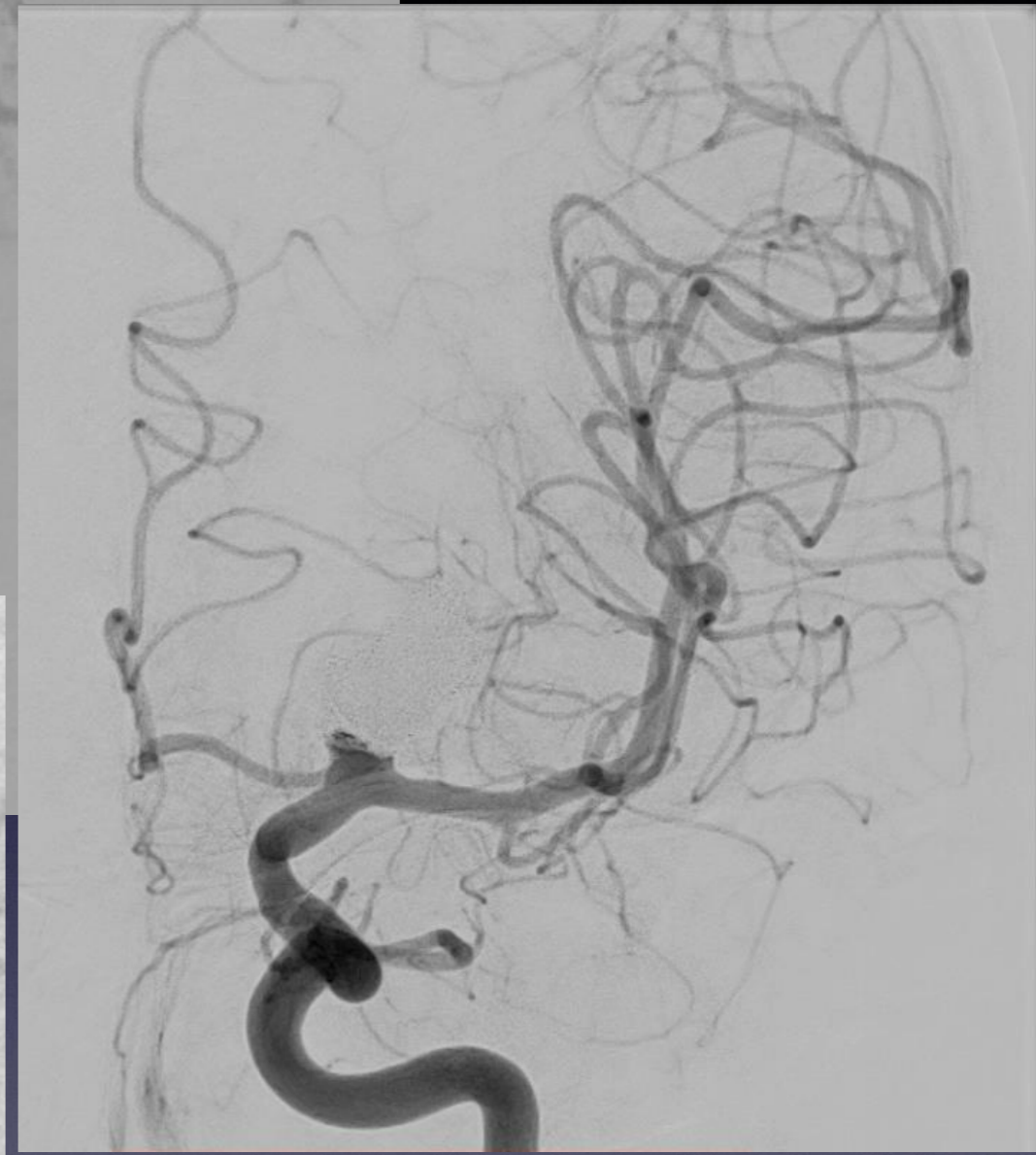
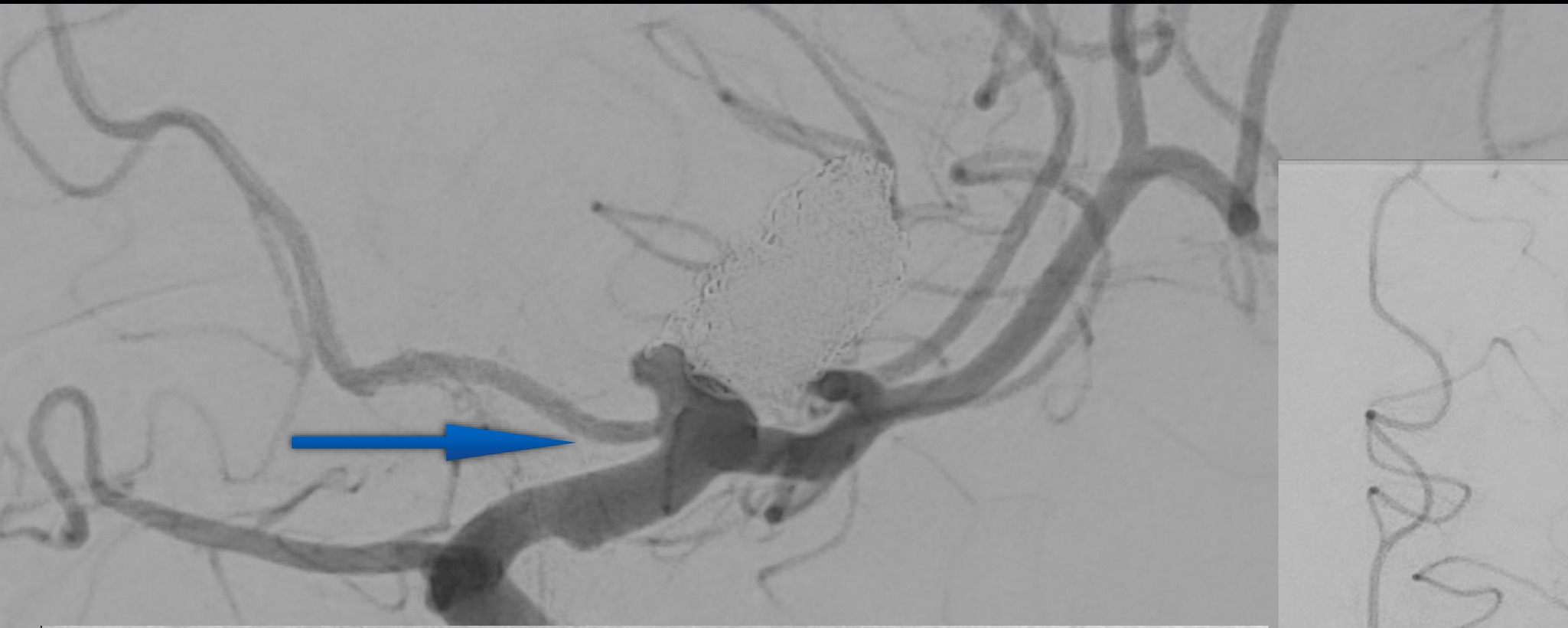


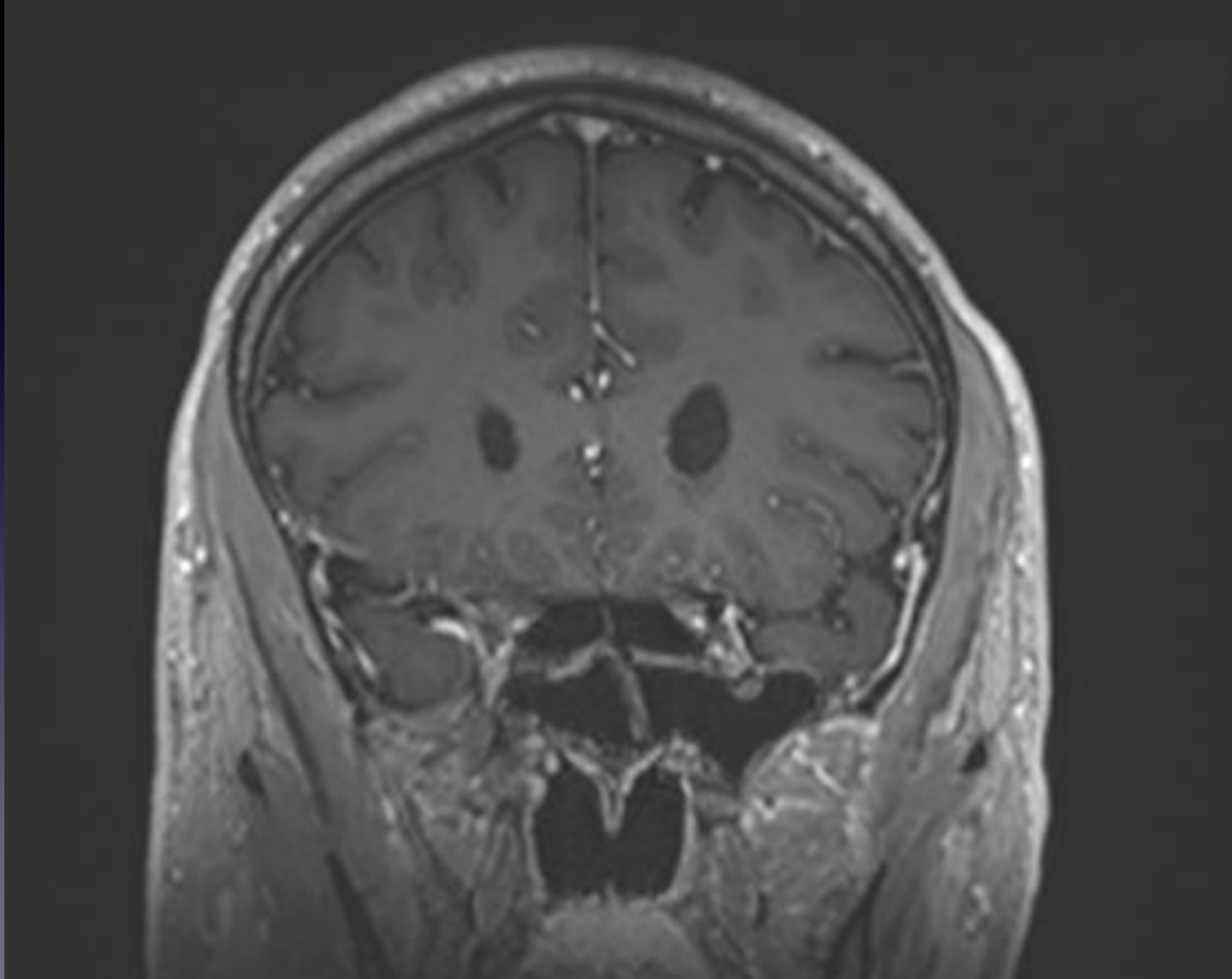
**FOLLOW UP**



**immediate post embo images**



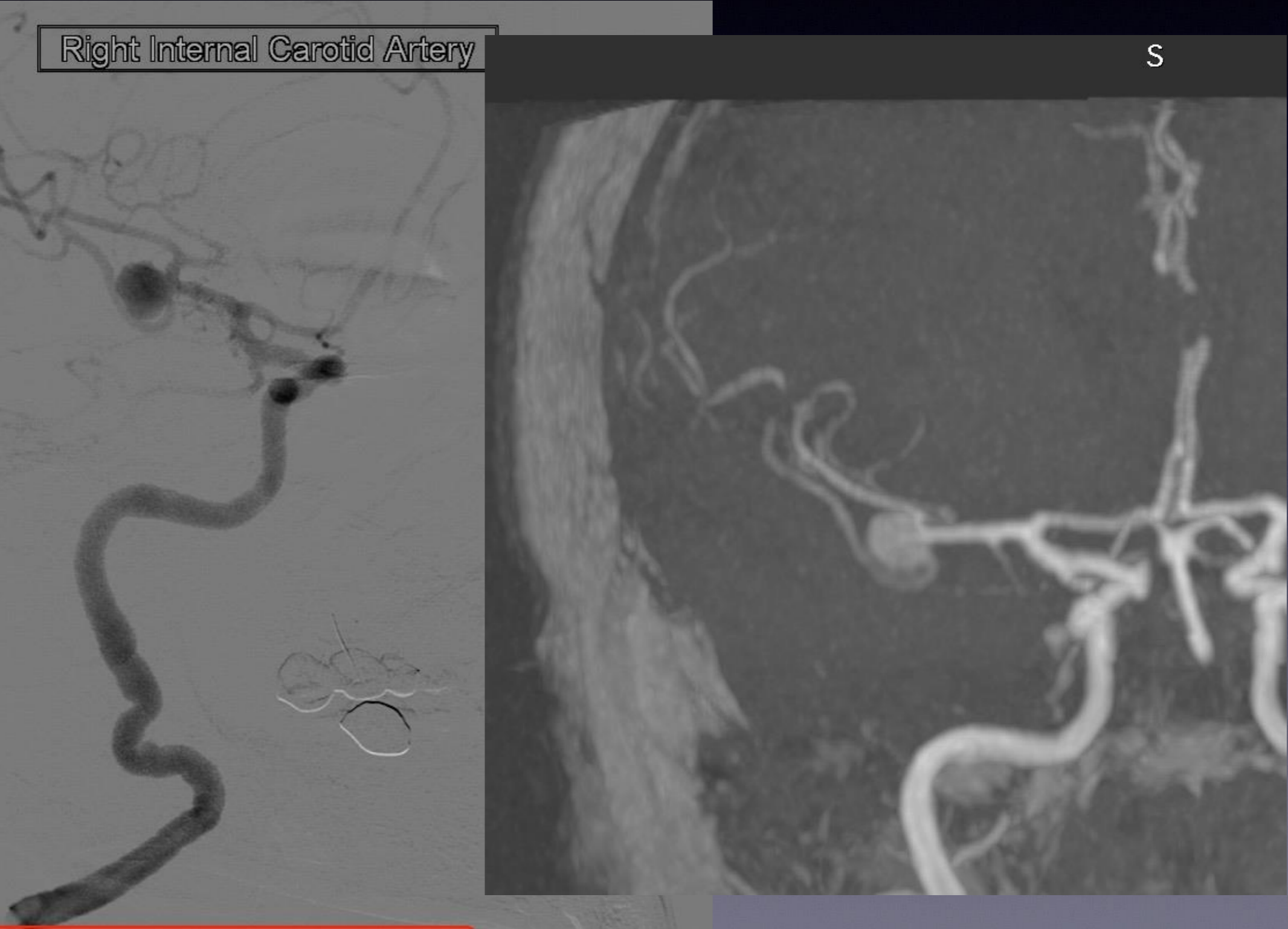




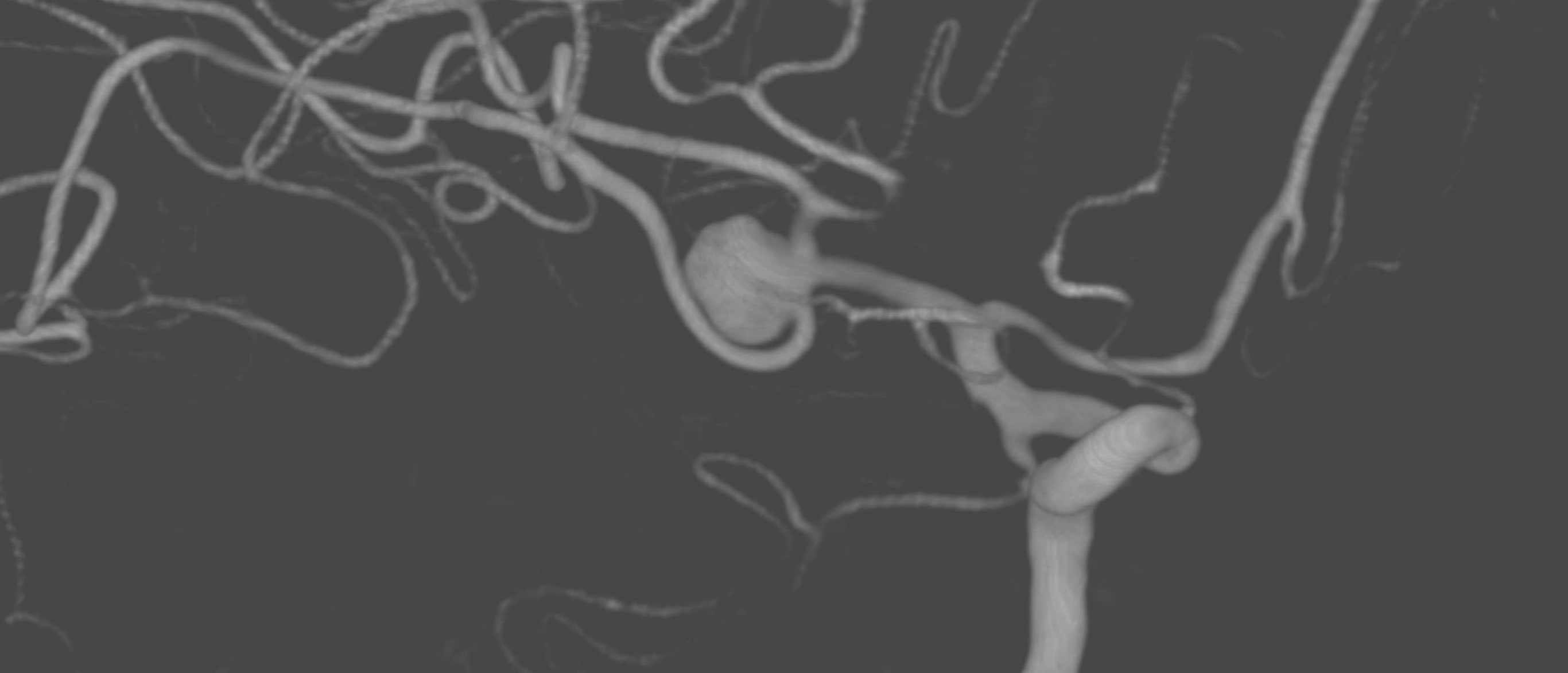
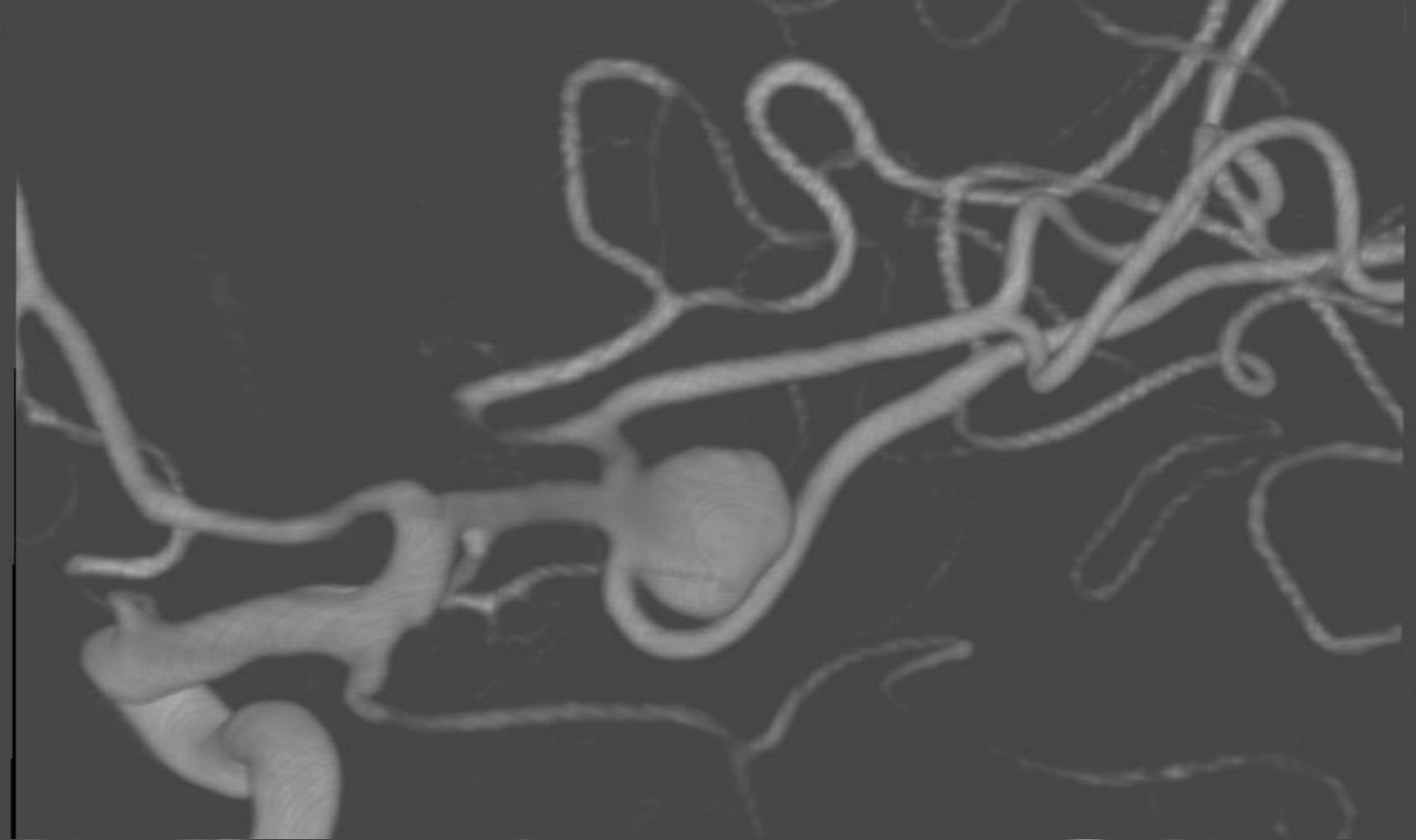
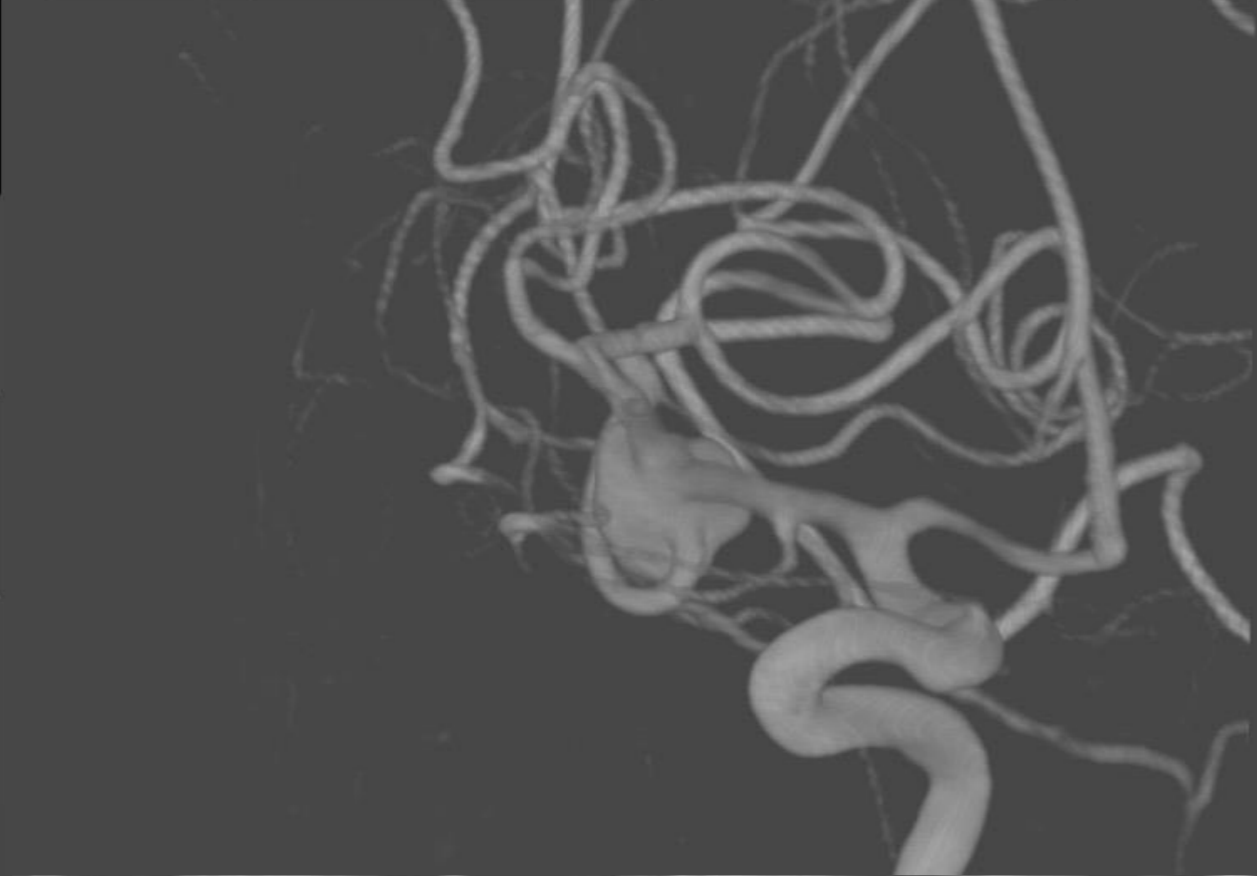
# 56 year old female patient with new onset of headaches

Right Internal Carotid Artery

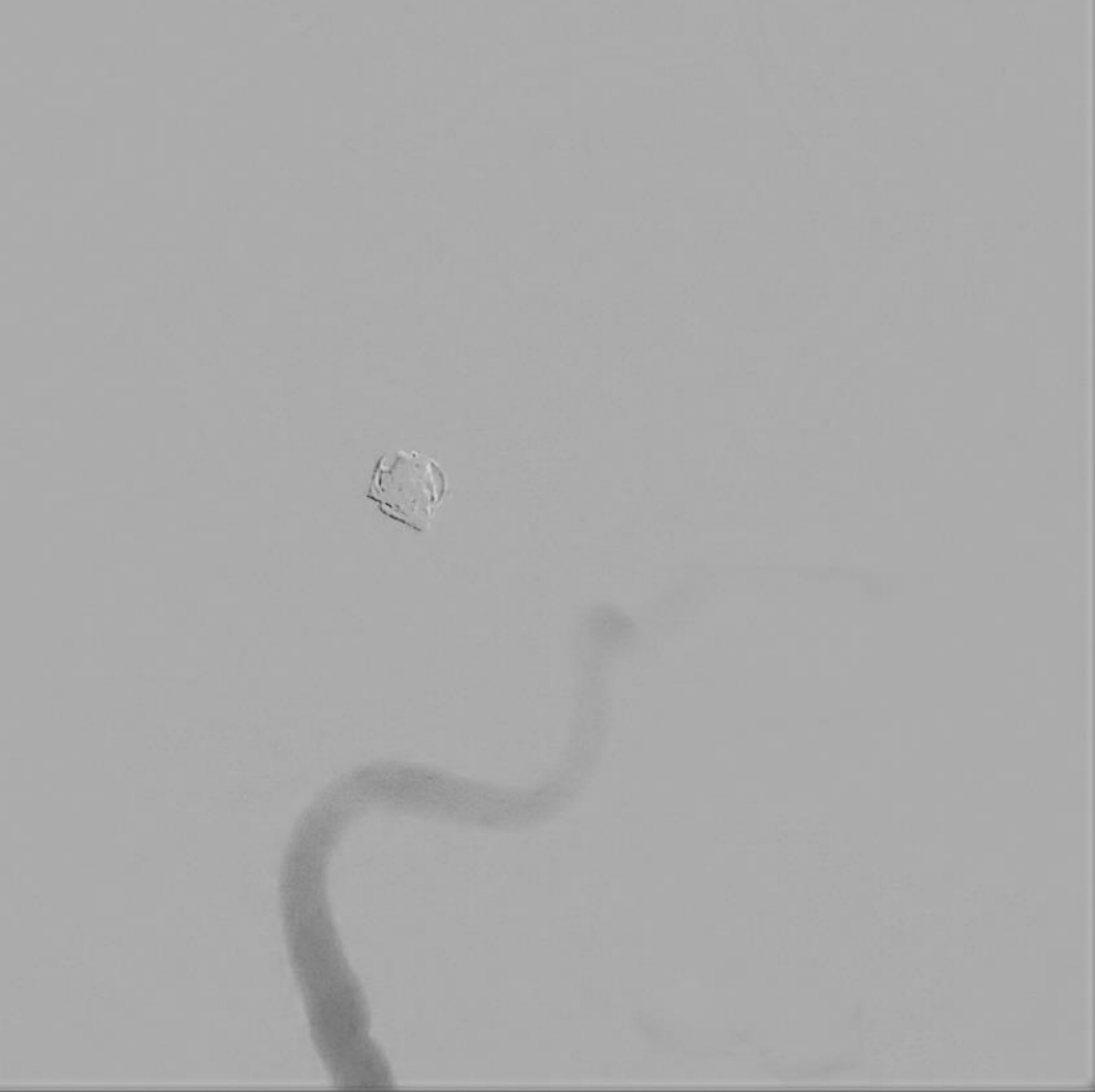S



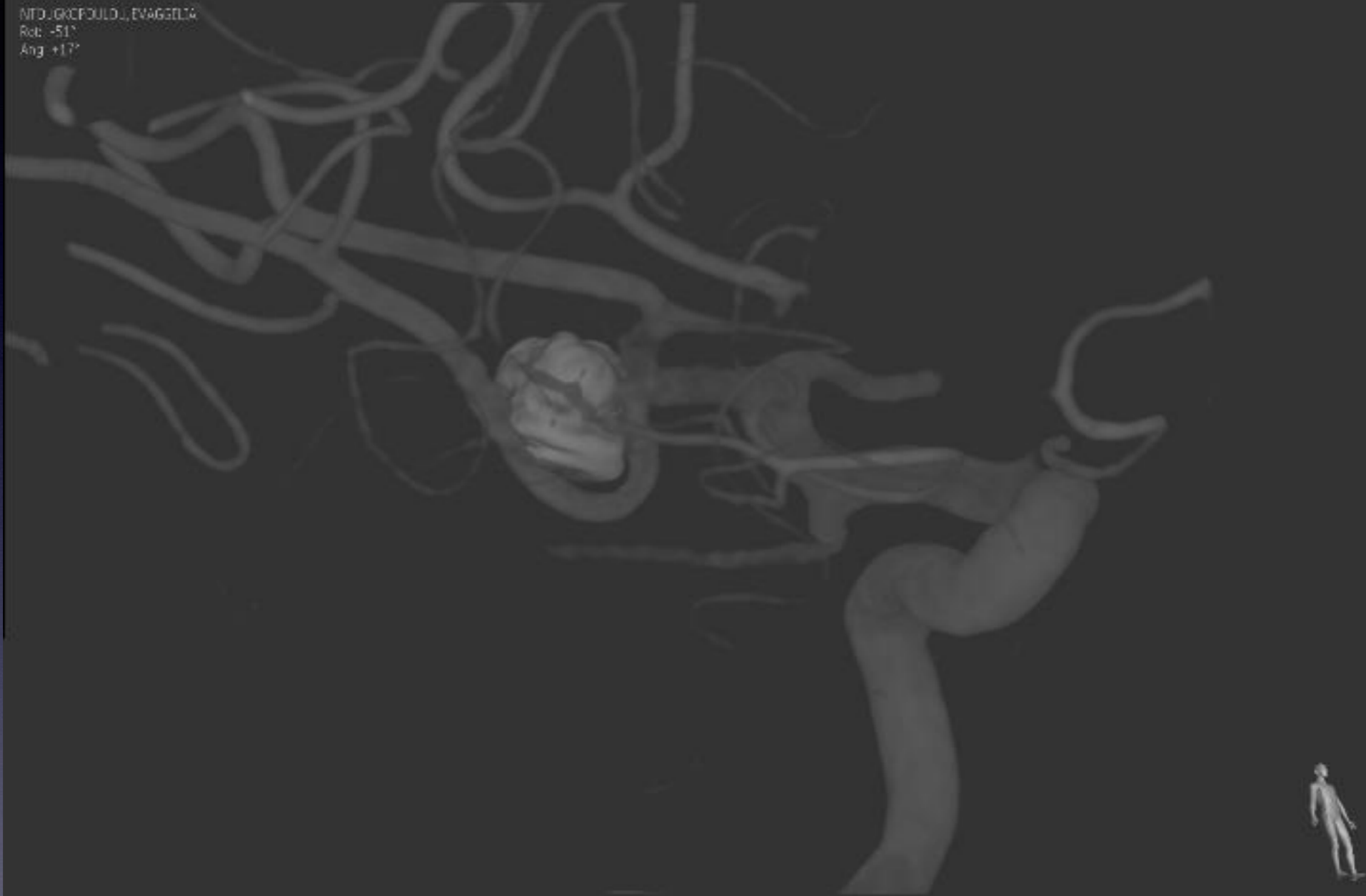




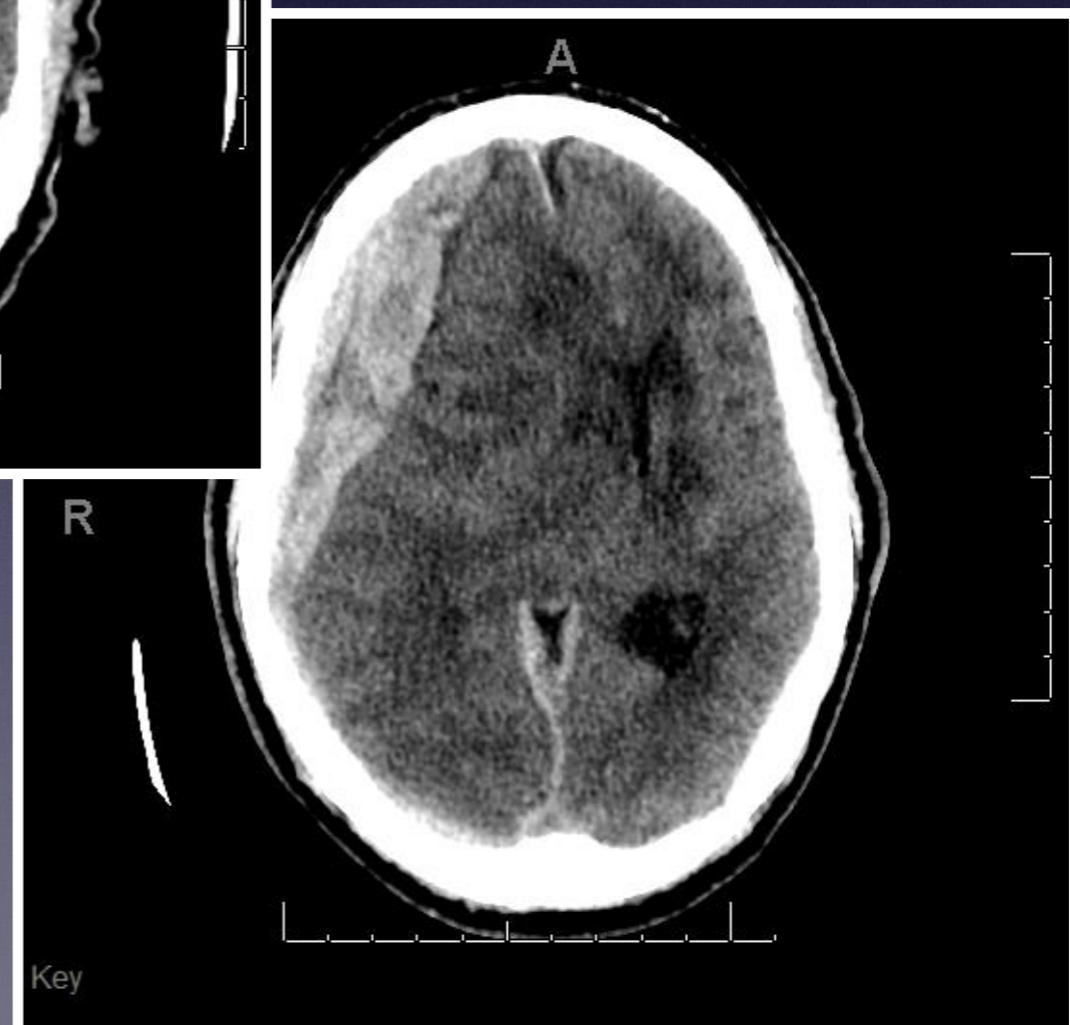
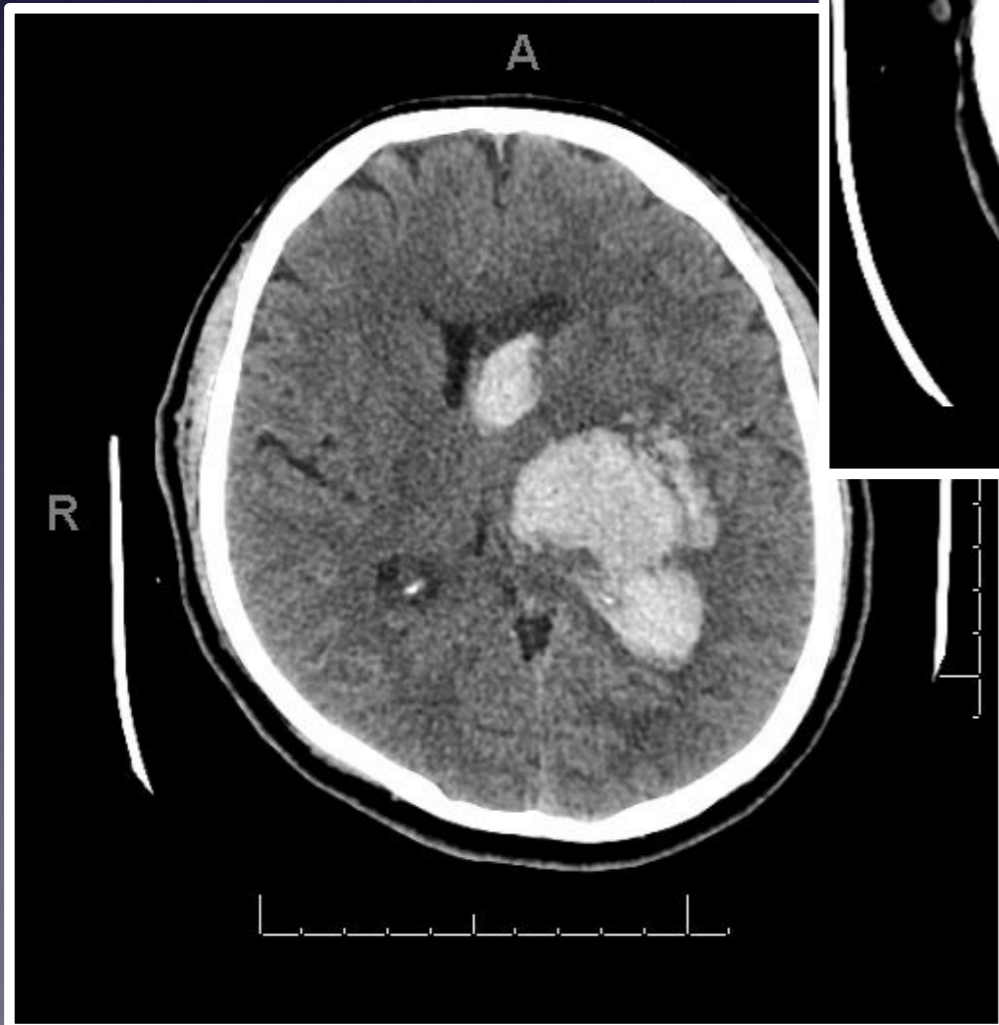
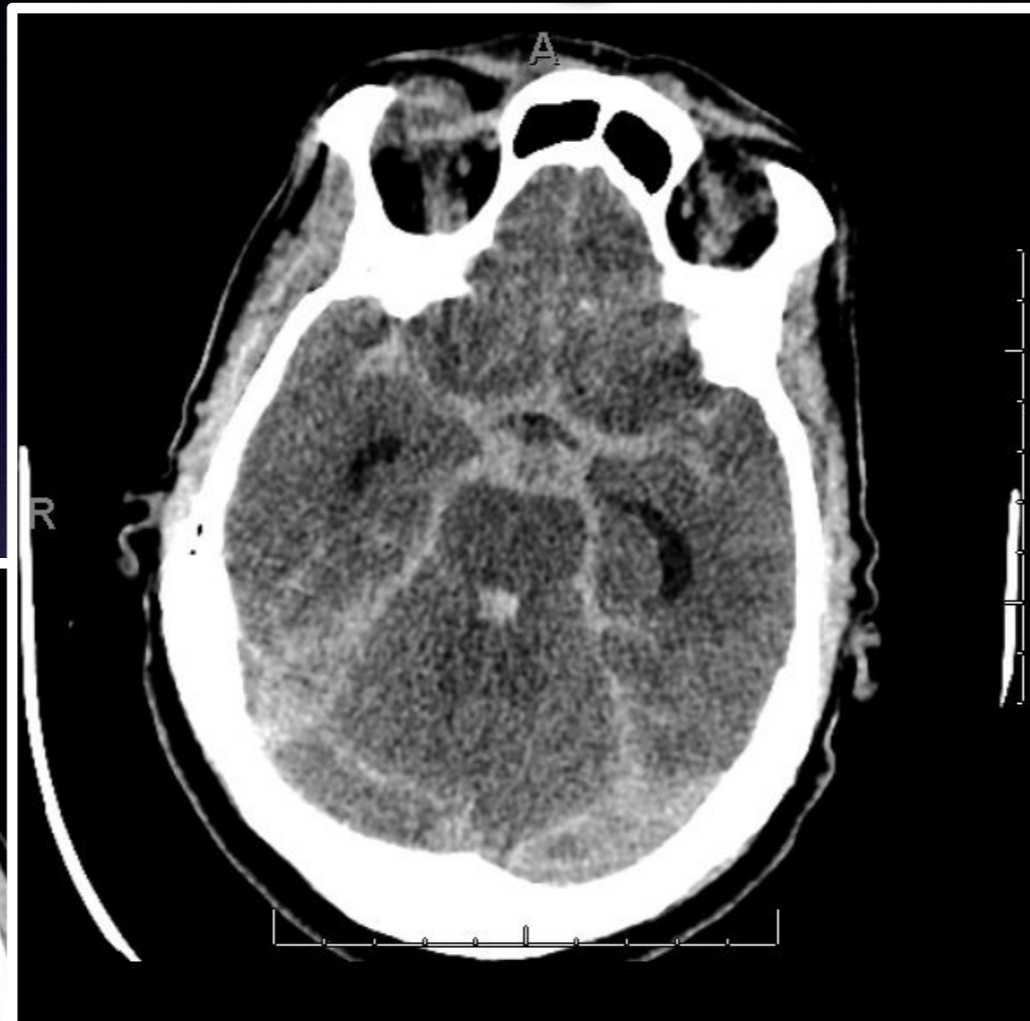



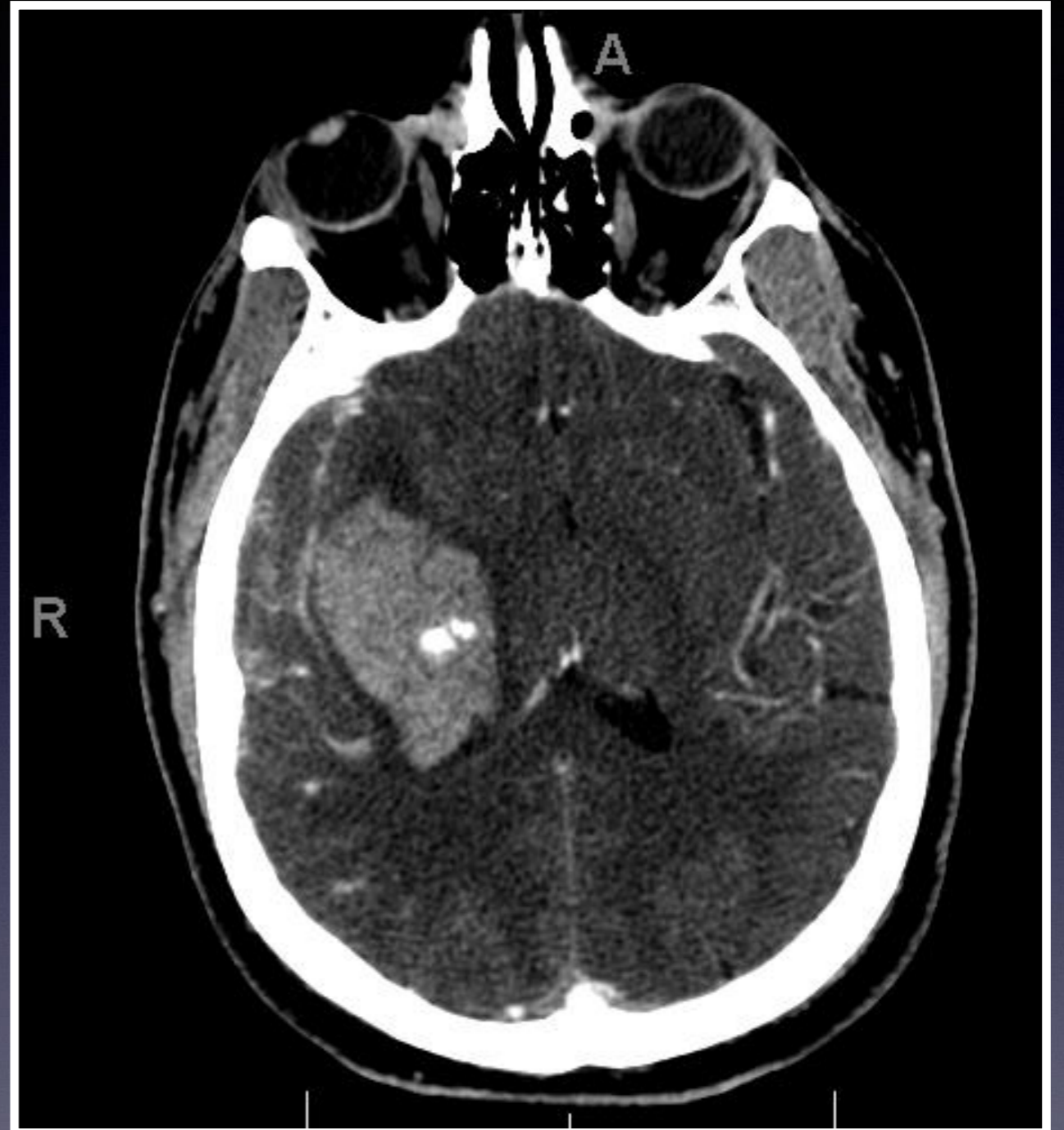
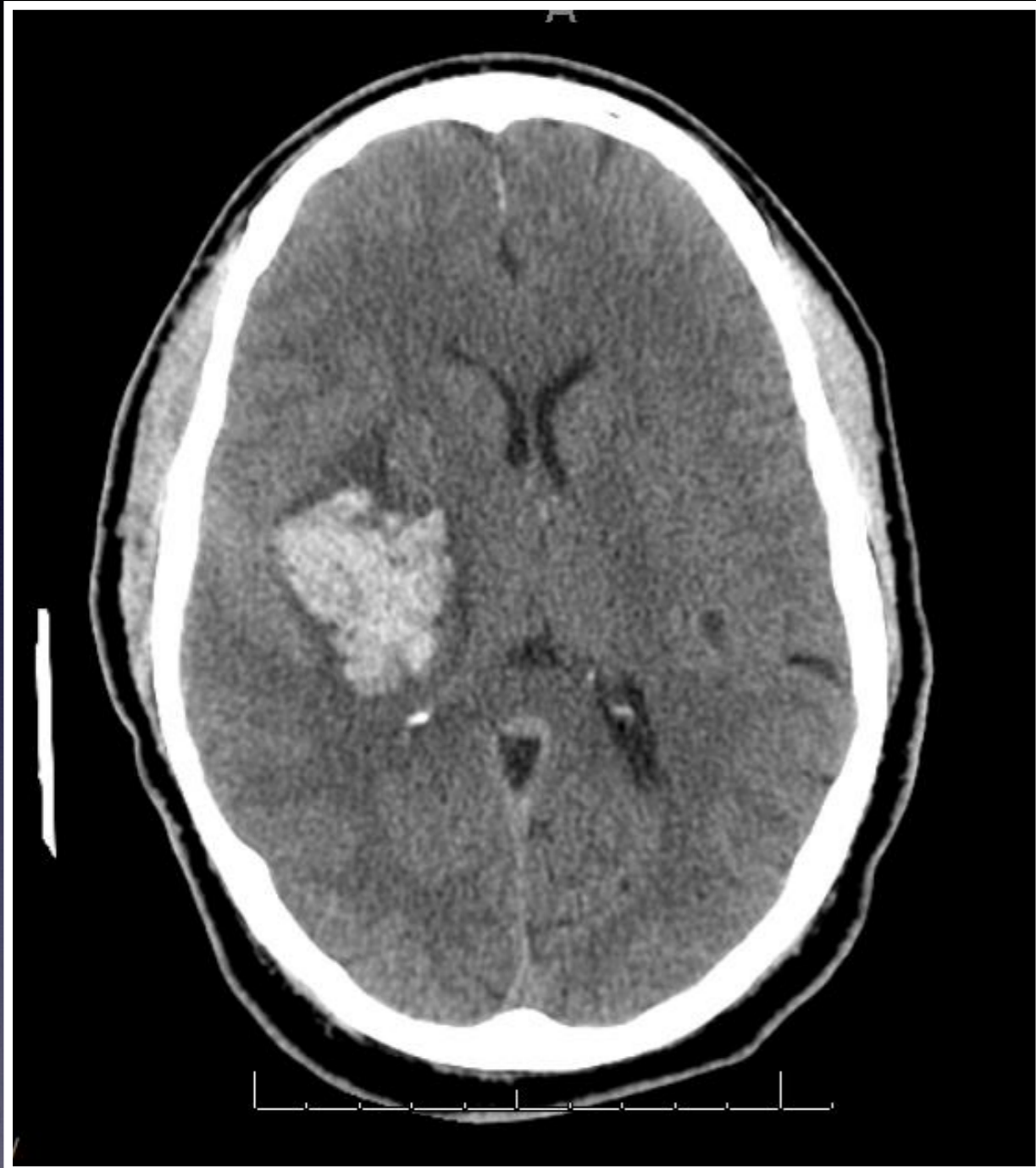NTD JGRCP00LDJ, EVAGGSLA  
Rot: -51°  
Ang: +17°



# Hemorrhagic Stroke



70 yo man presenting with left hemiplegia and altered mental status



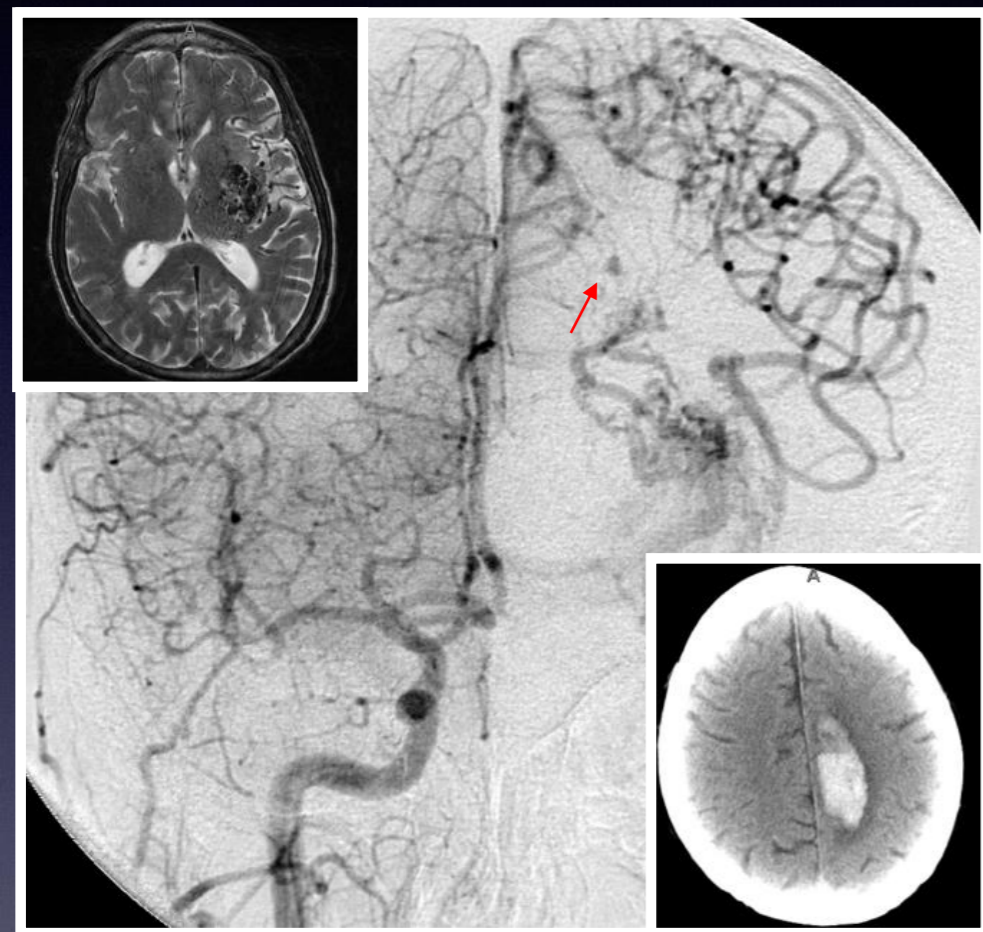
# Striato-capsular Hemorrhage

- Etiology: HTN
- 40% ICH, 10-15% of all strokes
- Location: BG, thalamus, pons and cerebellar nuclei
- CTA has prognostic value
- Dot sign -> active hemorrhage, enlarging hematoma (25-40% of pts)
- *Lipohyalinosis and fibrinoid necrosis => Charcot-Bouchard aneurysms*

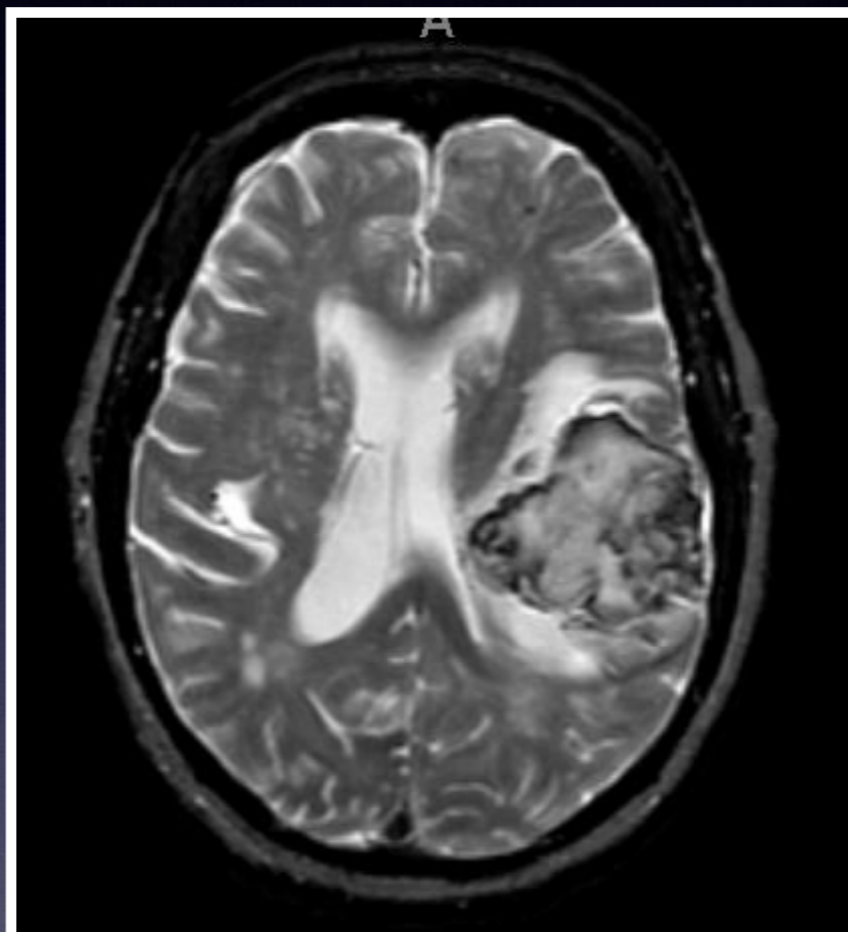
# Differential Diagnosis

- Underlying vascular lesion:
  - Vascular malformation
  - Neoplasm (hypervascular)
- Vasculopathy:
  - HTN, Amyloid, Moyamoya, Cocaine

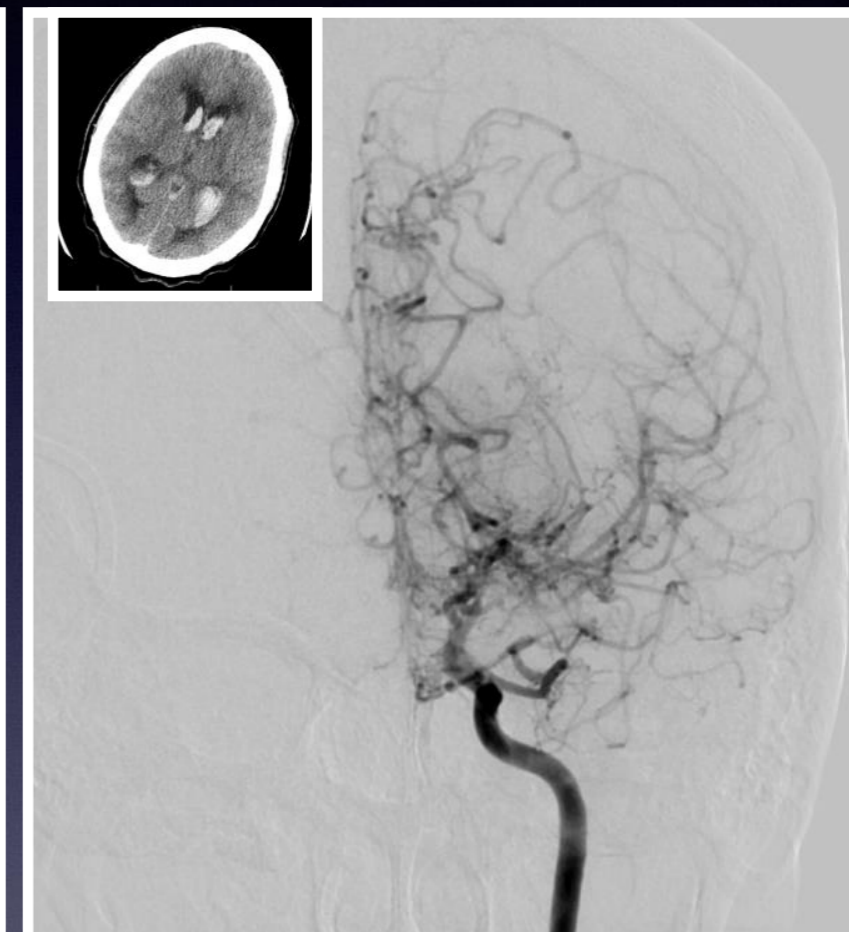
# Differential Diagnosis



Ruptured AVM

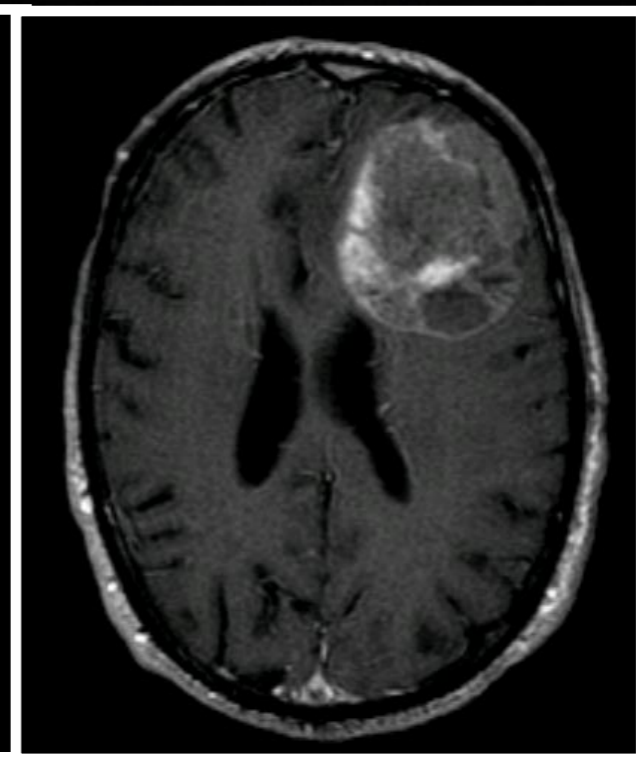
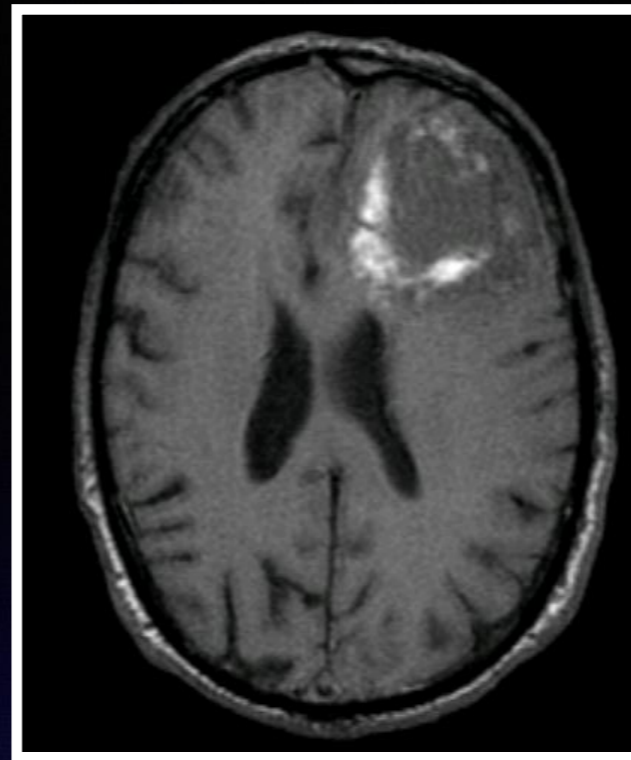
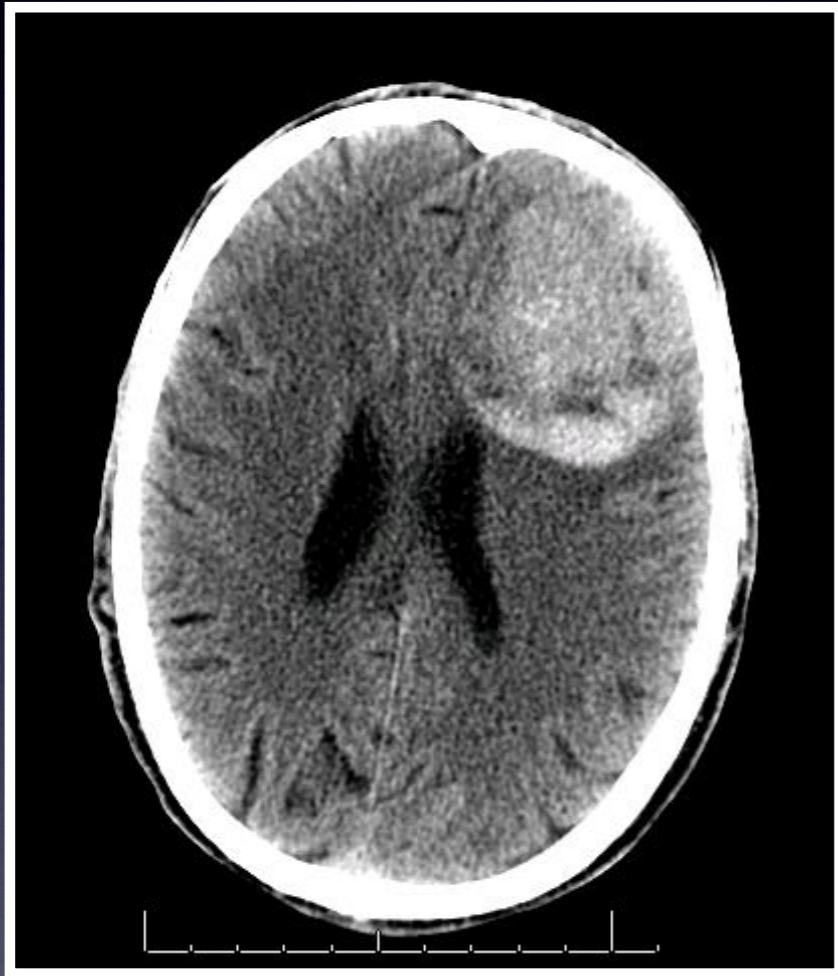

Amyloid angiopathy



Moyamoya disease

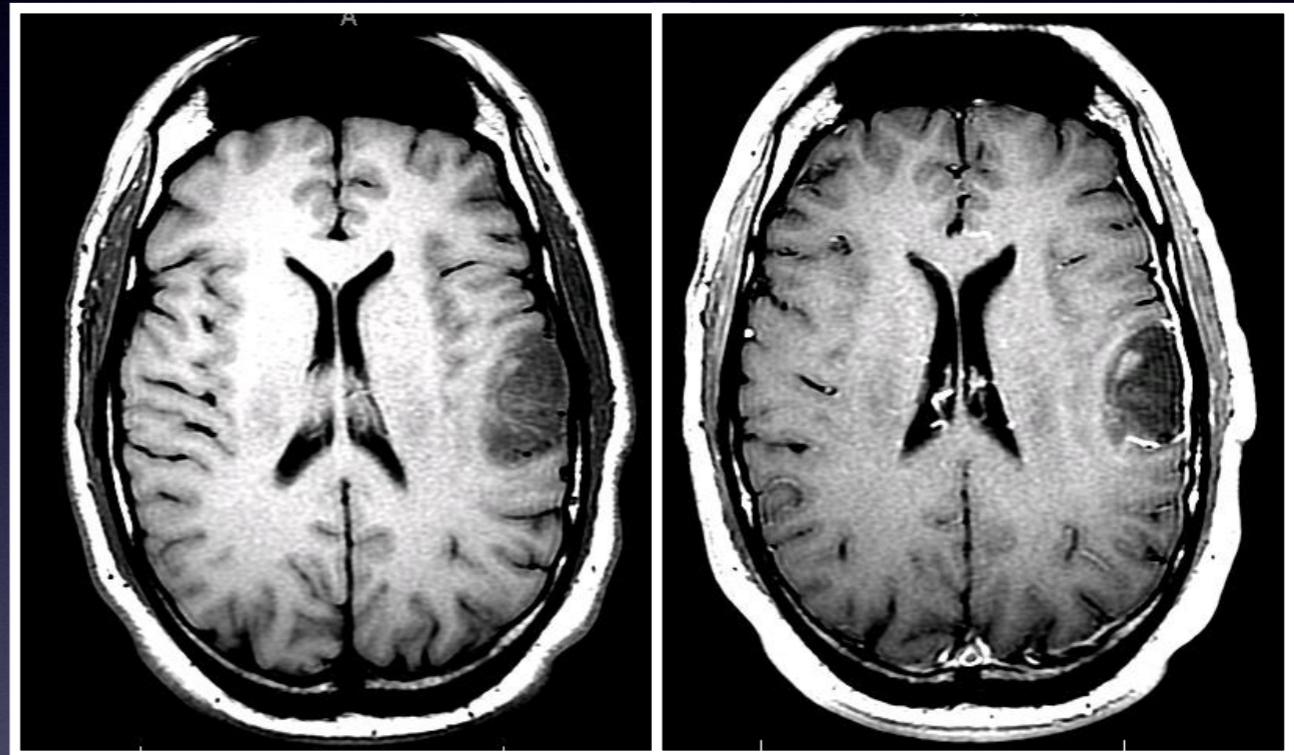
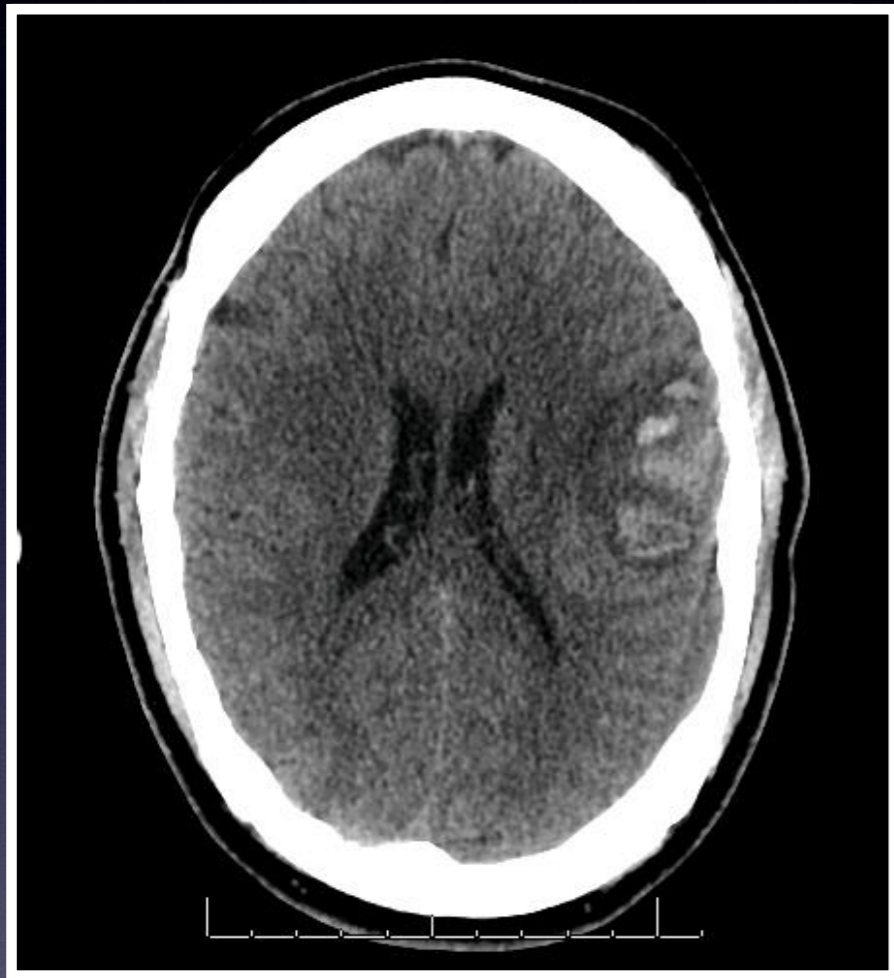# LOBAR HEMORRHAGE



Frontal hemorrhagic metastasis – lung ca

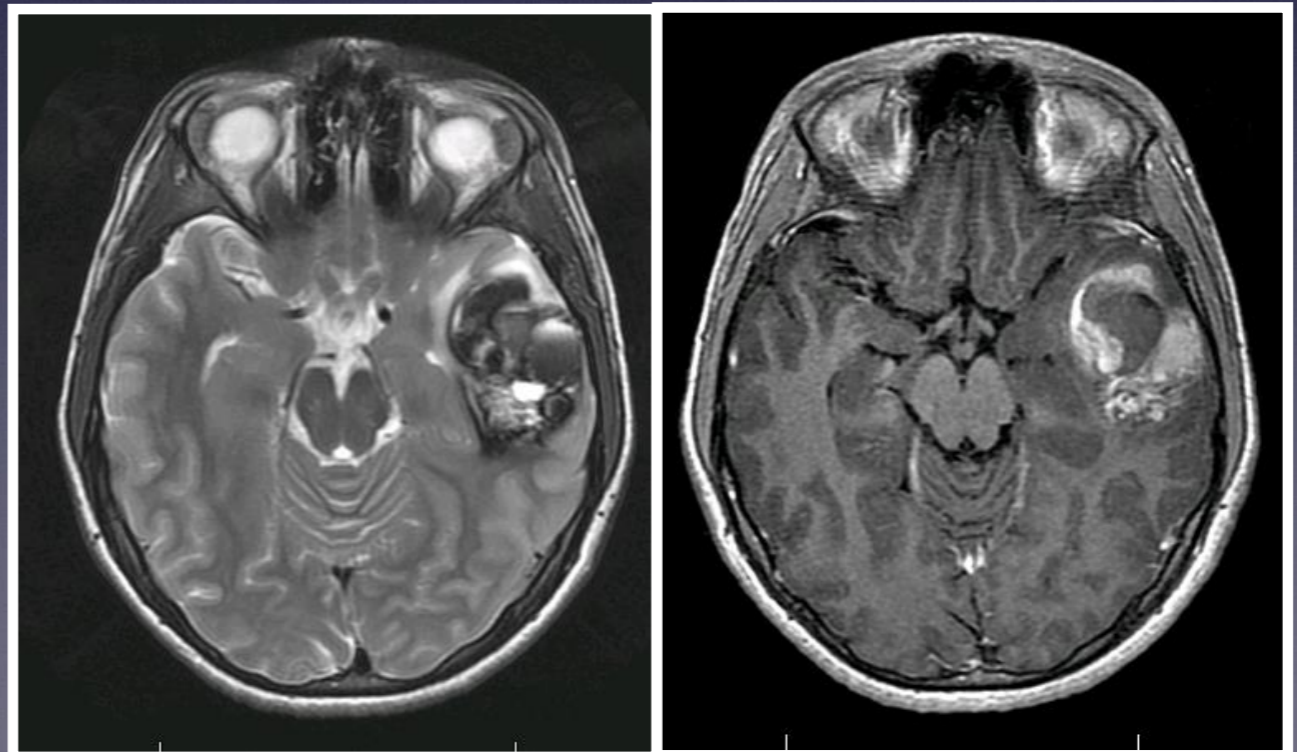
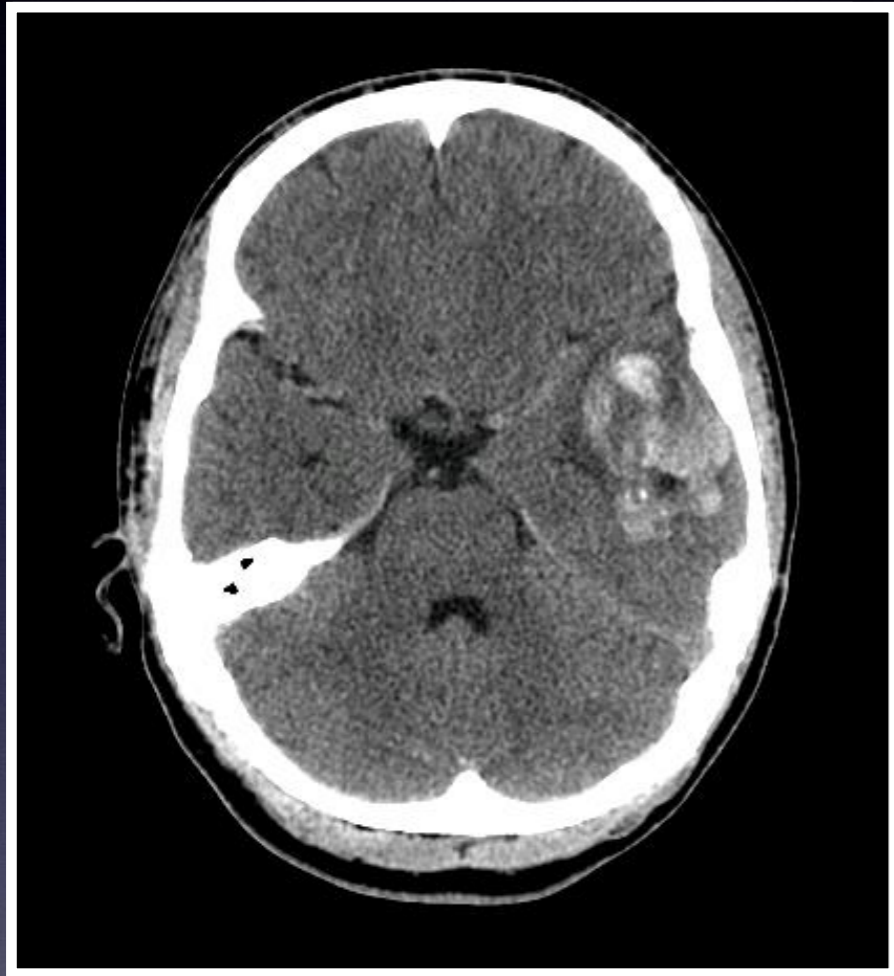

# LOBAR HEMORRHAGE



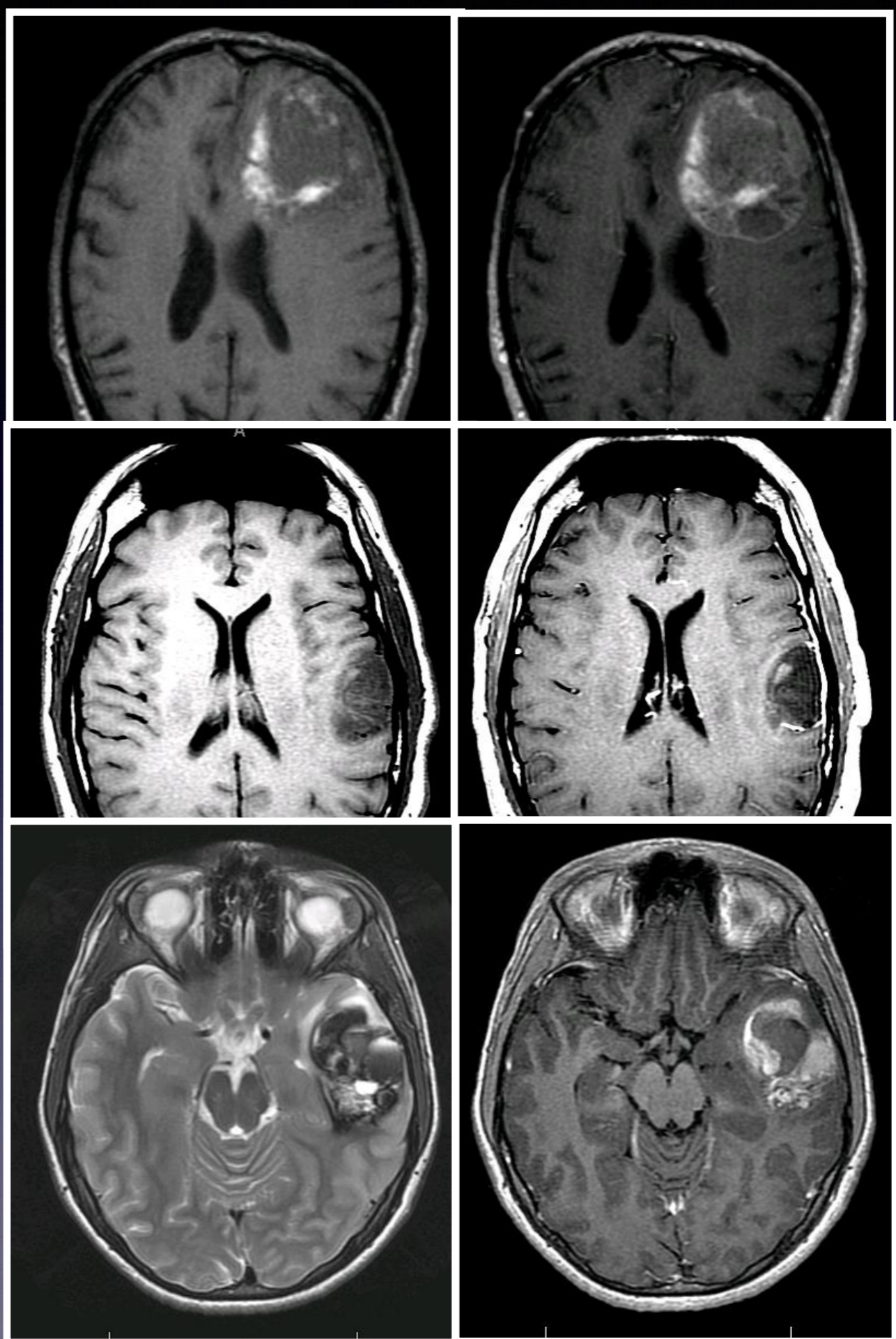
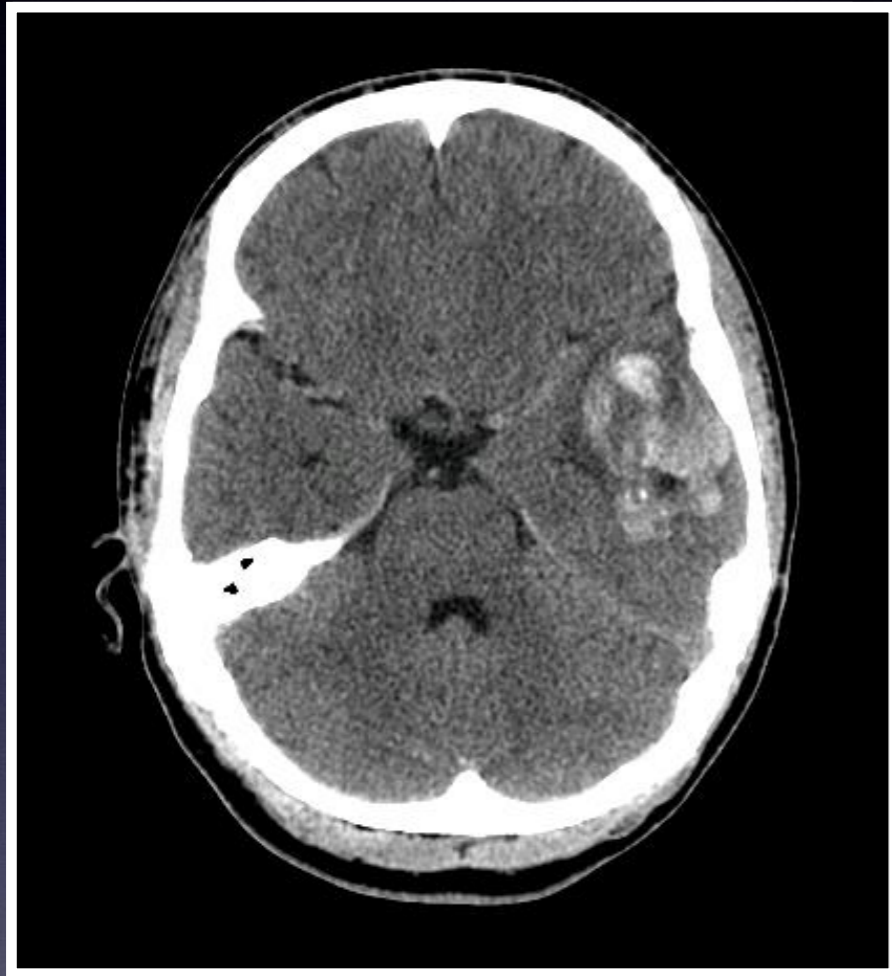Frontal hemorrhagic mass – GBM

# LOBAR HEMORRHAGE



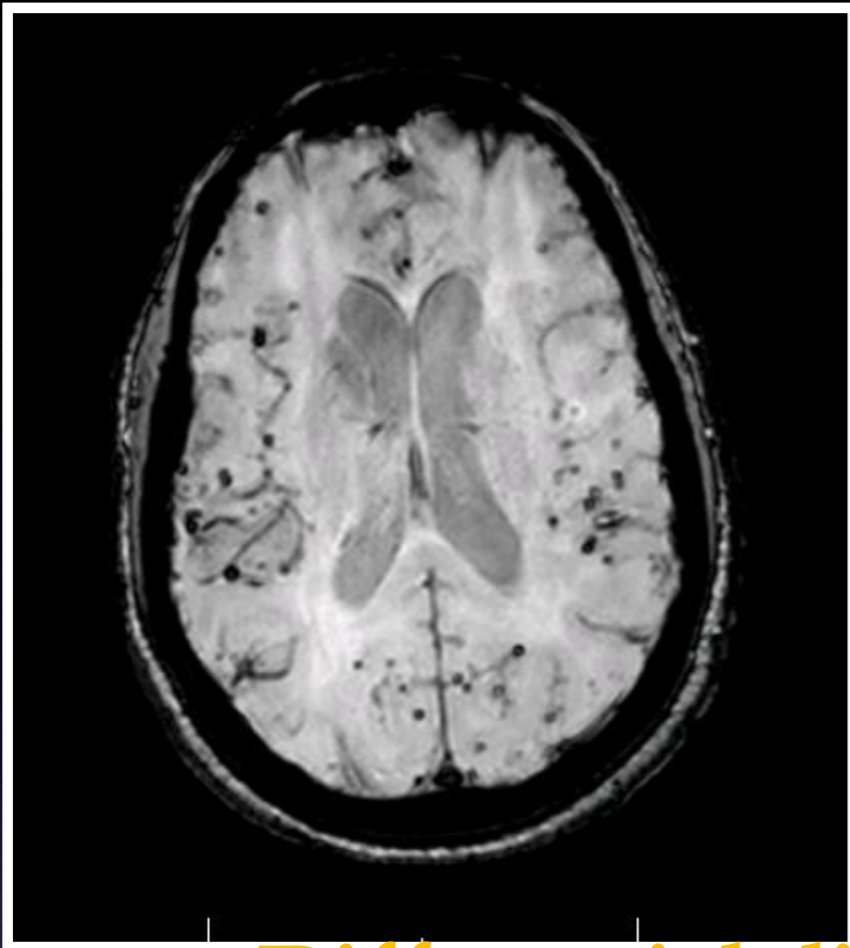
Temporal hemorrhagic mass – Cavernous mal.

# LOBAR HEMORRHAGE



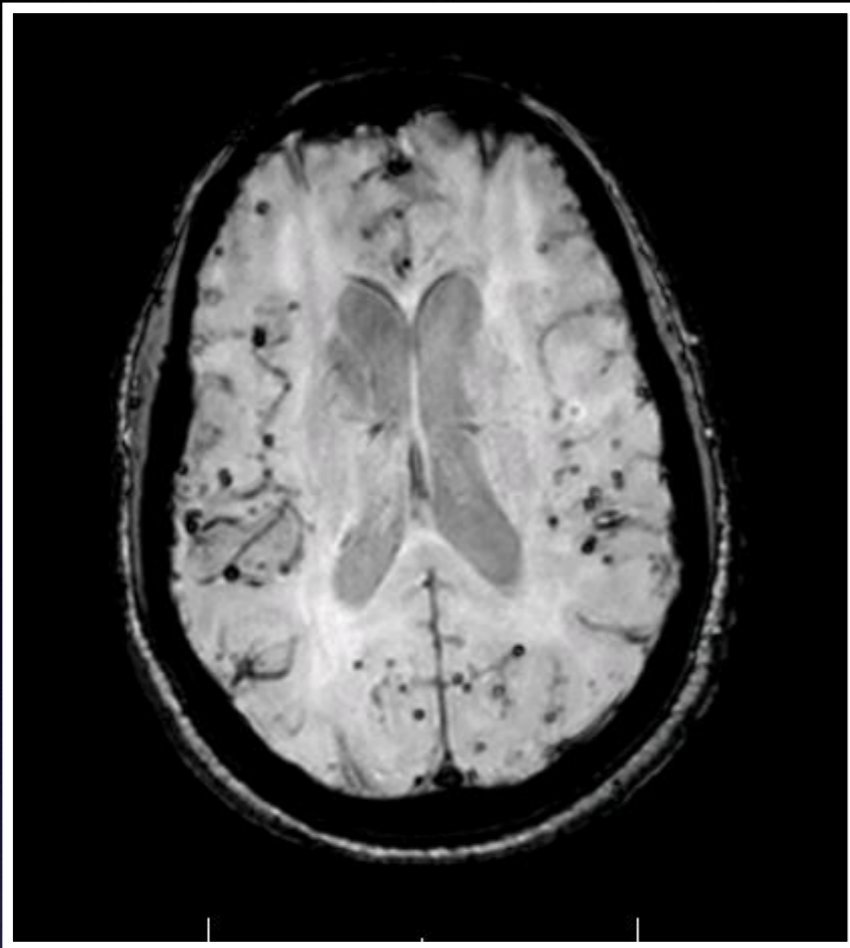
Temporal hemorrhagic mass – Cavernous mal.

# Microbleeds

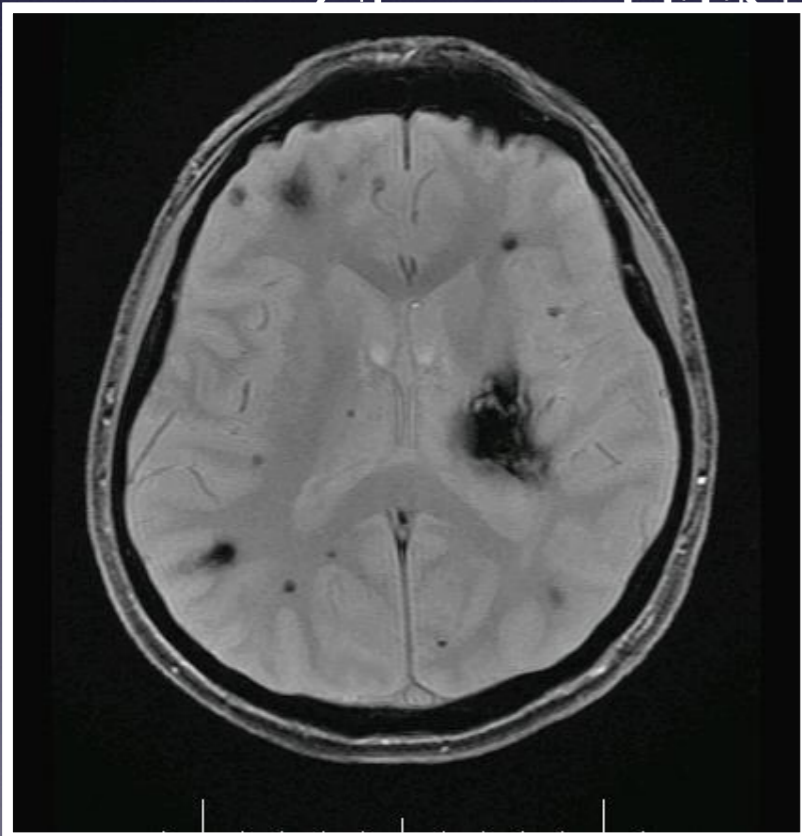


- **Differential diagnosis:**
  - Chronic HTN encephalopathy
  - Cerebral amyloid angiopathy
  - Hemorrhagic metastasis

# Microbleeds



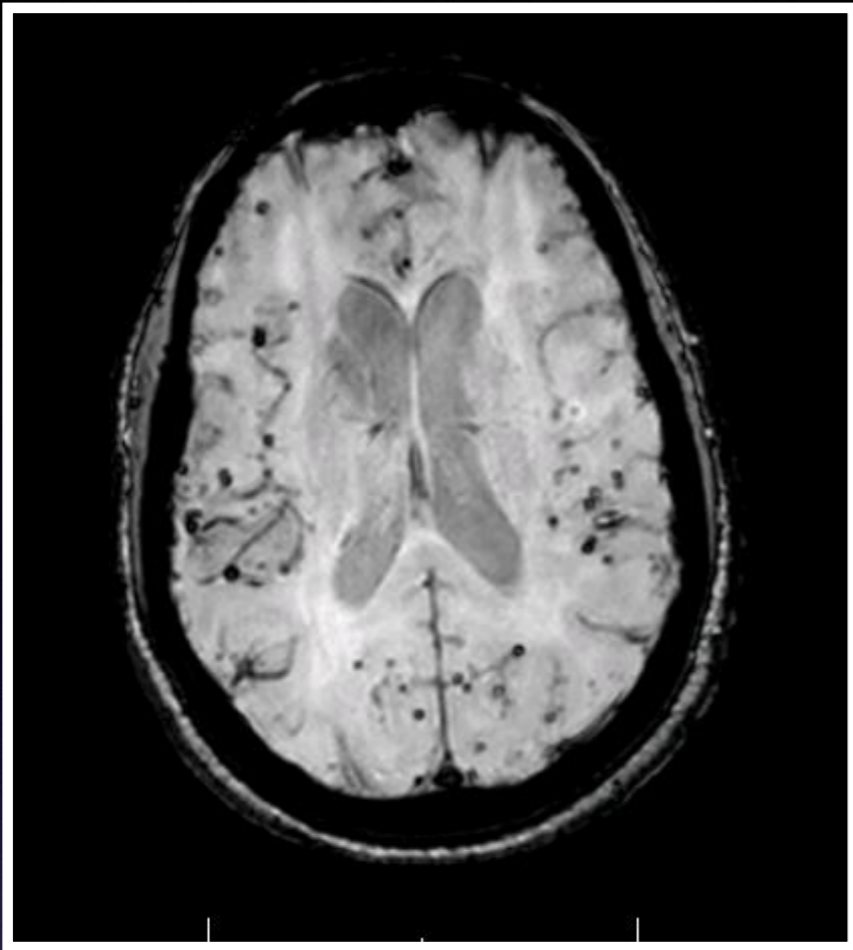
**agnosis:**



Familial cav. mal.

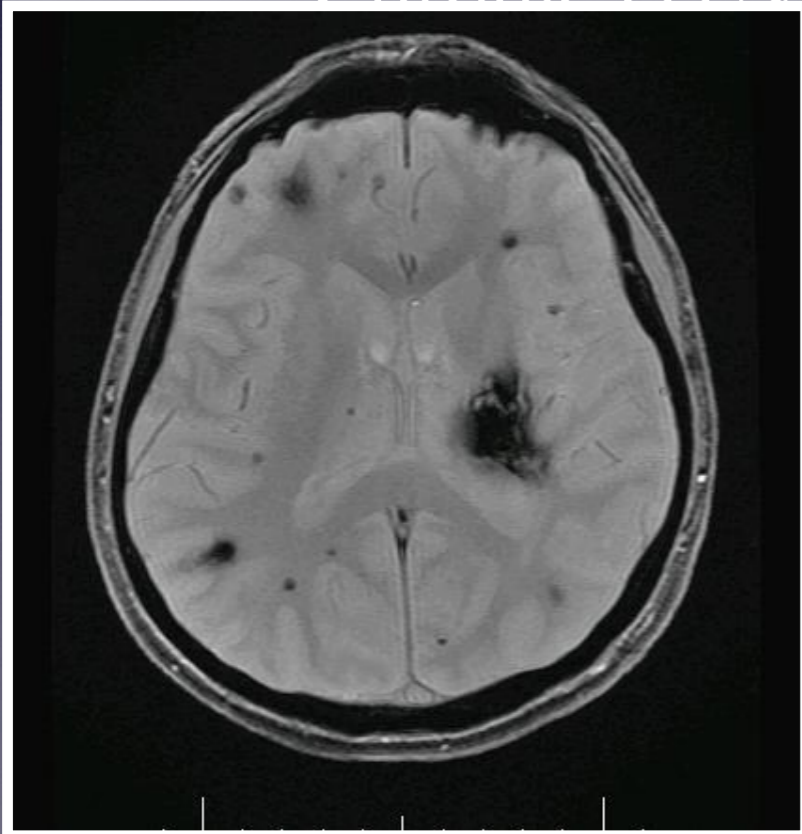
encephalopathy  
oid angiopathy  
metastasis  
cavernous malformations

# Microbleeds

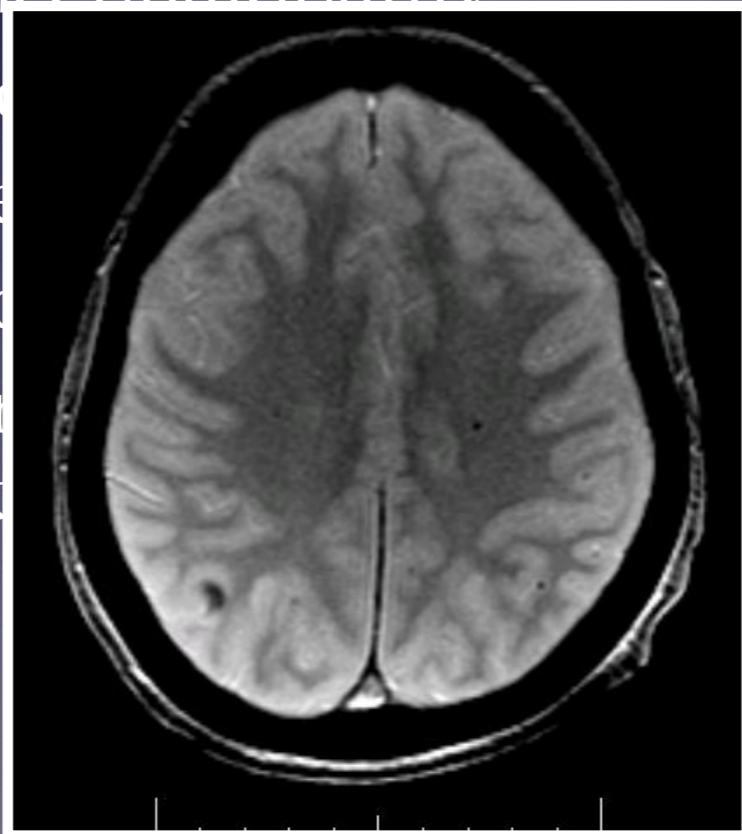


agnosis:

- Chronic HTN encephalopathy



Familial cav. mal.

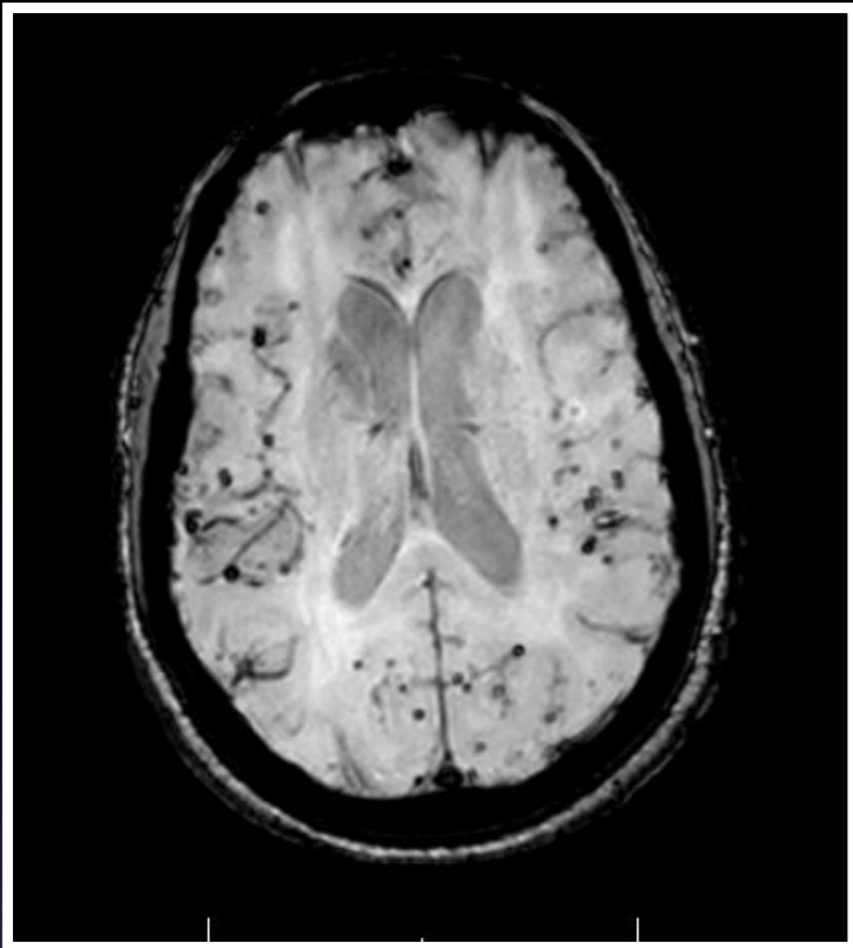


E.Coli sepsis

oid  
me  
rno  
ic  
uk

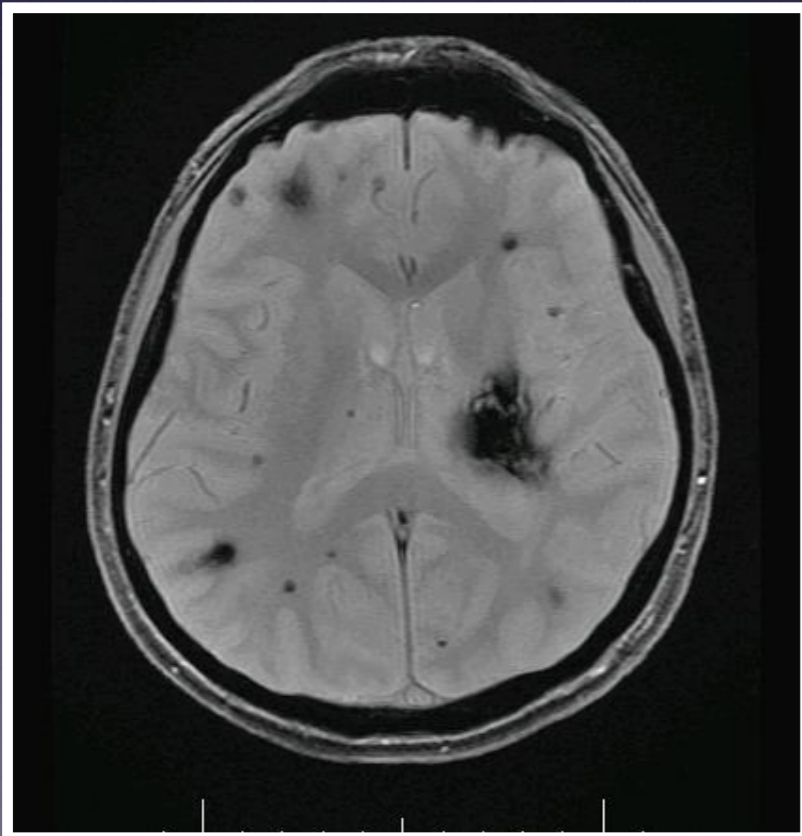
TTP/HUS,

# Microbleeds

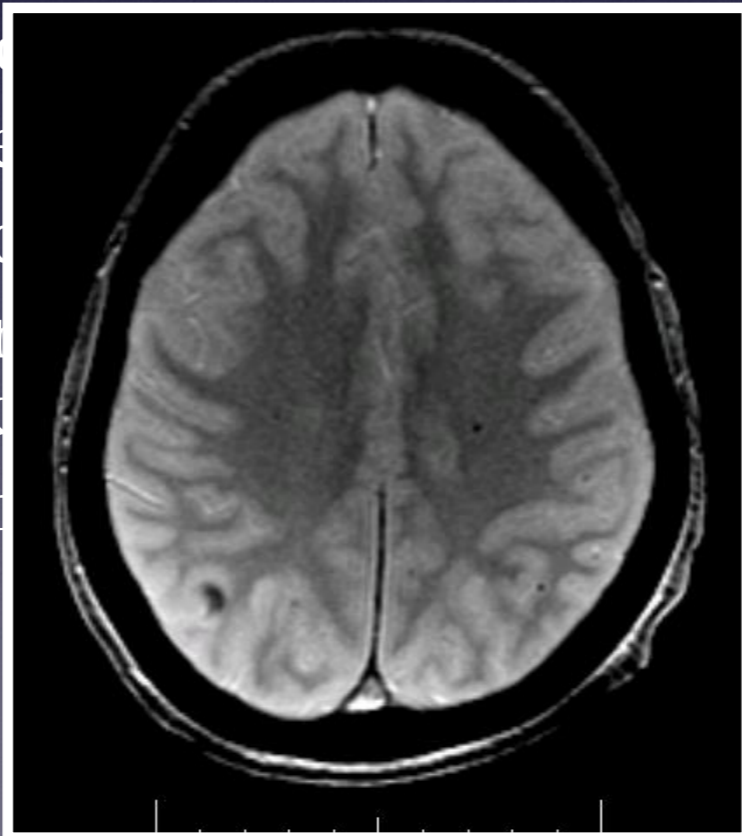


**agnosis:**

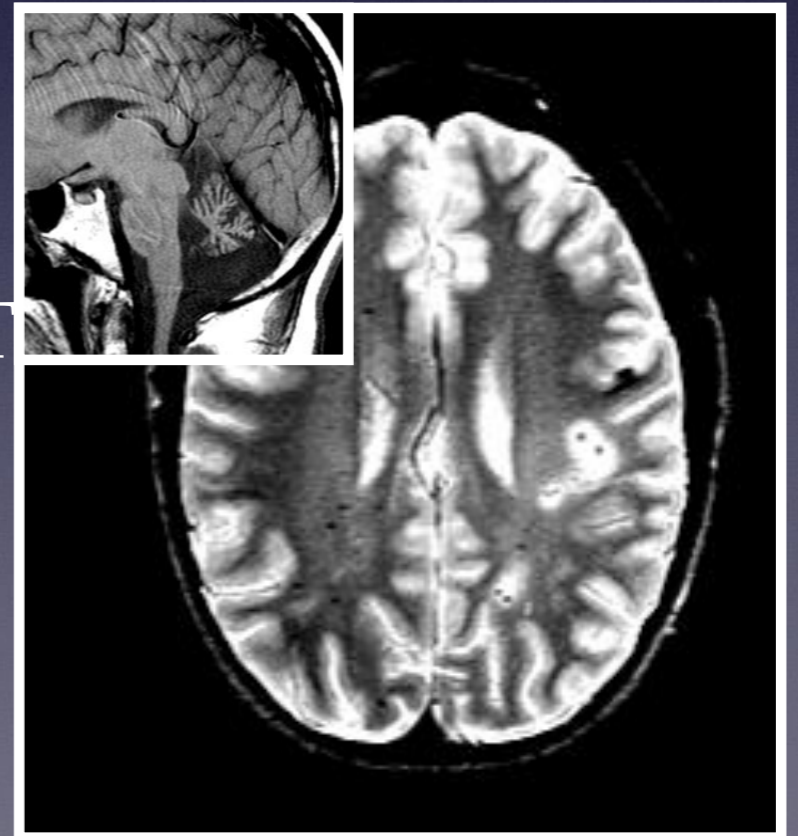- Chronic HTN encephalopathy



Familial cav. mal.

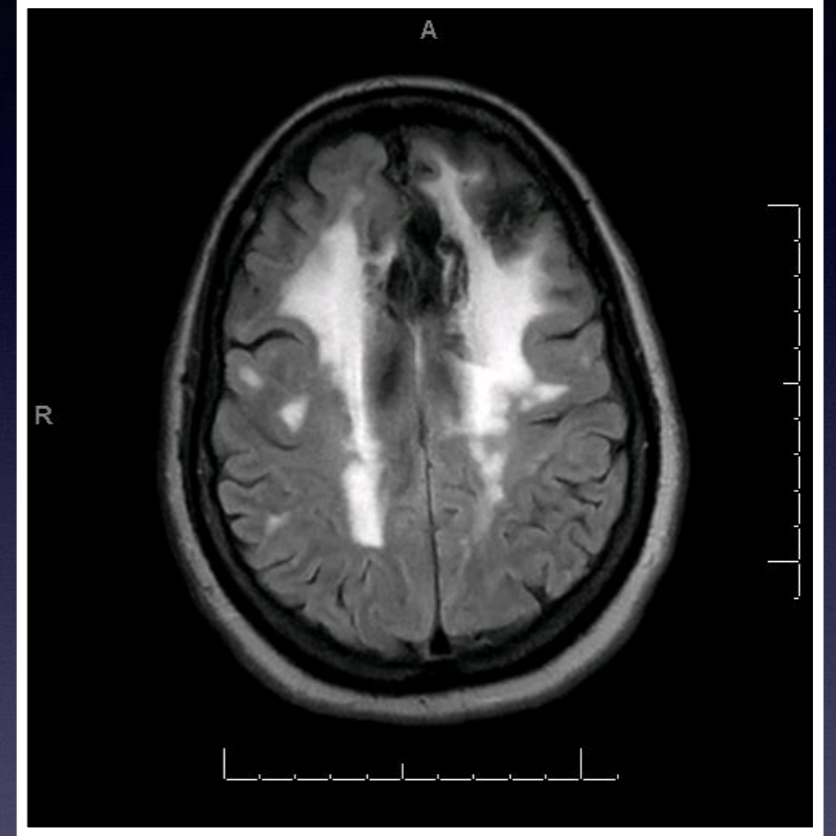
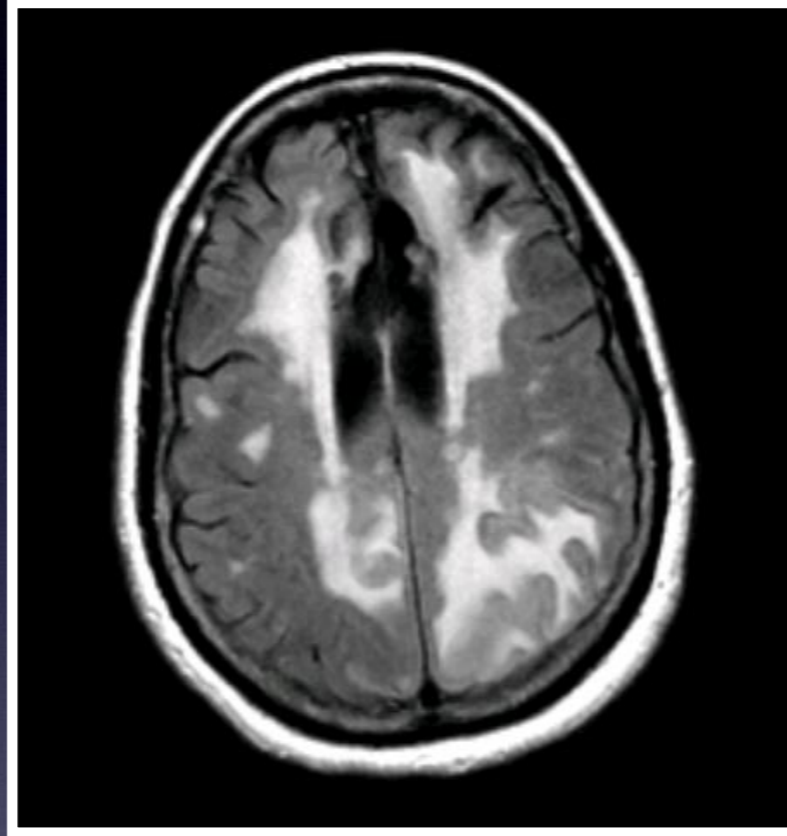
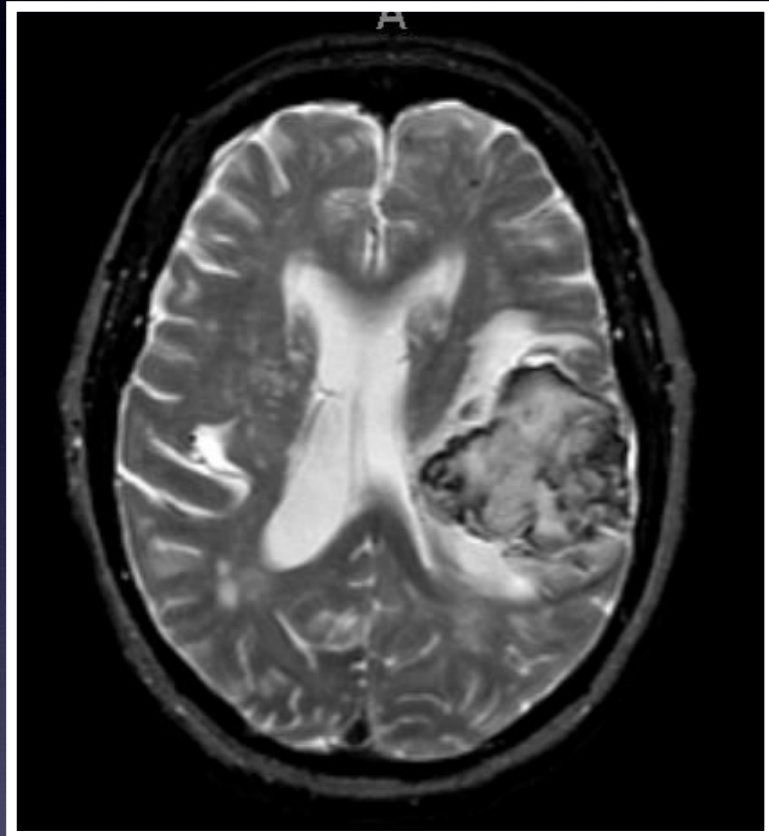


E.Coli sepsis



Ataxia-telangiectasia syndrome

# Amyloid angiopathy



## Cerebral amyloid disease

- Arterial wall deposition A $\beta$  fibrils
  - Major lobar hemorrhages
- Cortical petechial hemorrhages
- Small cerebral infarcts, microbleeds
  - White matter ischemic lesions

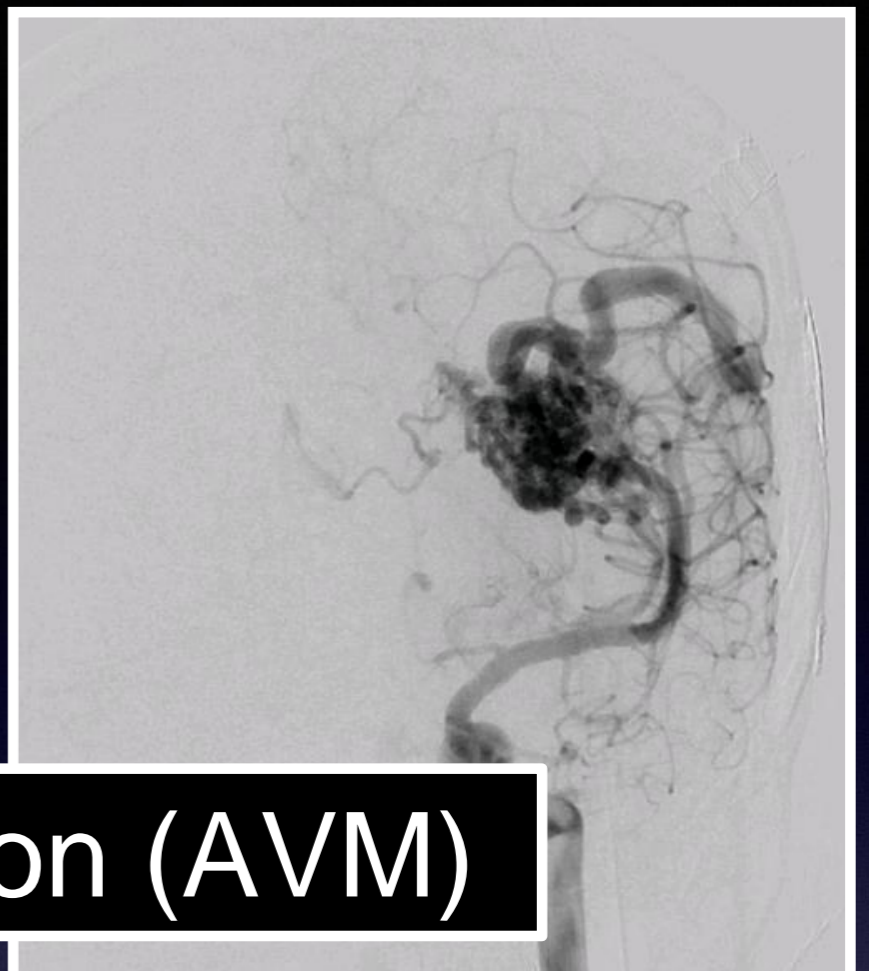
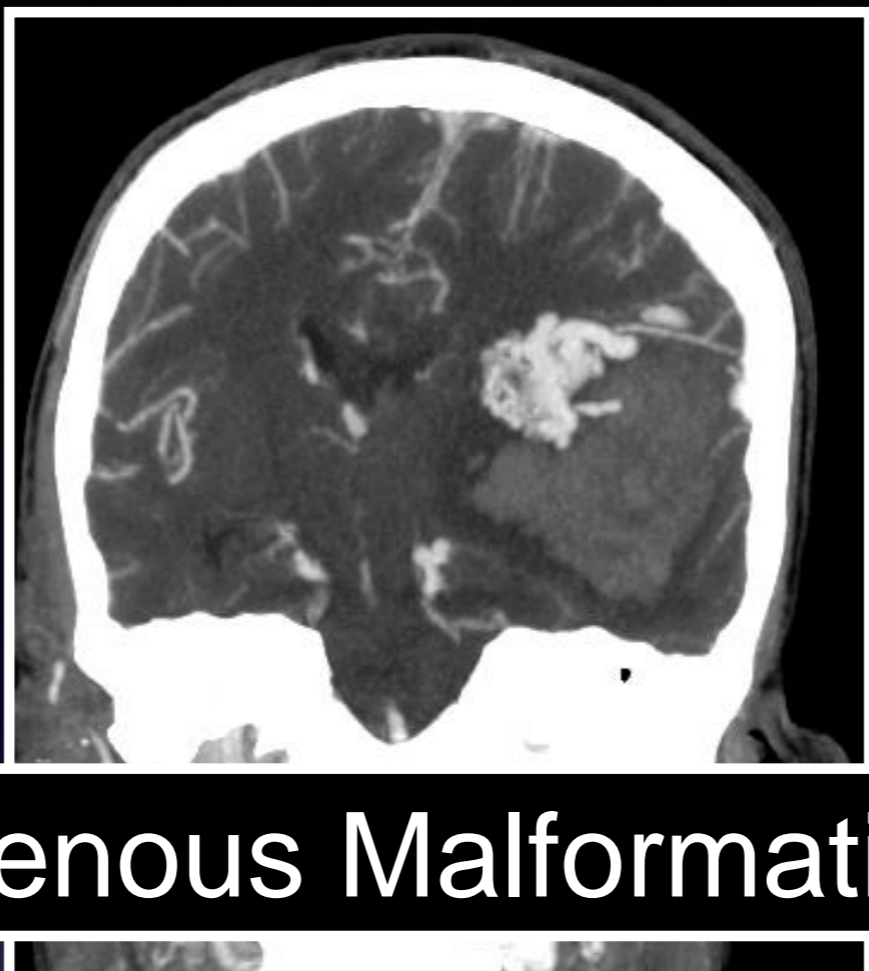
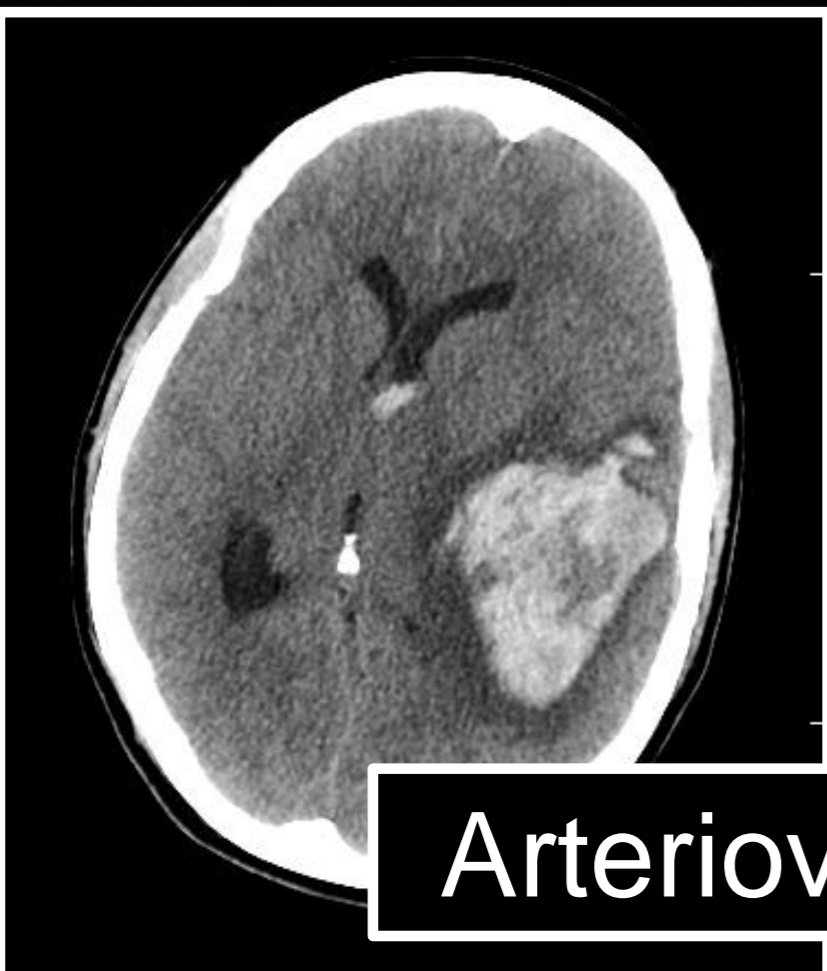## Amyloid $\beta$ -related angiitis (ABRA)

- White matter lesions predominate
  - Inflammatory component
  - Responds to steroids

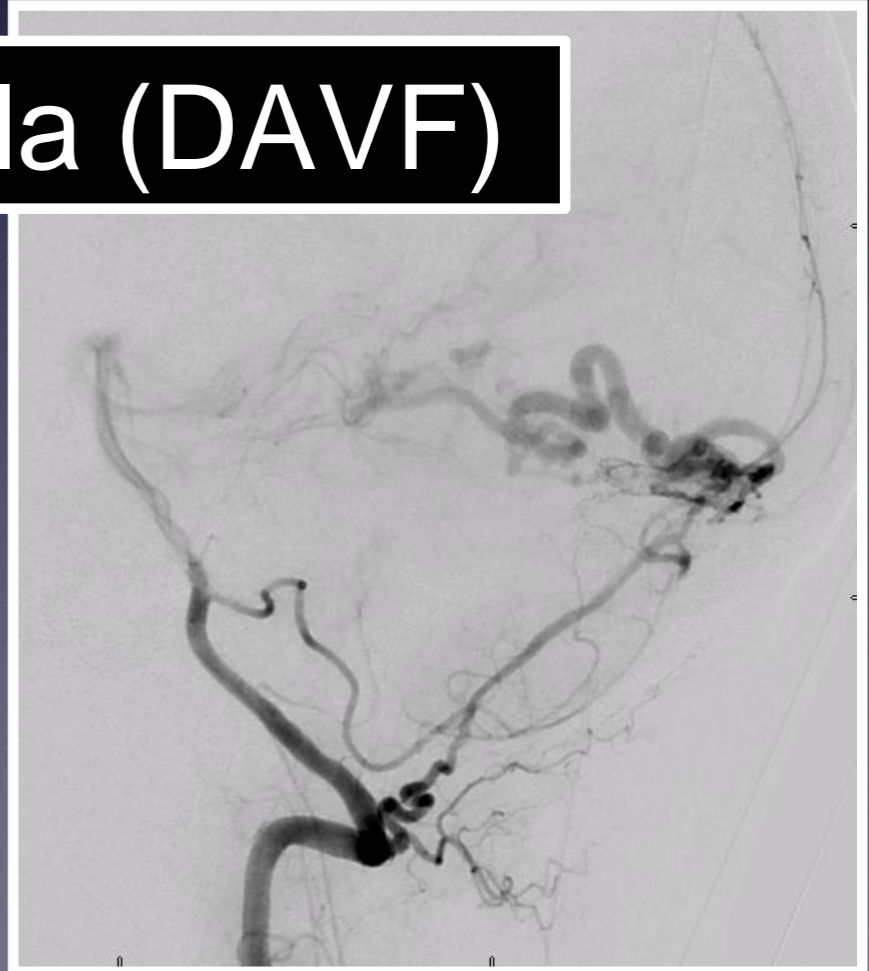
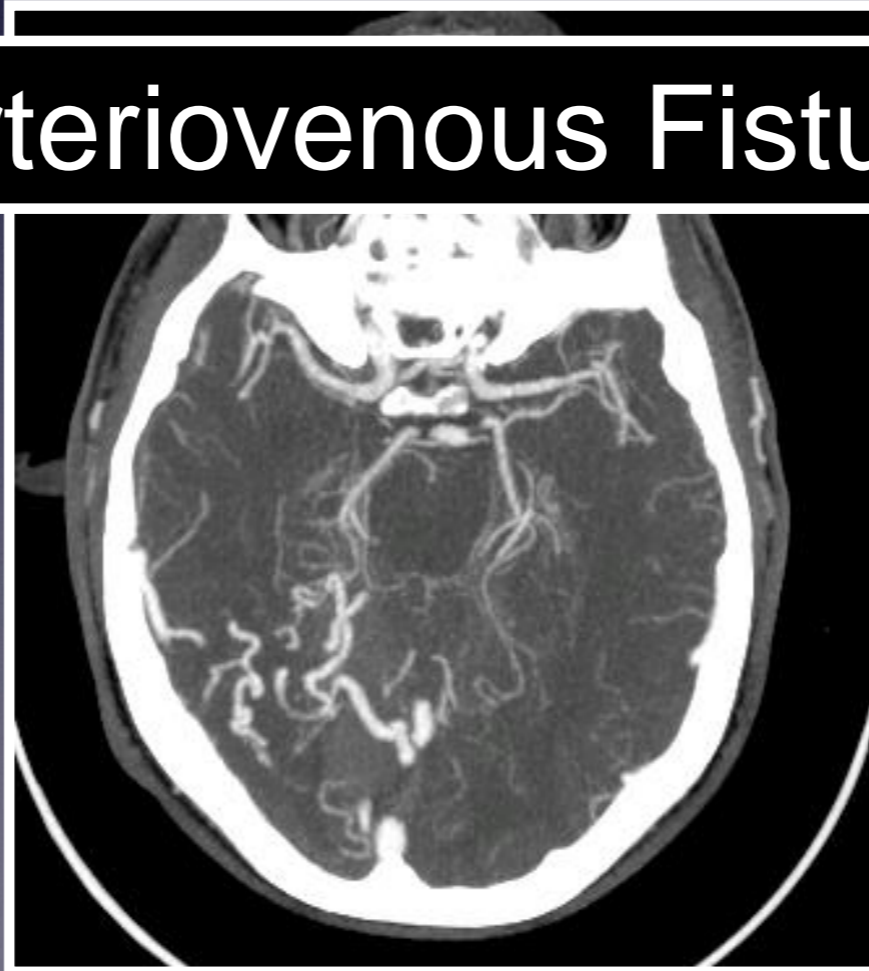
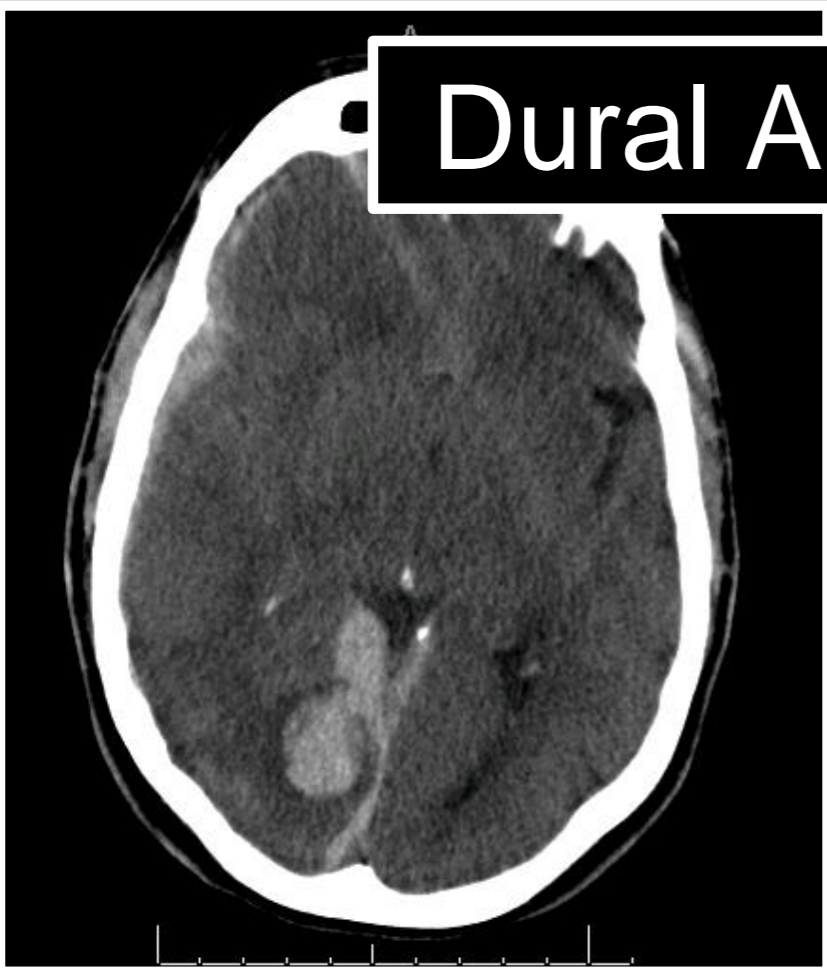


# Cerebrovascular malformations

- **With AV Shunts**
  - AVM
  - Dural AV fistula
  - Vein of Galen malformation
- ▣ **Without AV shunt**
  - ▣ Cavernous malformations
  - ▣ Developmental venous anomaly
    - ▣ Sinus pericranii
    - ▣ Capillary teleangiectasia

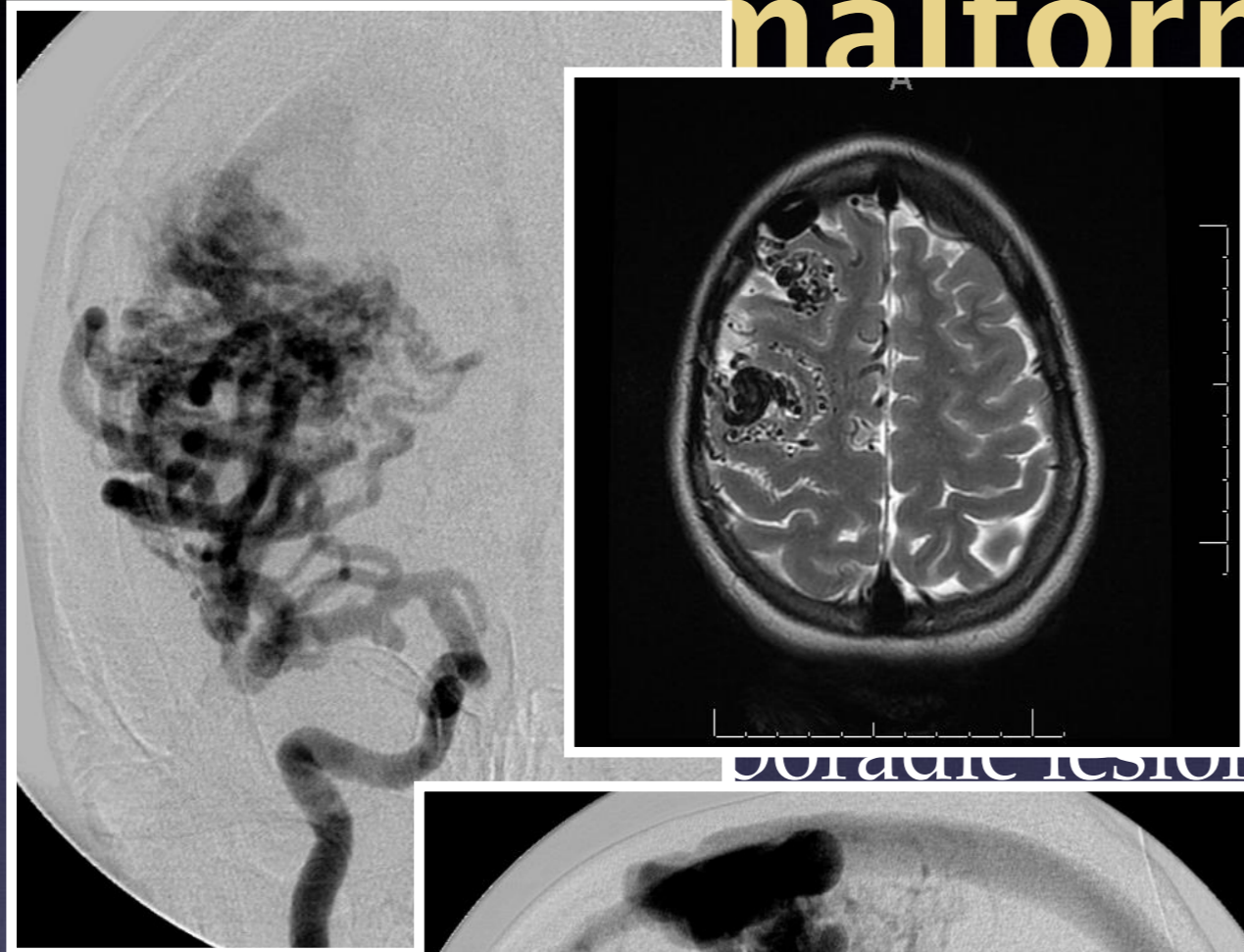

**Arteriovenous Malformation (AVM)**

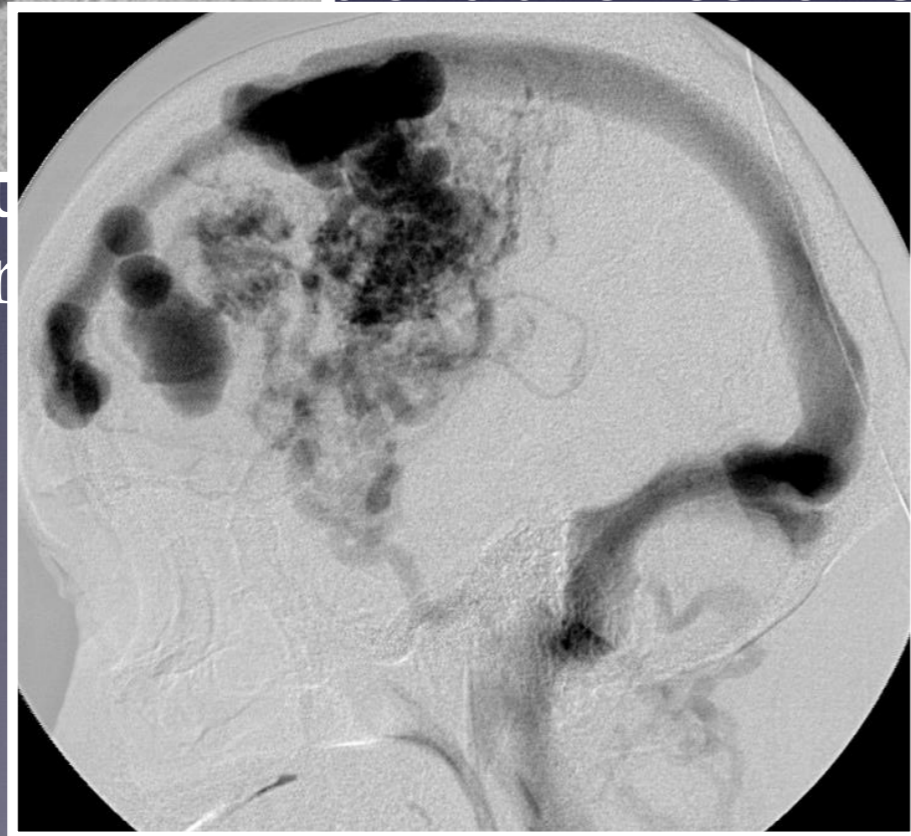

**Dural Arteriovenous Fistula (DAVF)**

# Arterio-venous malformations



- Aneurysm  
obstruction



of thin-walled vessels with  
shunting

vascular lesions

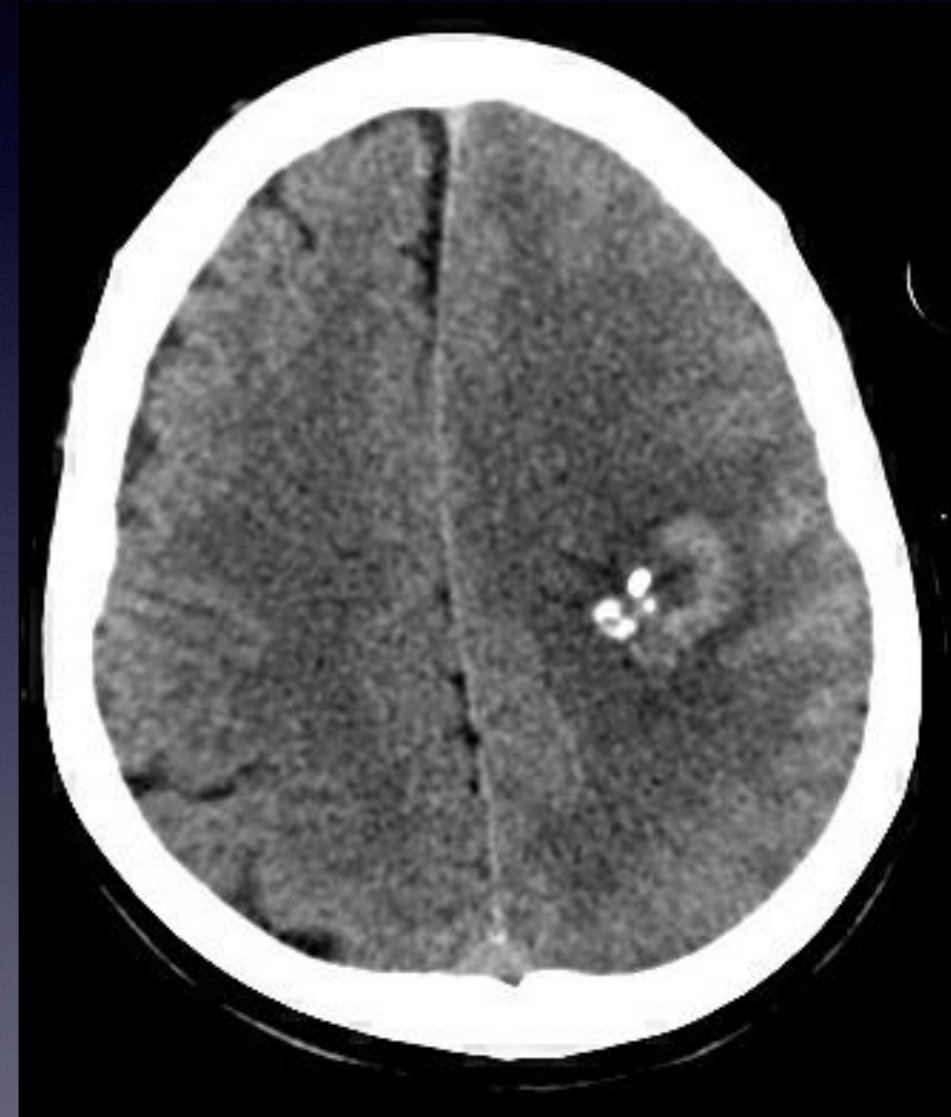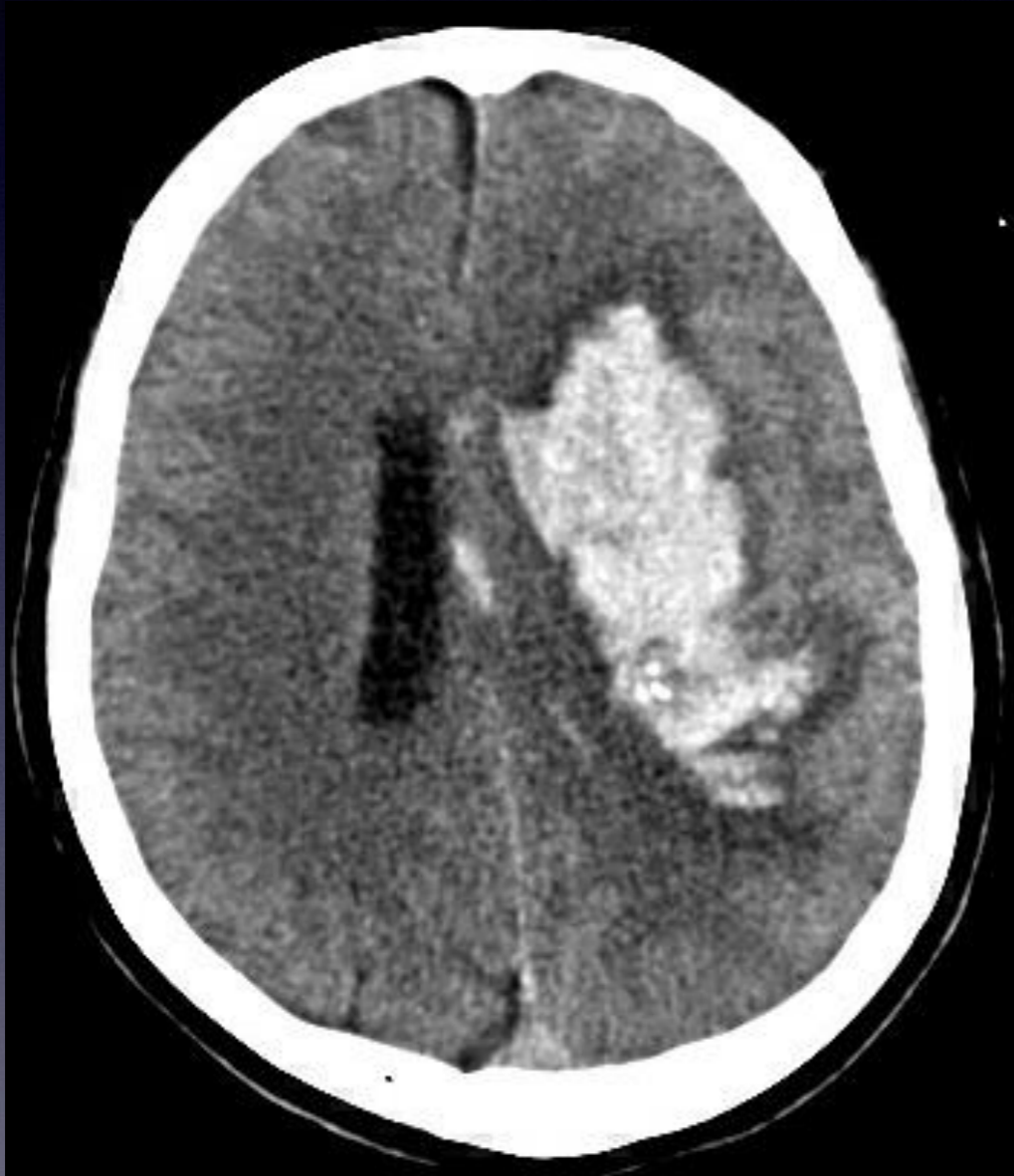year

venous outflow  
for ICH

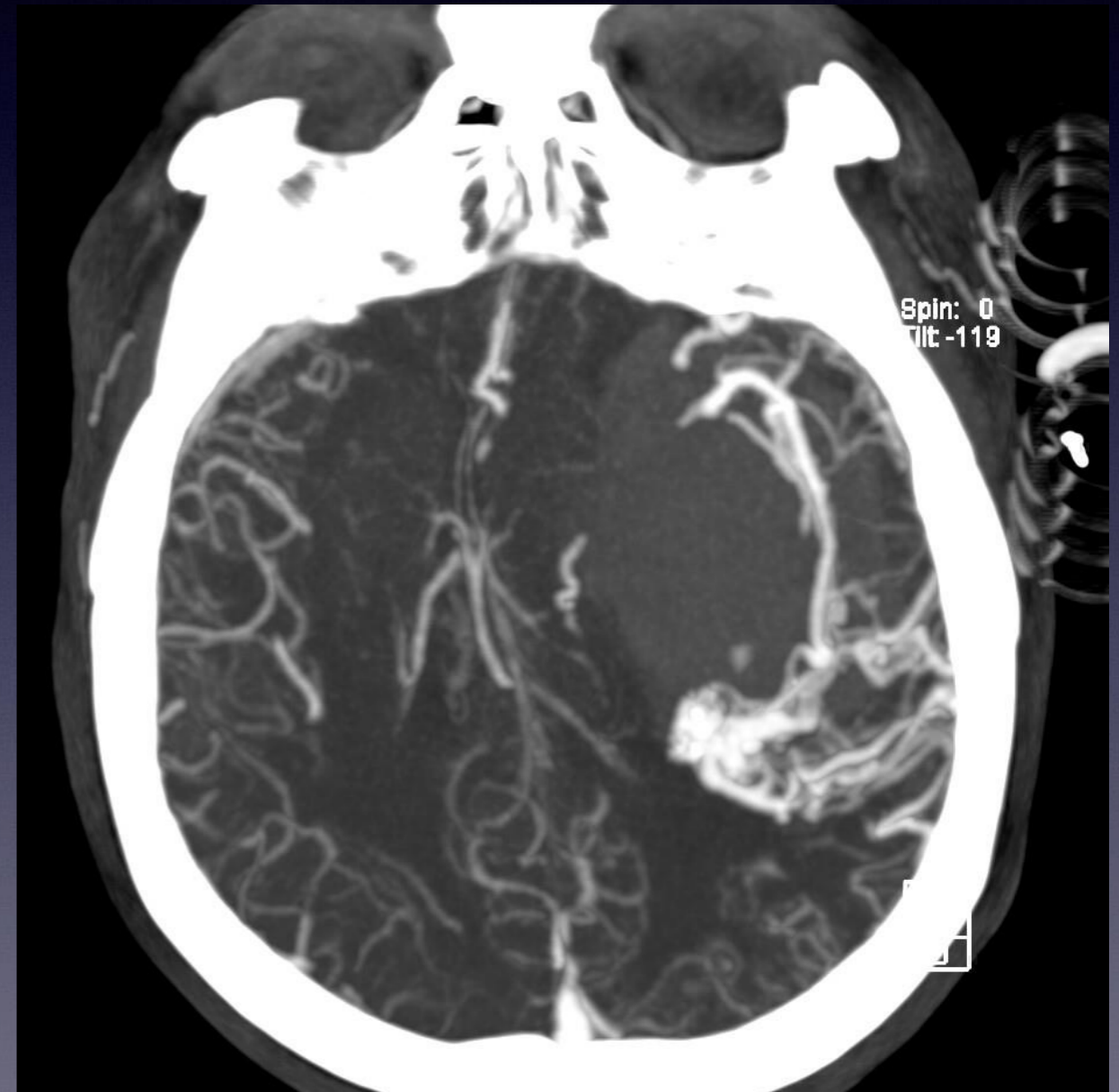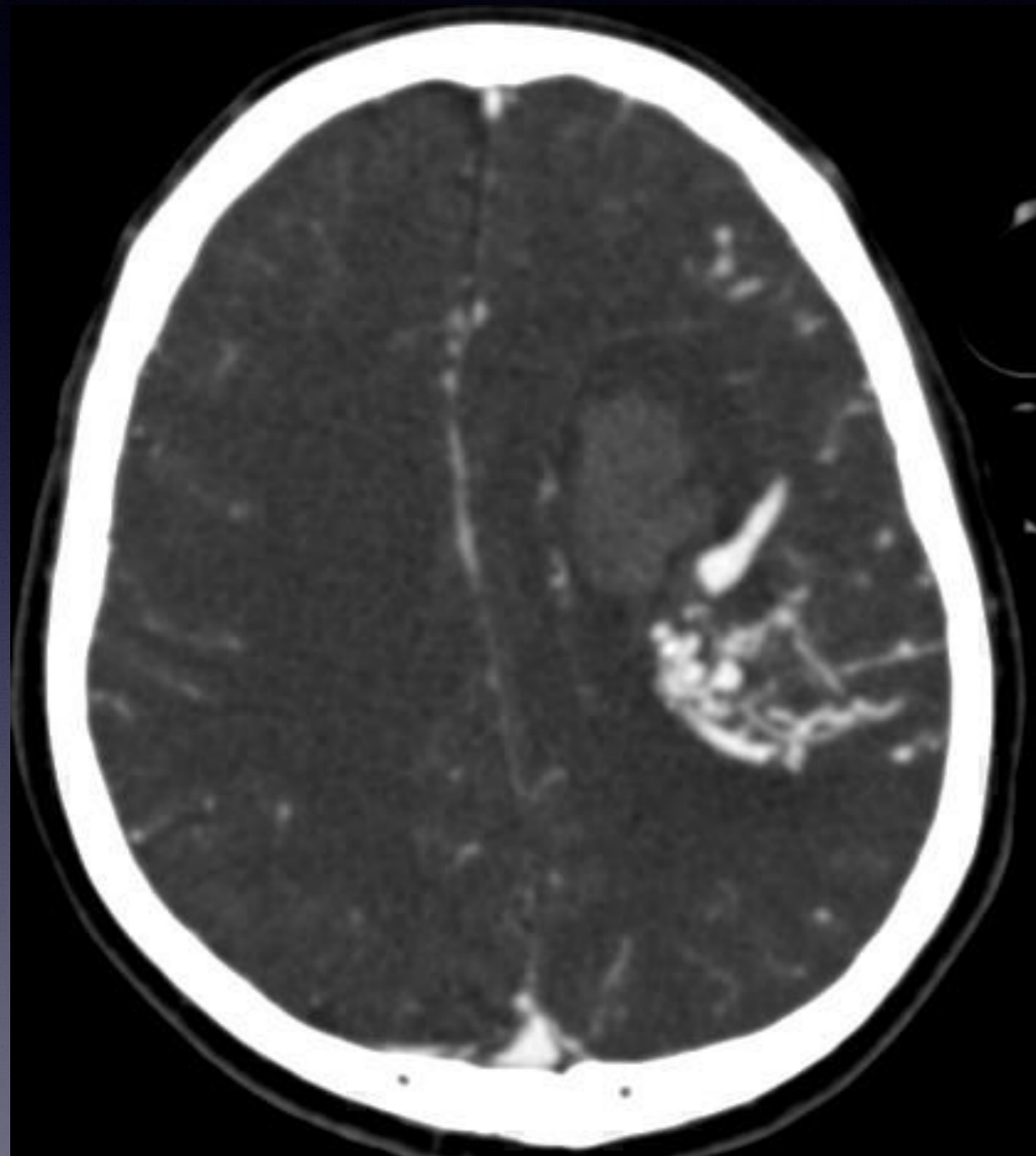
# AVM-Hemorrhage Location

- 30% SAH
- 16% IVH
- Combined location 31%
- Parenchymal 23%
  
- Hartmann et al 1998

# 45 YEAR OLD WITH HEADACHE

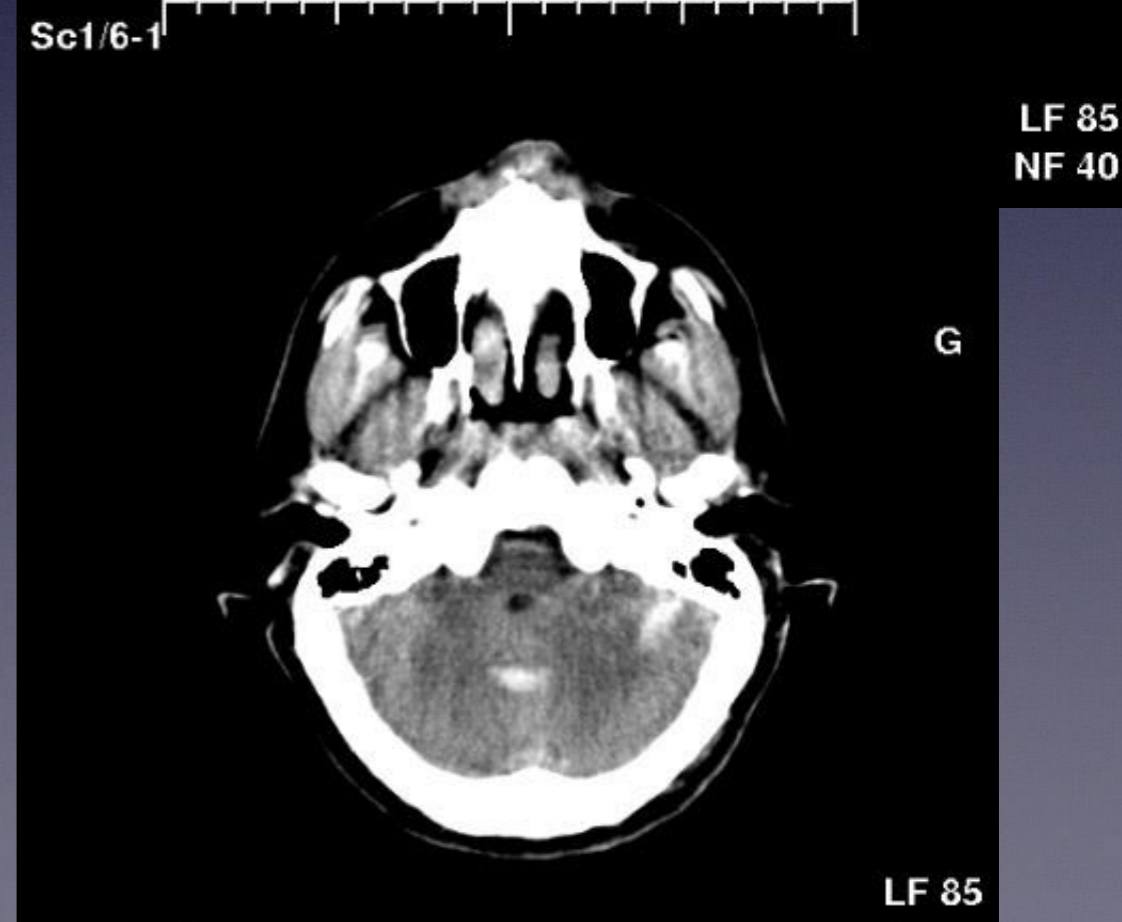
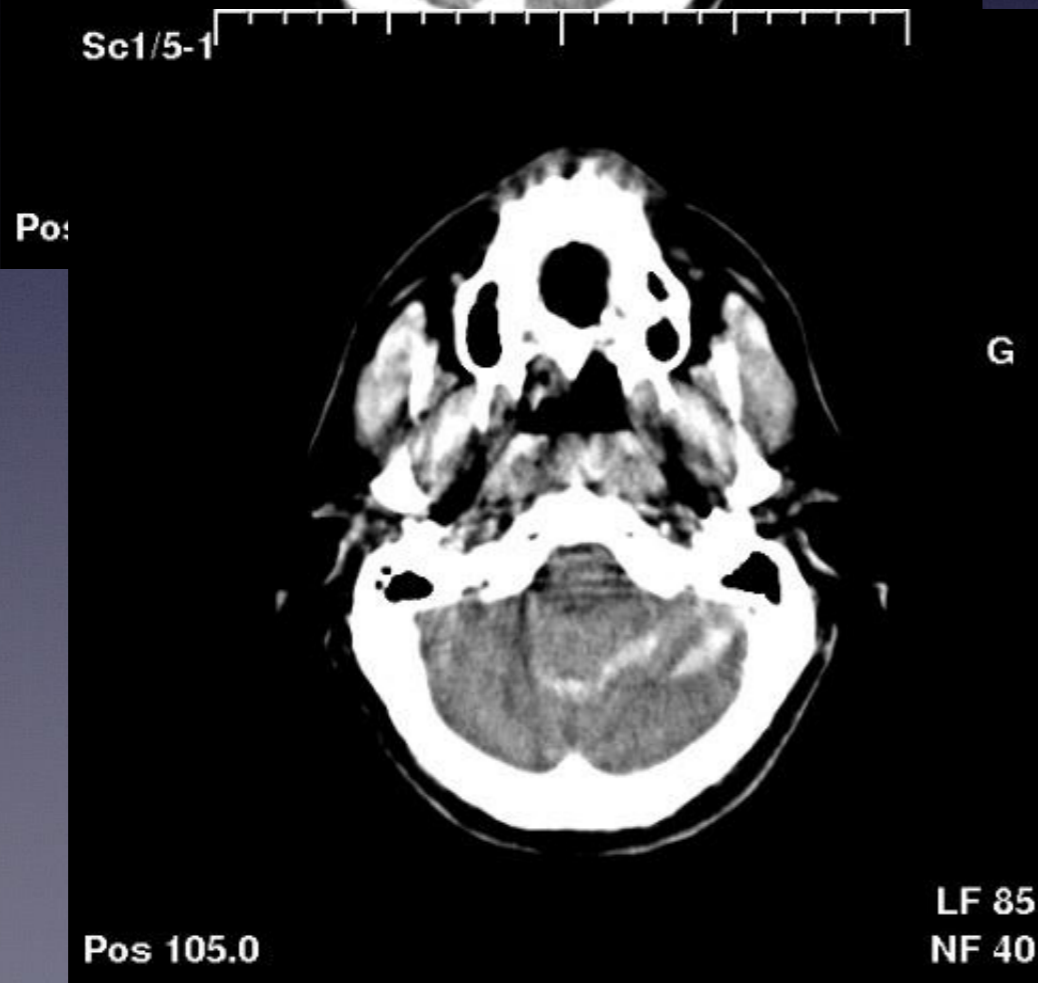
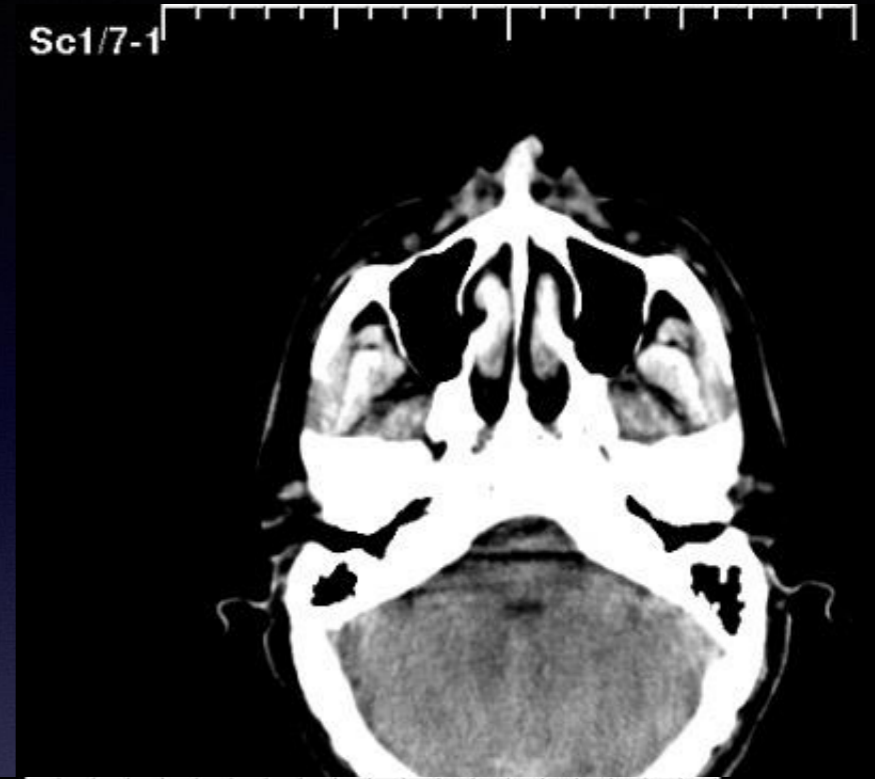
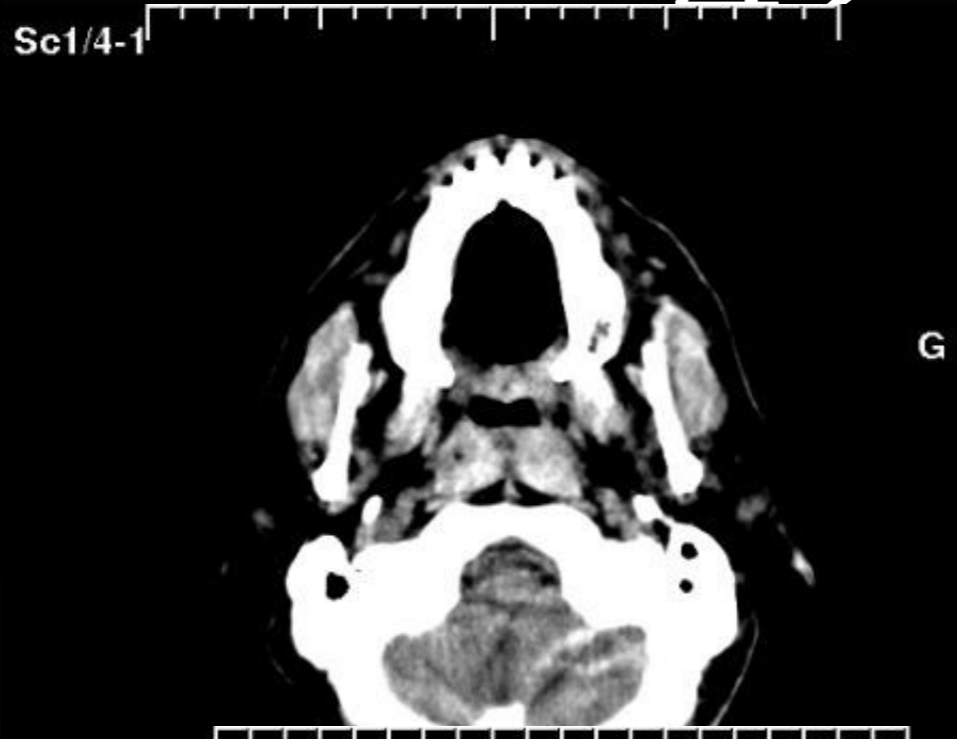


# 45 YEAR OLD WITH HEADACHE

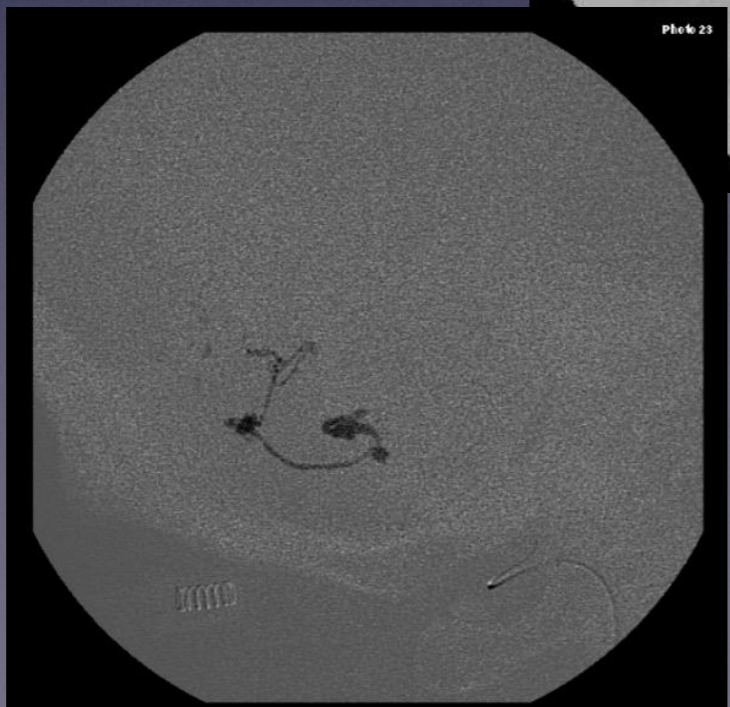
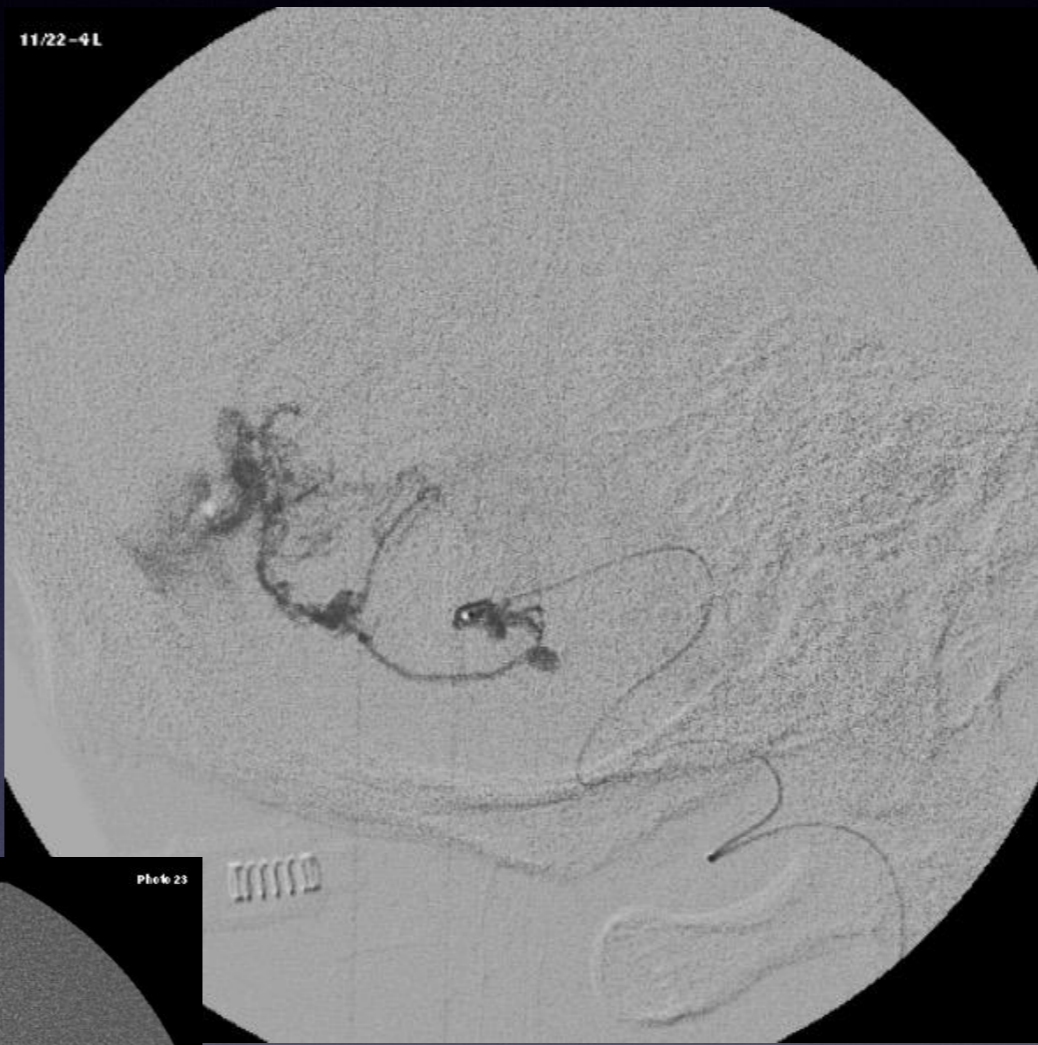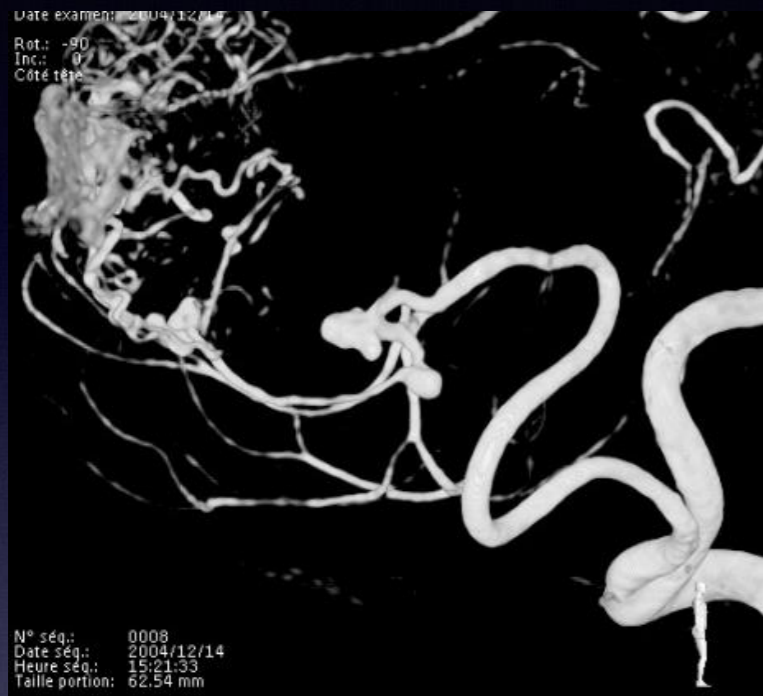




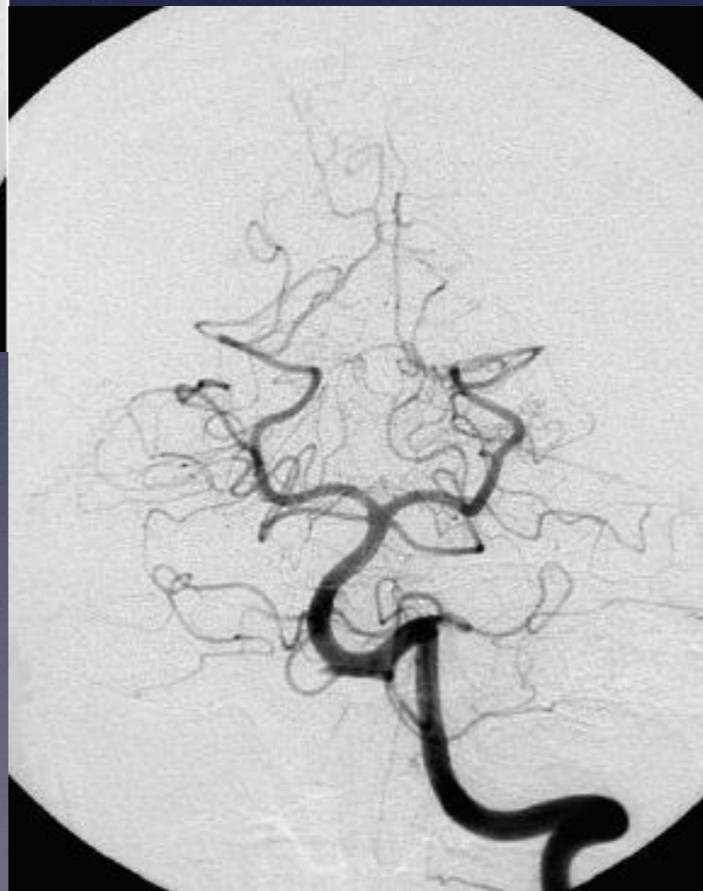
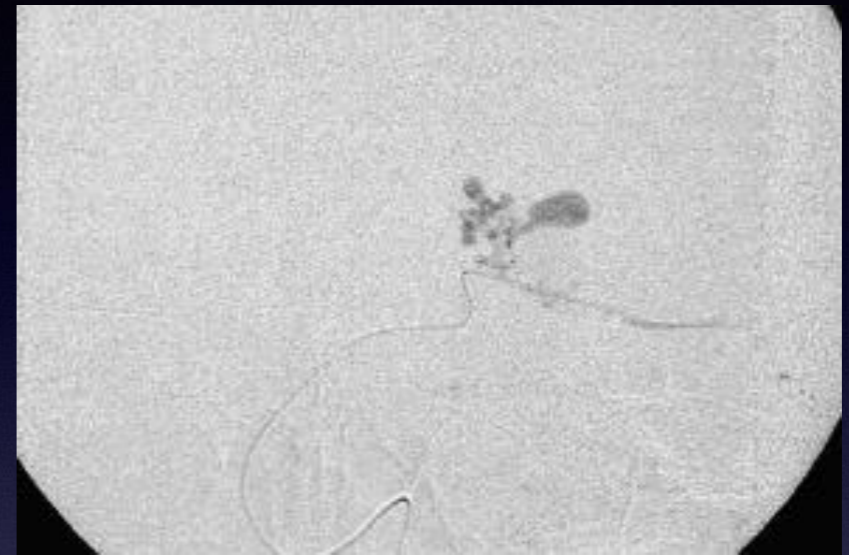
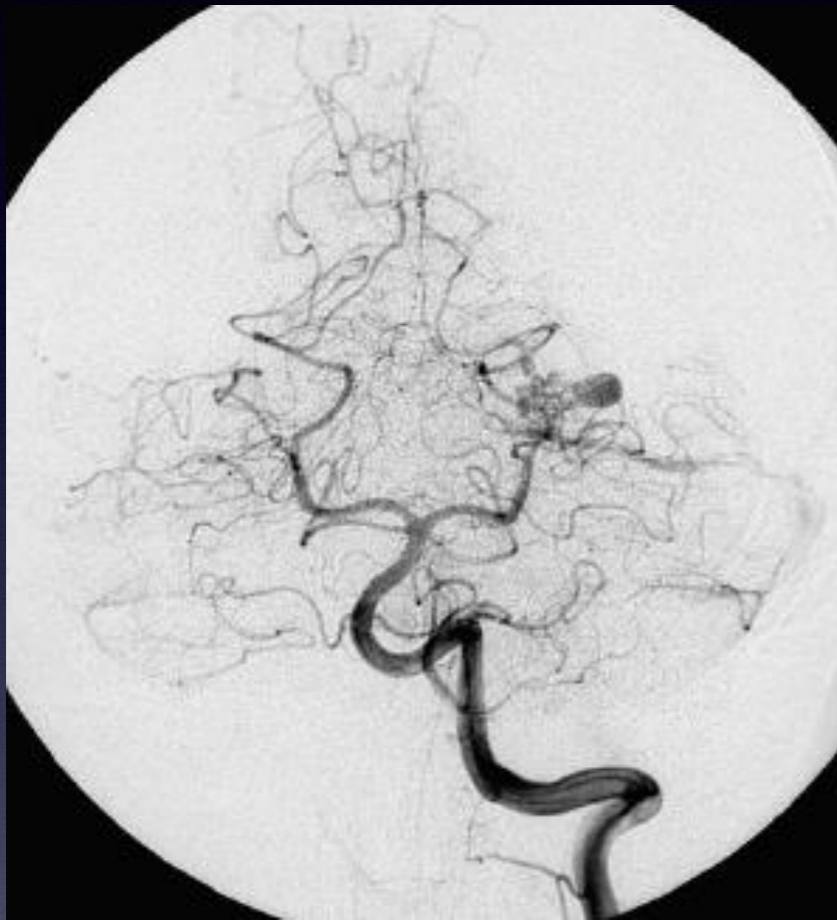# 42 SAH



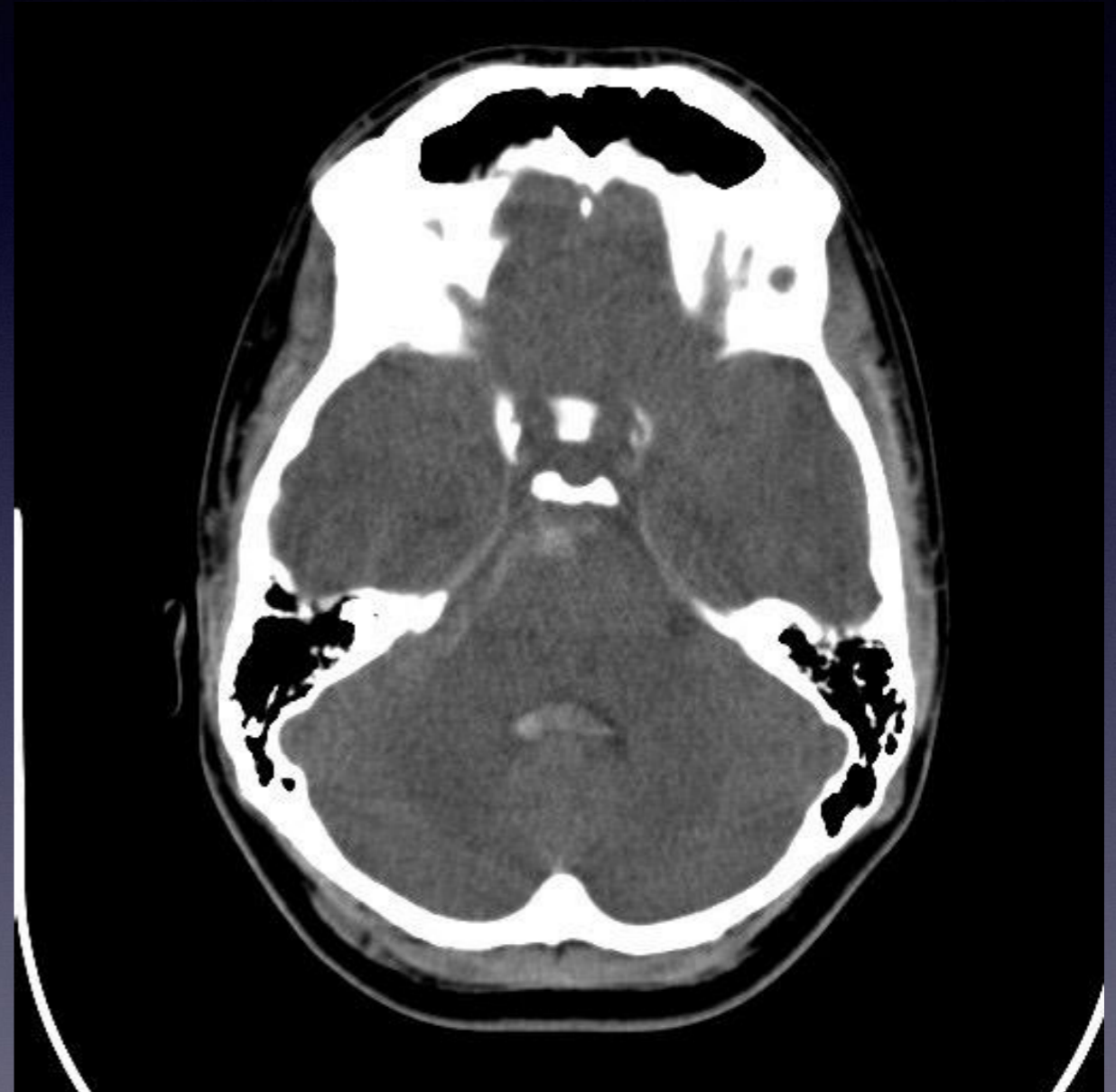
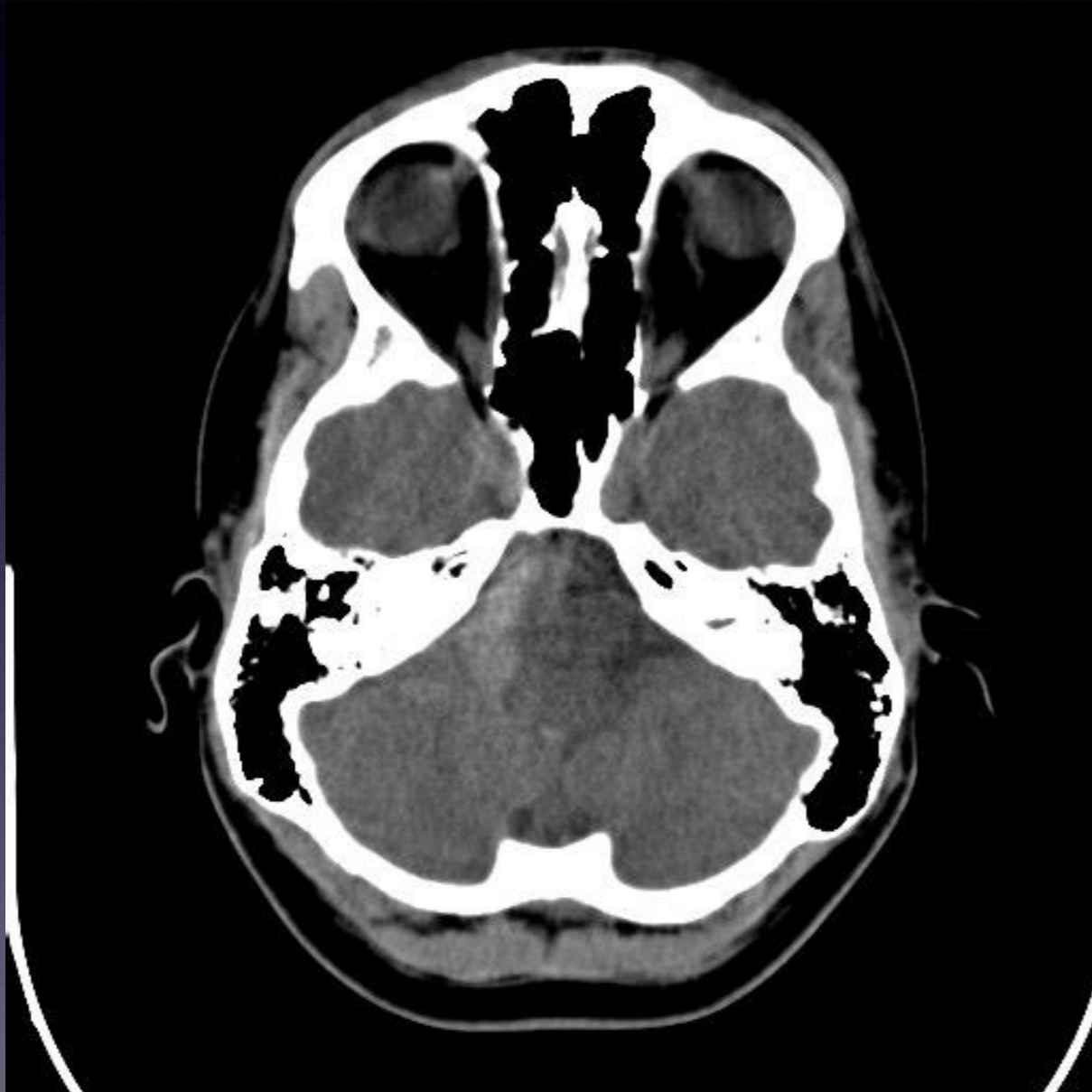



# IVH, Small AVM



# SAH HH Gr 3 22 yo male

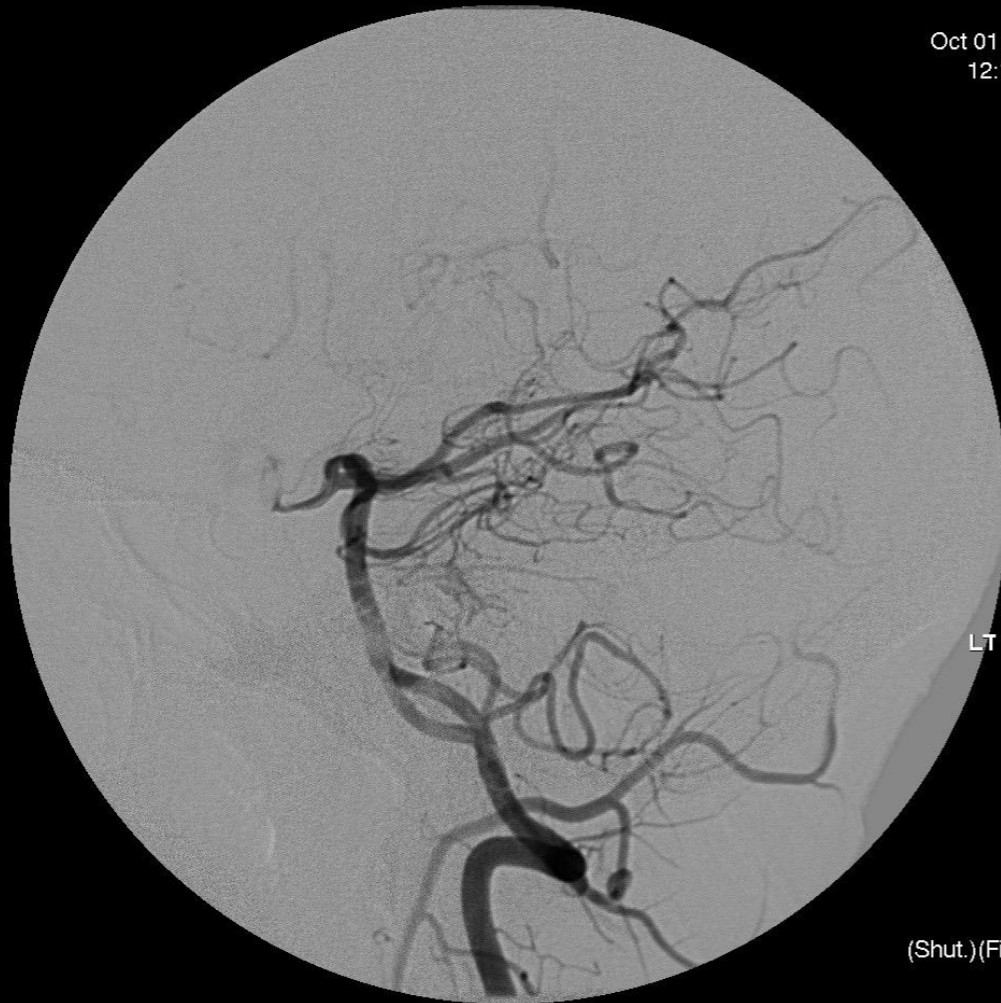


# Initial angio

GE MEDICAL SYSTEMS  
BrighamandWomens  
REDDY

PETROV-KONDRATOV VADIM  
# 20459731  
M Apr 14 1983  
LT VERT

Oct 01 2005  
12:14:02



LT

(Shut.)(Filt. 7)

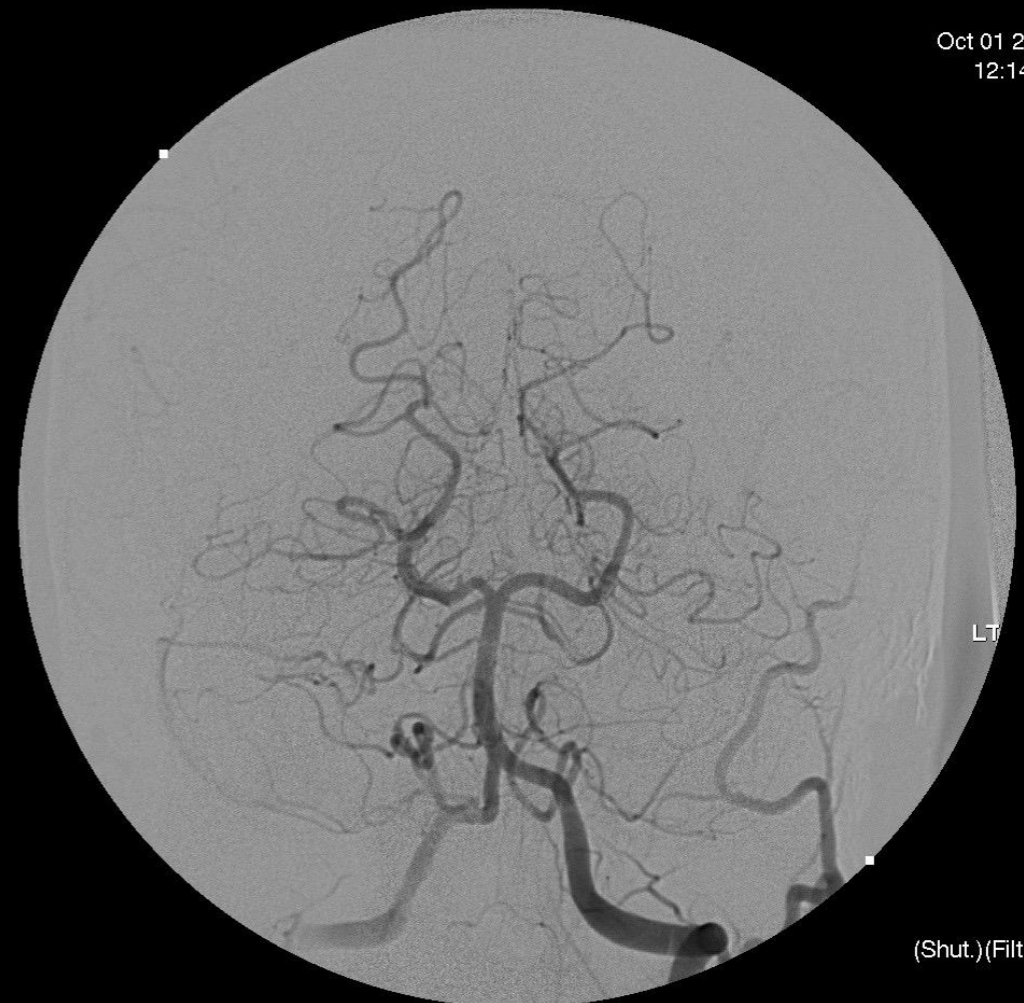
depart. LAO: 87  
depart. CAU: 0  
Mag = 1.00  
FL: ROT:  
WW: 1024WL: 512  
XA 1024x1024

LAT  
Seq: 14  
FRAME = 8 / 20  
MASK = 1

GE MEDICAL SYSTEMS  
BrighamandWomens  
REDDY

PETROV-KONDRATOV VADIM  
# 20459731  
M Apr 14 1983  
LT VERT

Oct 01 2005  
12:14:02

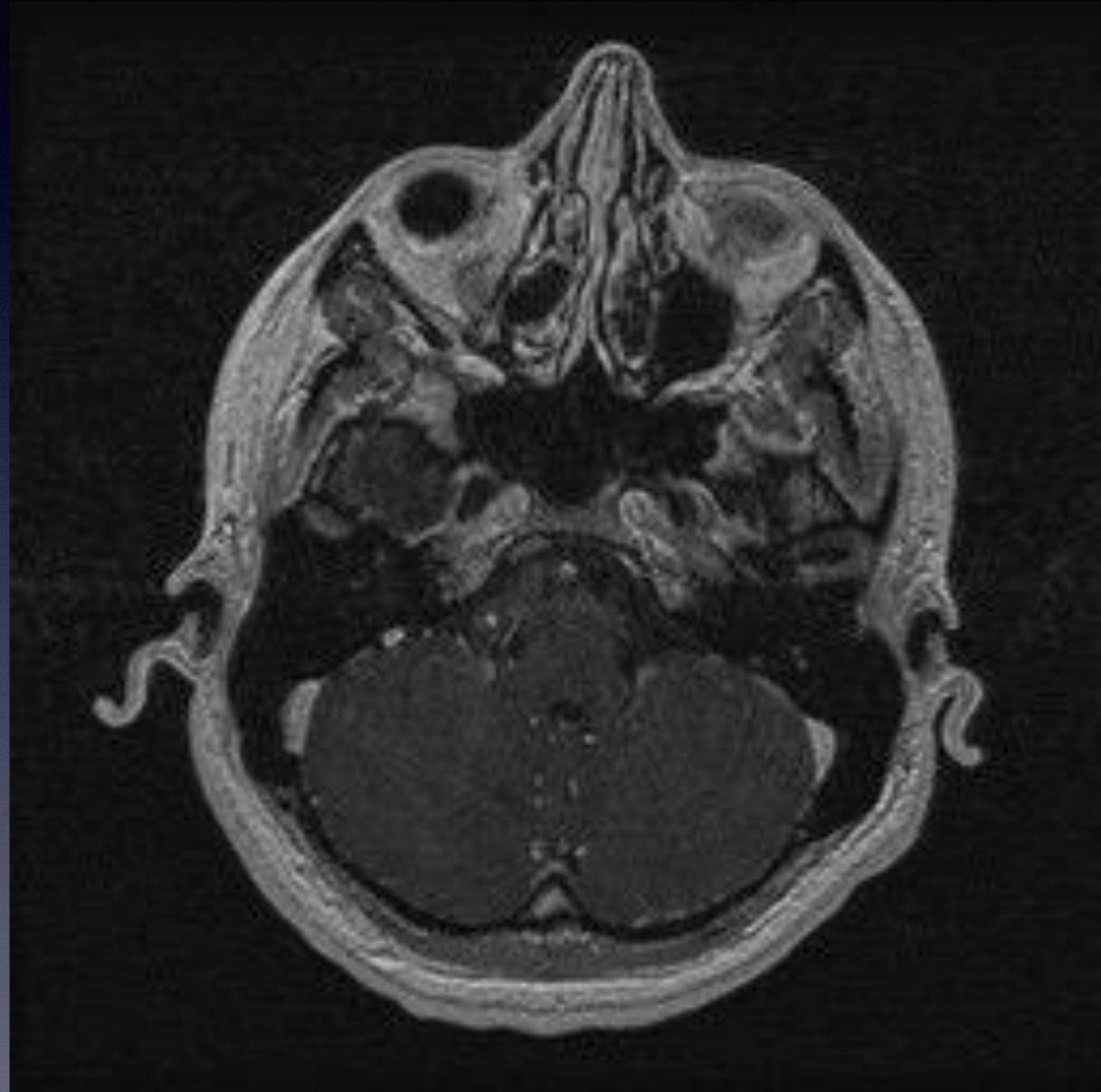
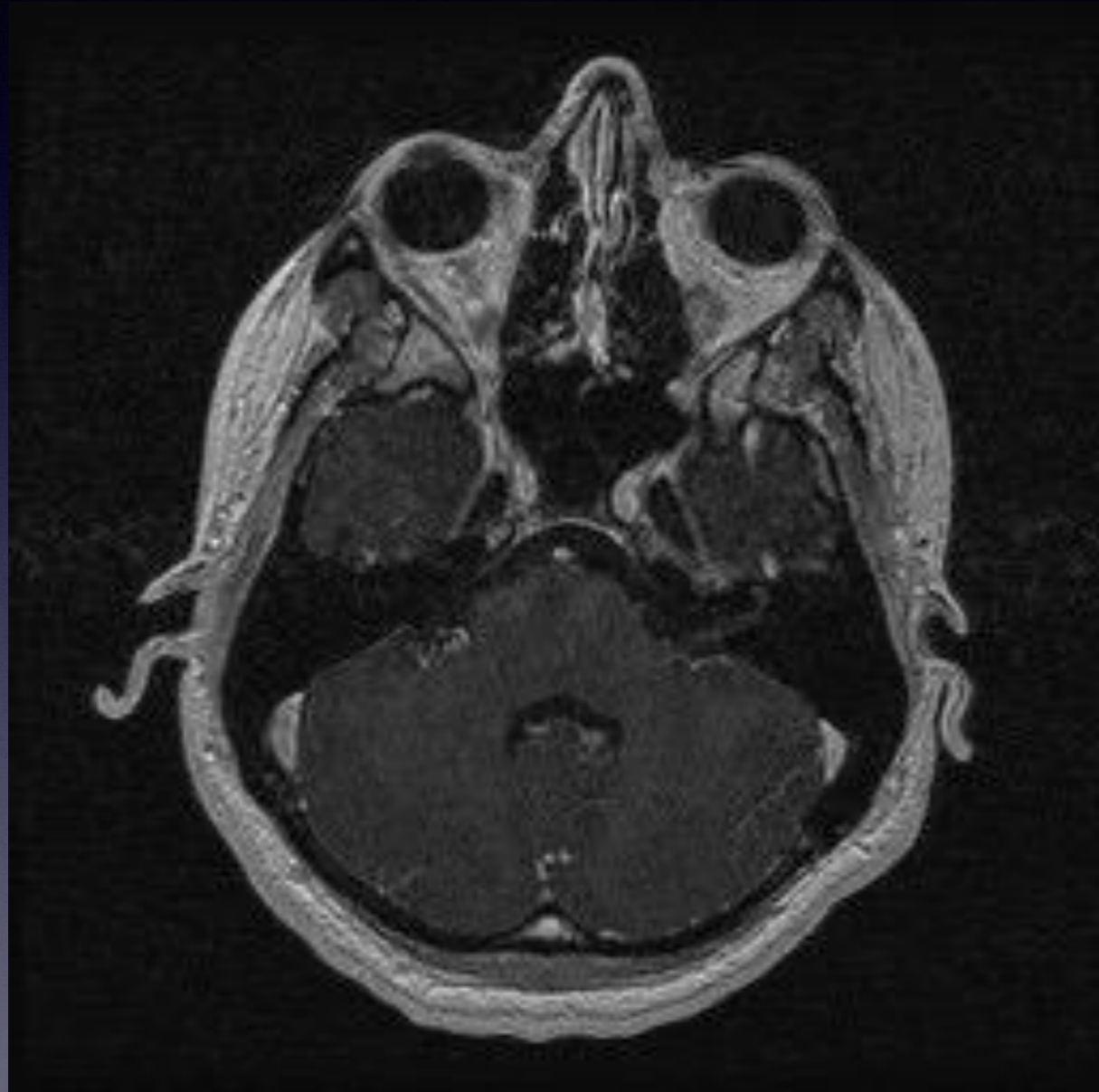


LT

(Shut.)(Filt. 7)

depart. LAO: 0  
depart. CRA: 16  
depart. L: -2  
Mag = 1.00  
FL: ROT:  
WW: 1024WL: 512  
XA 1024x1024

FRNT  
Seq: 14  
FRAME = 9 / 20  
MASK = 1

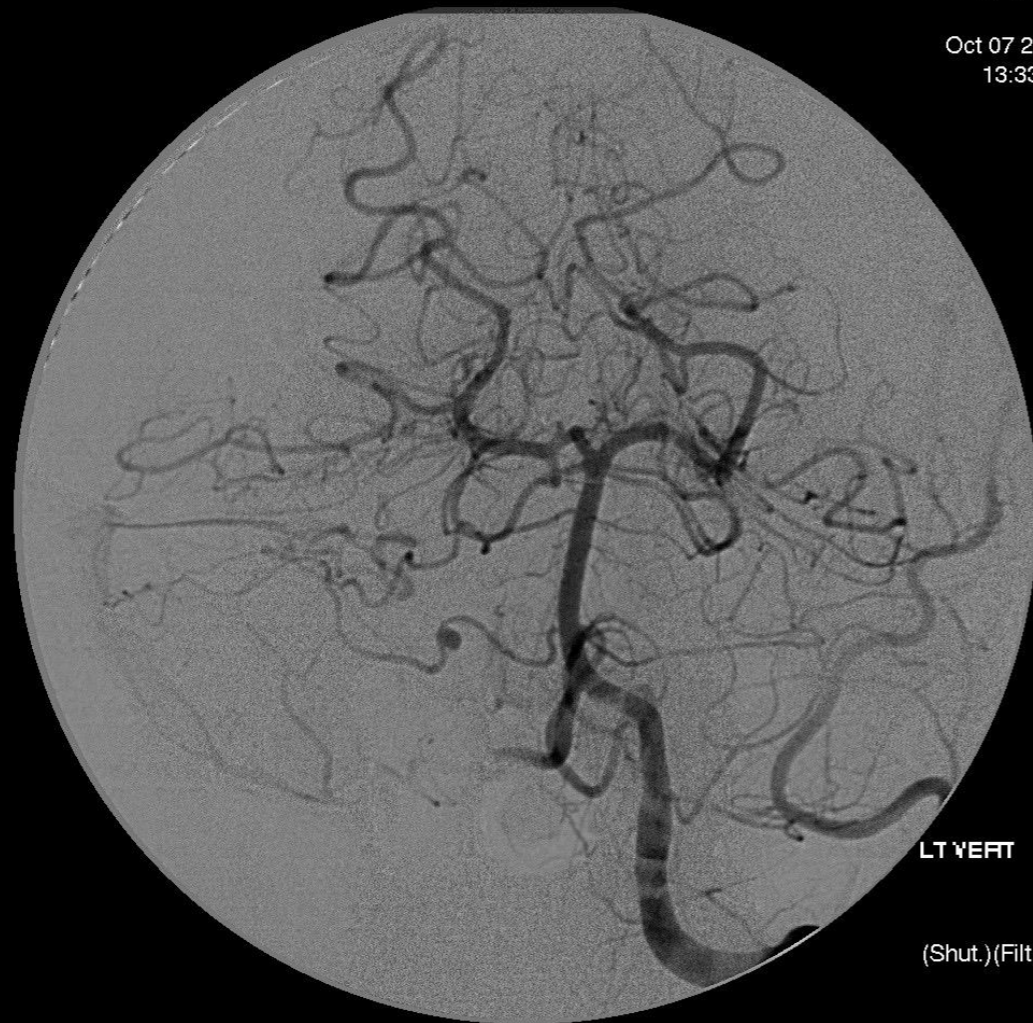


# Control angio 6 days later

GE MEDICAL SYSTEMS  
BrighamandWomens  
REDDY/CG

PETROV-KONDRATOV VADIM  
# 20459731  
M Apr 14 1983  
LT VERT

Oct 07 2005  
13:33:17



LT VERT

(Shut.)(Filt. 7)

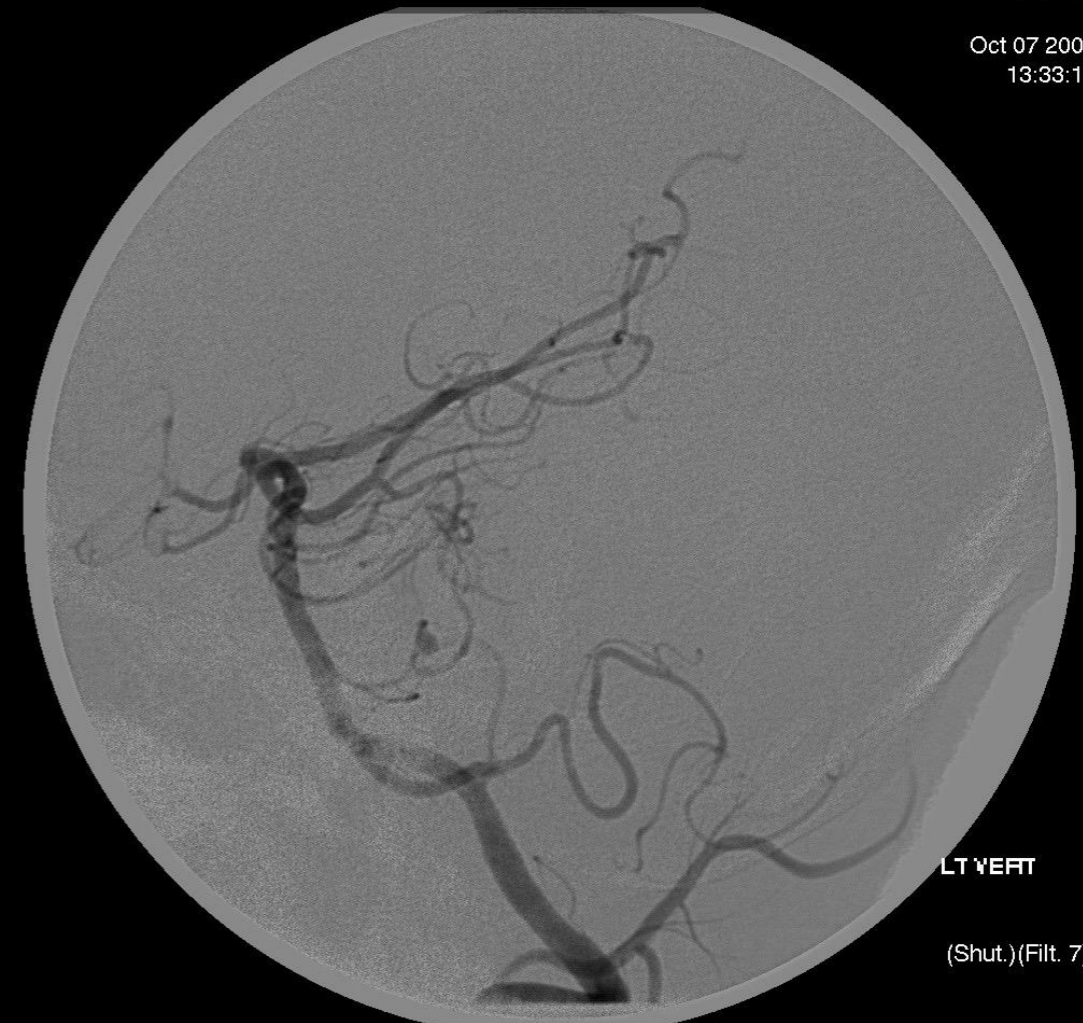
depart. RAO: 10  
depart. CAU: 2  
depart. L: -11  
Mag = 1.00  
FL: ROT:  
WW: 970WL: 453  
XA 1024x1024

FRNT  
Seq: 17  
FRAME = 8 / 17  
MASK = 1

GE MEDICAL SYSTEMS  
BrighamandWomens  
REDDY/CG

PETROV-KONDRATOV VADIM  
# 20459731  
M Apr 14 1983  
LT VERT

Oct 07 2005  
13:33:17



LT VERT

(Shut.)(Filt. 7)

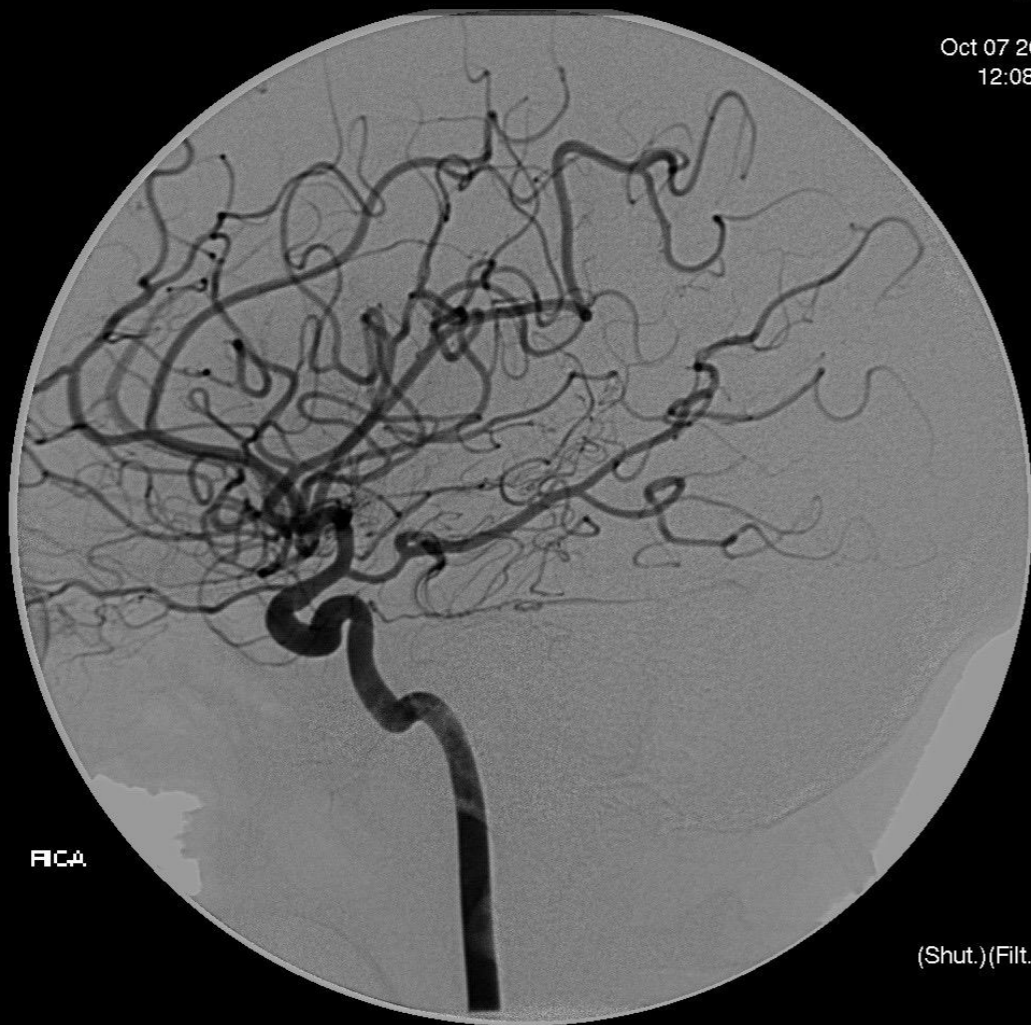
depart. LAO: 93  
depart. CRA: 10  
Mag = 1.00  
FL: ROT:  
WW: 987WL: 450  
XA 1024x1024

LAT  
Seq: 17  
FRAME = 6 / 17  
MASK = 1

GE MEDICAL SYSTEMS  
BrighamandWomens  
REDDY/CG

PETROV-KONDRATOV VADIM  
# 20459731  
M Apr 14 1983  
RICA

Oct 07 2005  
12:08:45



RICA

(Shut.)(Filt. 7)

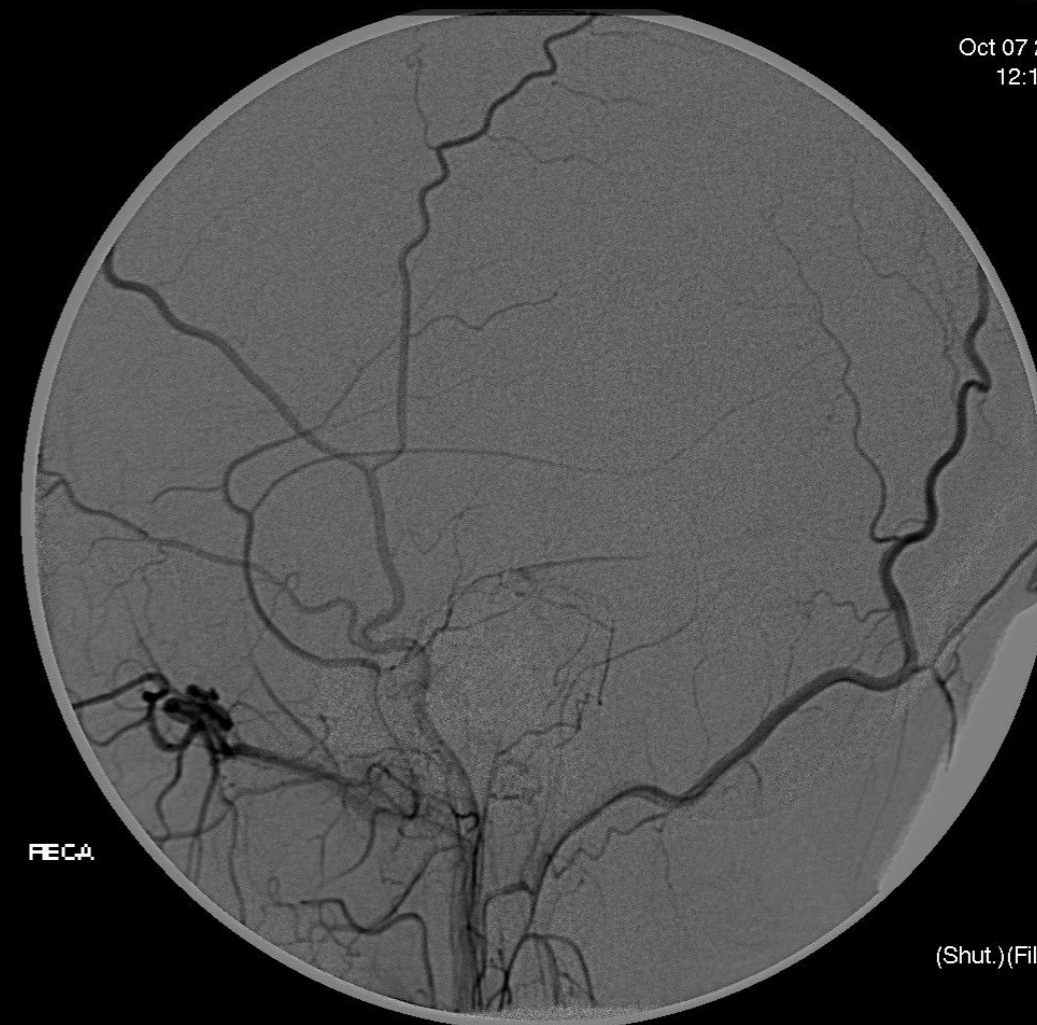
depart. LAO: 86  
depart. CRA: 1  
Mag = 1.00  
FL: ROT:  
WW: 941WL: 390  
XA 1024x1024

LAT  
Seq: 1  
FRAME = 8 / 19  
MASK = 1

GE MEDICAL SYSTEMS  
BrighamandWomens  
REDDY/CG

PETROV-KONDRATOV VADIM  
# 20459731  
M Apr 14 1983  
RECA

Oct 07 2005  
12:18:27

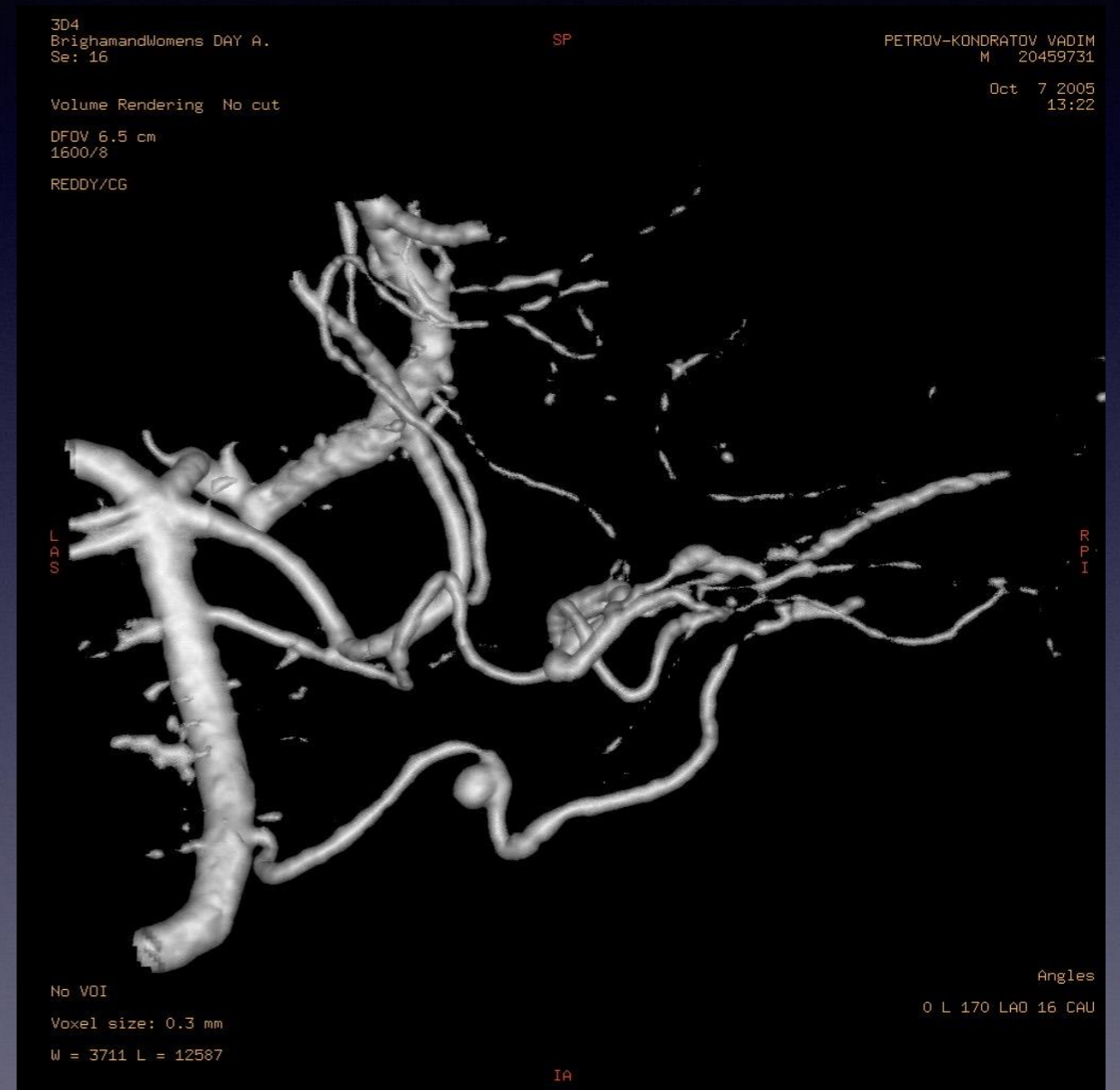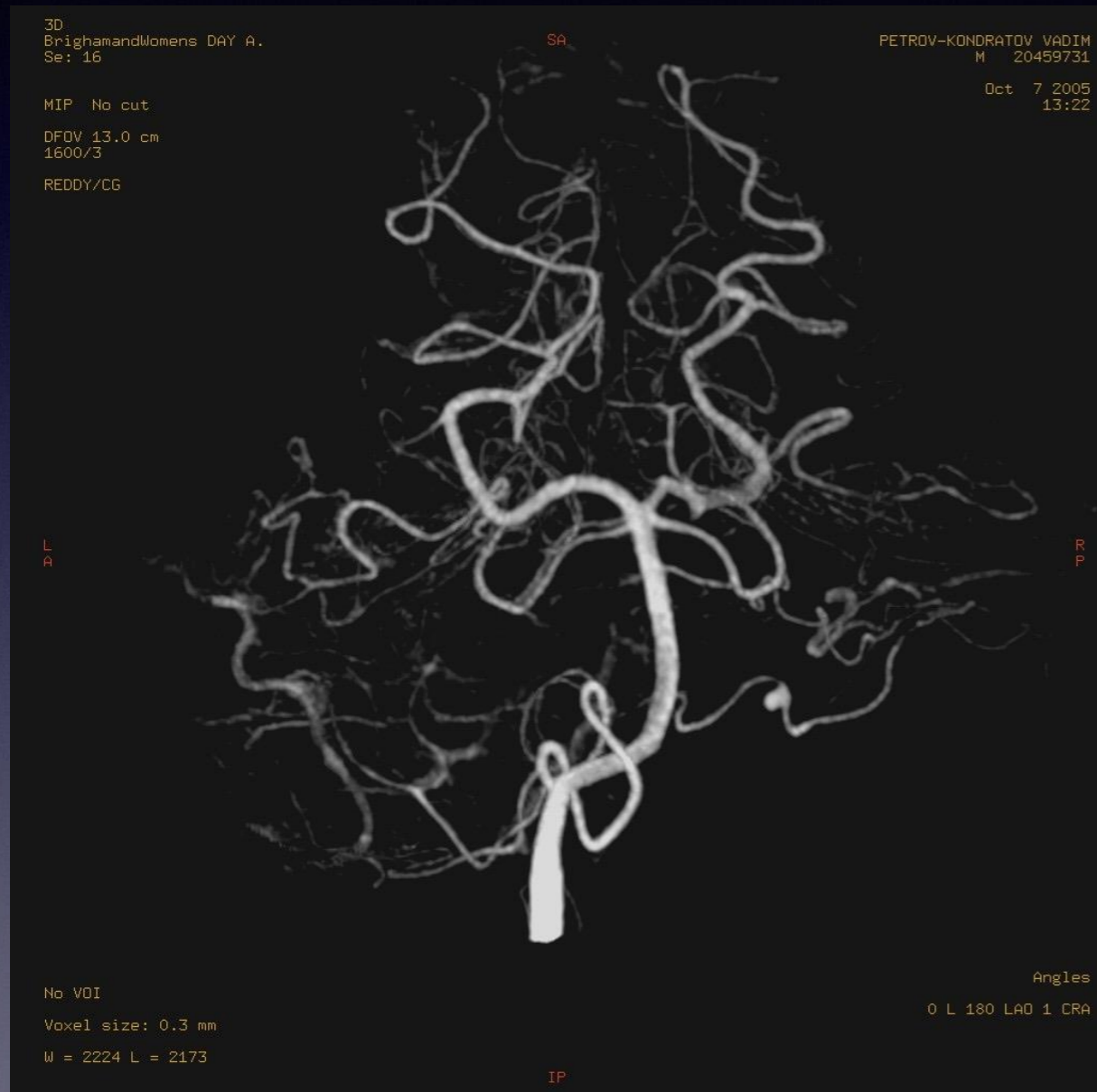


RECA

(Shut.)(Filt. 7)

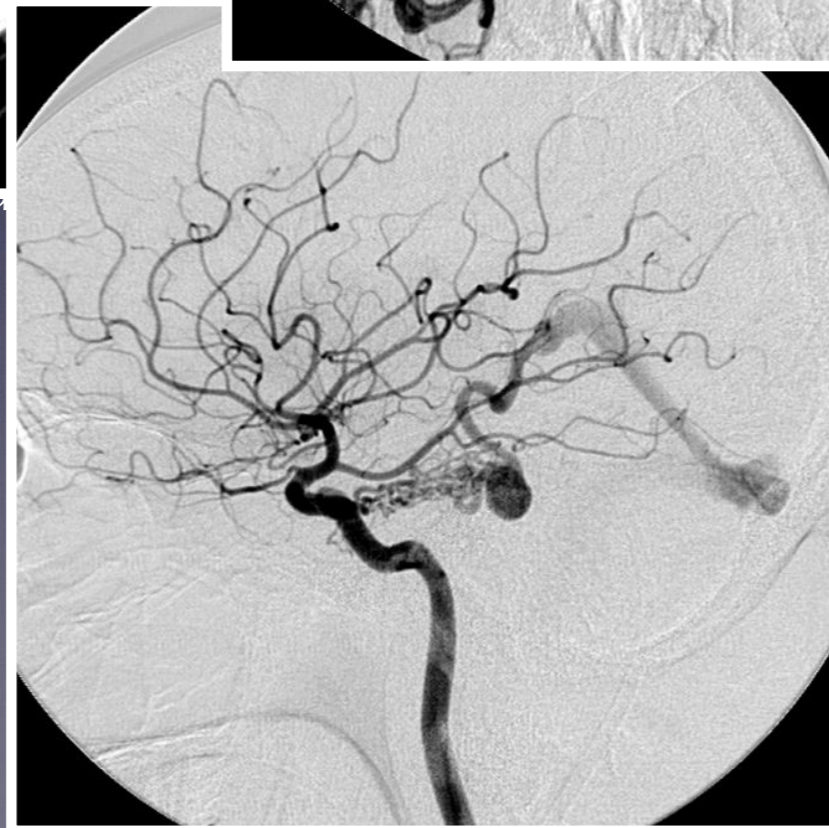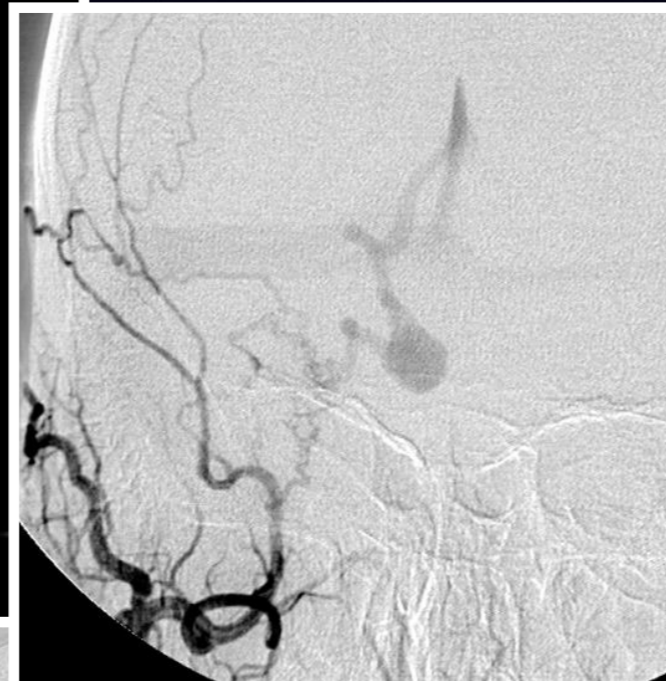
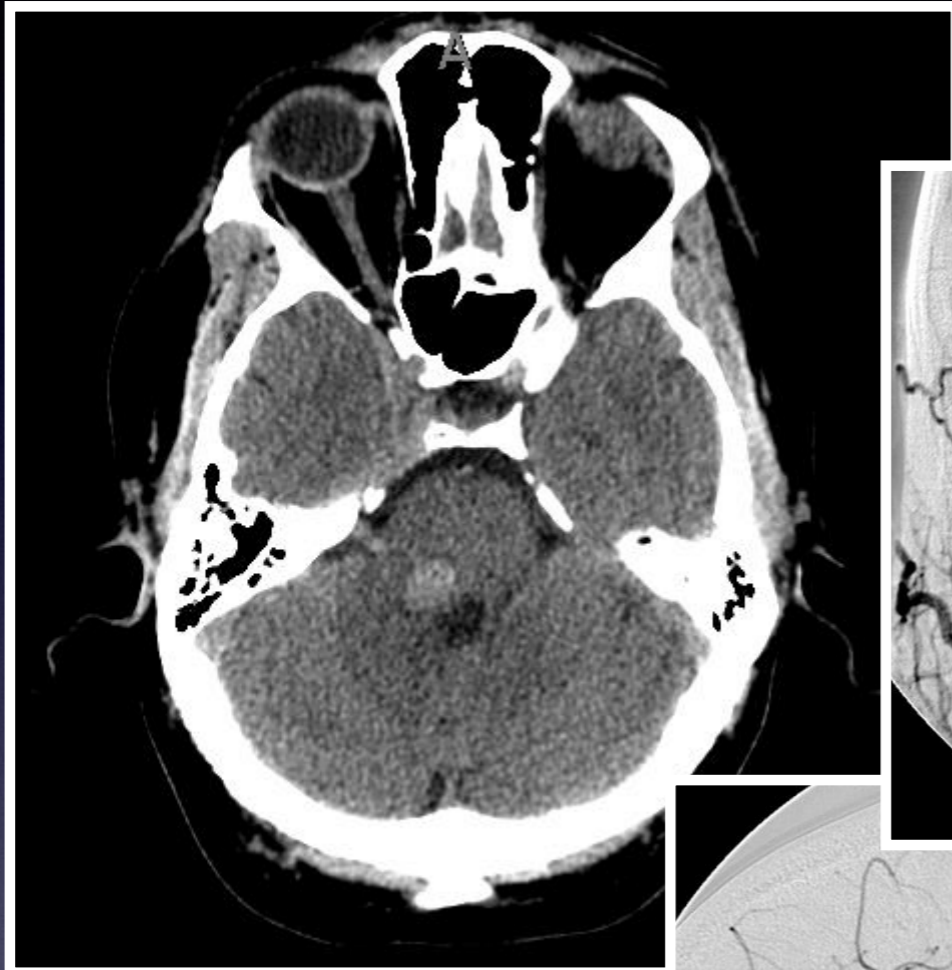
depart. LAO: 88  
depart. CRA: 4  
Mag = 1.00  
FL: ROT:  
WW: 959WL: 467  
XA 1024x1024

LAT  
Seq: 3  
FRAME = 9 / 15  
MASK = 1





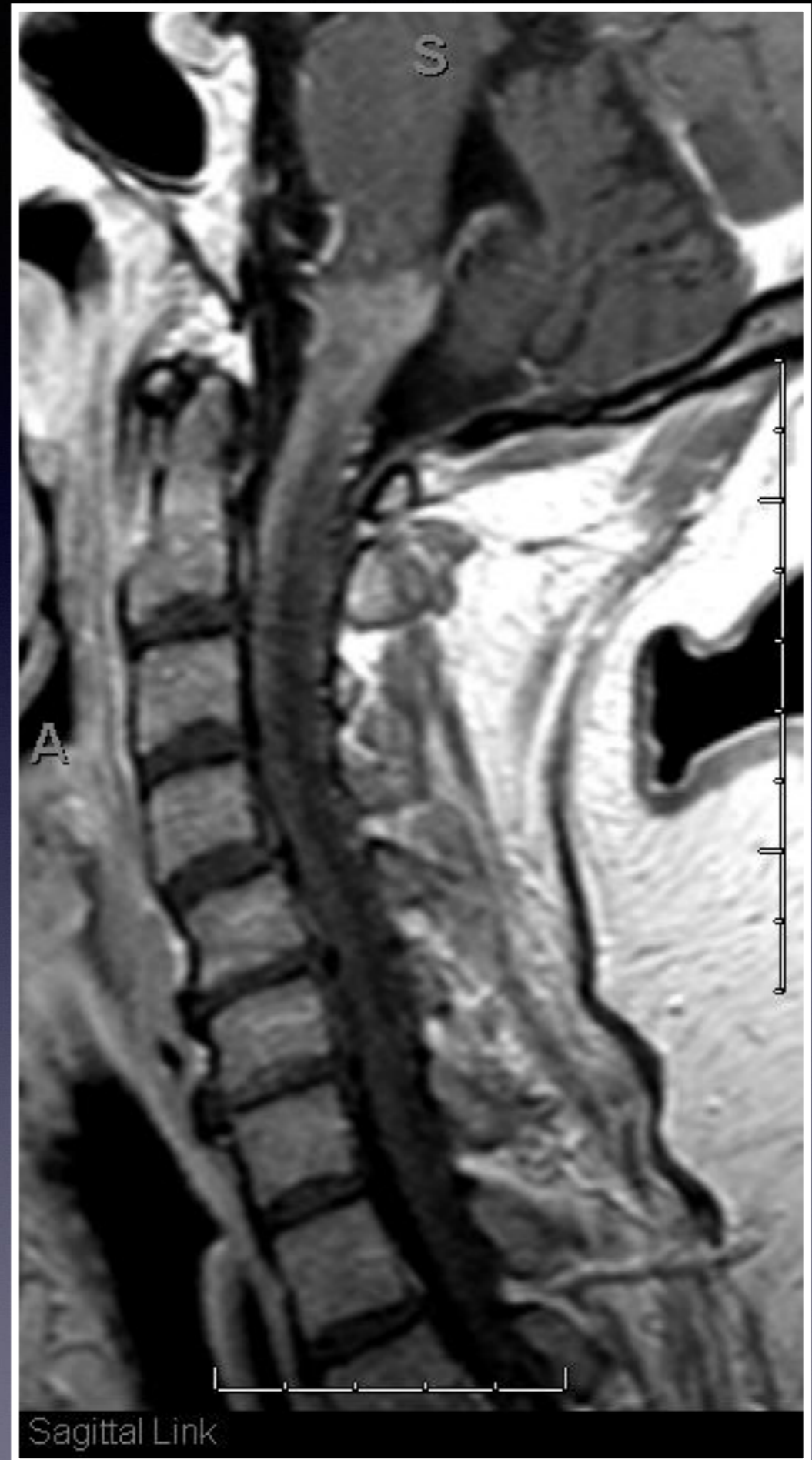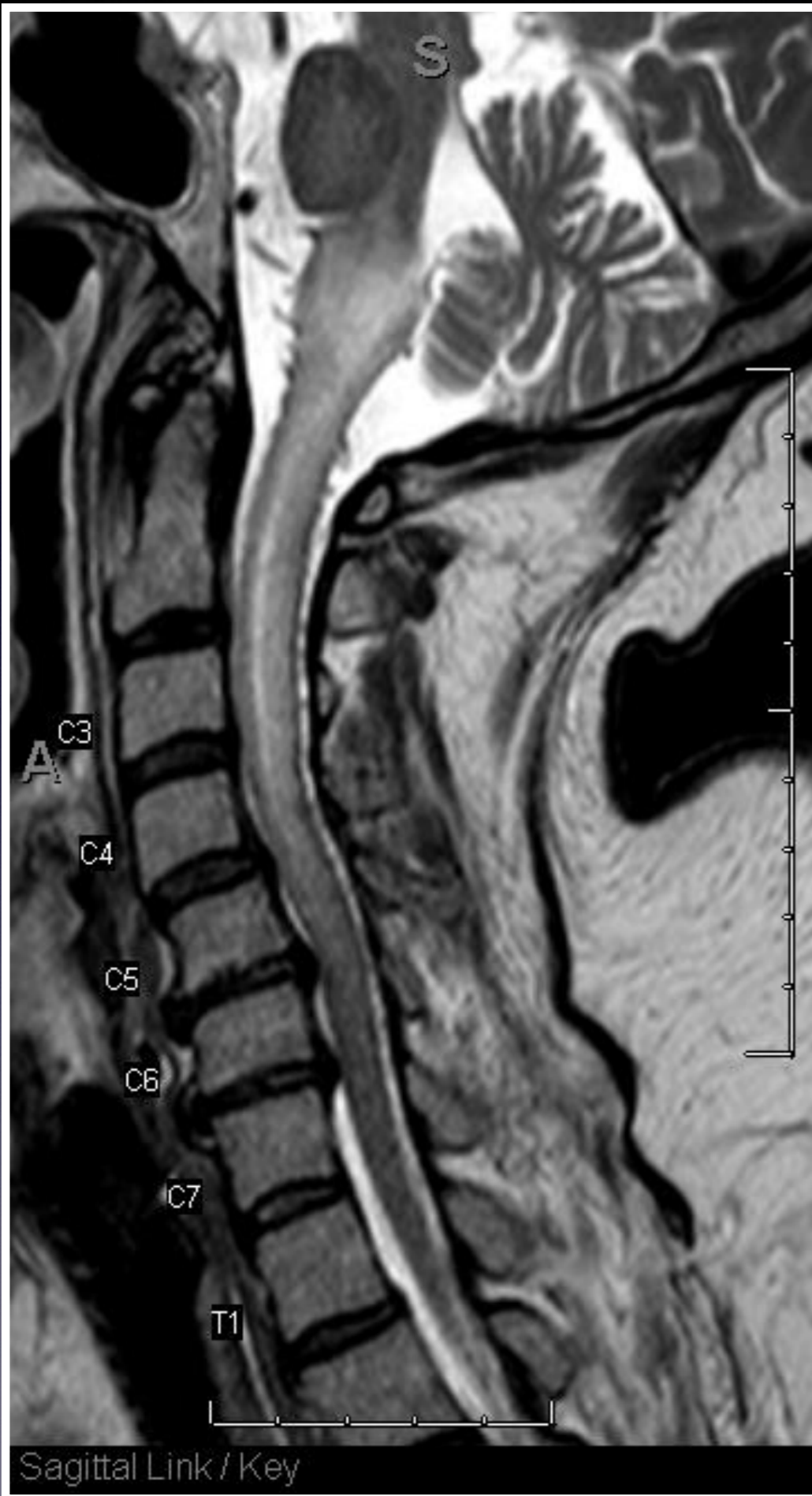# Dural AV fistula

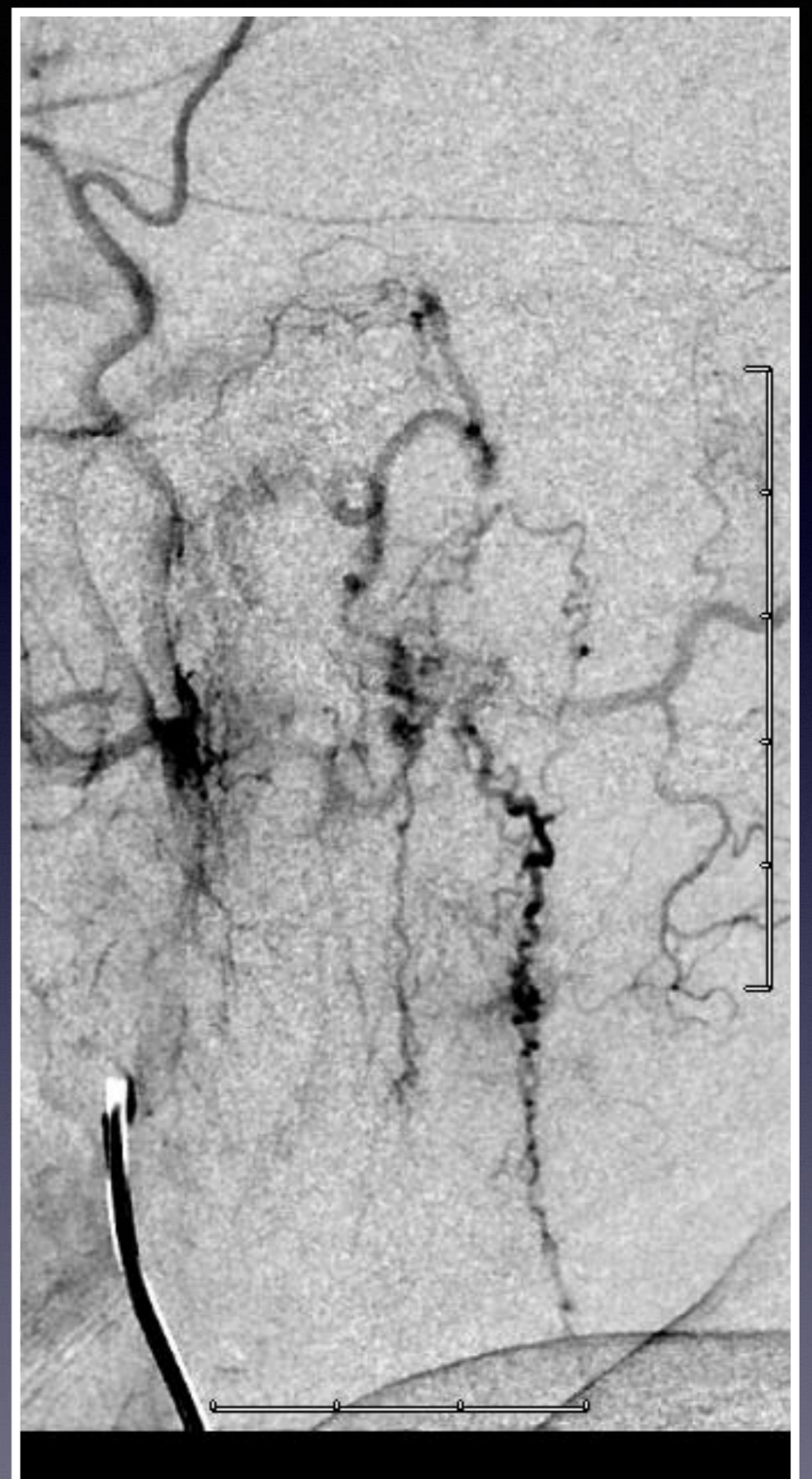
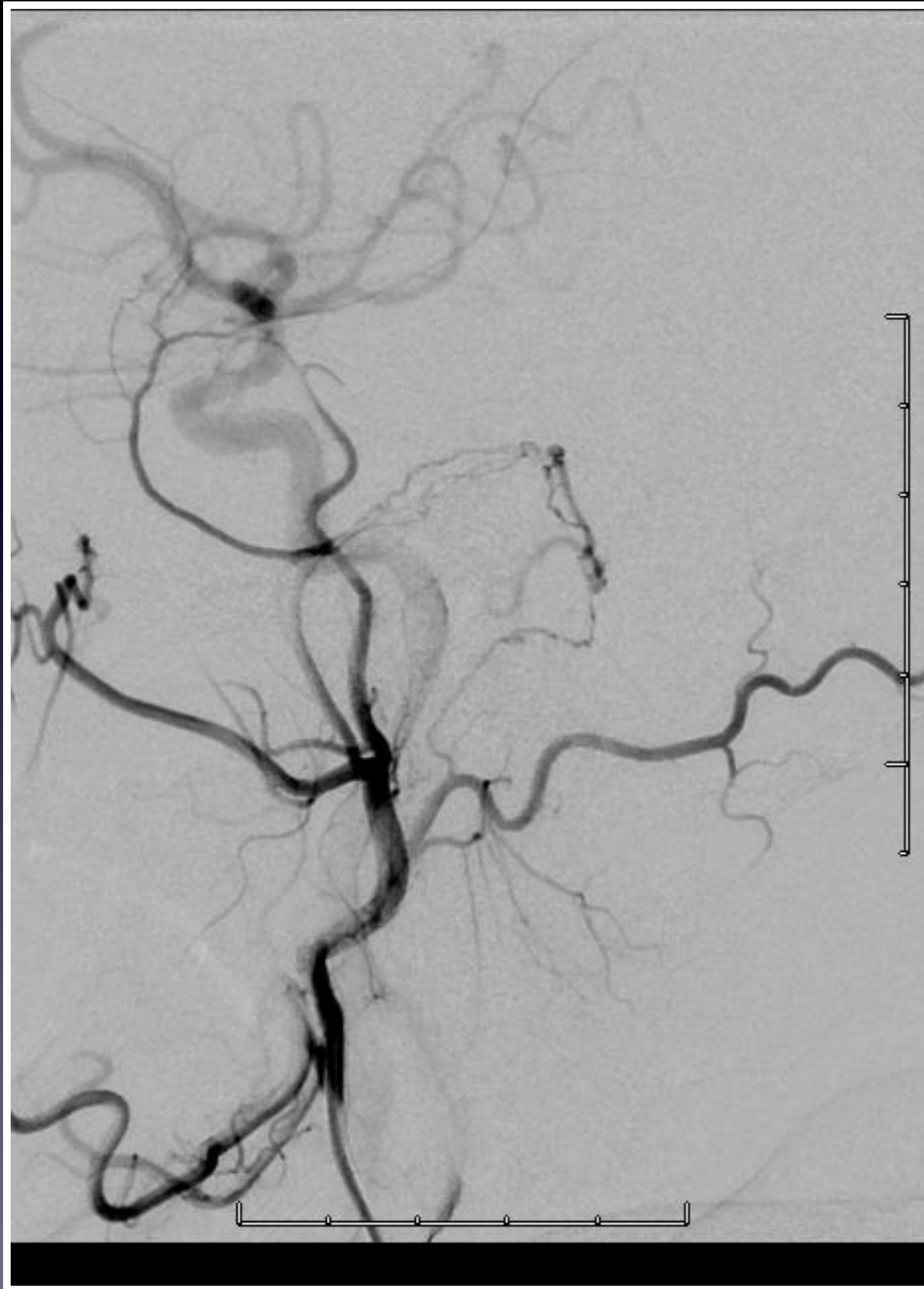


...us or a bridging vein

...us thrombosis

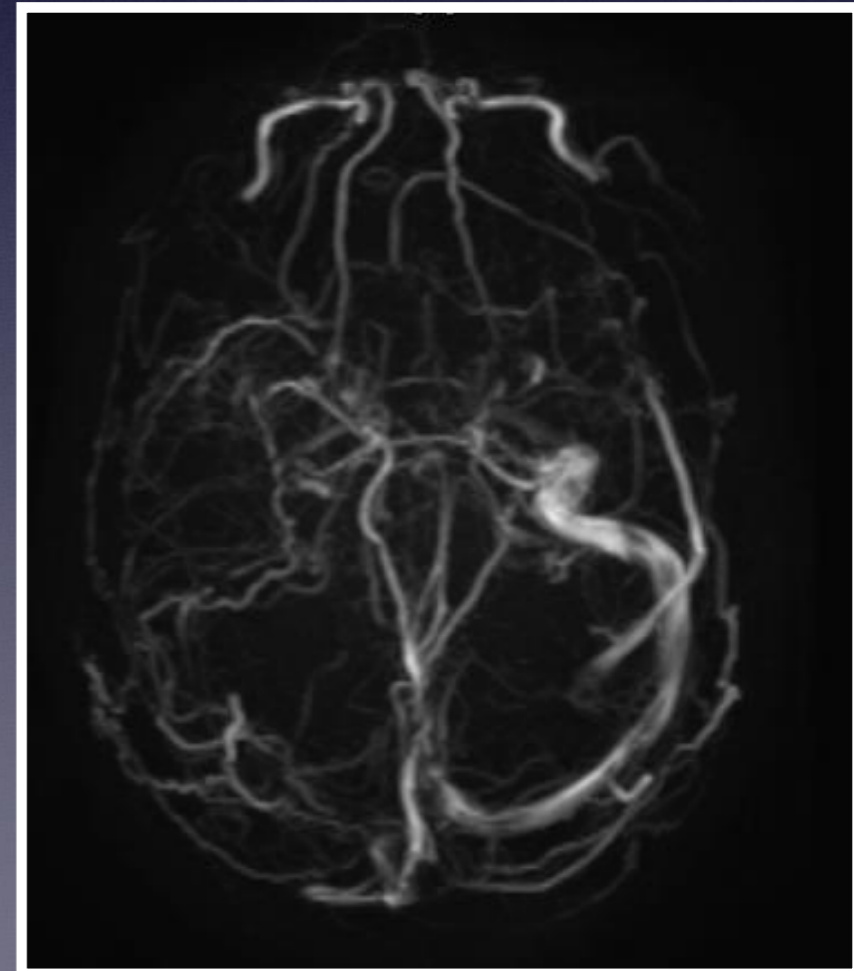
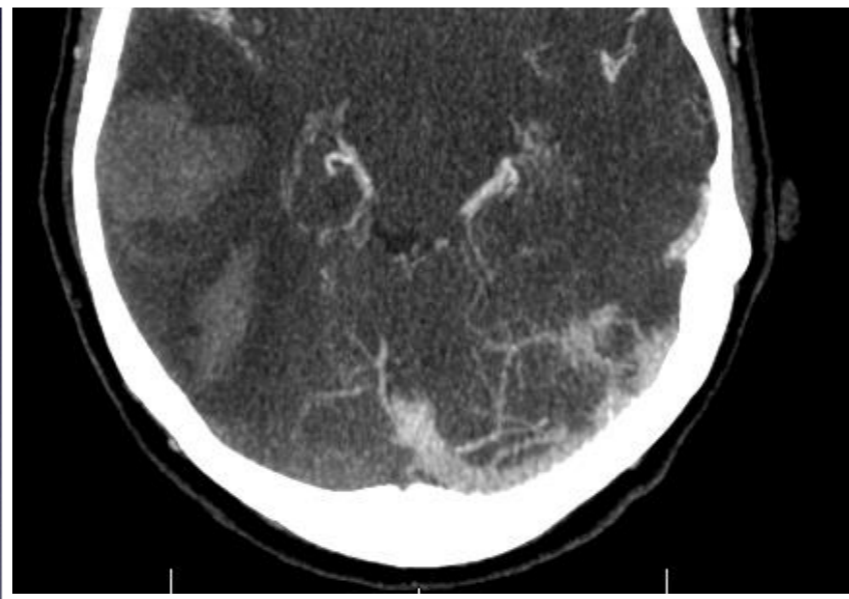
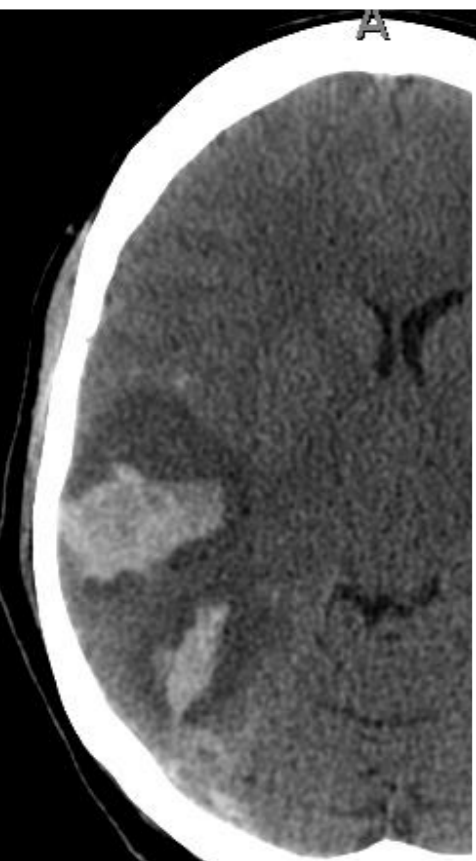
...annual risk of ICH of 7.5%

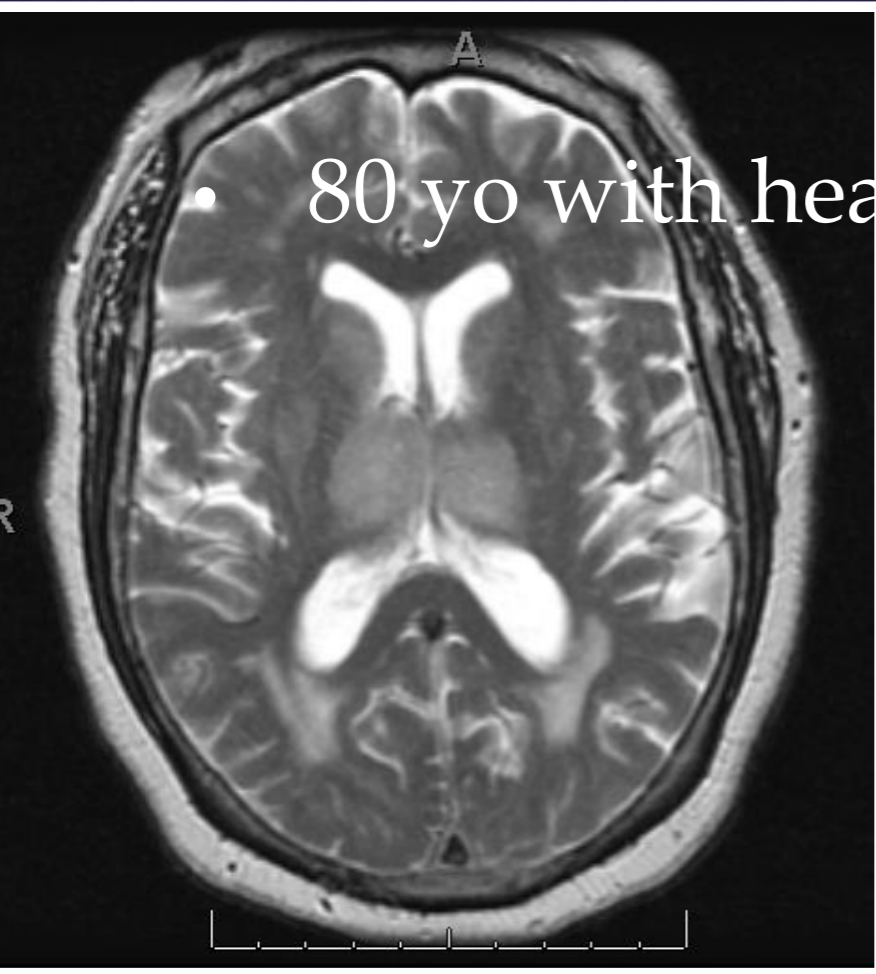
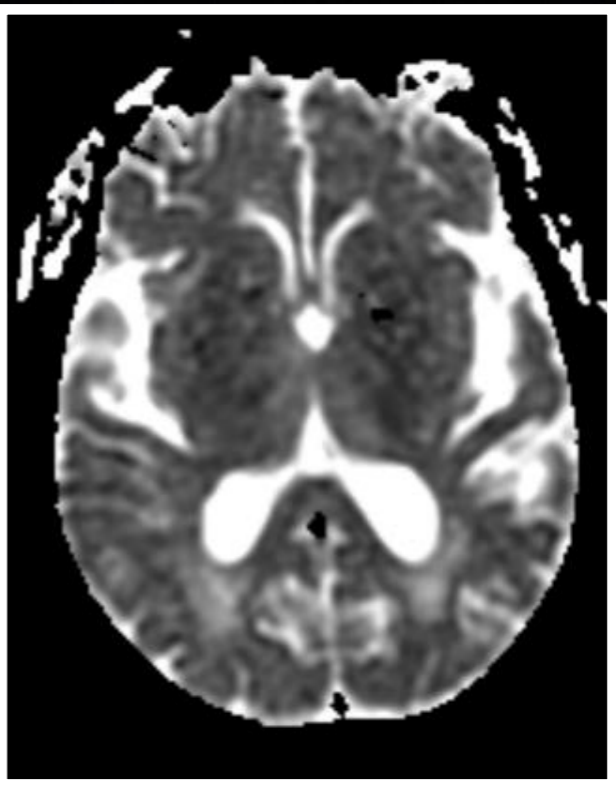
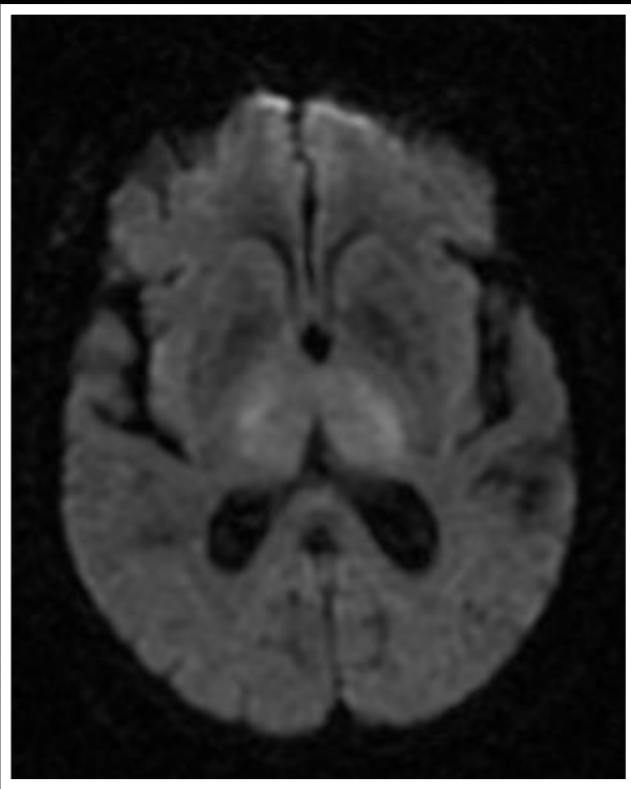
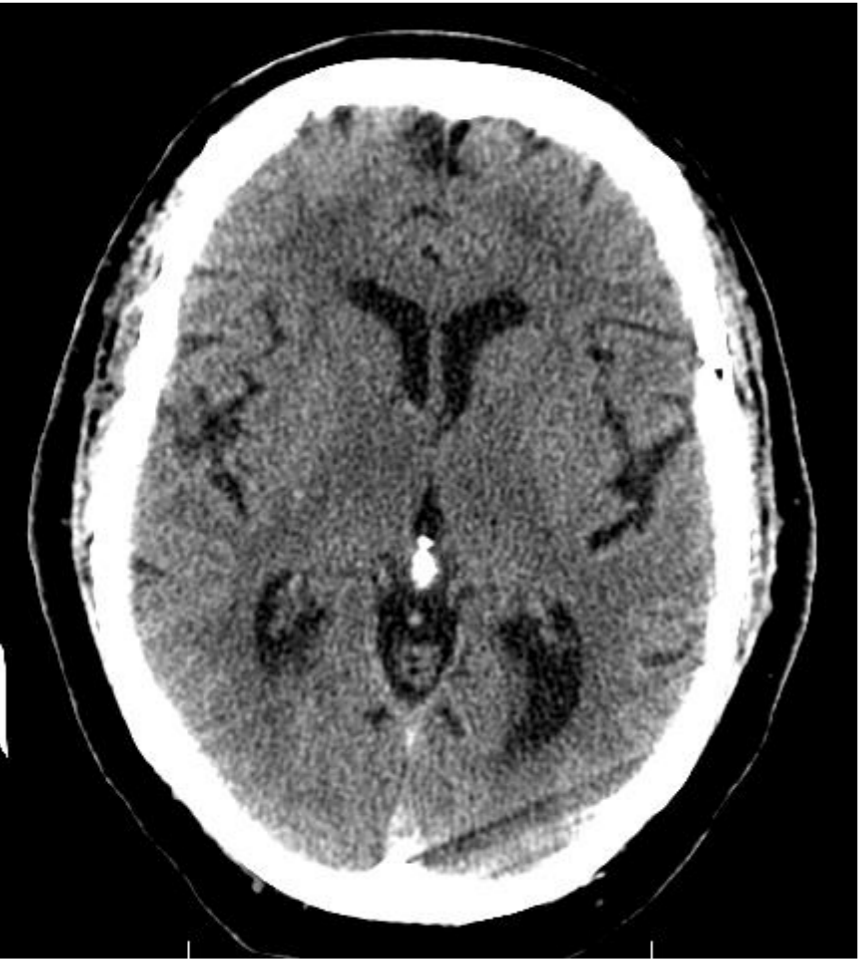



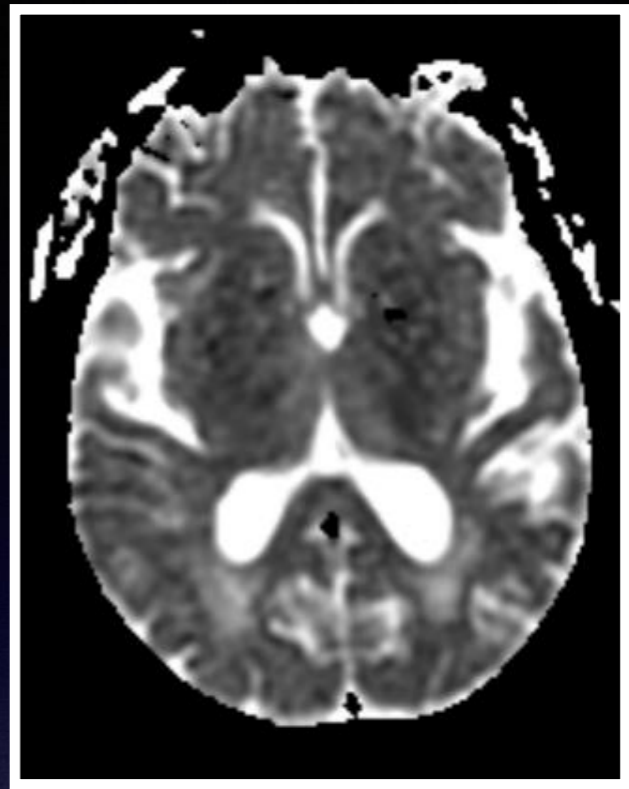
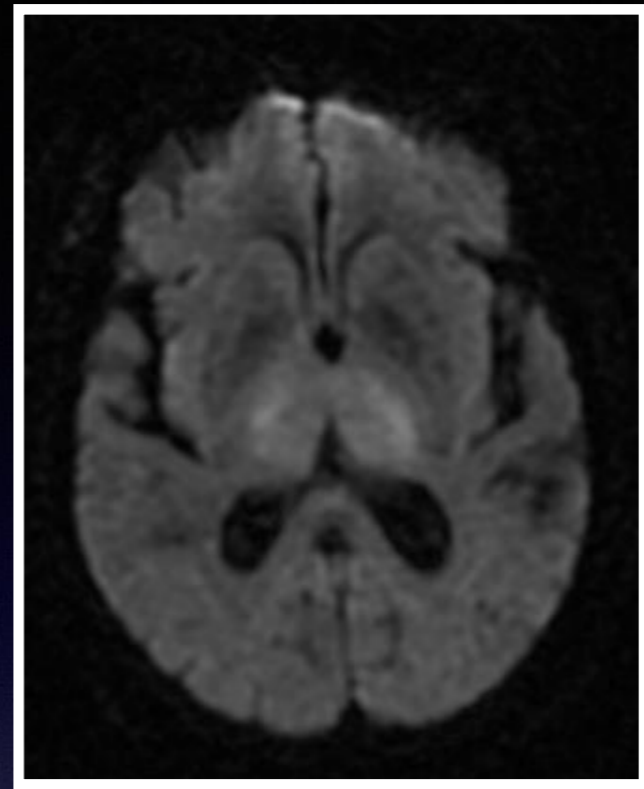
## Hemorrhagic venous infarct

- ▣ Thrombosis of the transverse sigmoid sinus
- ▣ Isolated cortical vein/anastomotic vein (Labbe)
  - ▣ ! signs of septic thrombophlebitis (otomastoiditis, orbital cellulitis)
- ▣ Treatment is with systemic anticoagulation

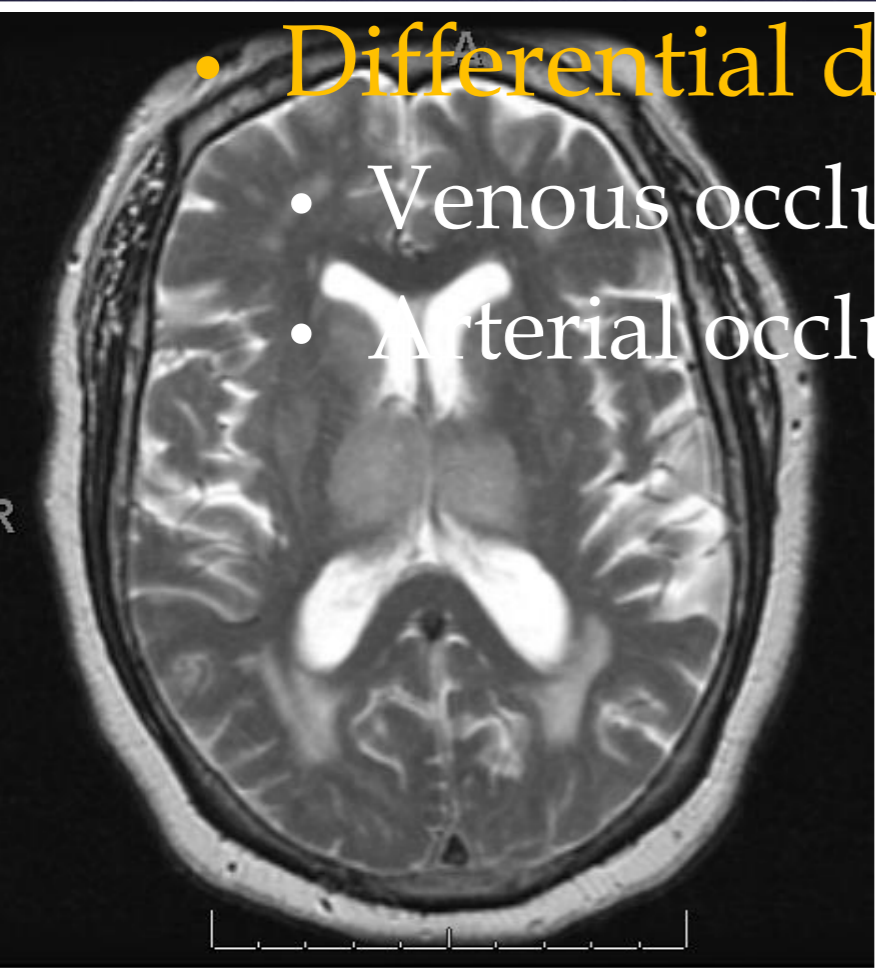




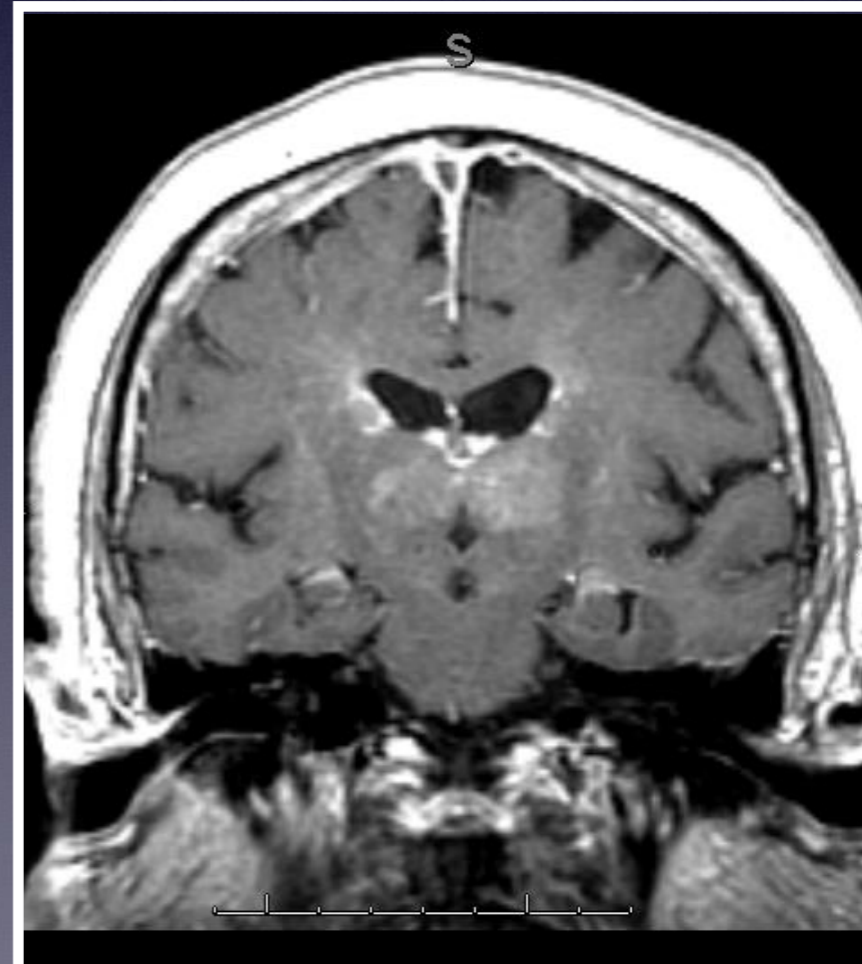
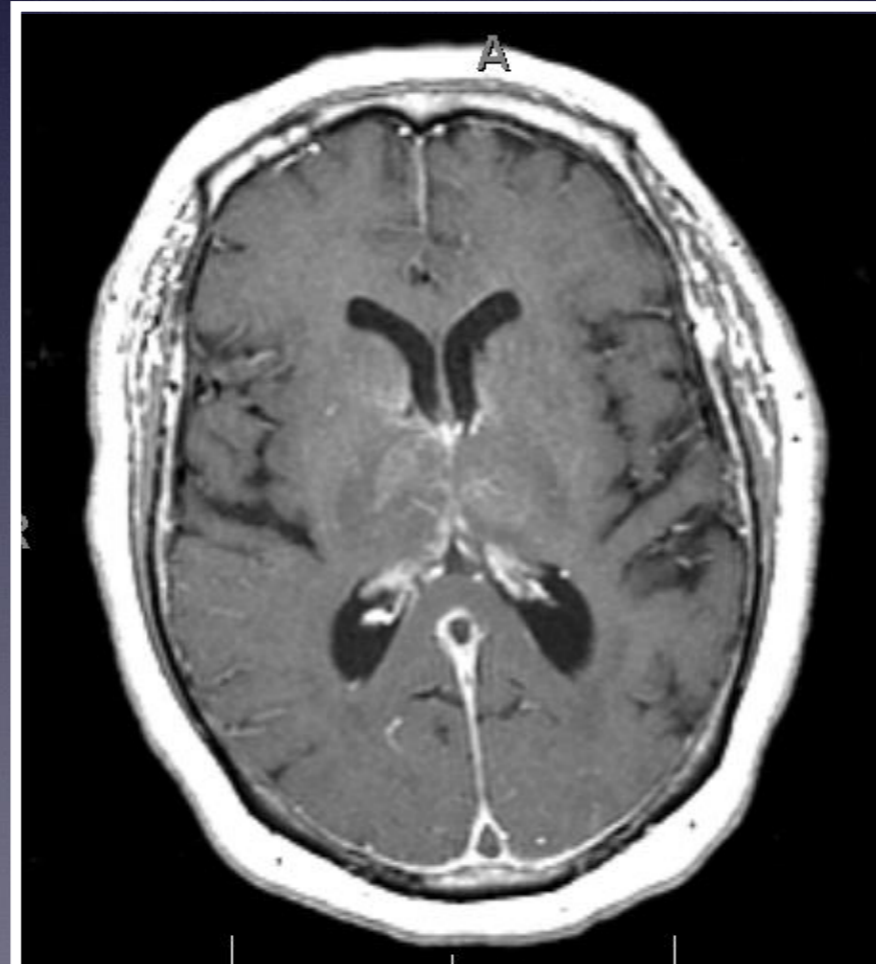
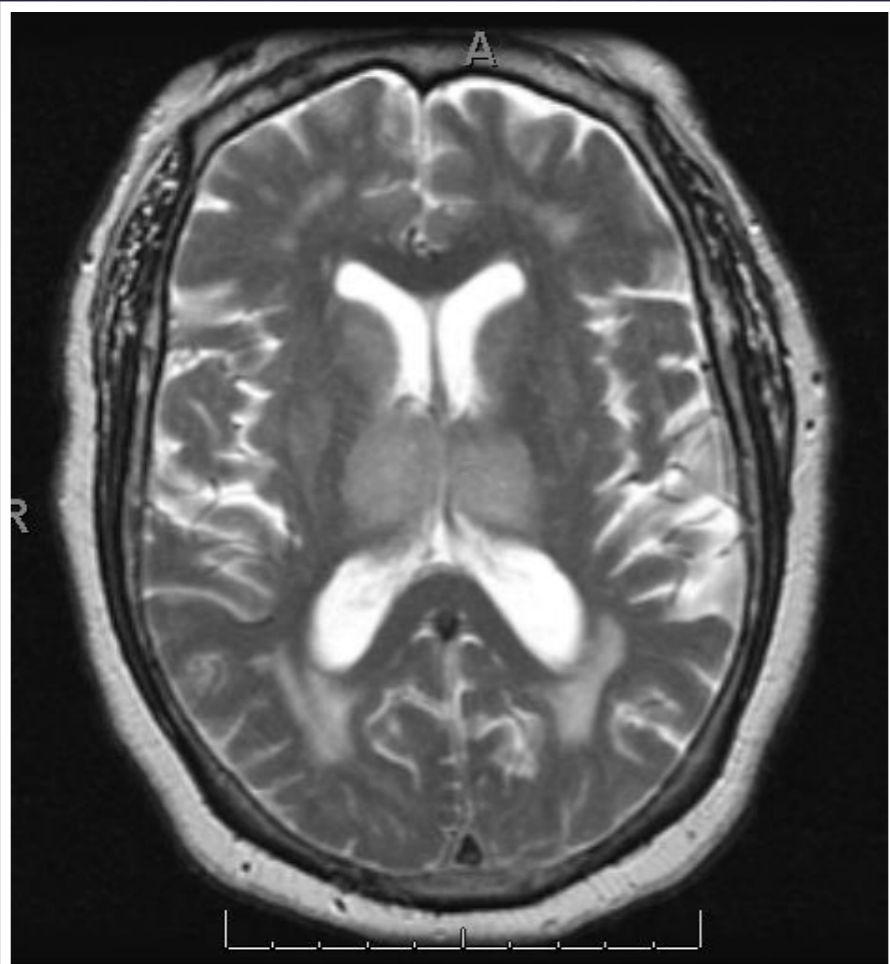
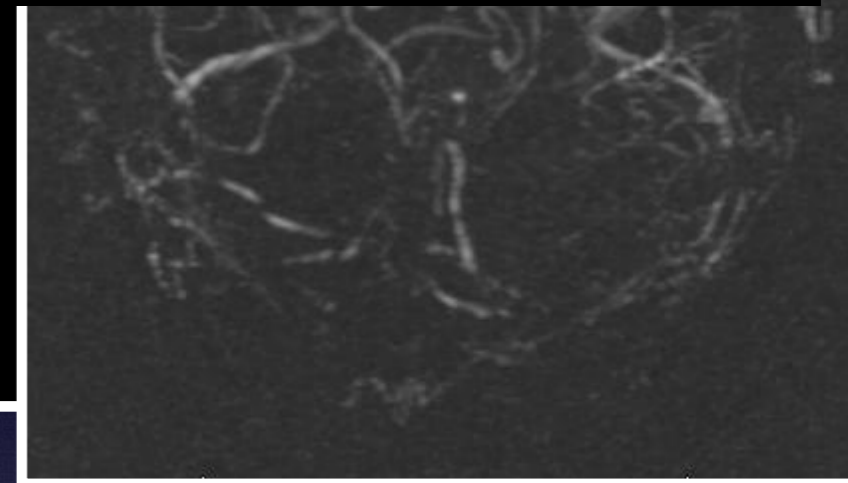
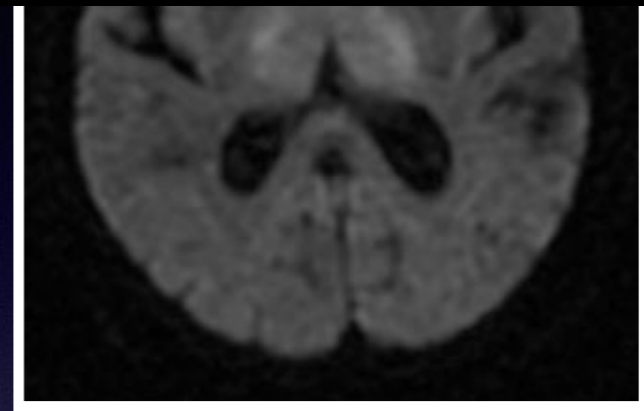
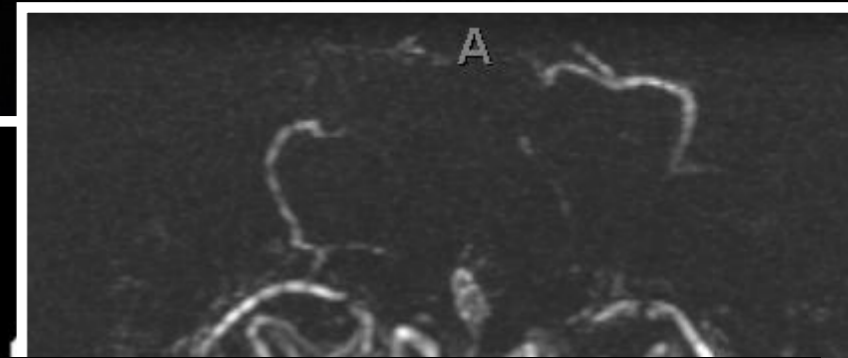
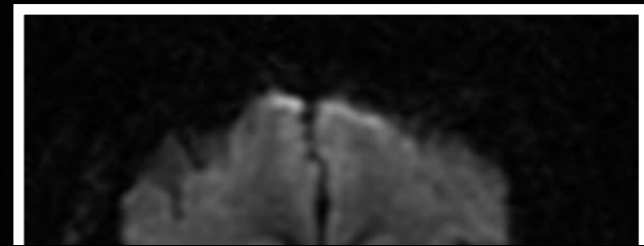
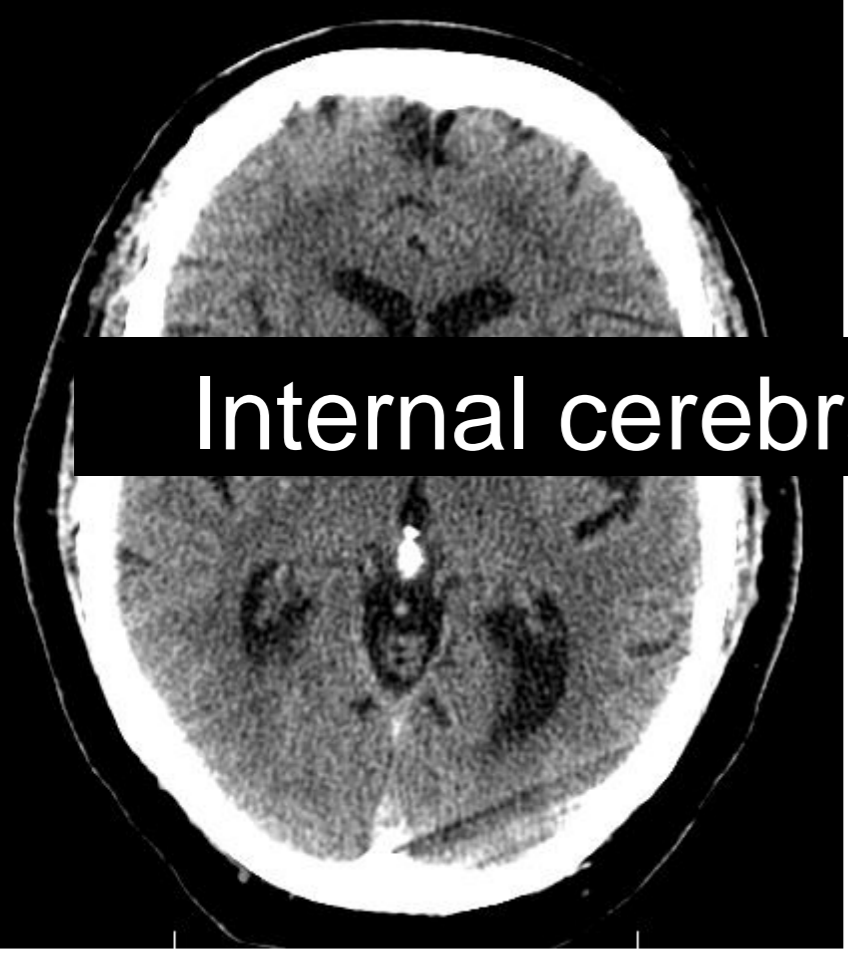
• 80 yo with headache and mental status changes



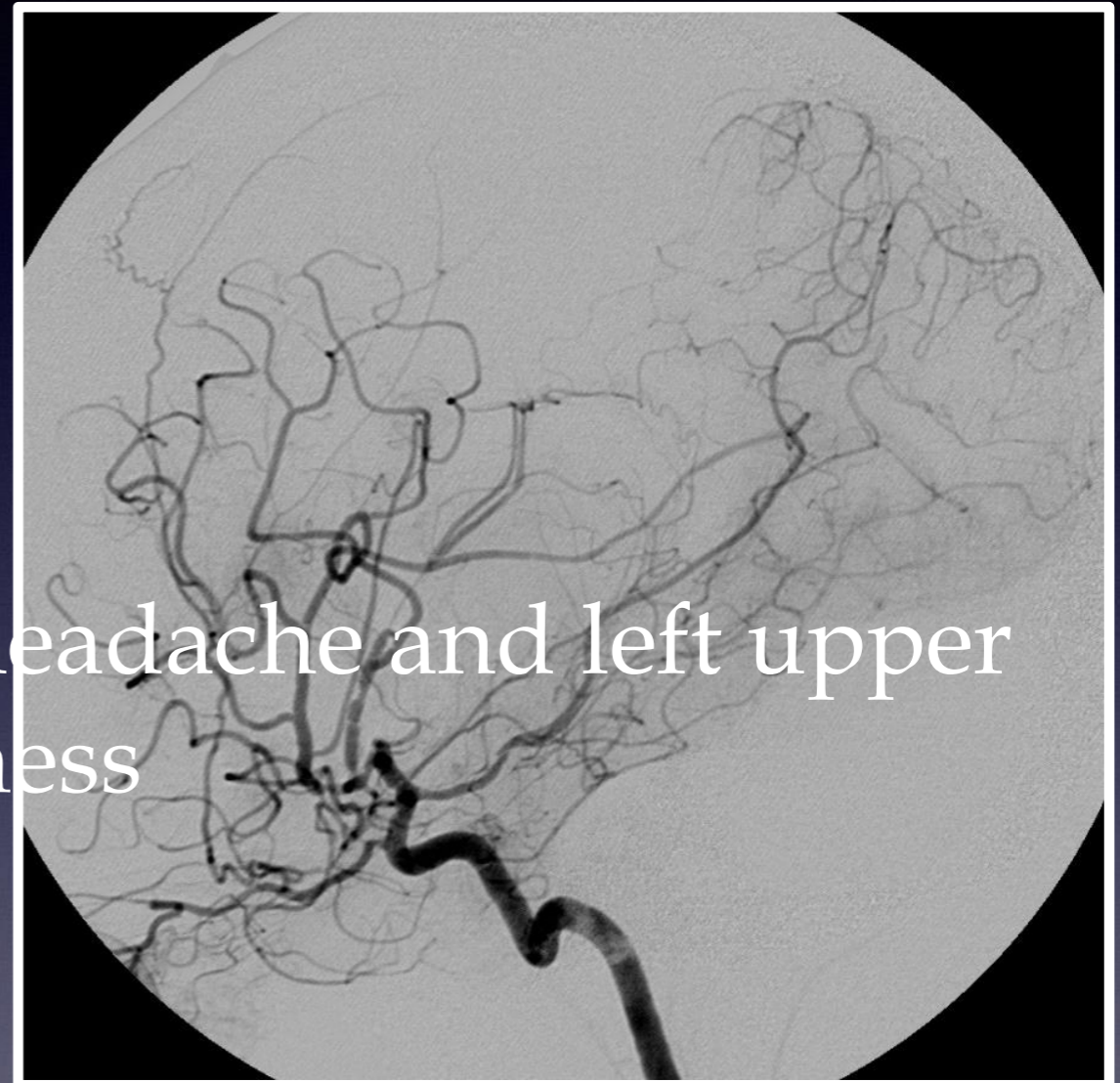
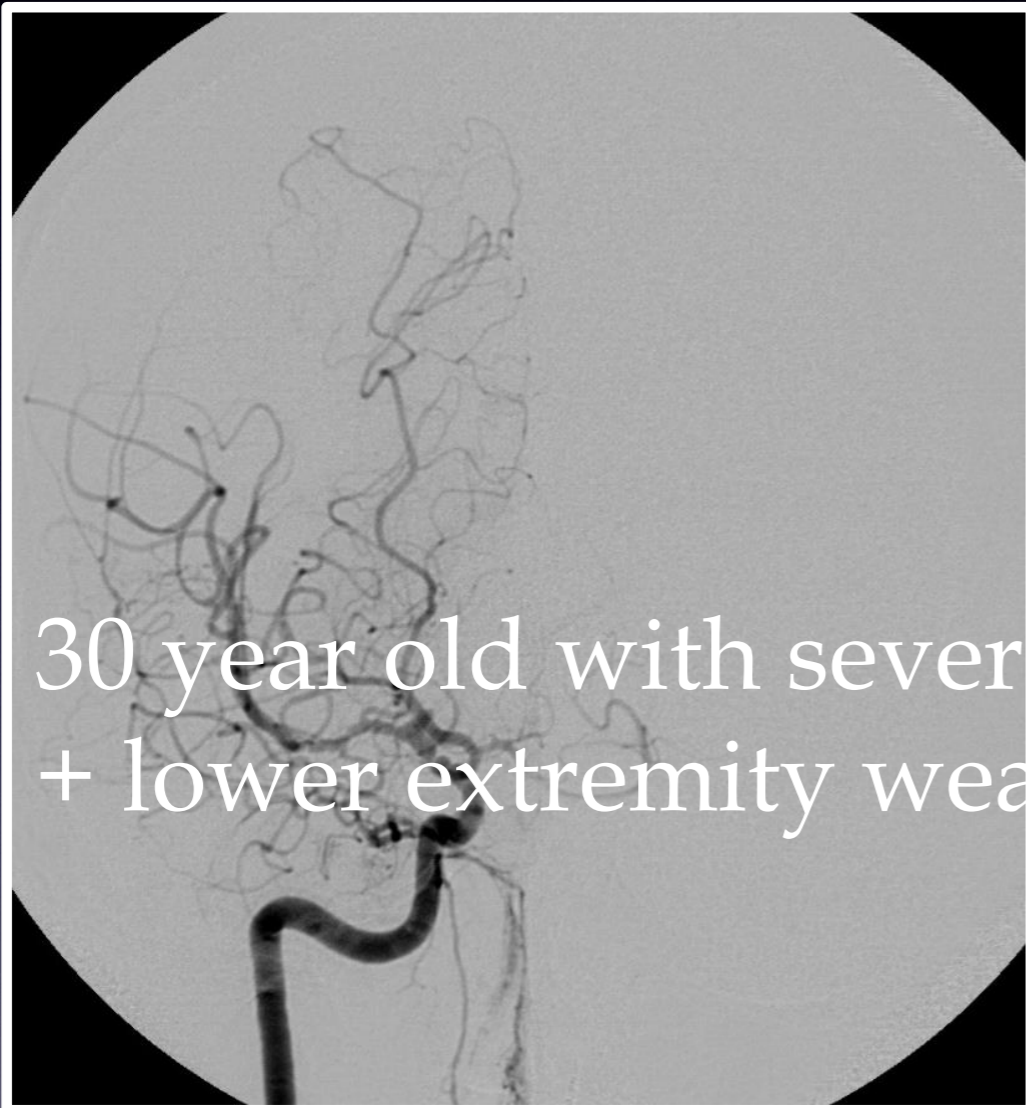- Differential diagnosis:
  - Venous occlusion
  - Arterial occlusion (Percheron)



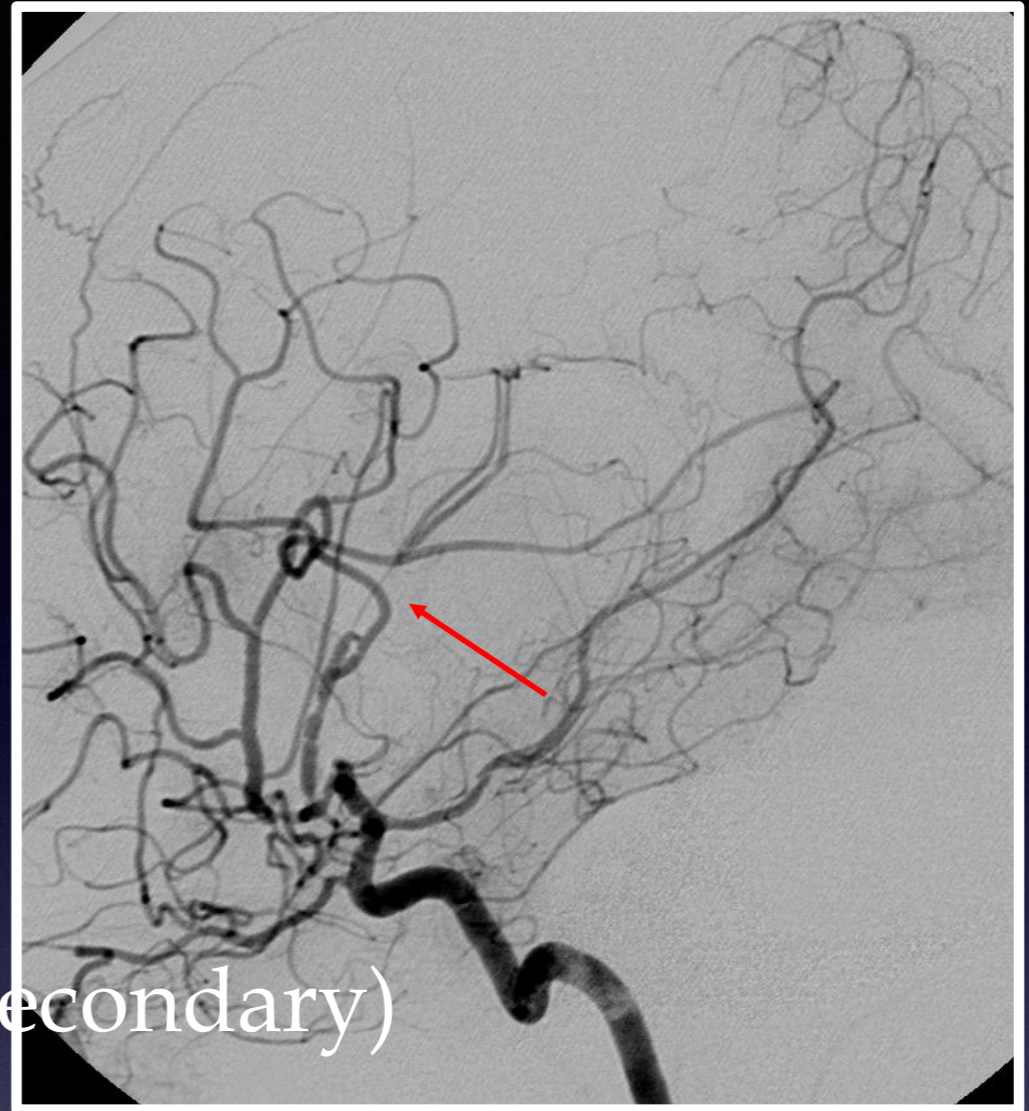
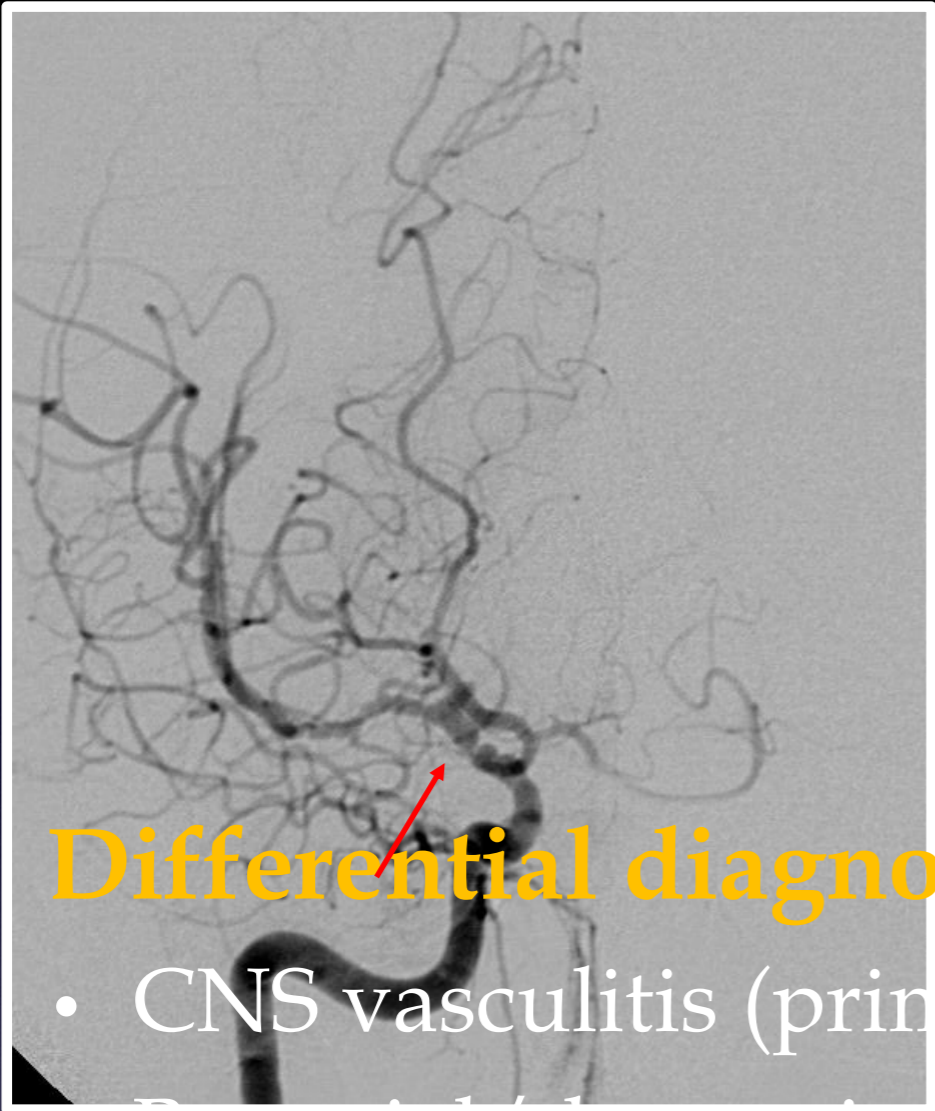
Internal cerebral vein and venous sinus thrombosis



- 30 year old with severe headache and left upper + lower extremity weakness



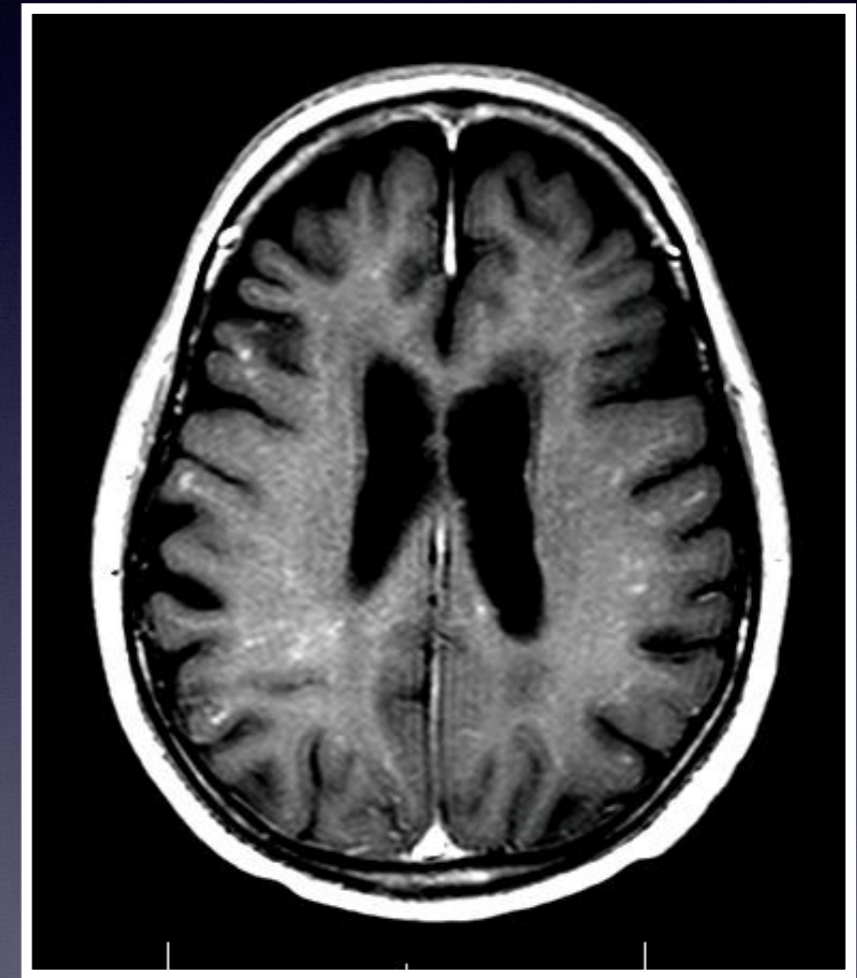
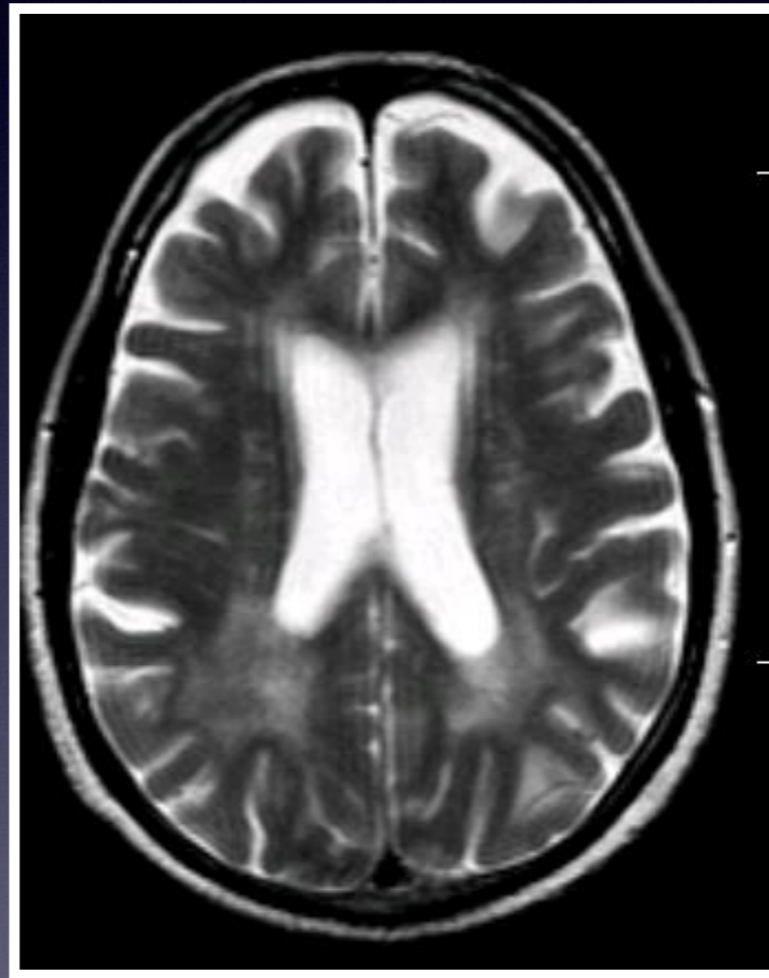
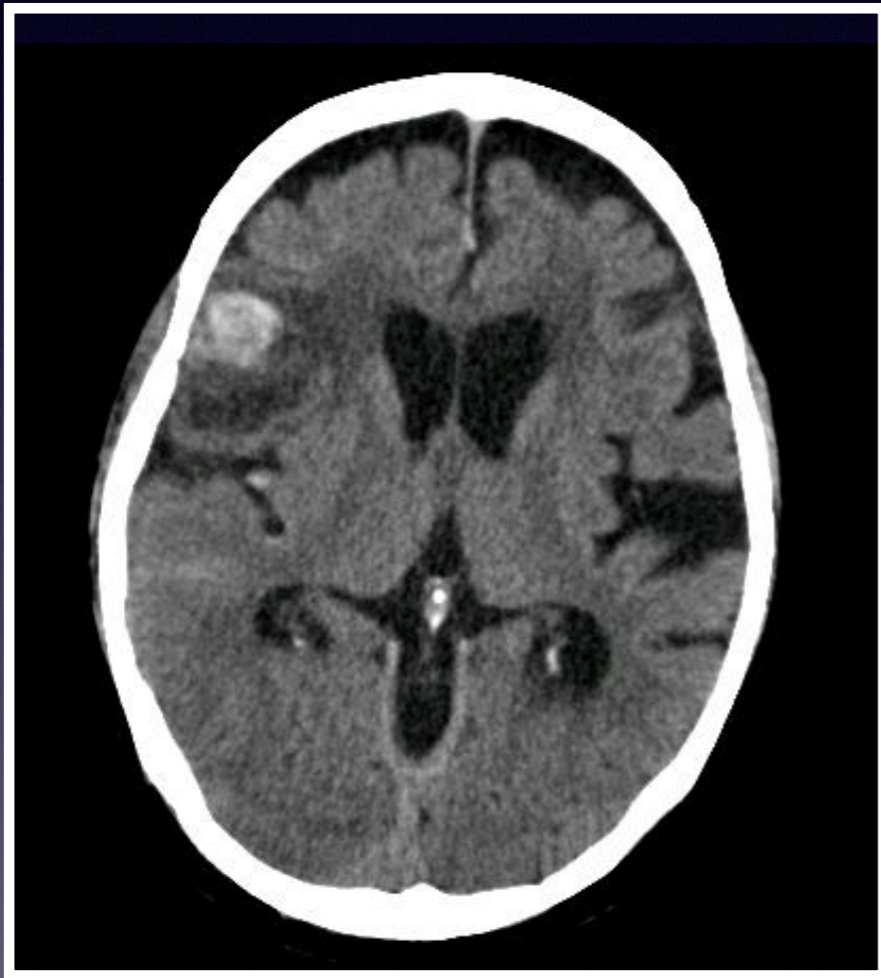



- **Differential diagnosis**

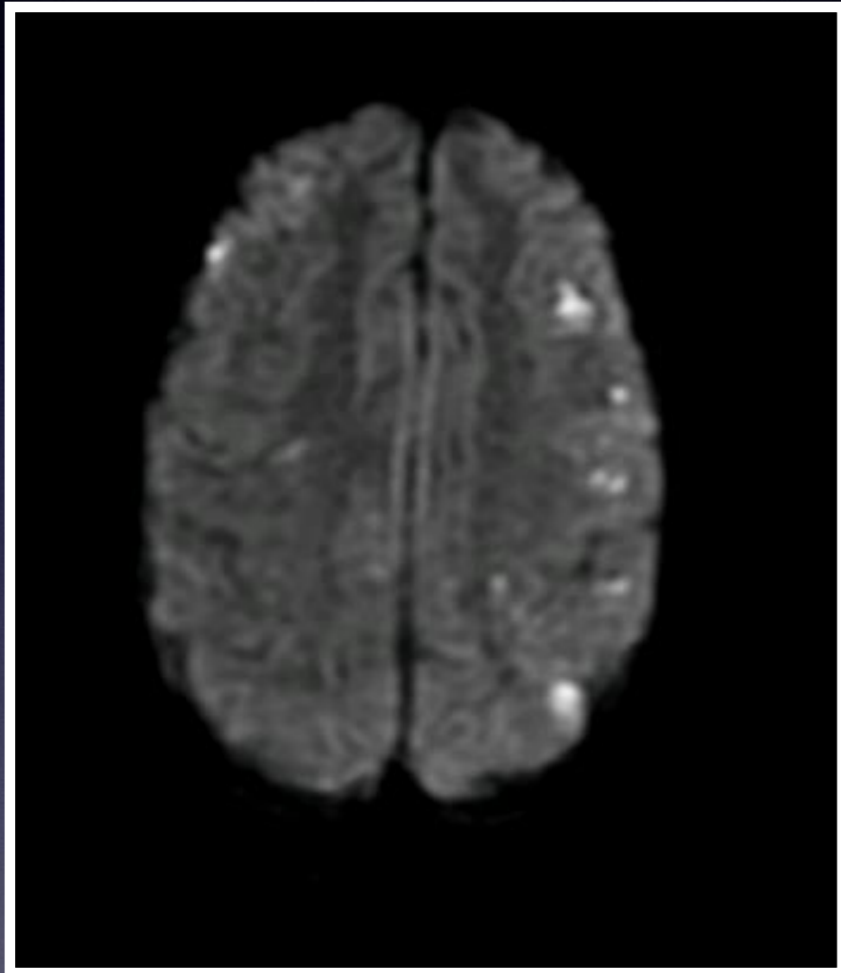
- CNS vasculitis (primary/secondary)
- Bacterial/tb meningitis
- Reversible cerebral vasoconstriction syndrome
- Cocaine/ Amphetamine related vasculopathy

# Primary CNS angiitis

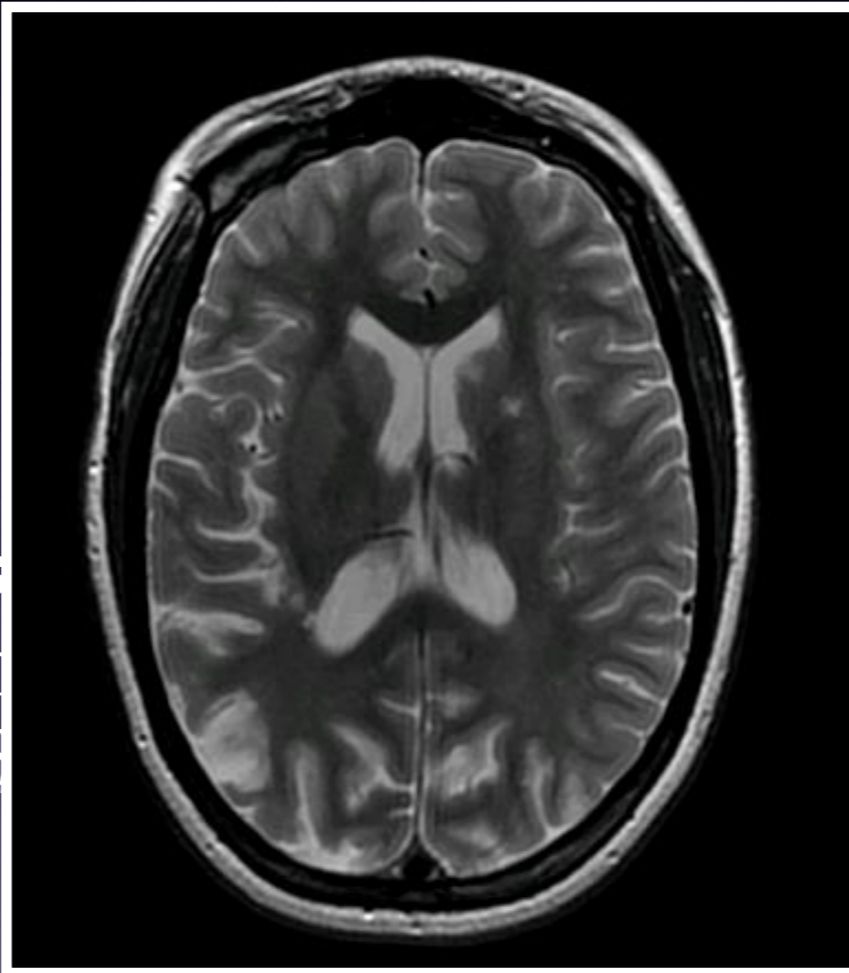


# CAPS

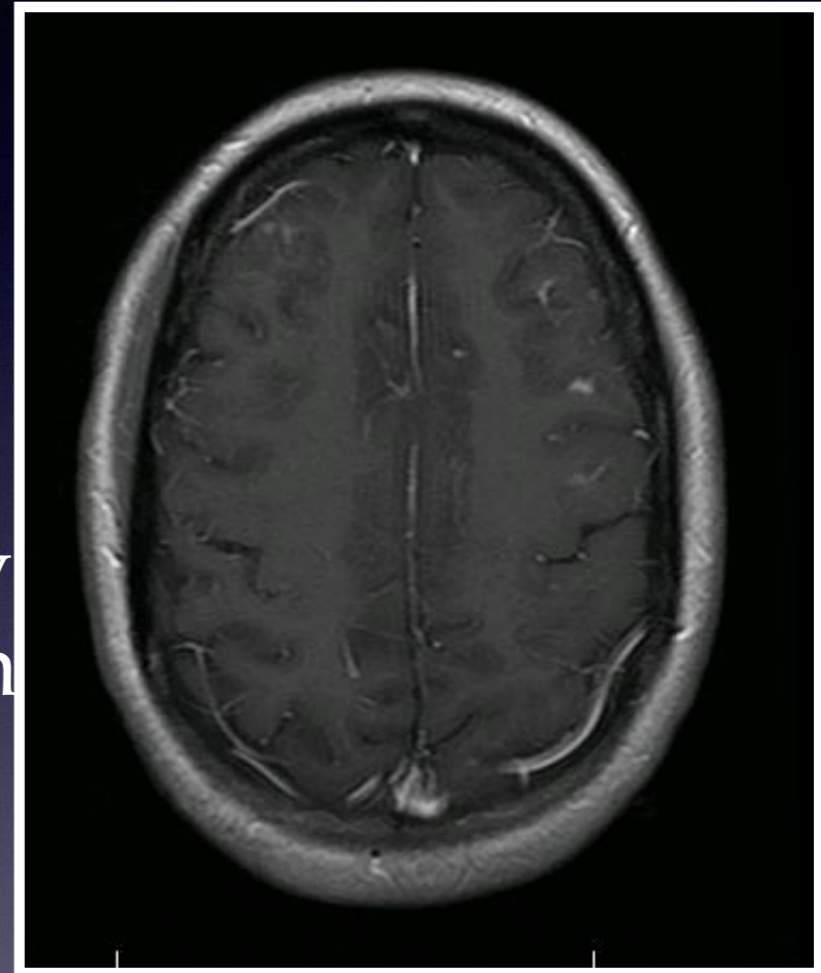
## Cerebral antiphospholipid syndrome



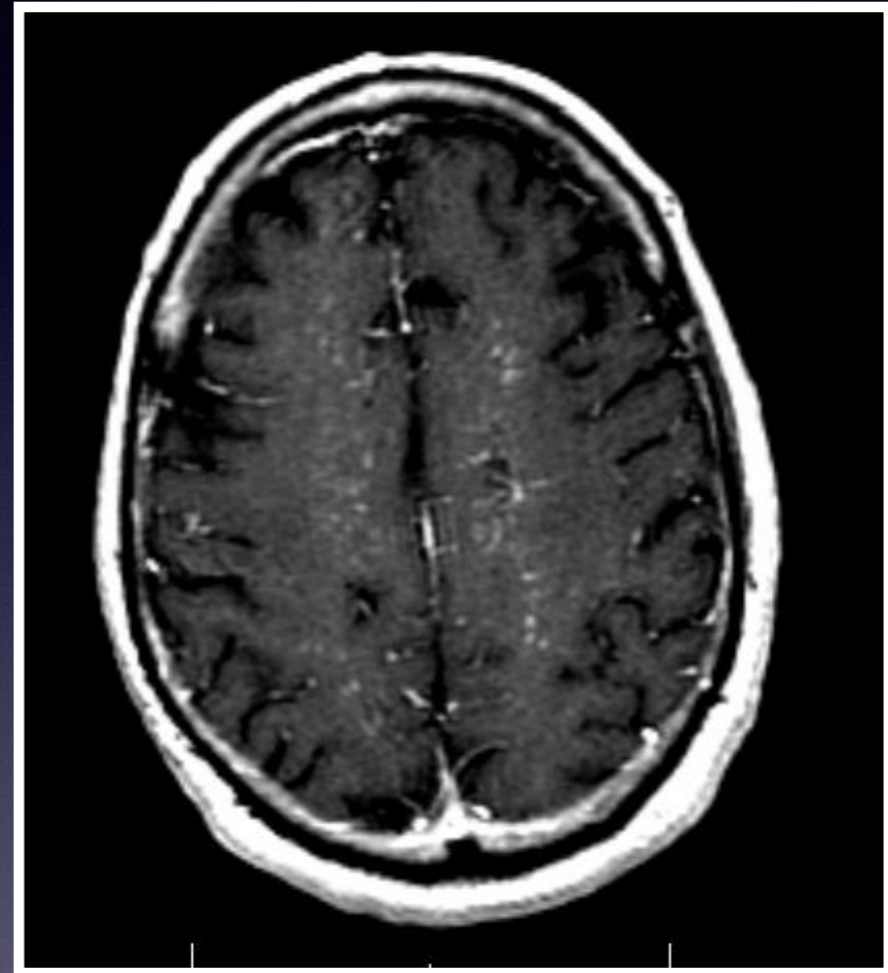
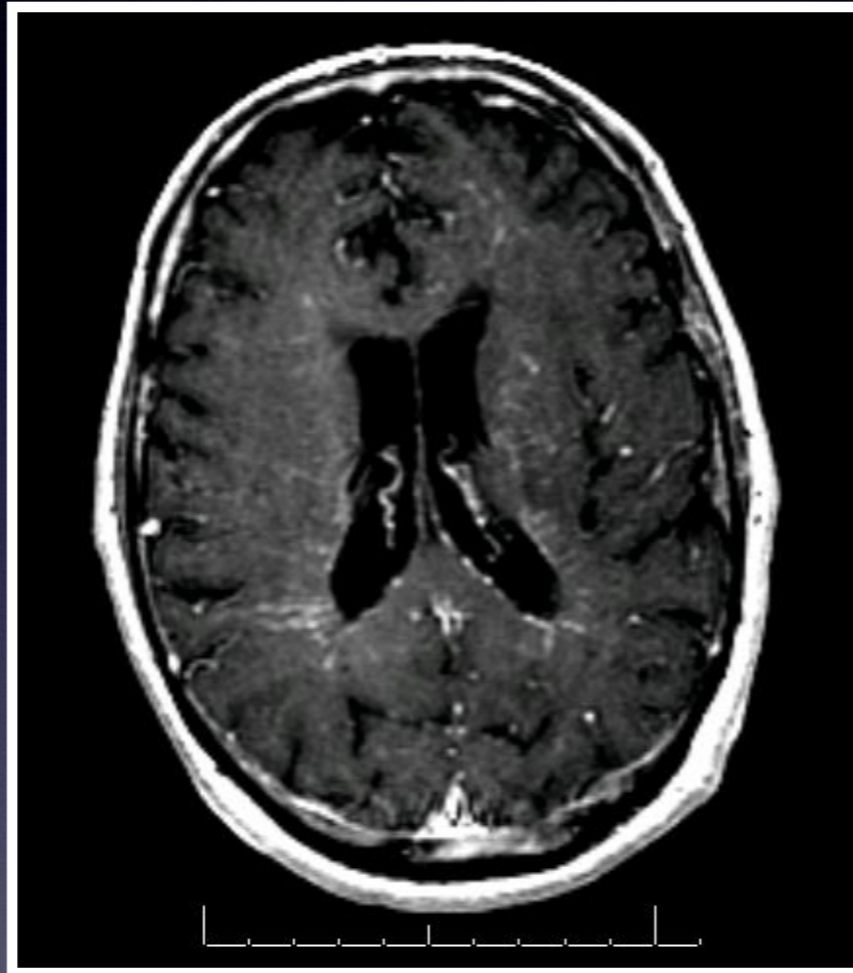
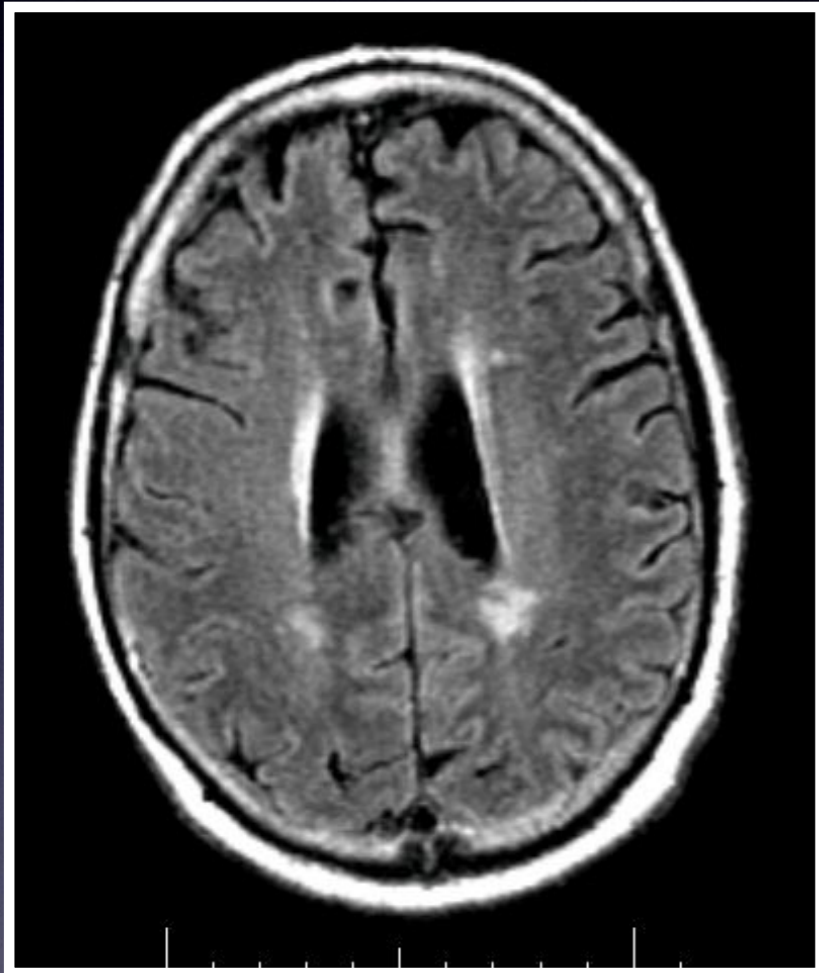
is  
oc  
nd



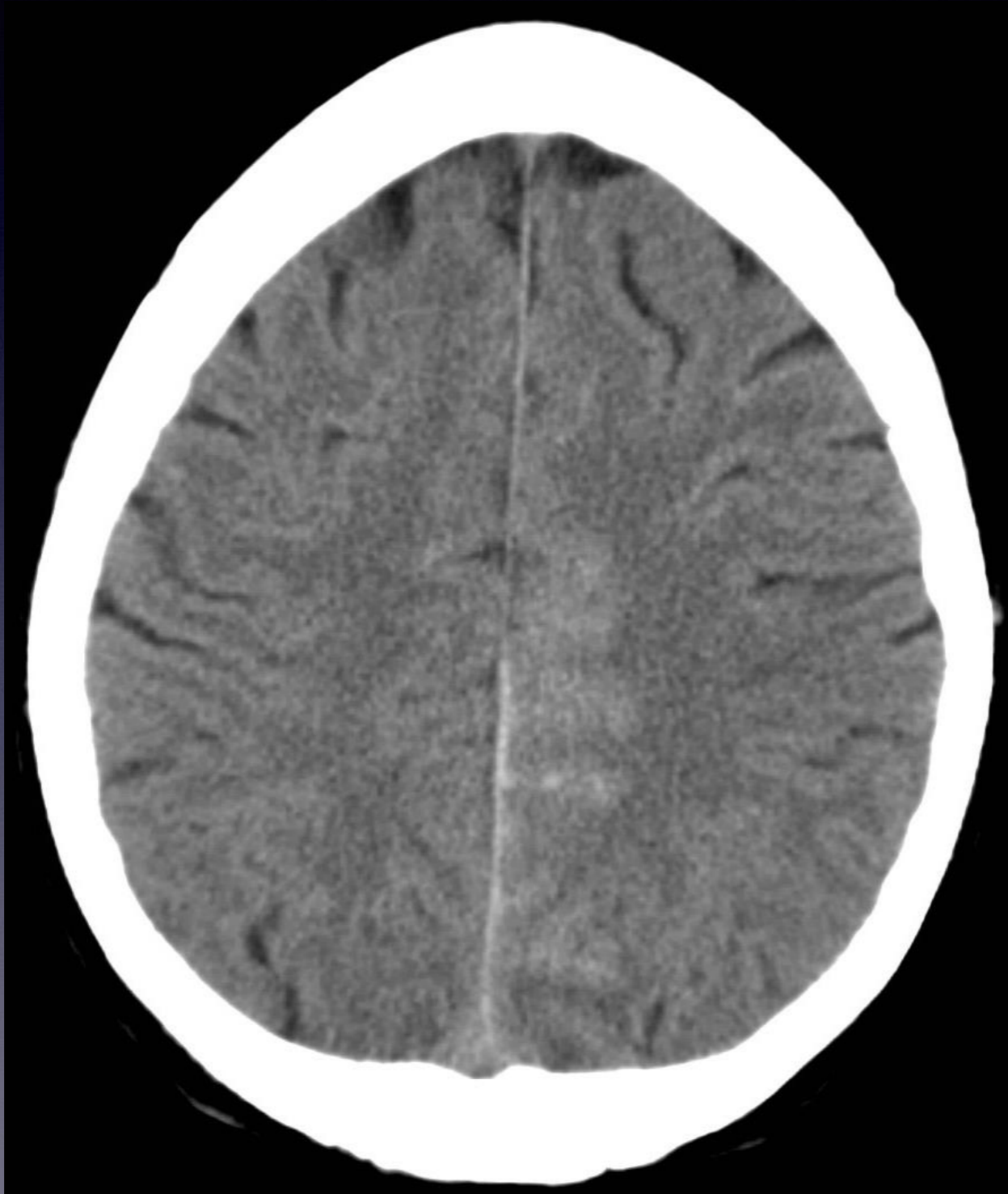
y  
n

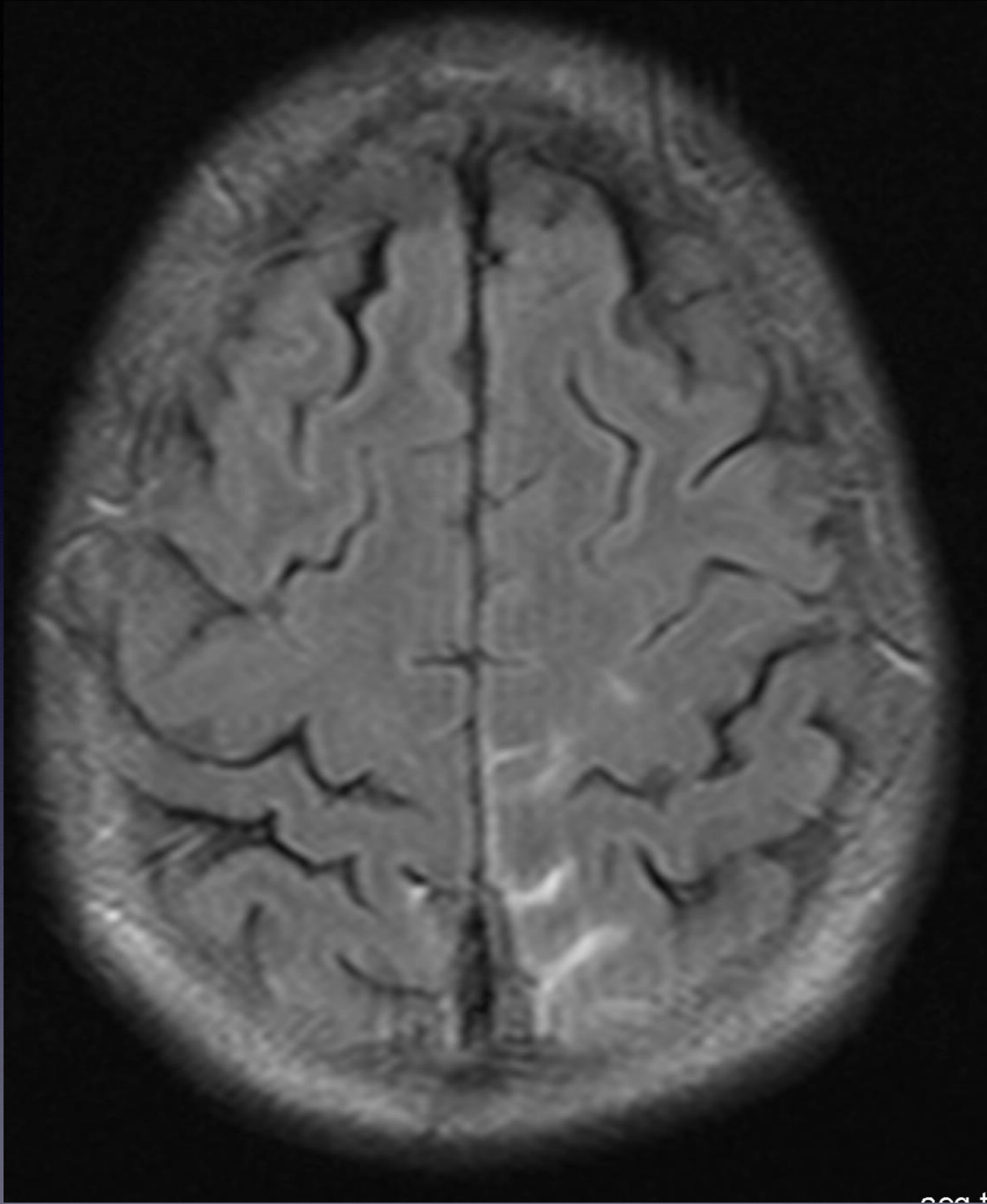


# Angiocentric Lymphoma/ Lymphoid granulomatosis (rare form of NHL)

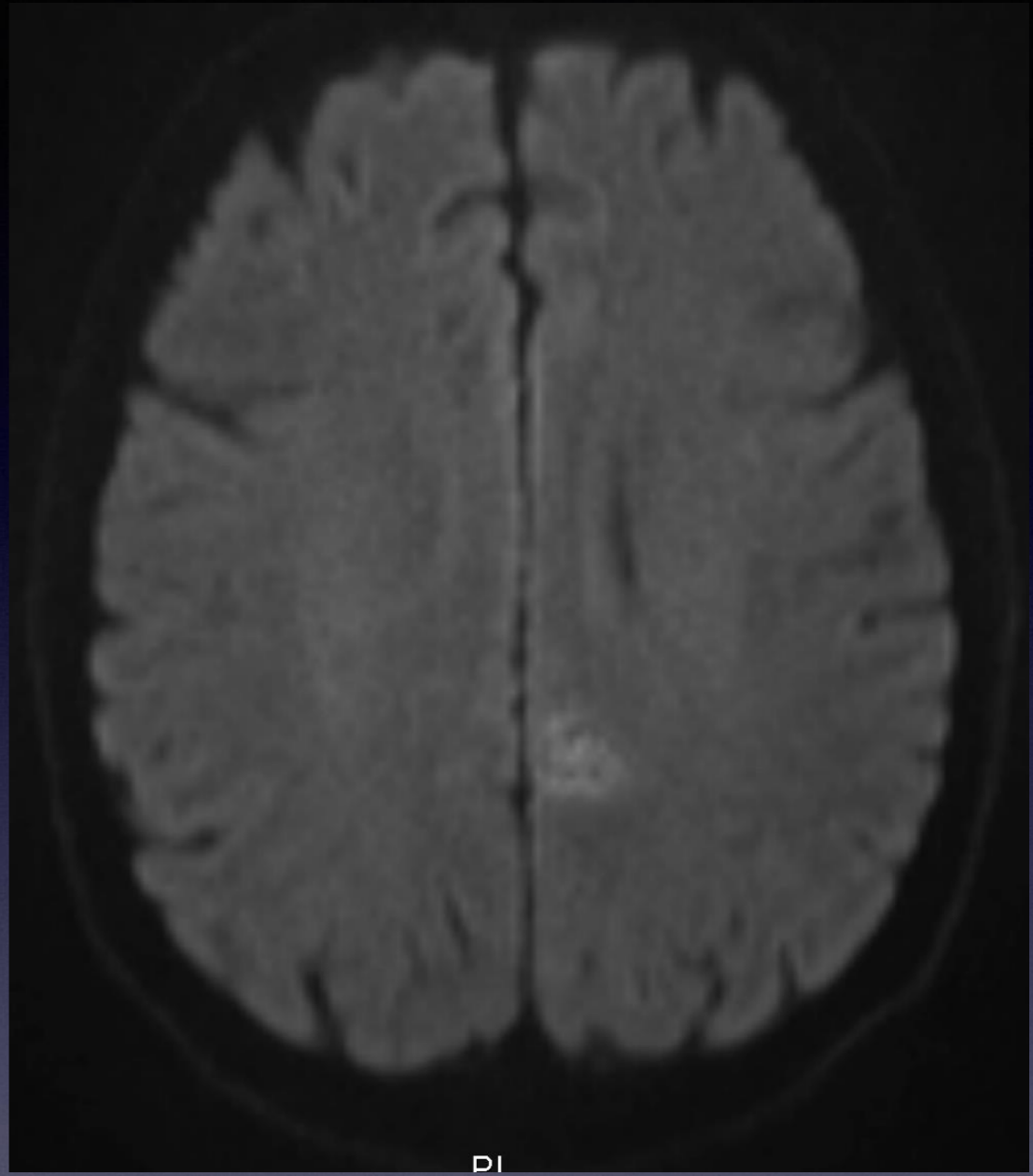


**54 male acute onset HA**

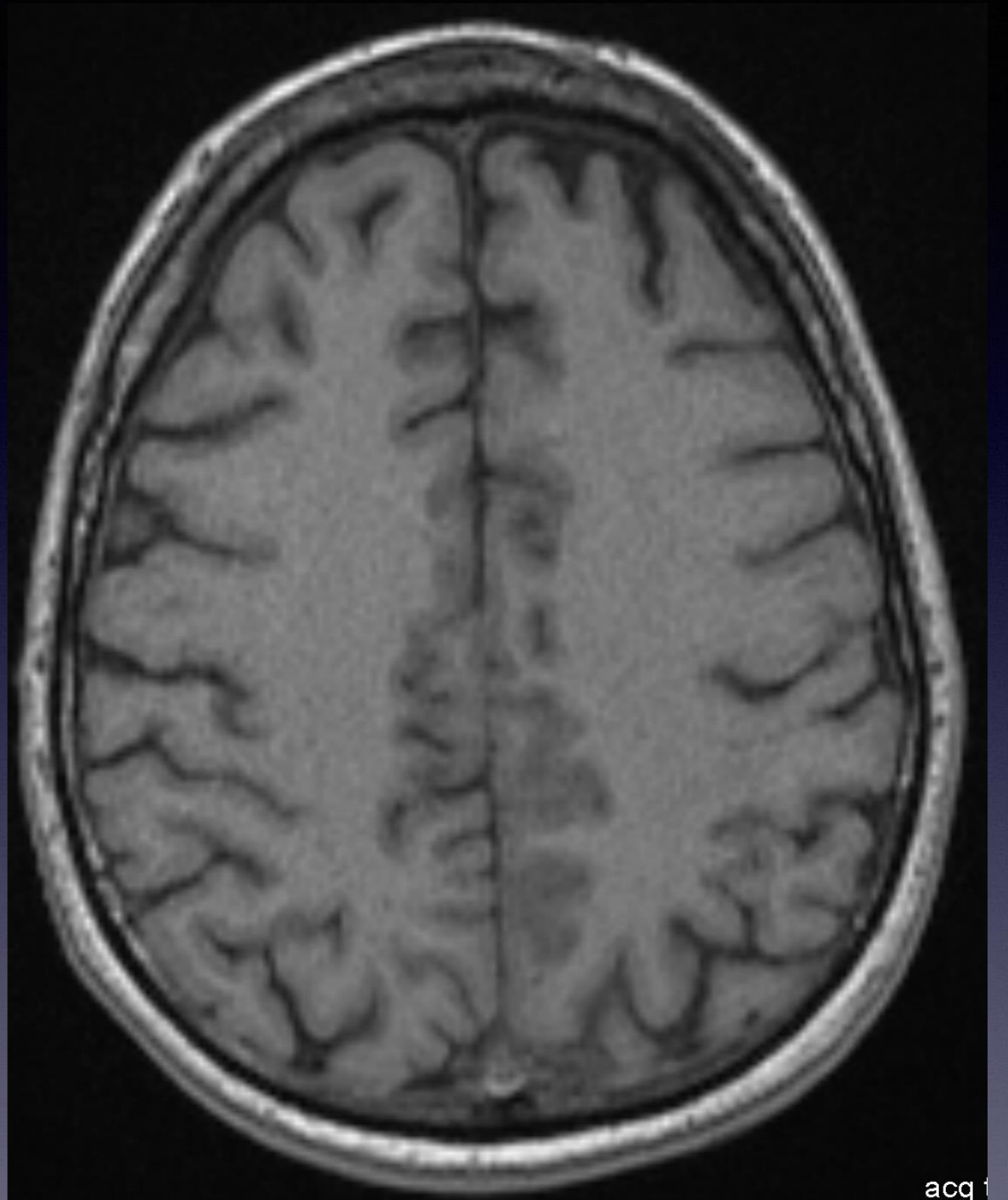
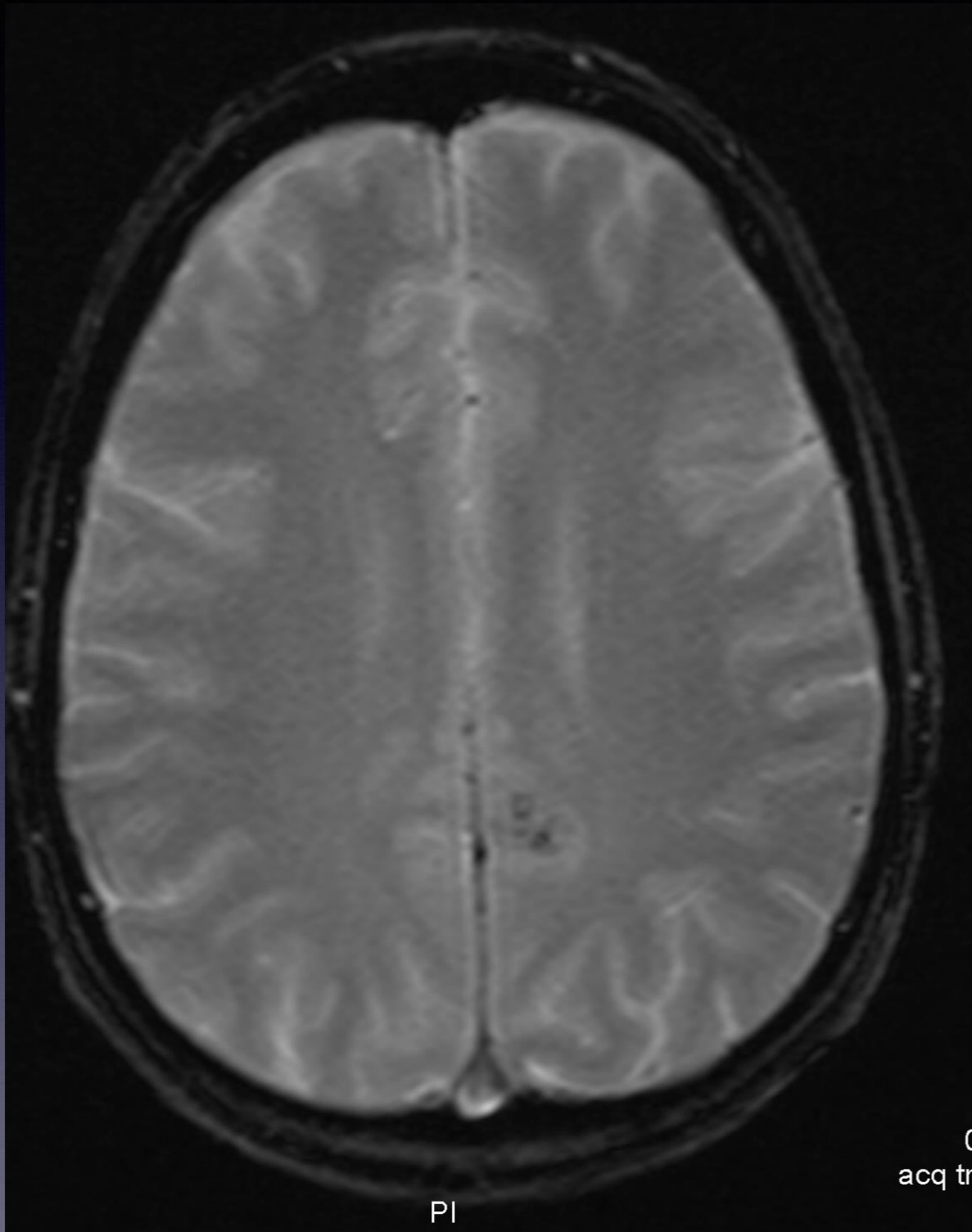


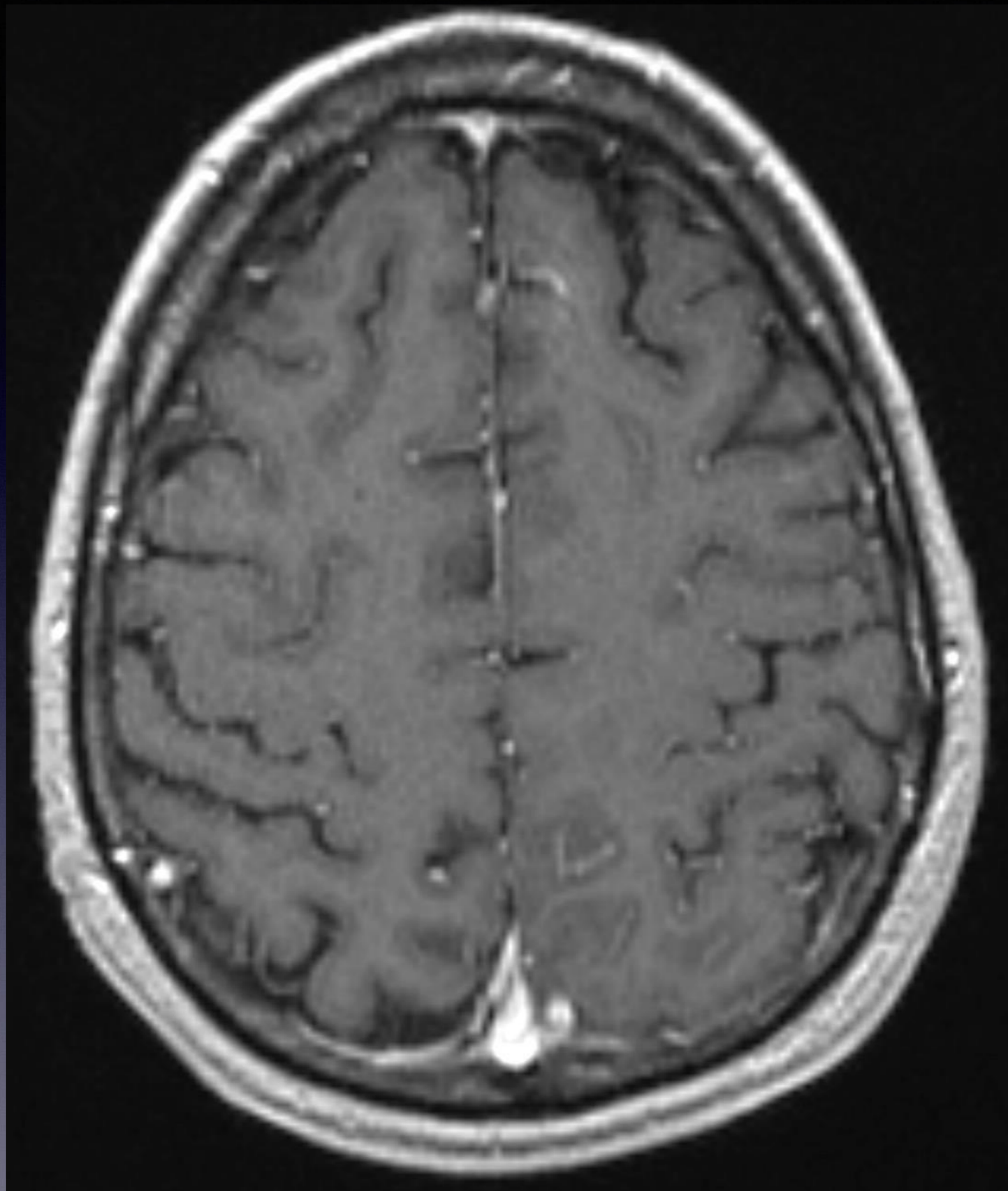


009 +

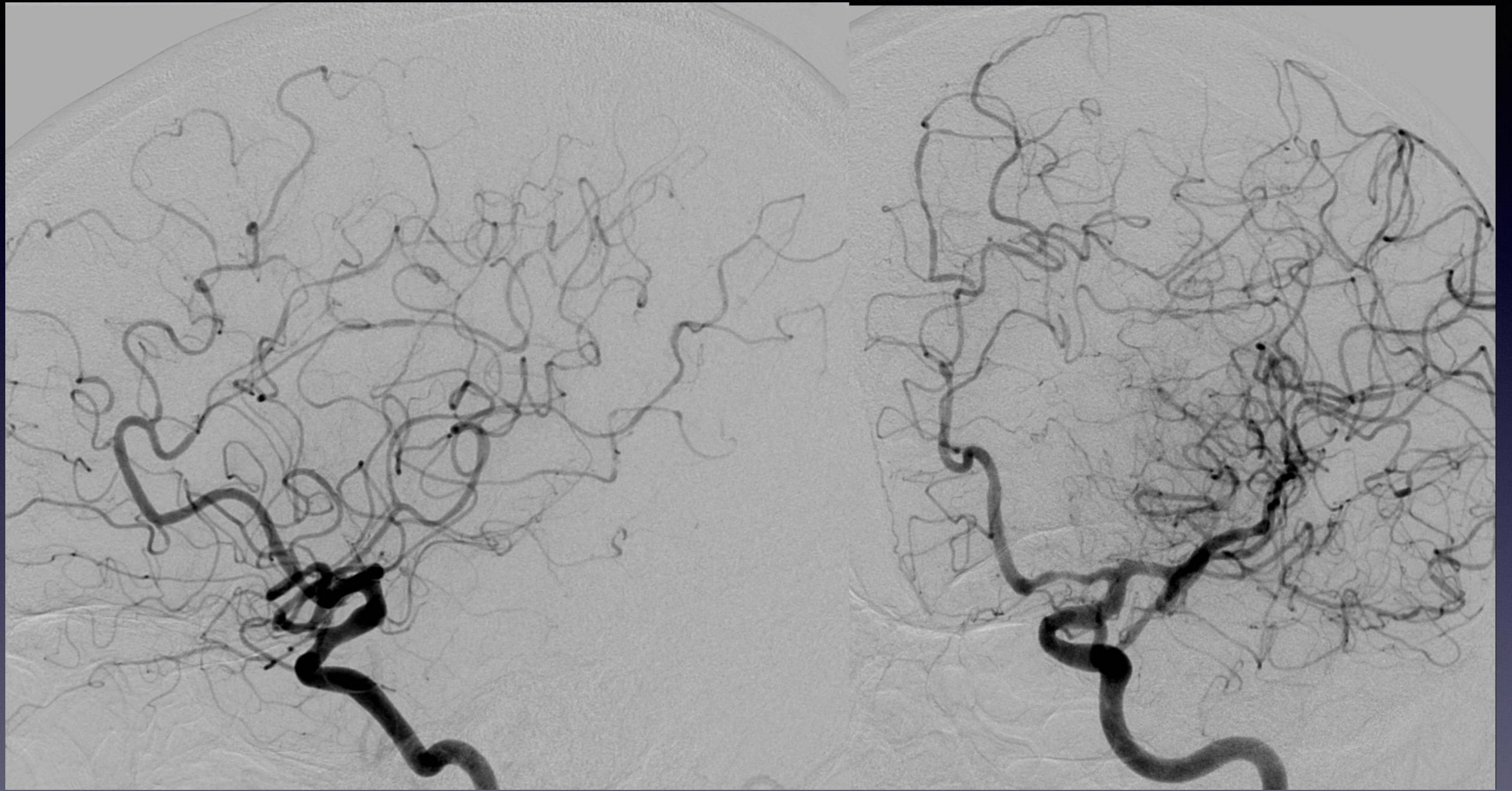


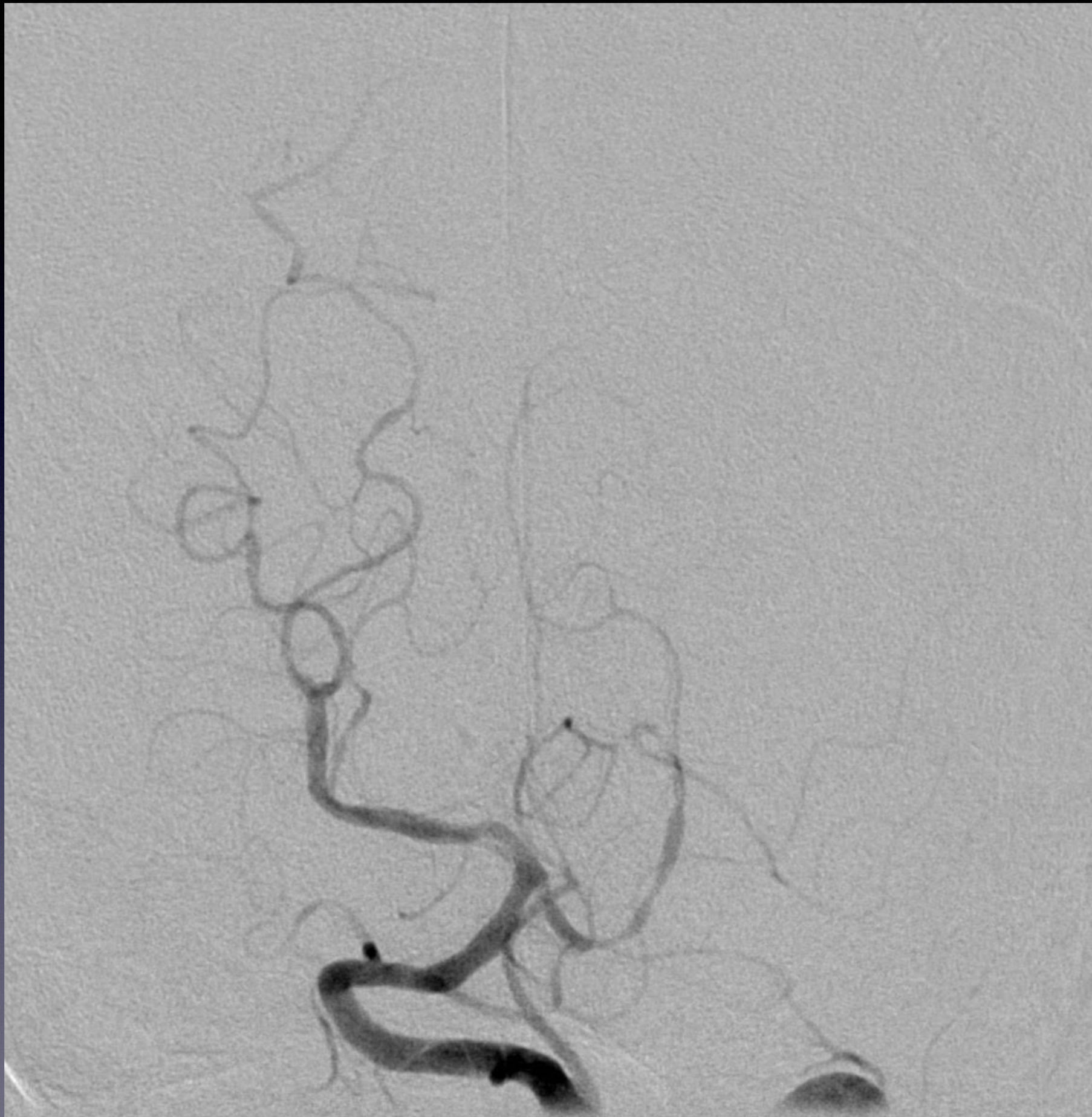PI









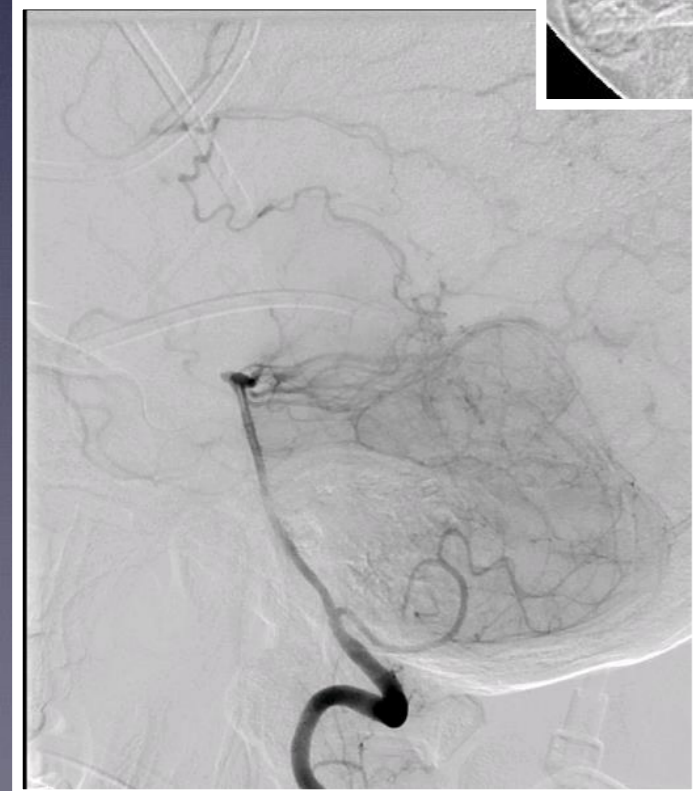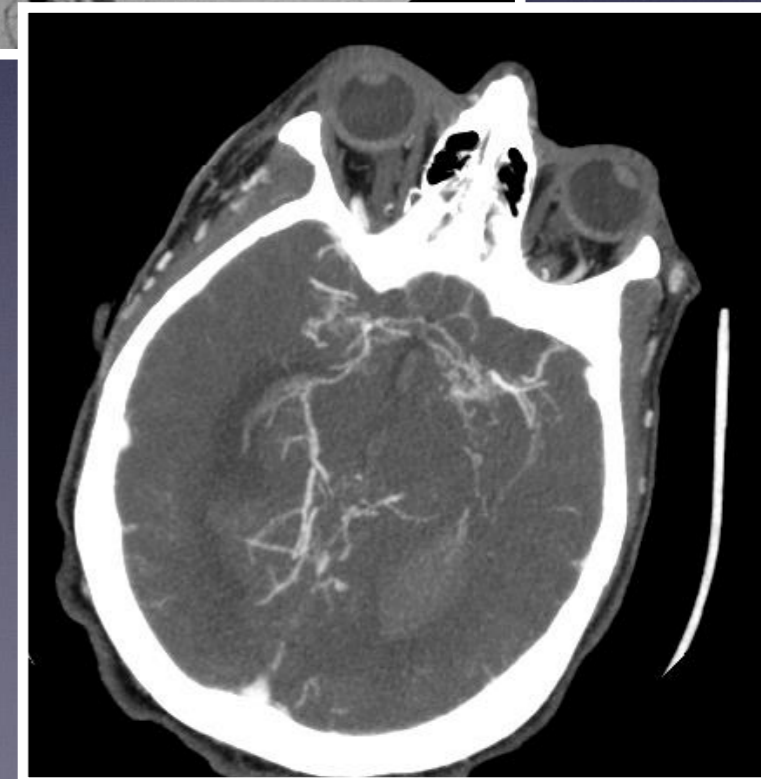
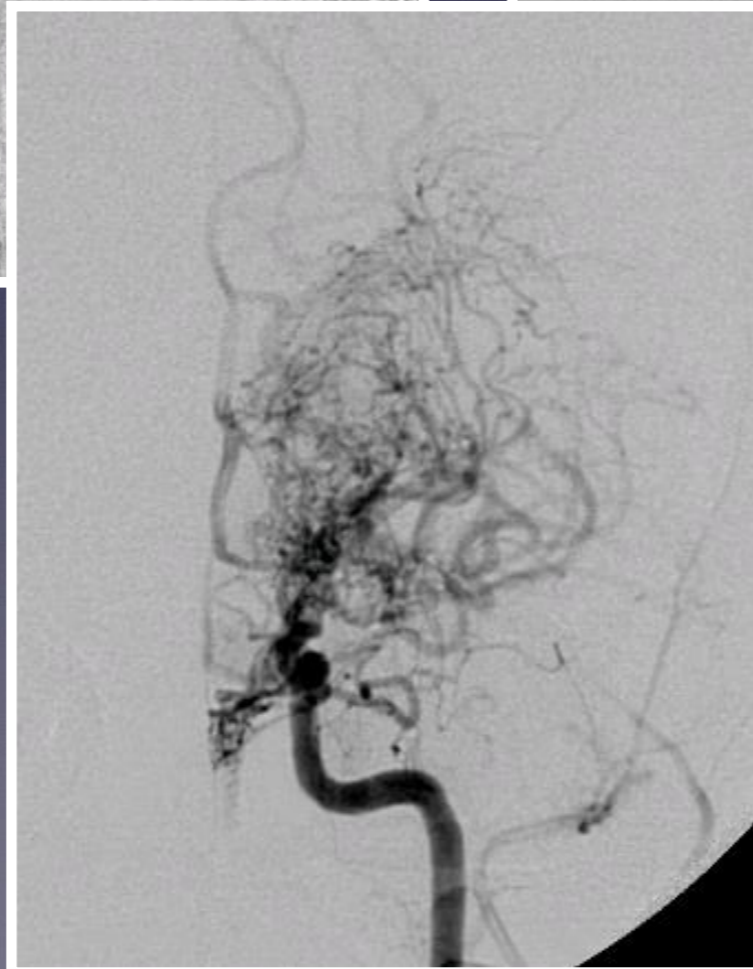
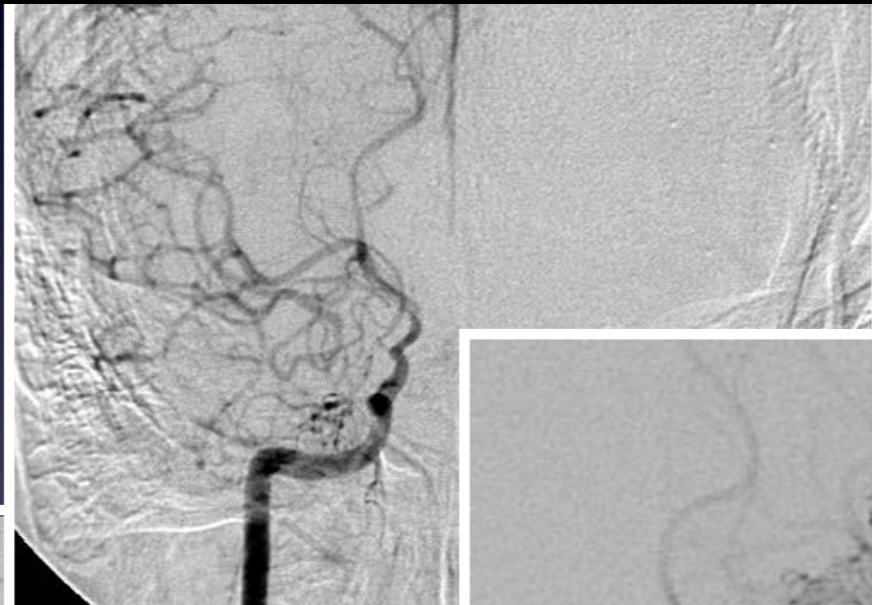
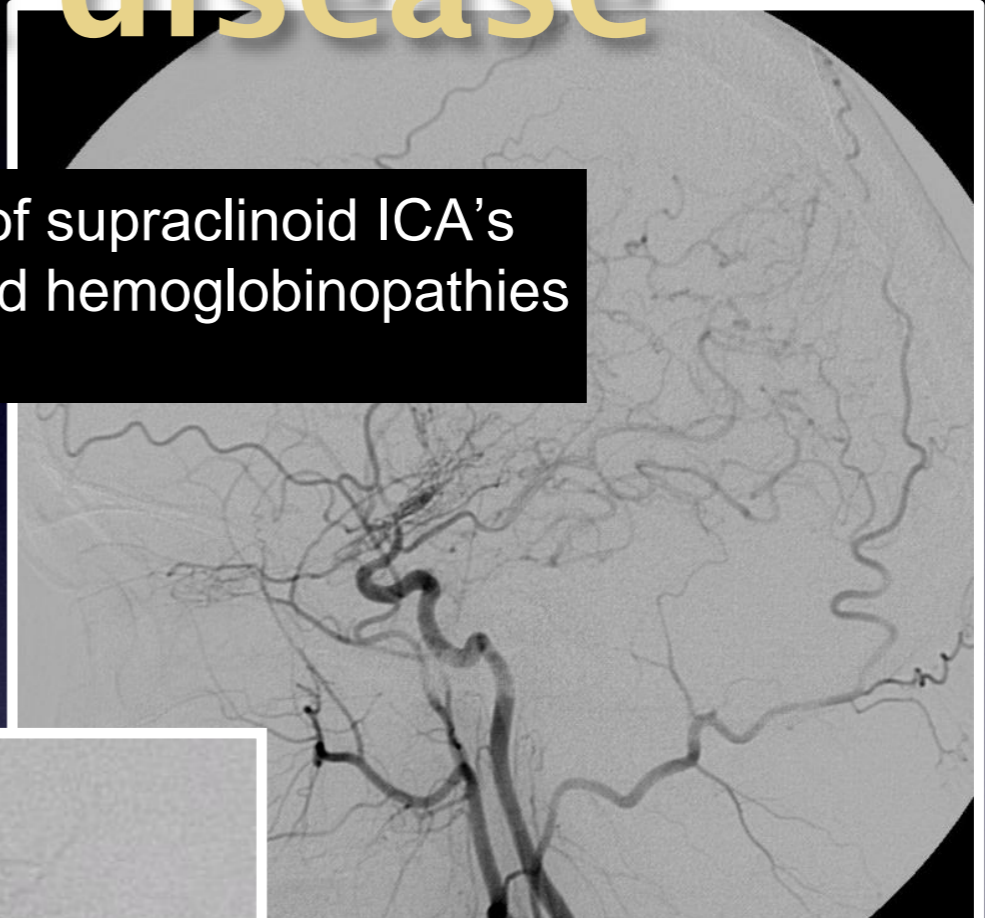
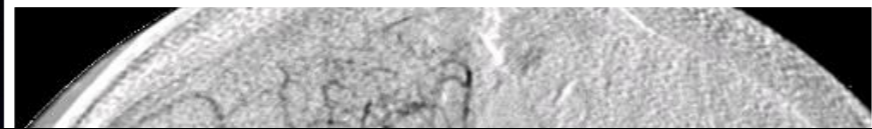


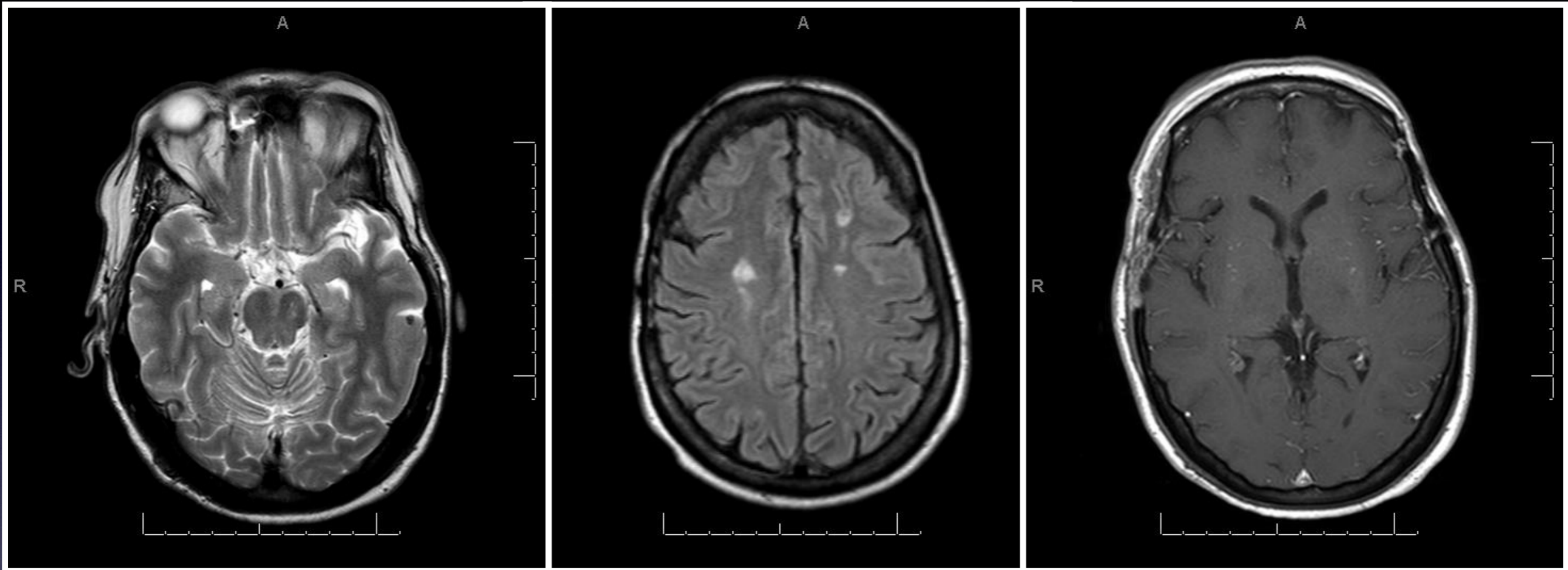
# CNS Vasculitis

- Vasculitis - **diffuse angiopathy**
  - primary angiitis of CNS PACNS
  - Benign angiopathy of CNS BACNS
  - systemic vasculitis
  - atherosclerosis
  - intravascular lymphoma
  - preeclampsia
  - cocaine use

# Moya-moya disease

- Idiopathic progressive arteriopathy occlusion of supraclinoid ICA's
- Syndrome: associated with NF1, trisomy 21, and hemoglobinopathies such as sickle cell anemia





metast

- DSA: dg, staging

# Σημαντικά Μυνηματα

- Απεικόνιση στο ισχαιμικό ΑΕΕ-Triage για ενδοαγγειακή θεραπεία
- Συνδυασμός των απεικονιστικών μεθόδων αποτελεί συχνά κλειδί για τη διάγνωση της αιτίας της υπαραχνοειδούς αιμορραγίας
- Επαναληπτικές αγγειογραφίες χρήσιμες στις υπαραχνοειδείς αιμορραγίες λόγω της δυναμικής φύσης των αγγειακών βλαβών



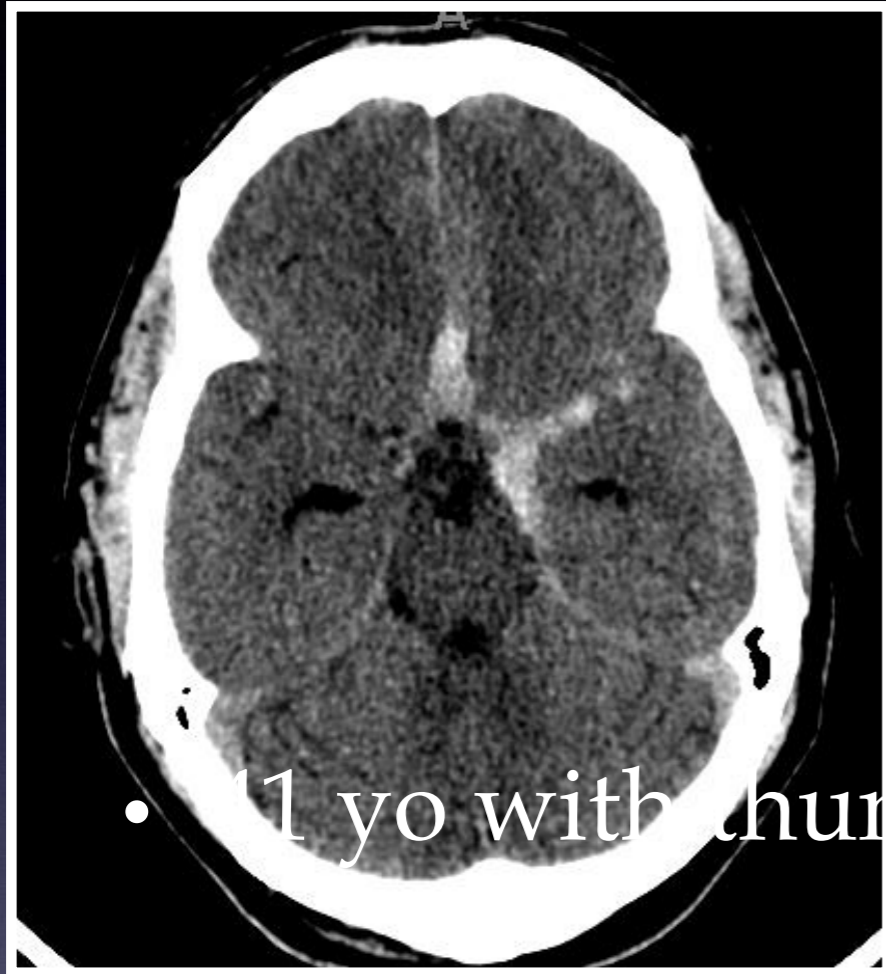




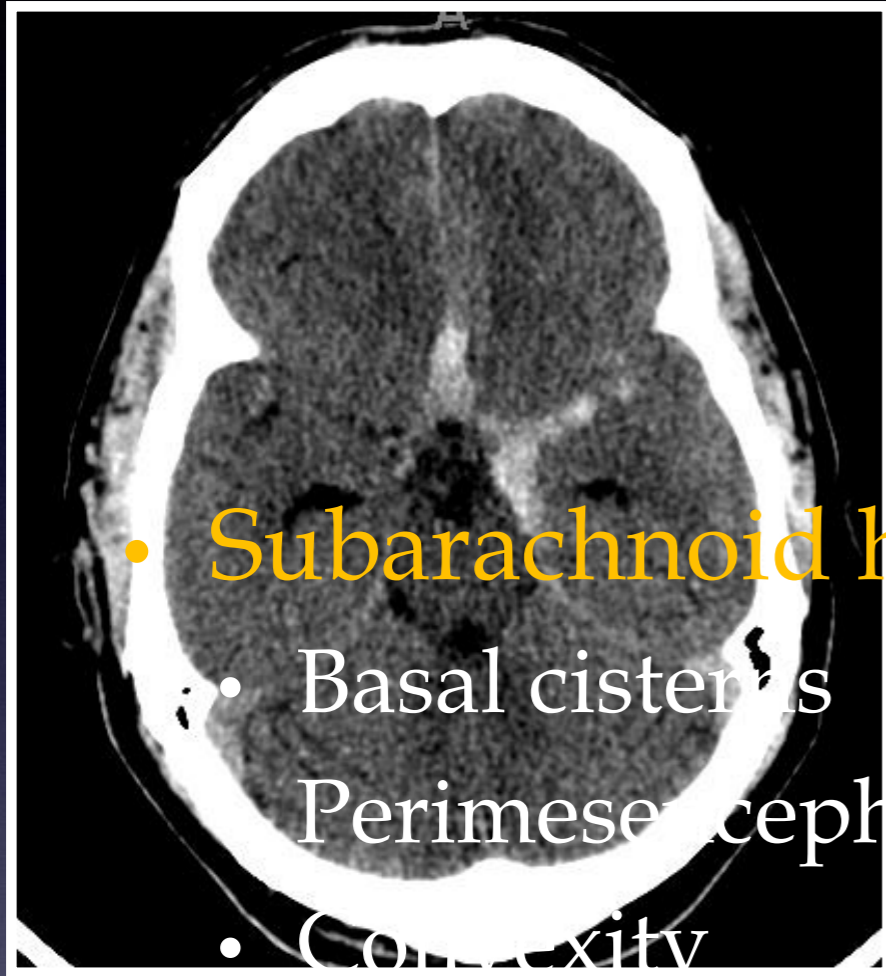








- 11 yo with thunderclap headache



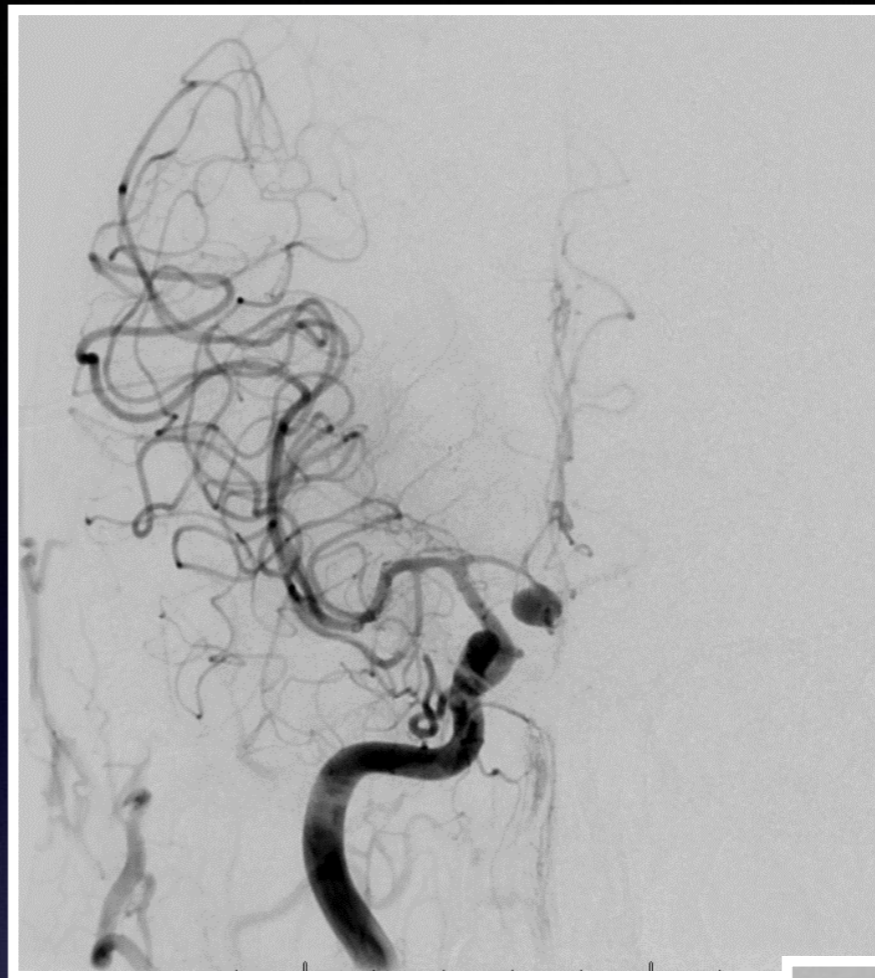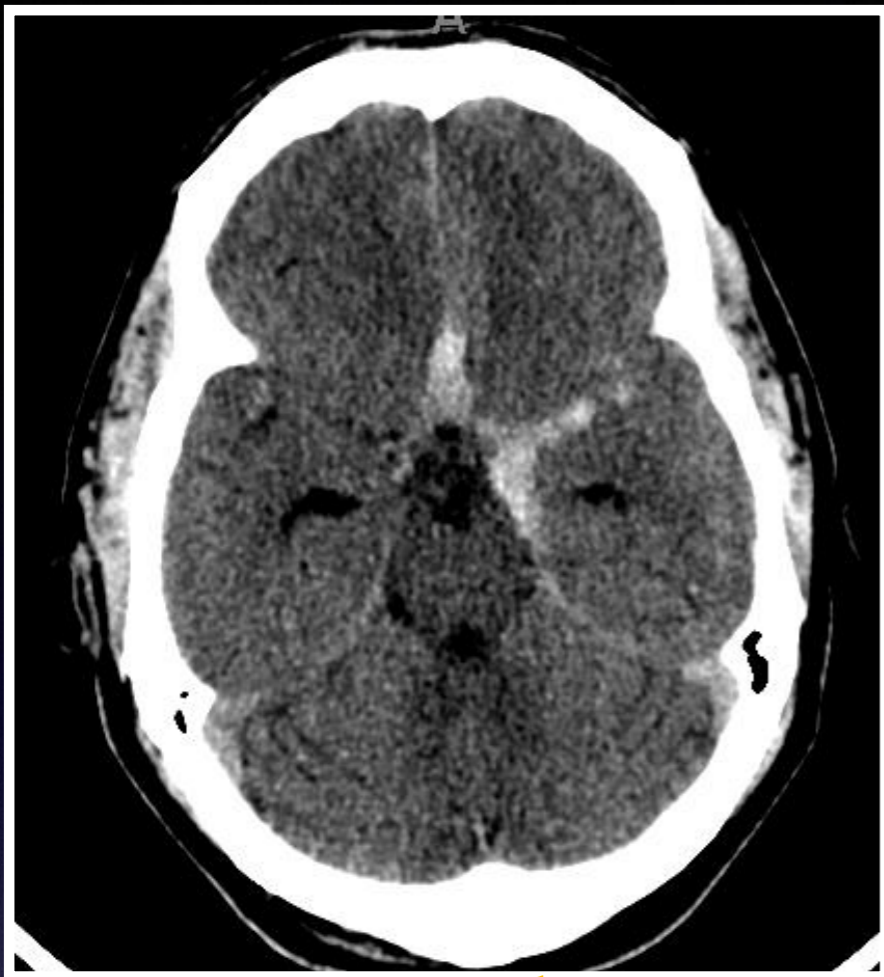
- Subarachnoid hemorrhage

- Basal cisterns

- Perimesencephalic

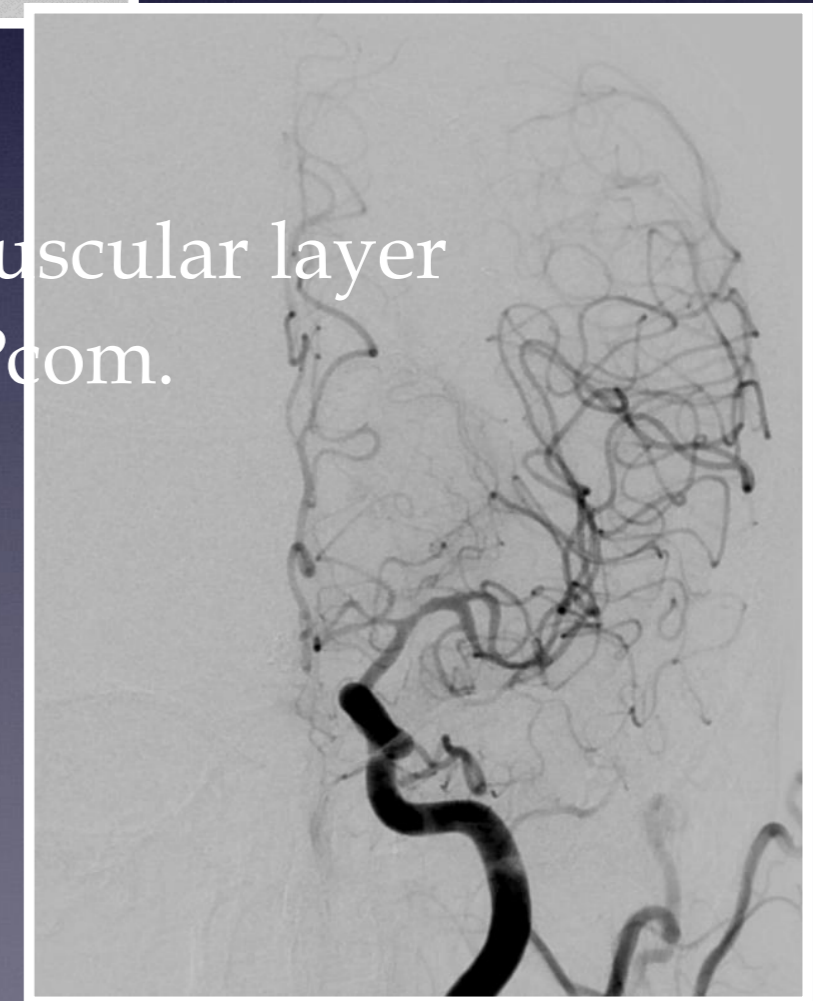
- Convexity

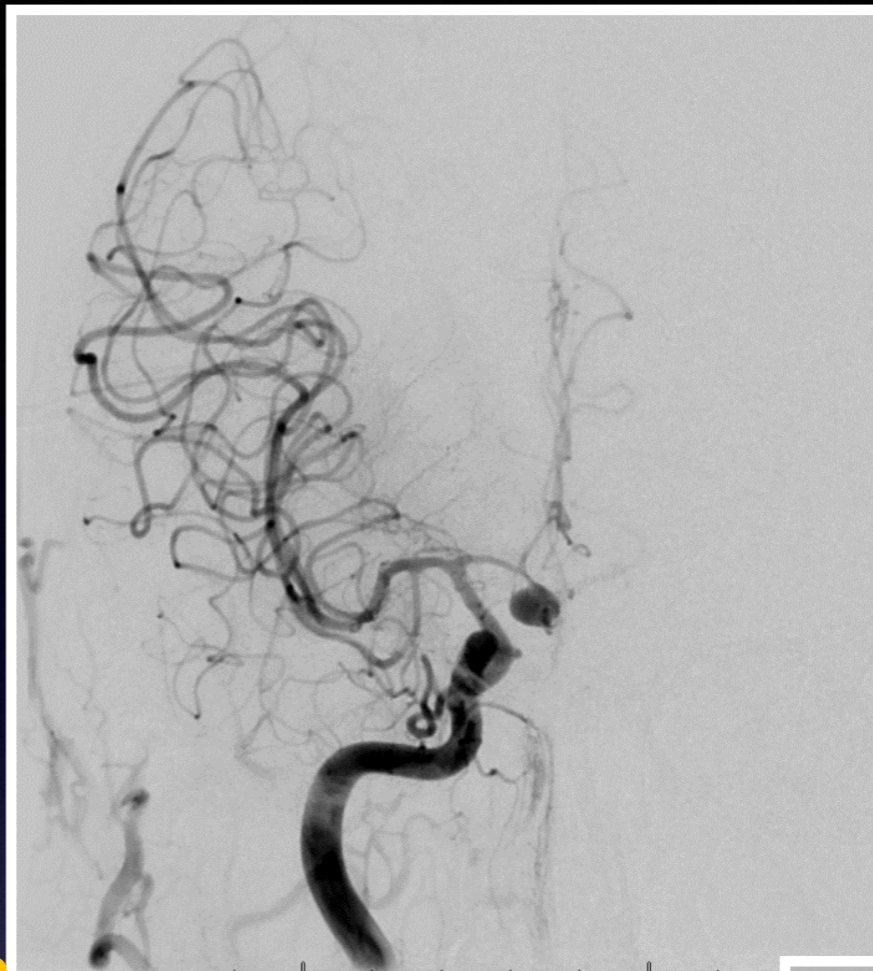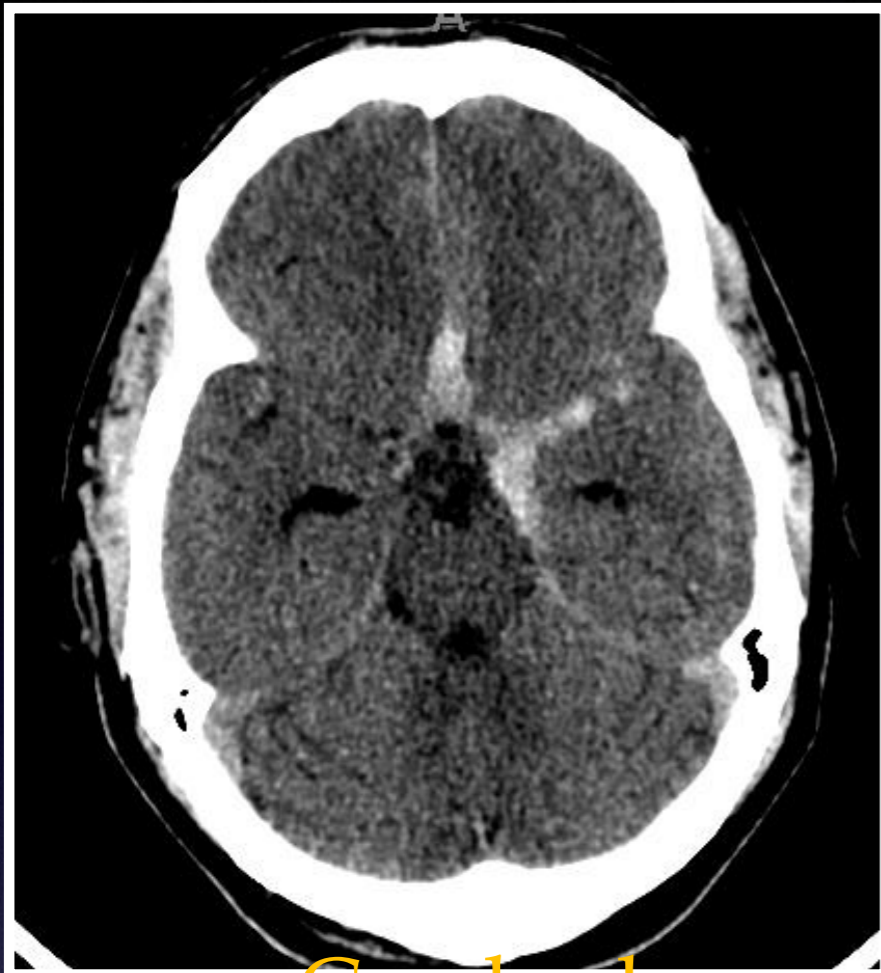- +/- IVH



- **Saccular aneurysms**

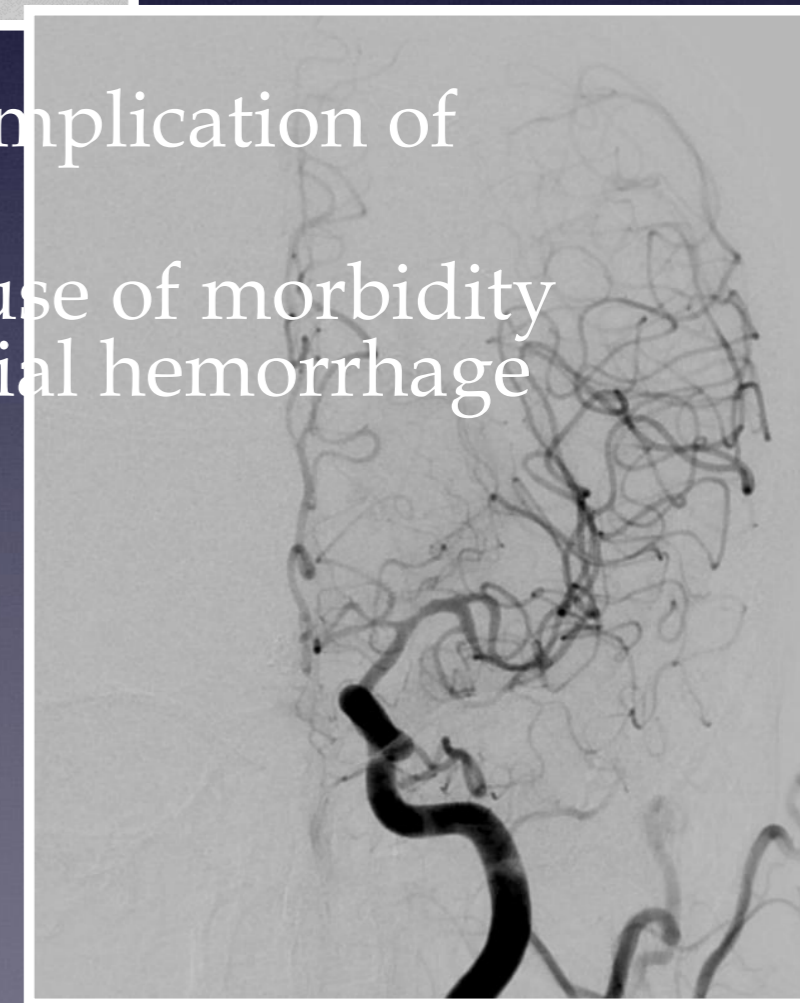
- 85-90% of SAH
- Lack the internal elastic lamina and the muscular layer
- CoW: 90% anterior circulation including Pcom.



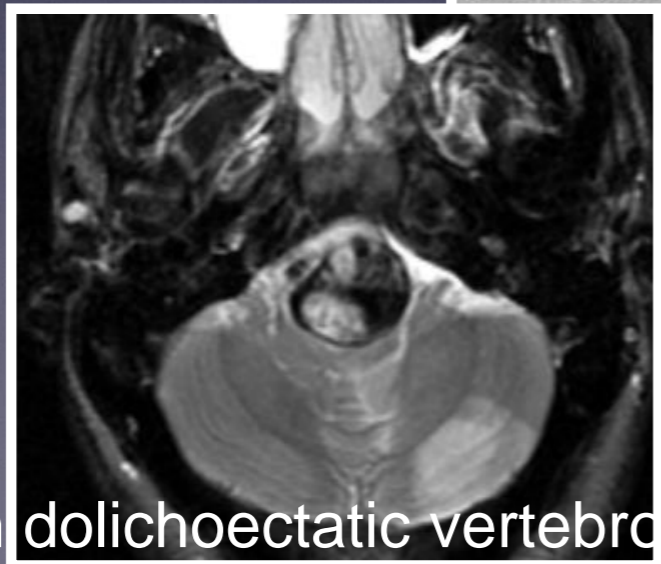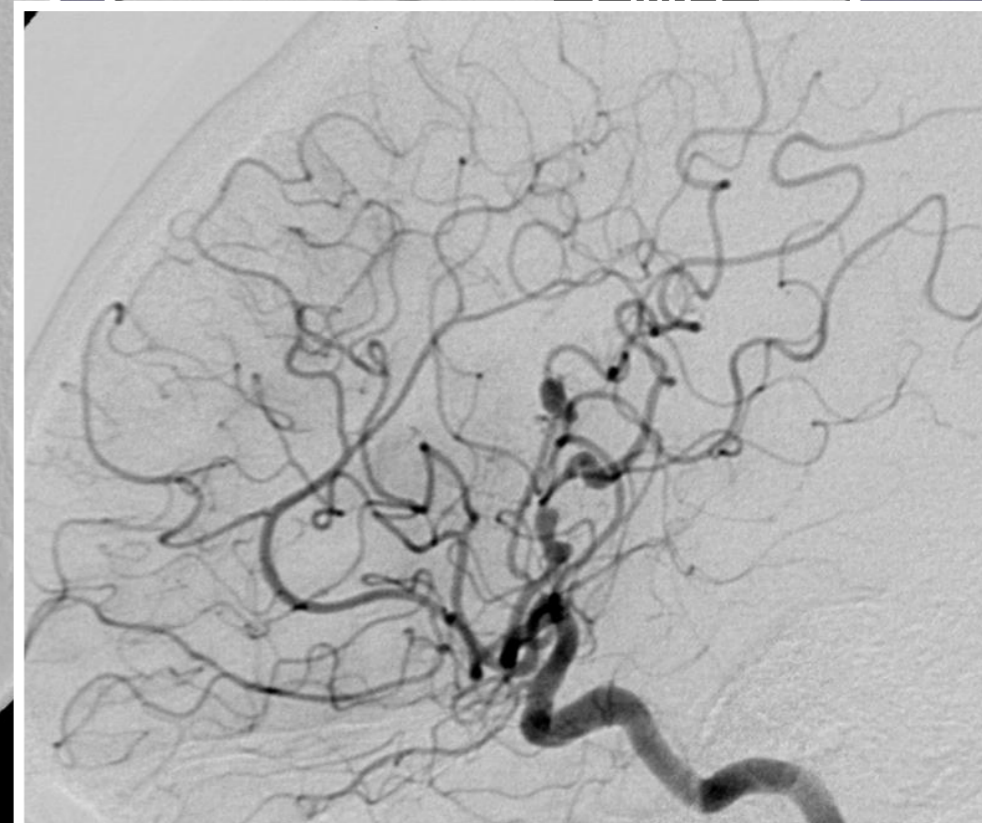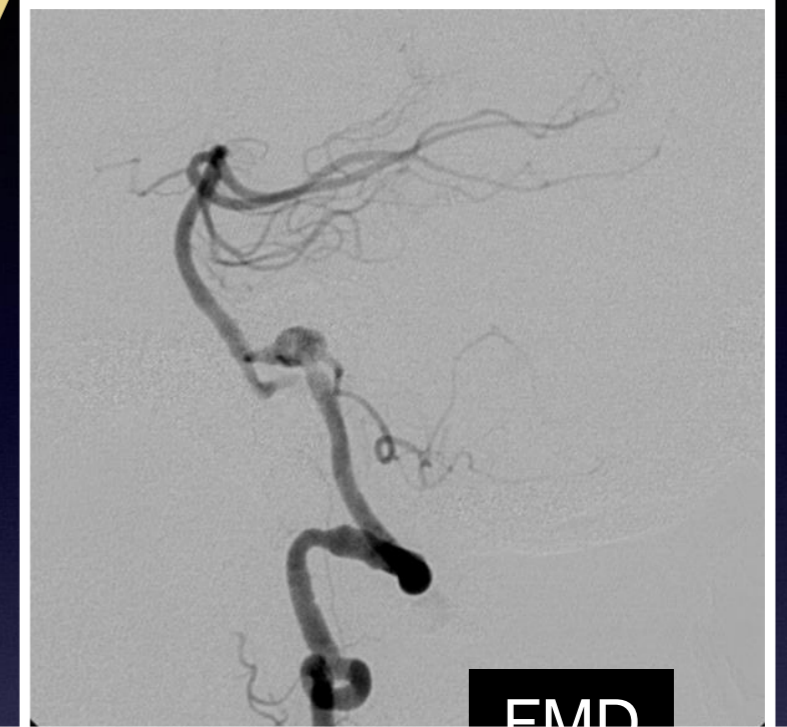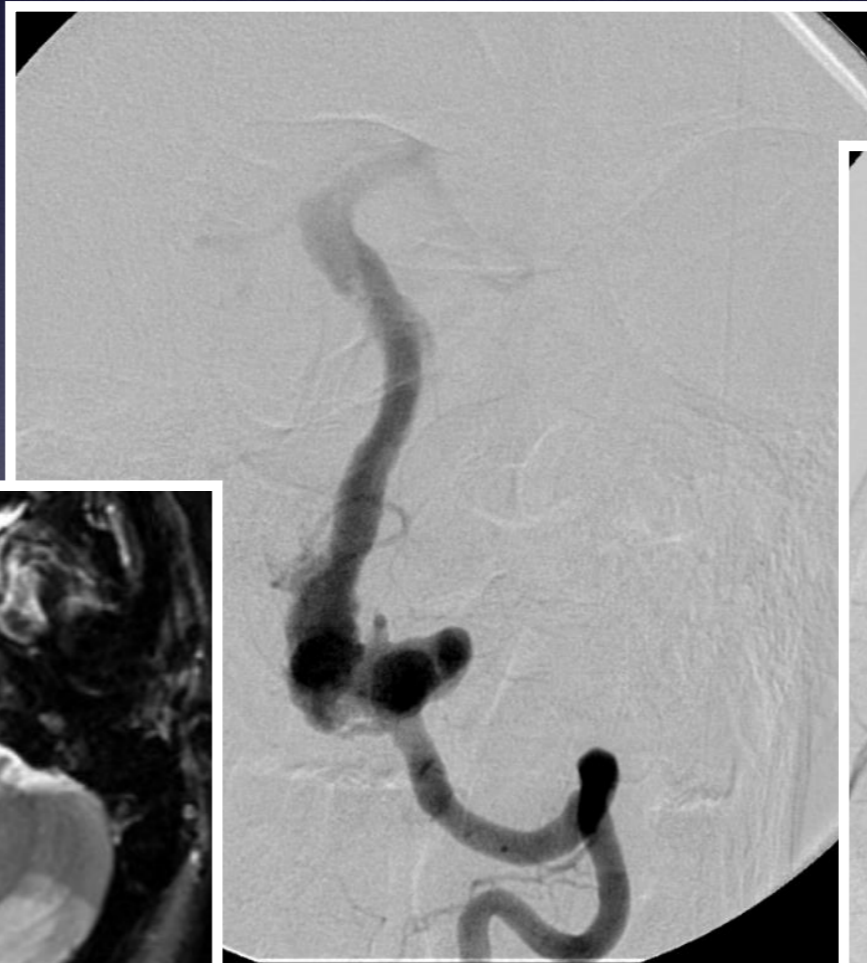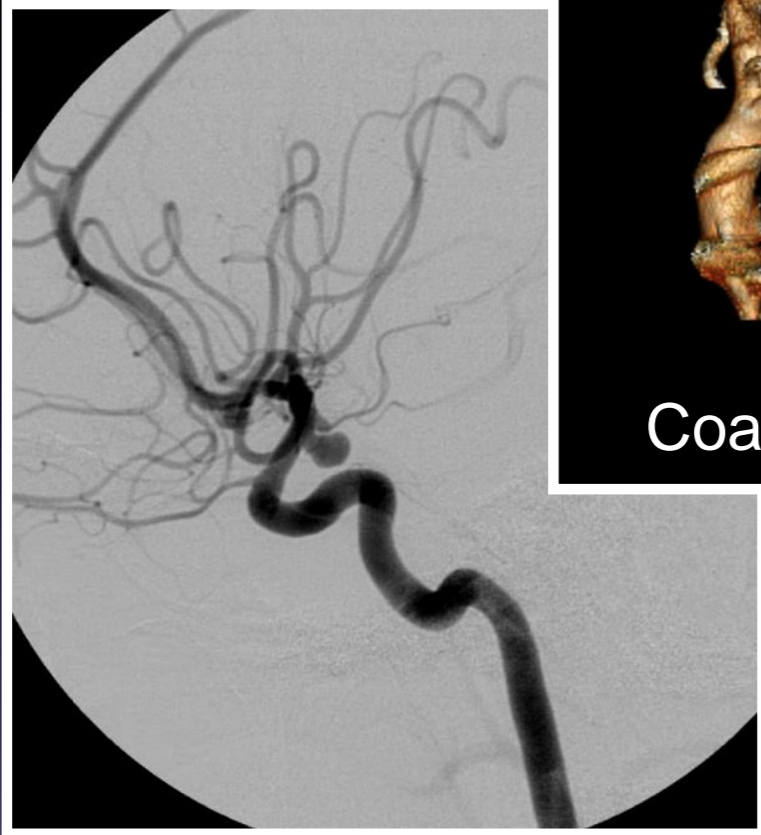
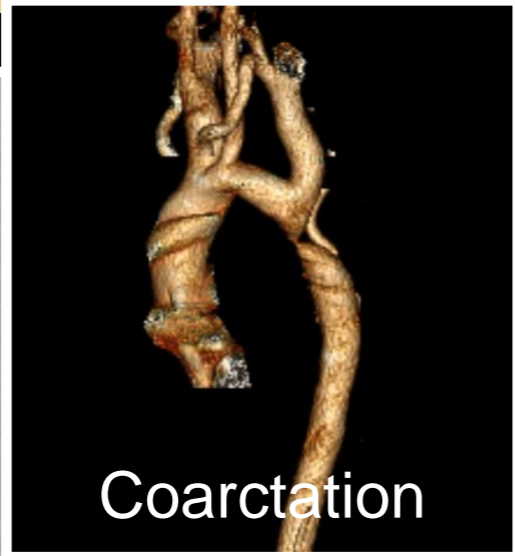


- **Cerebral vasospasm**

- Common (20%) but poorly understood complication of SAH
- Delayed cerebral ischemia is the major cause of morbidity and death in patients who survive the initial hemorrhage



# Cerebral Aneurysms



Fusiform dolichoectatic vertebral-basilar aneurysm

Mycotic pseudoaneurysms