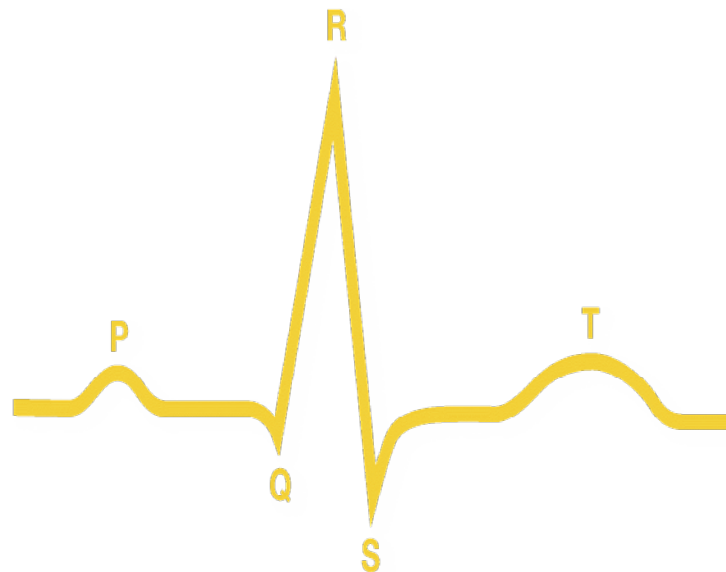
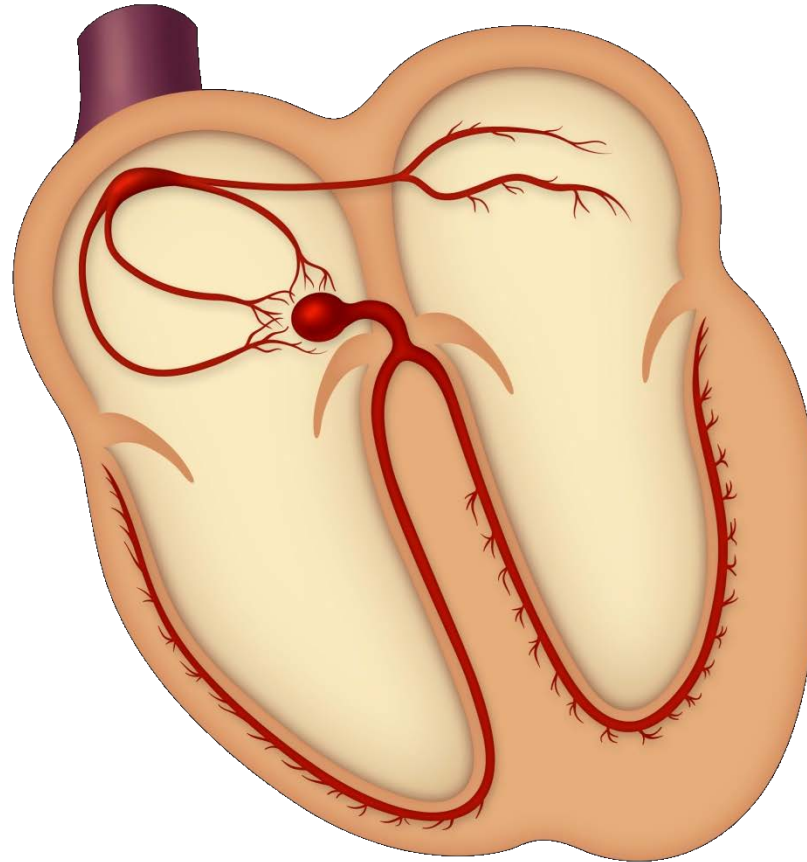


Ηλεκτροκαρδιογράφημα

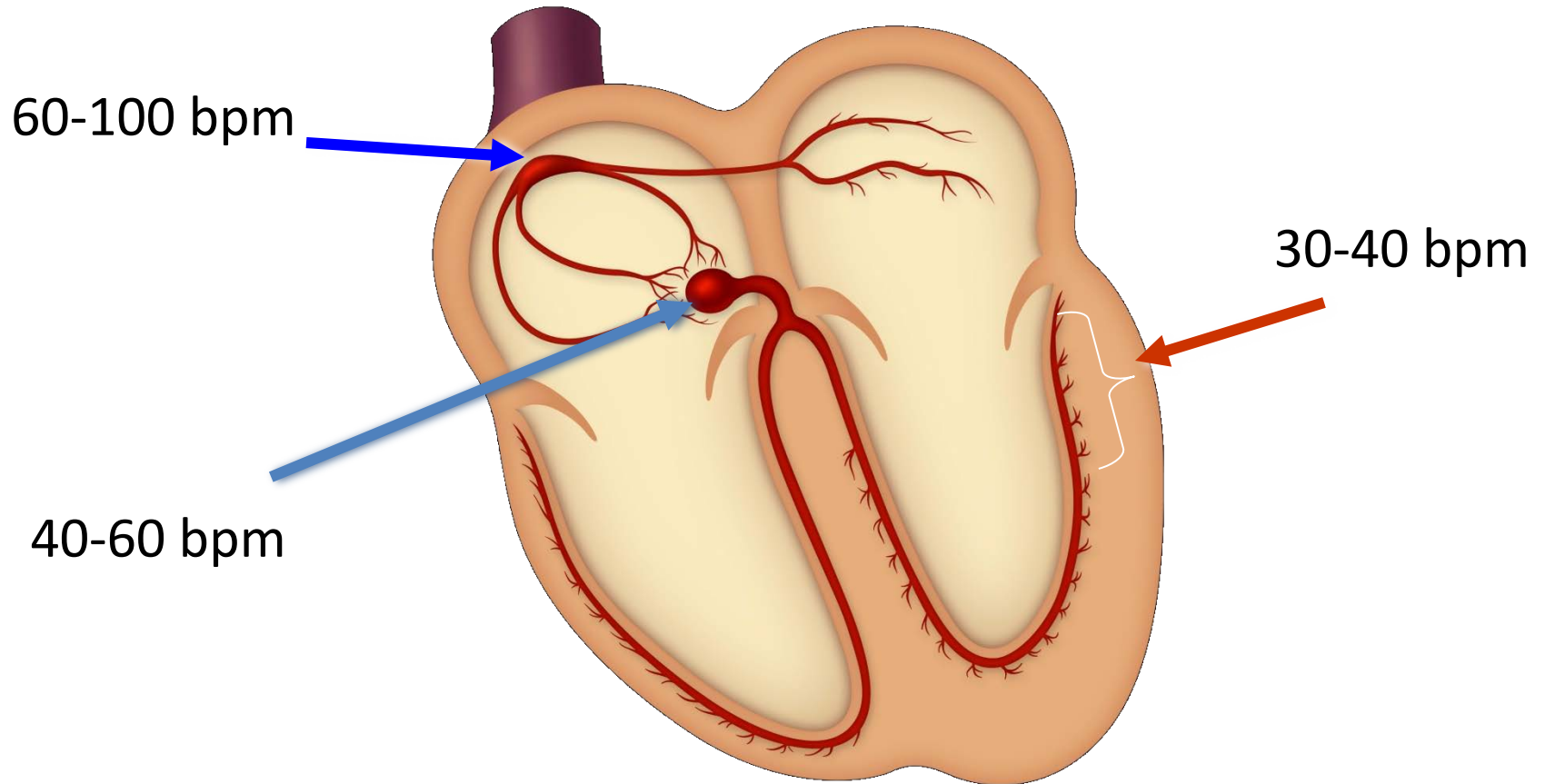
Δημήτρης Φαρμάκης

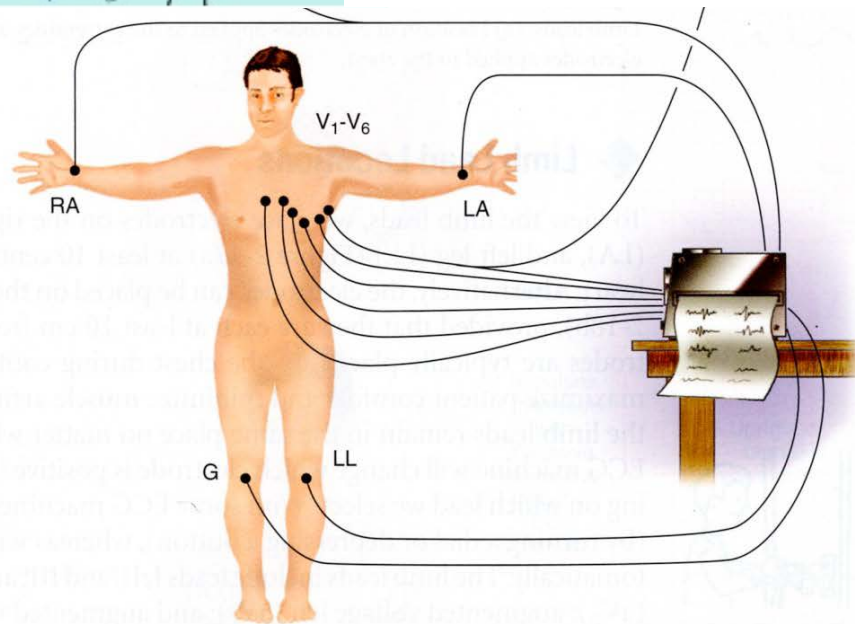
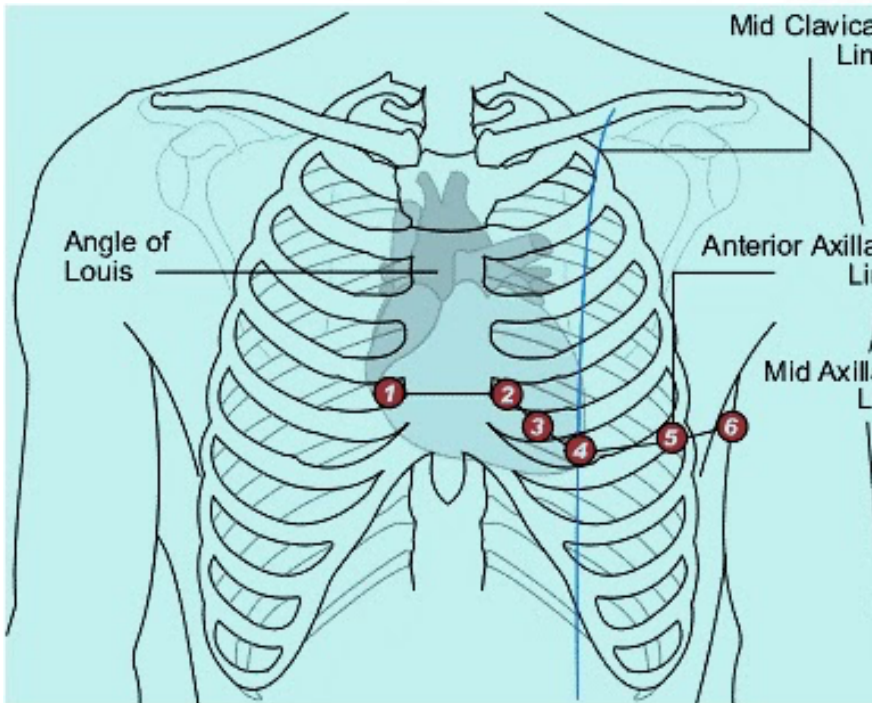


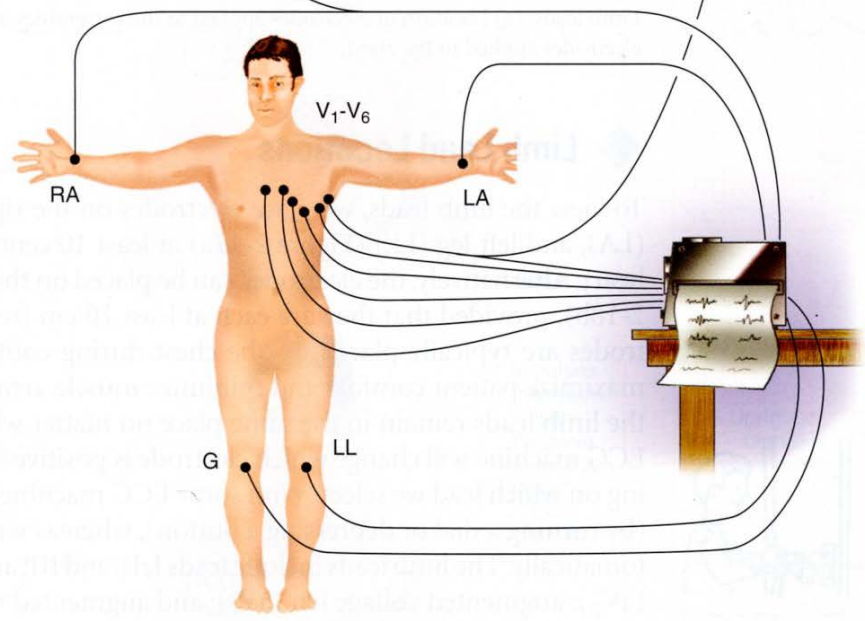
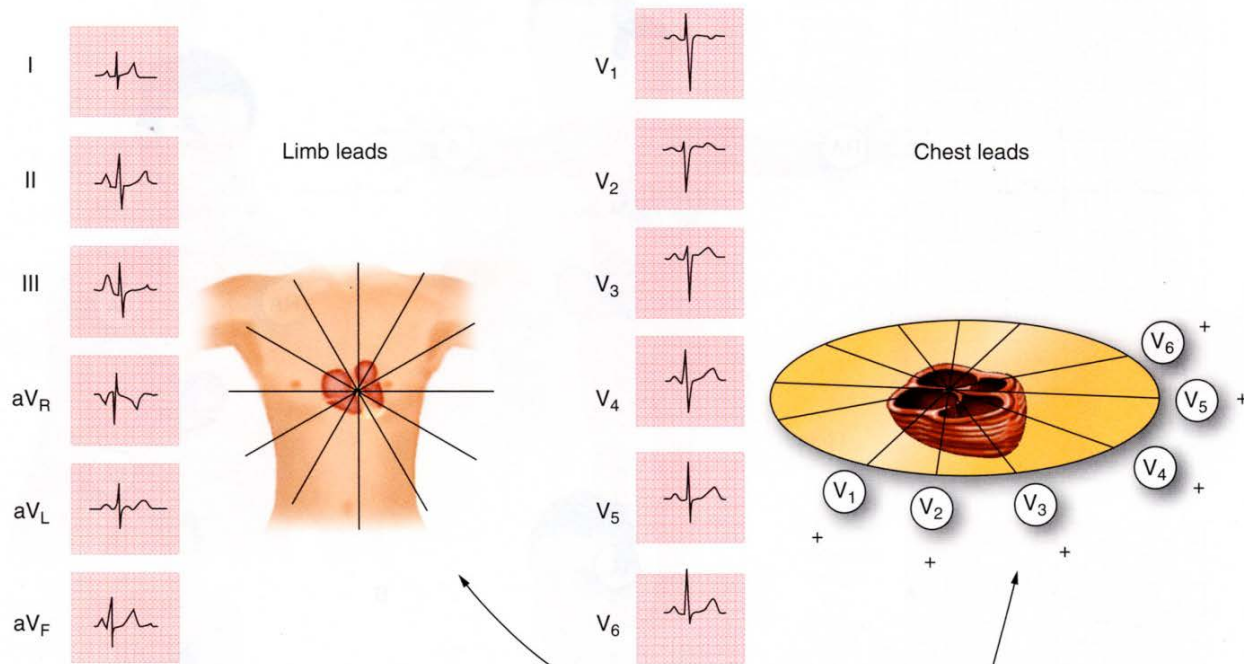
Ερεθισματοαγωγό σύστημα καρδιάς

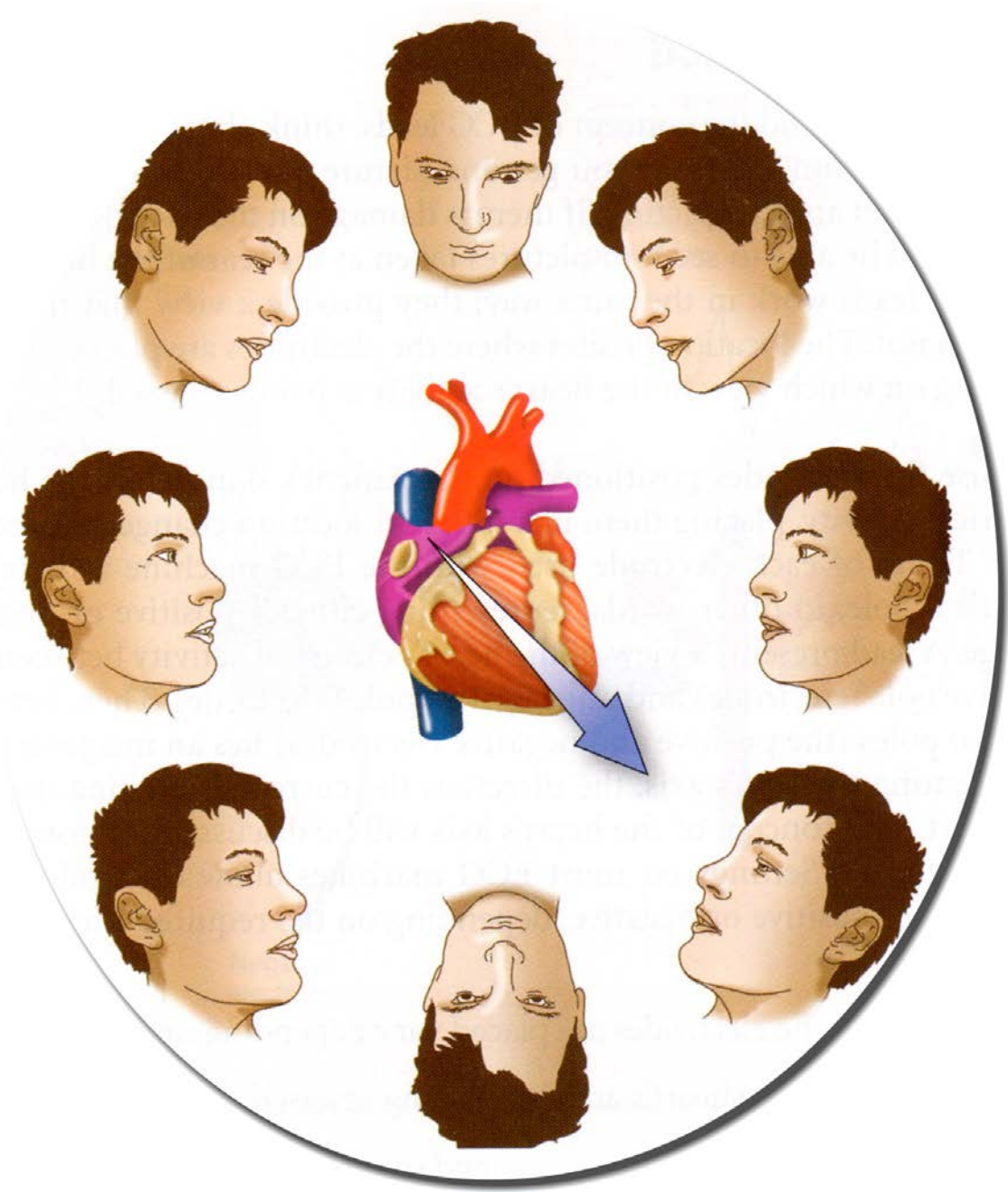


Βηματοδότες καρδιάς

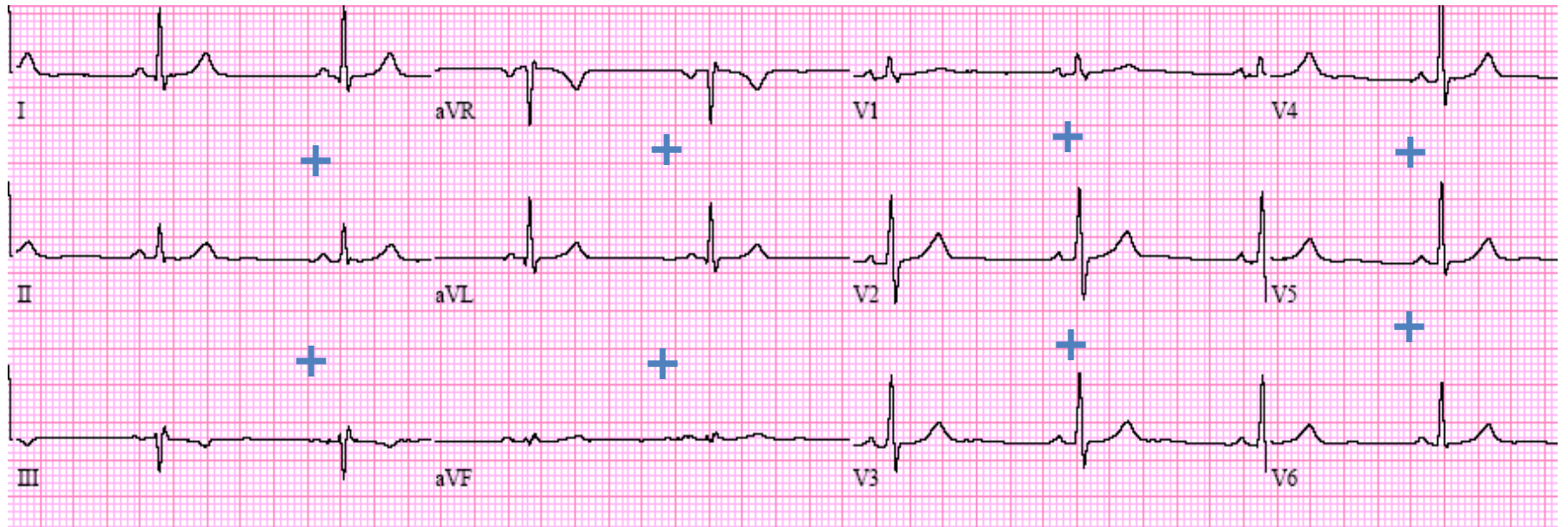




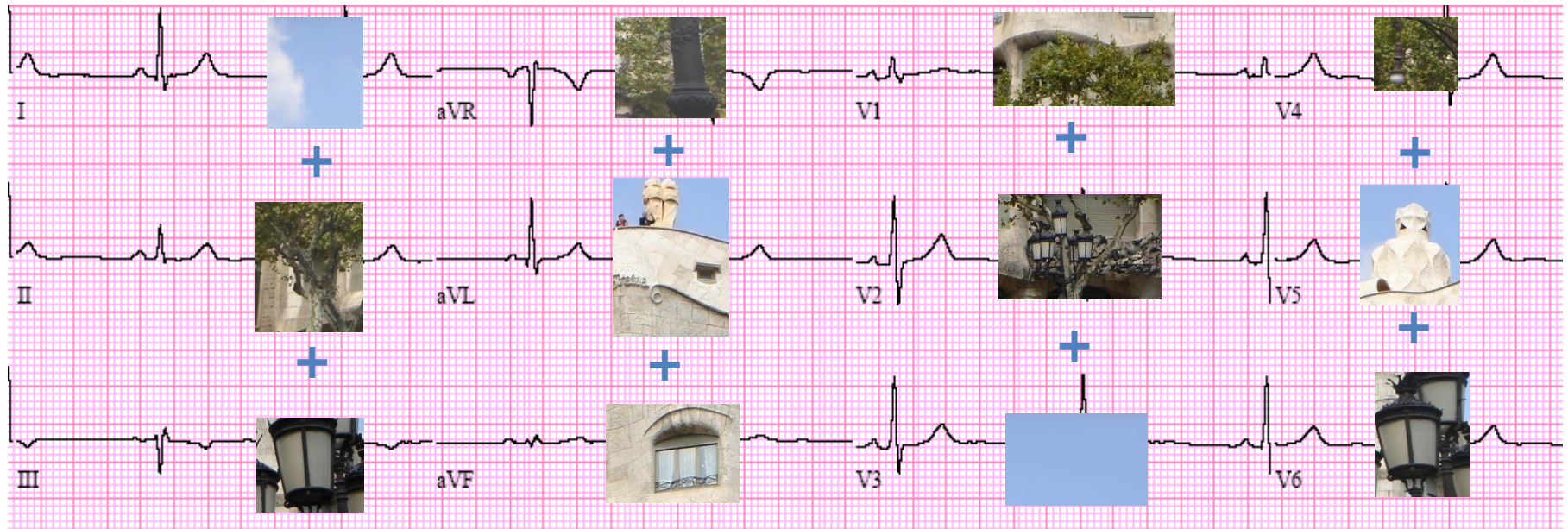




Ηλεκτροκαρδιογράφημα 12 απαγωγών



Ηλεκτροκαρδιογράφημα 12 απαγωγών

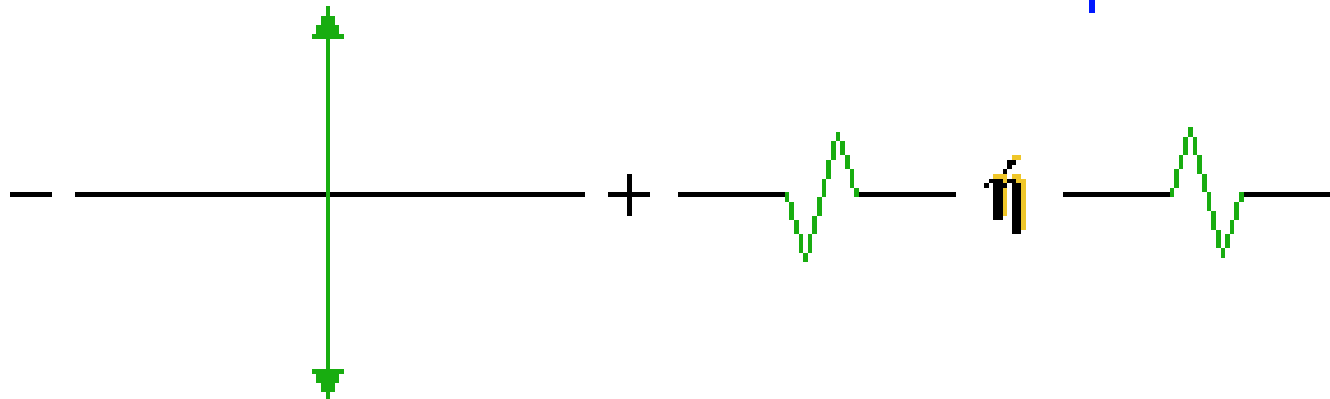

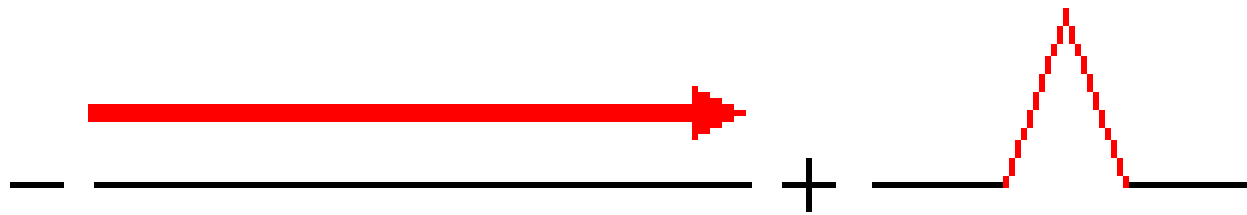


=

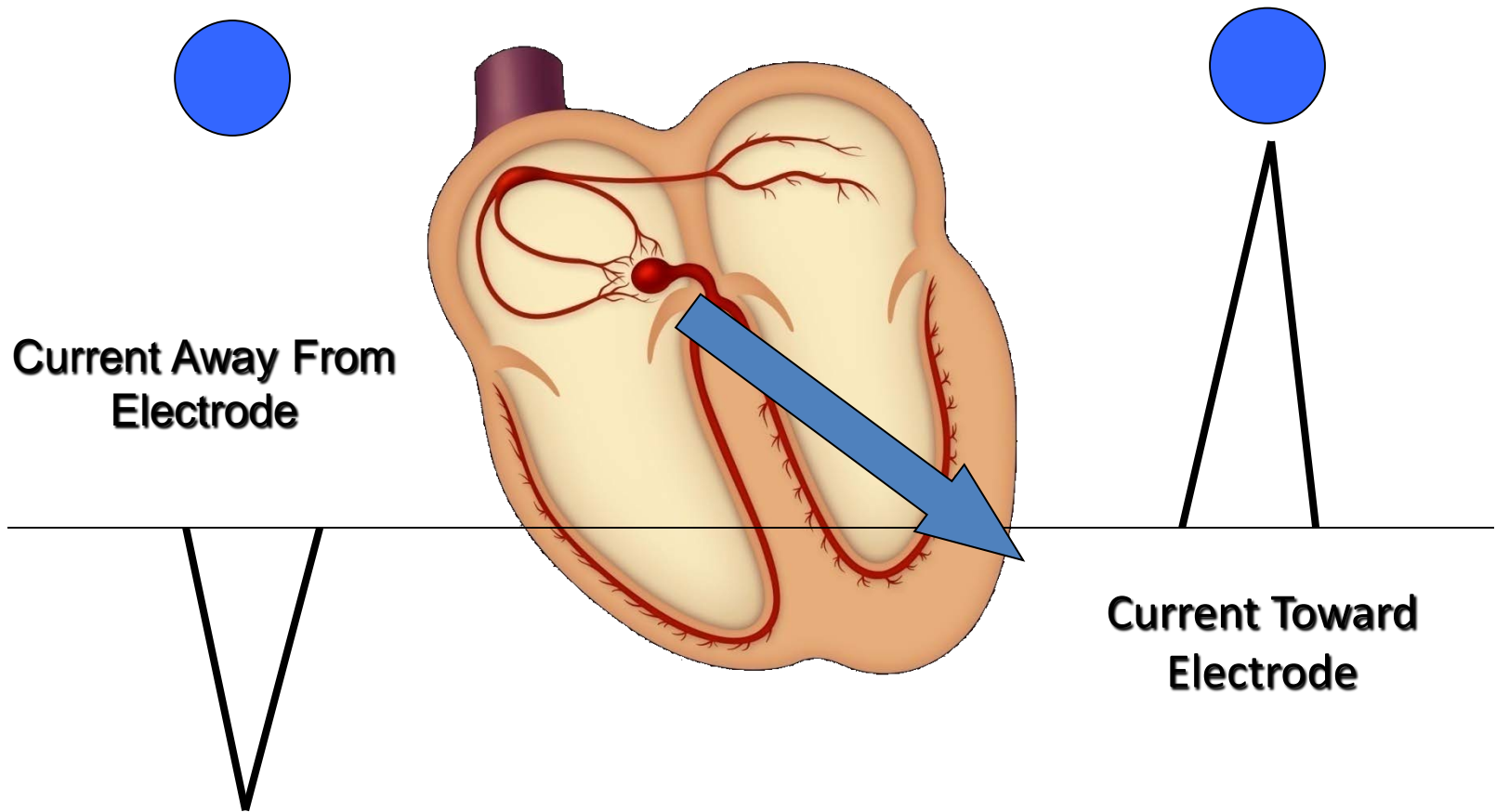


L'ESPLENDOR
DE LA RUINA

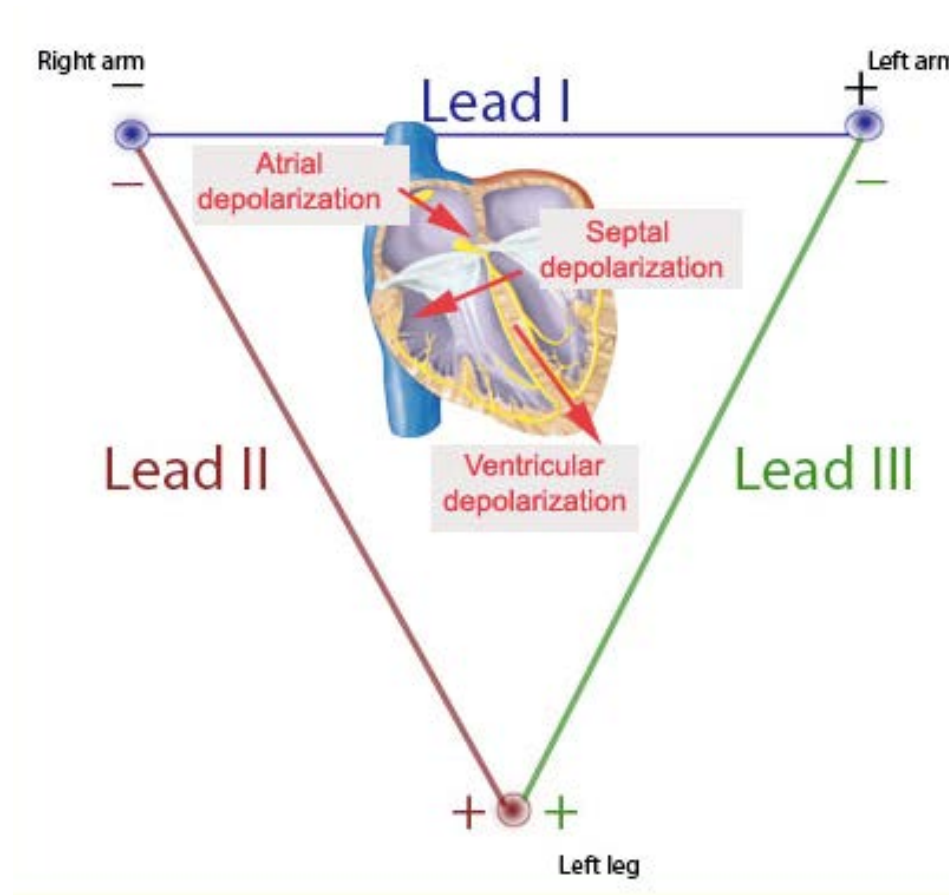
Θετικά & αρνητικά επάρματα



Θετικά & αρνητικά επάρματα

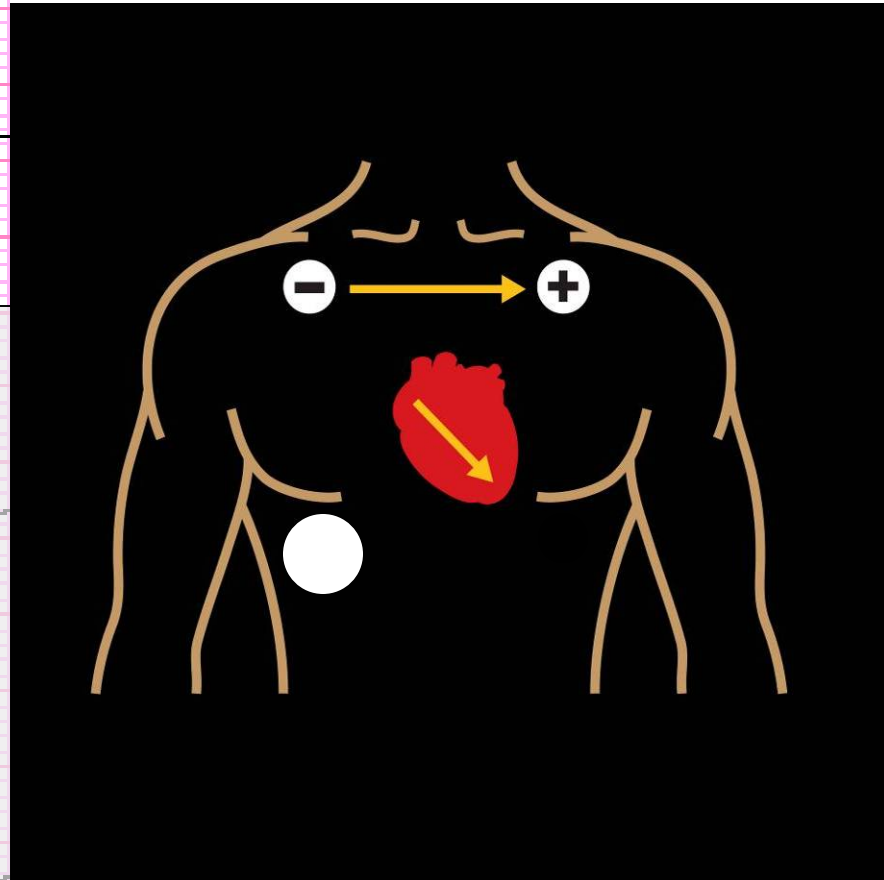
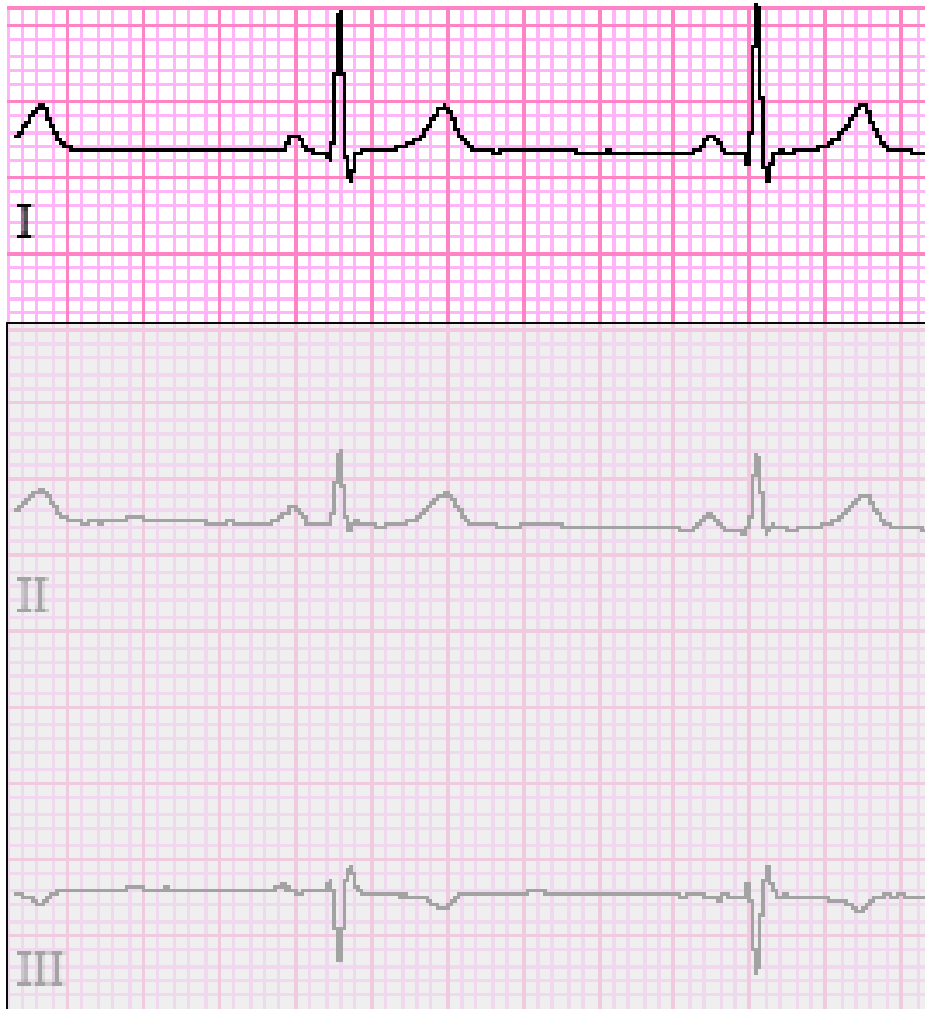


Τρίγωνο Einthoven



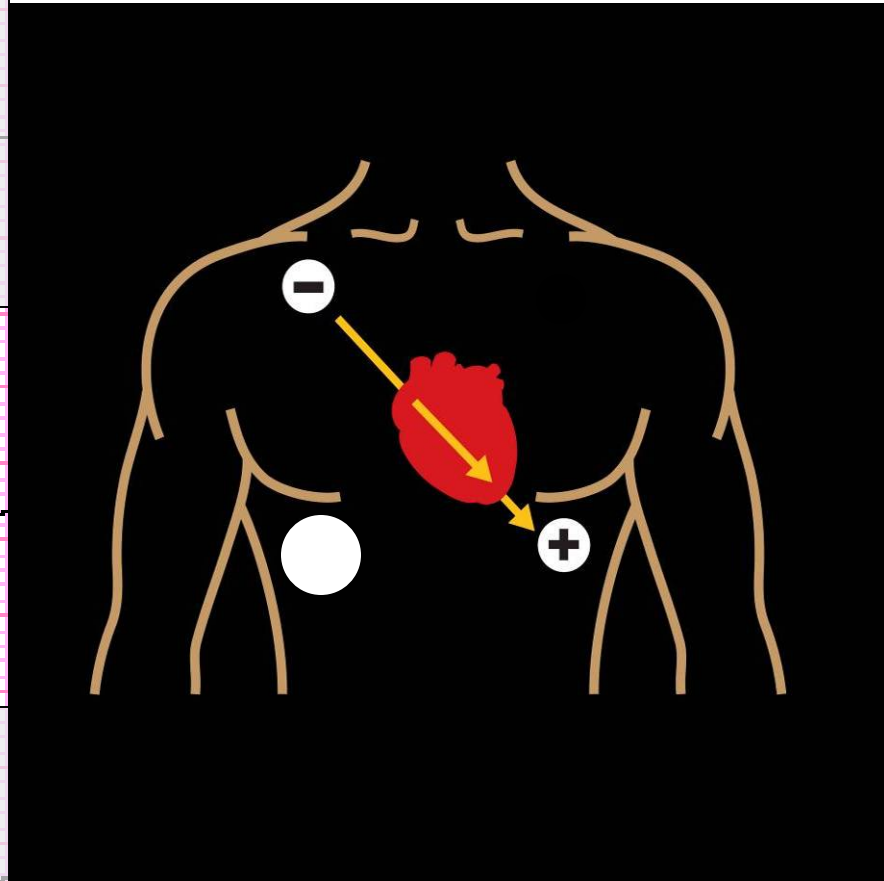
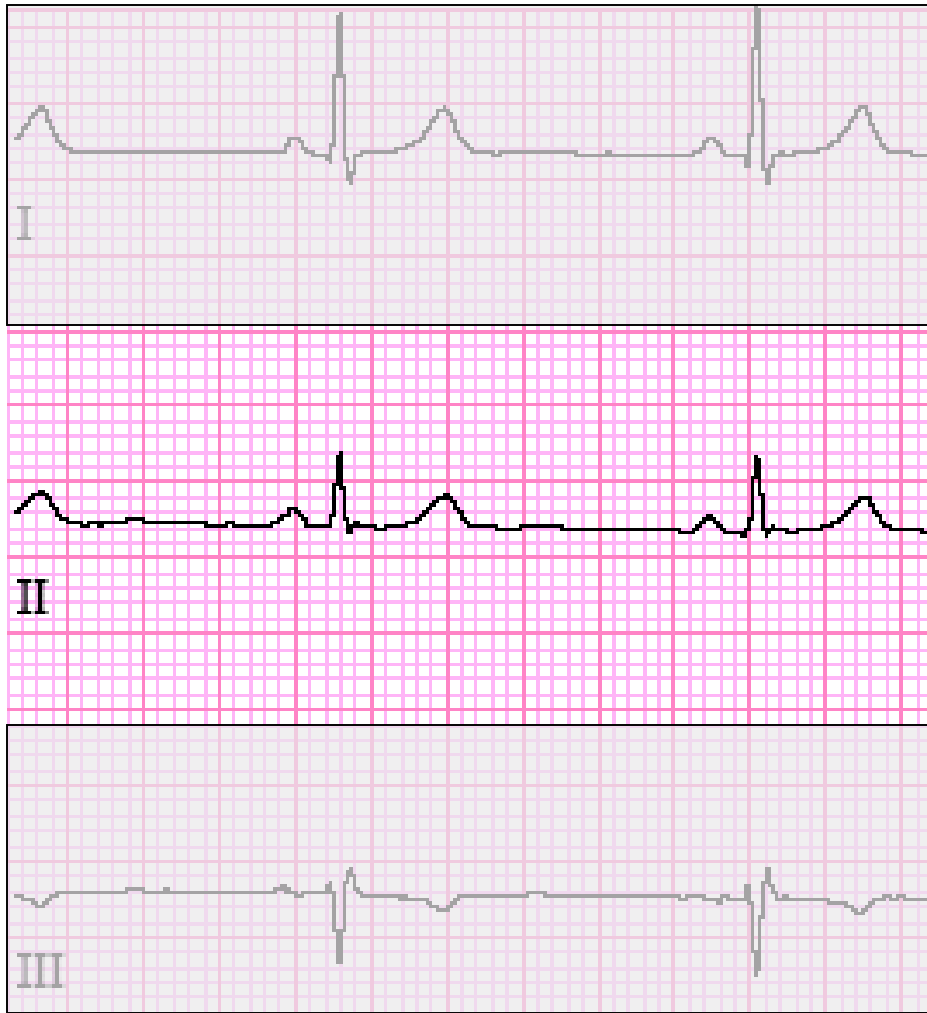
Κλασικές απαγωγές των άκρων

Απαγωγή 1



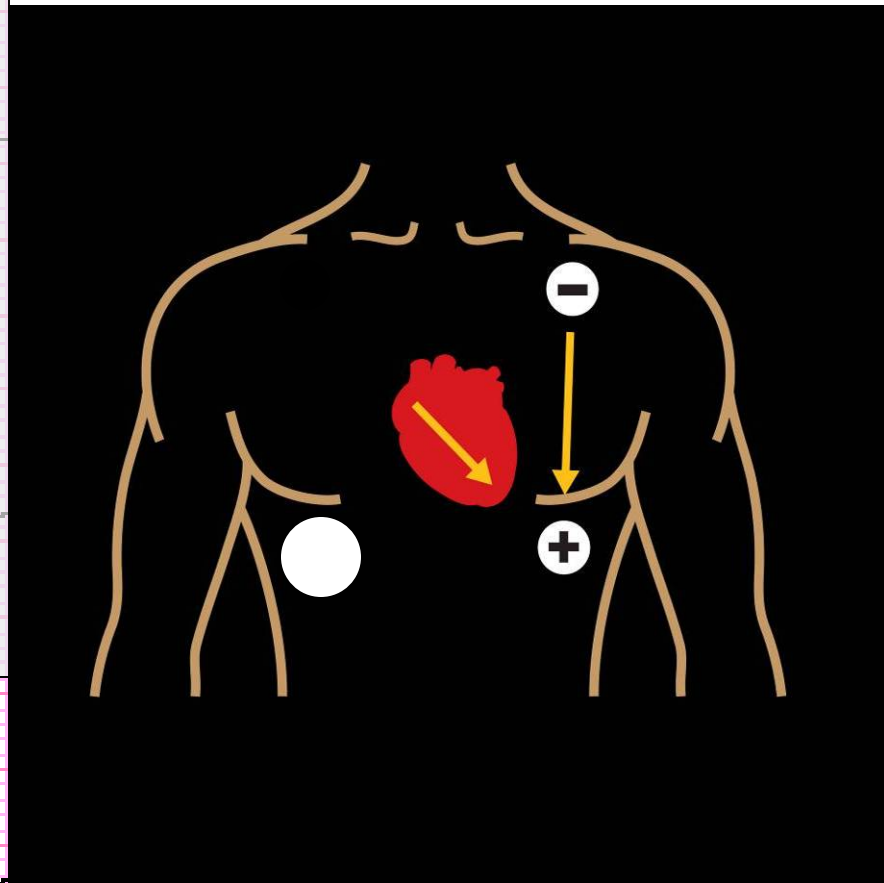
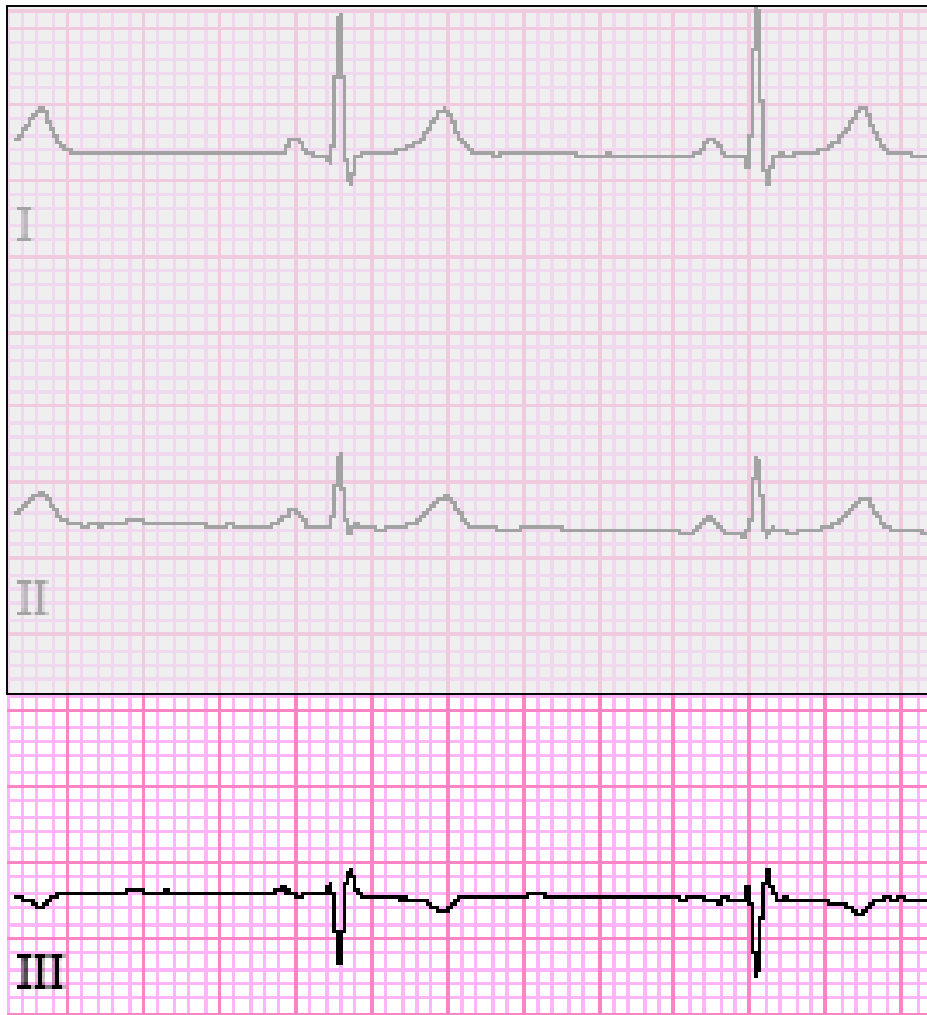
Κλασικές απαγωγές των άκρων

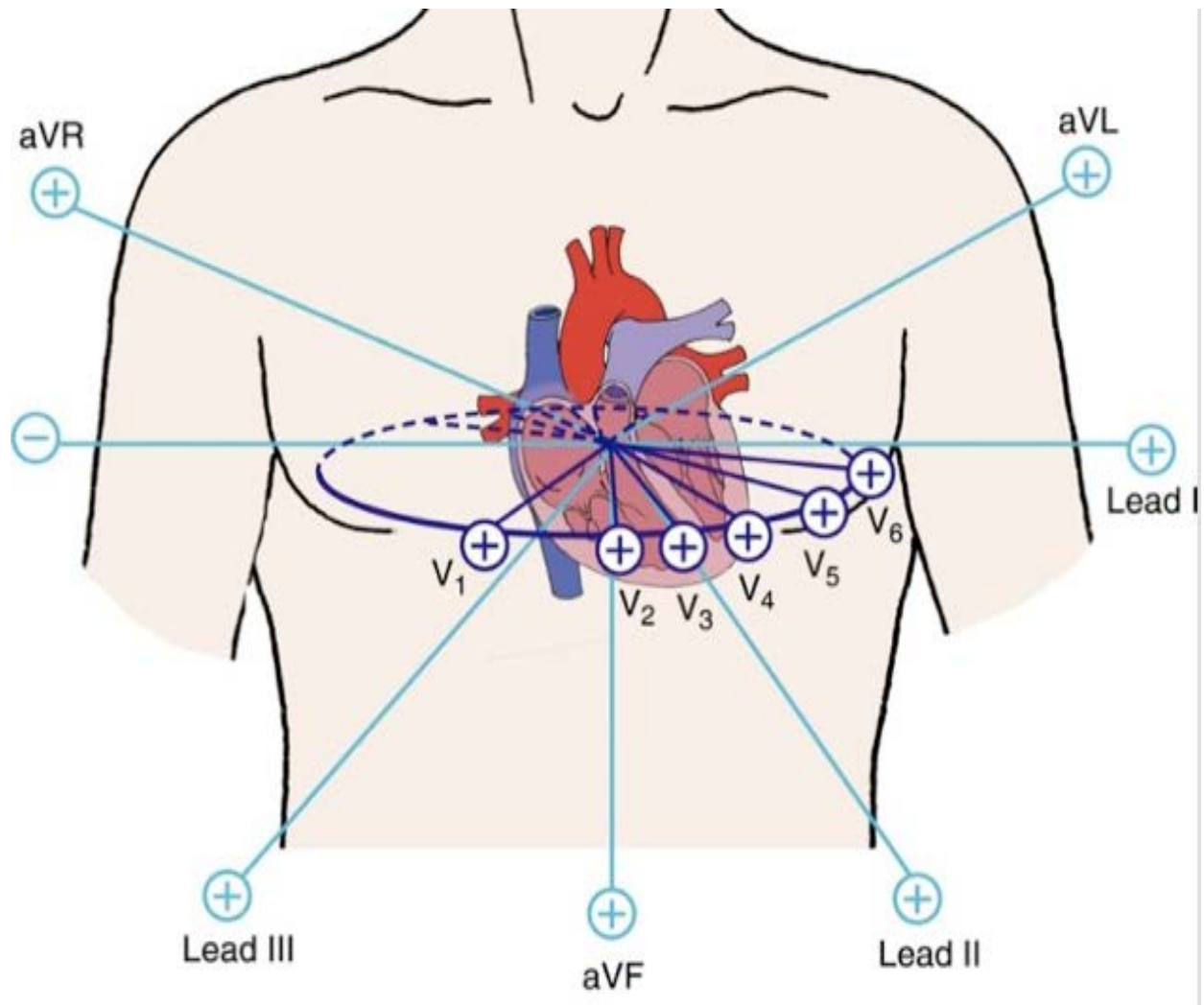
Απαγωγή 2

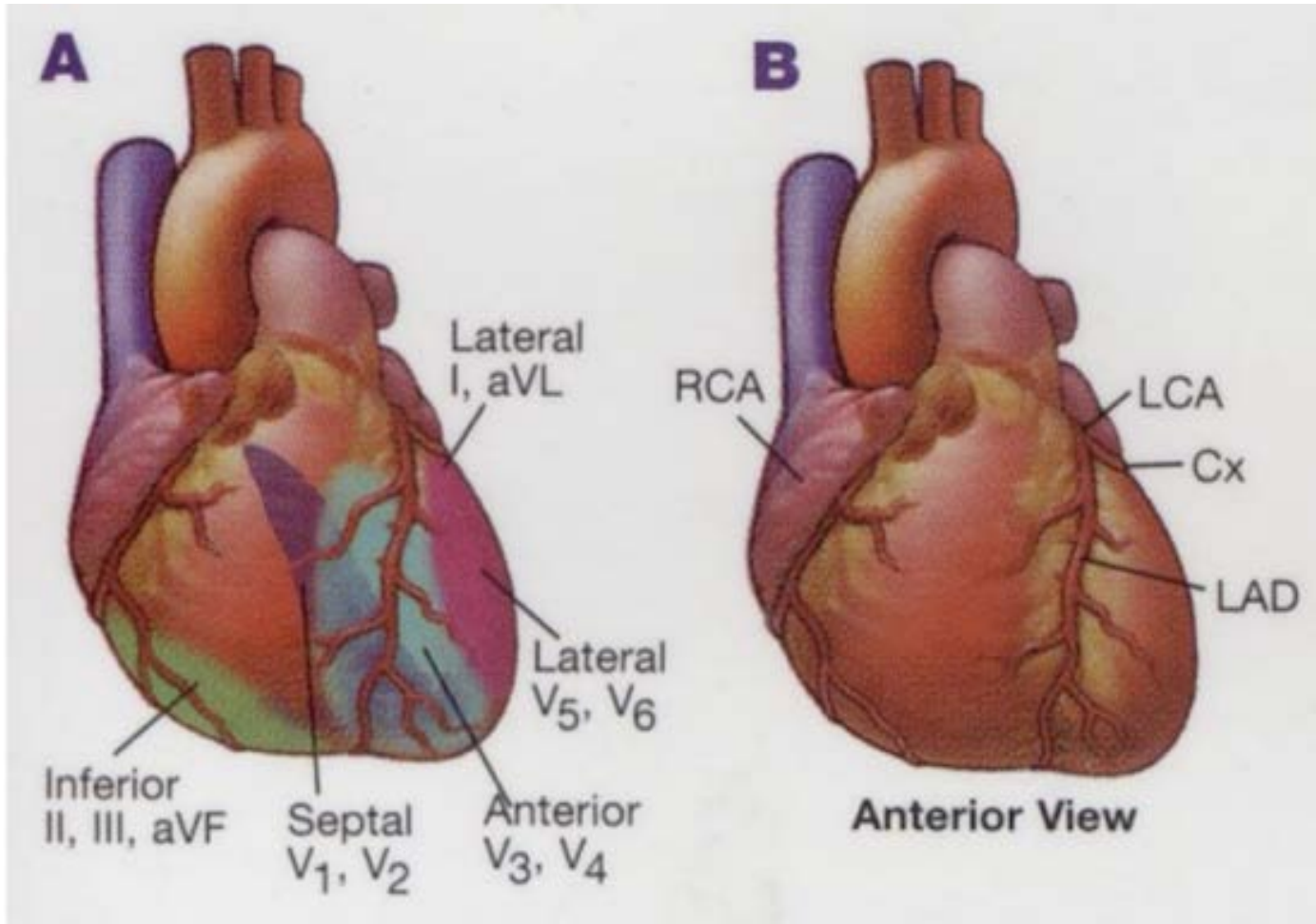


Κλασικές απαγωγές των άκρων

Απαγωγή 3







A

B

Lateral
I, aVL

RCA

LCA

Cx

Lateral
V5, V6

LAD

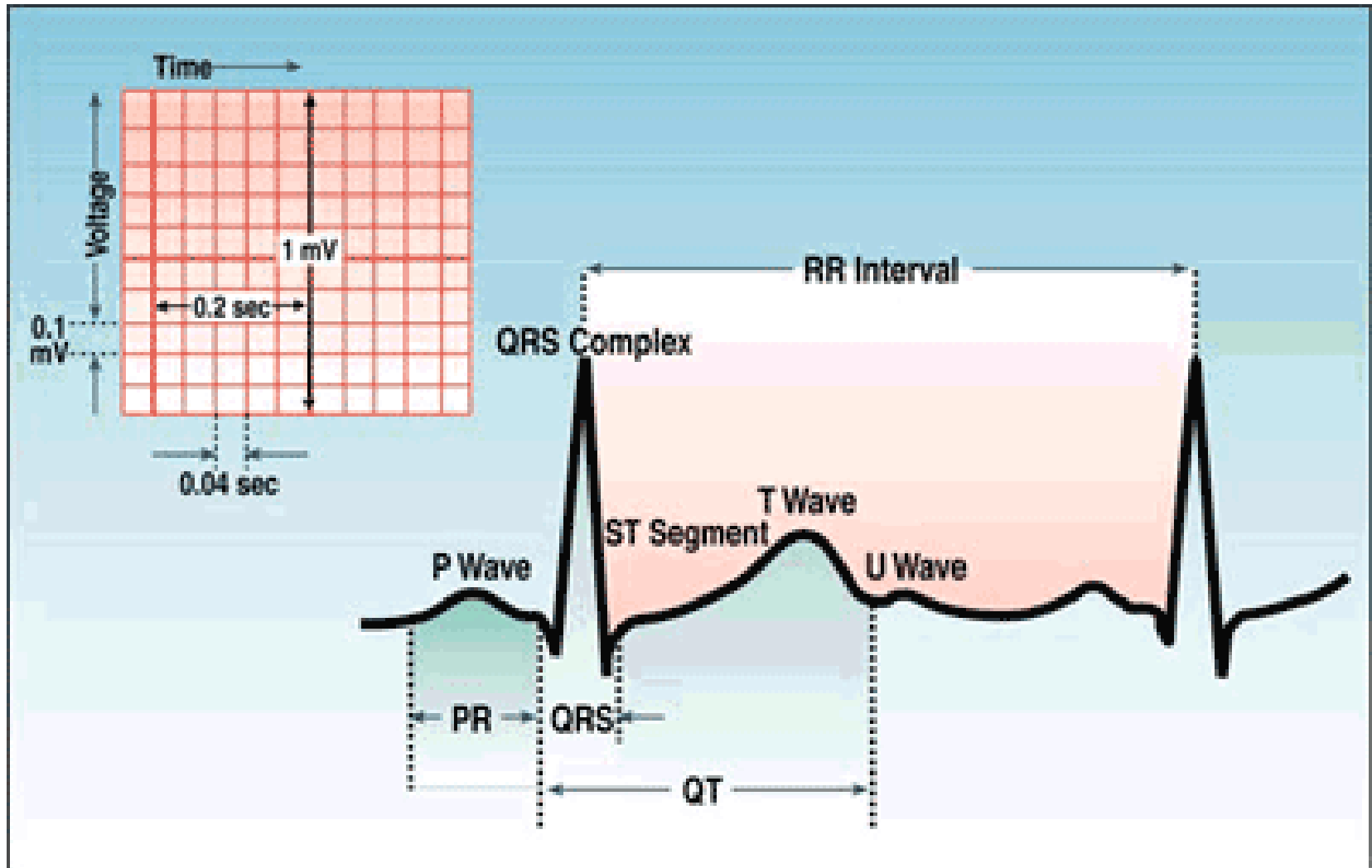
Inferior
II, III, aVF

Septal
V1, V2

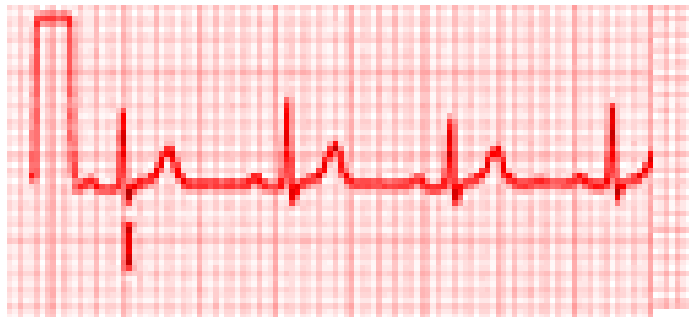
Anterior
V3, V4

Anterior View

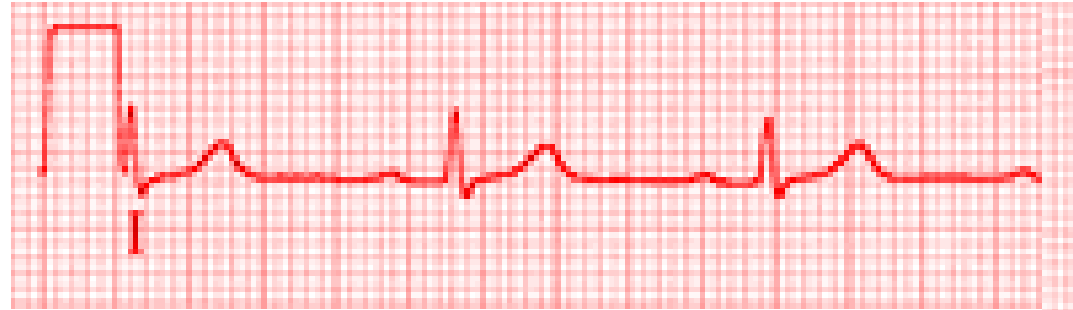
Βαθμονόμηση



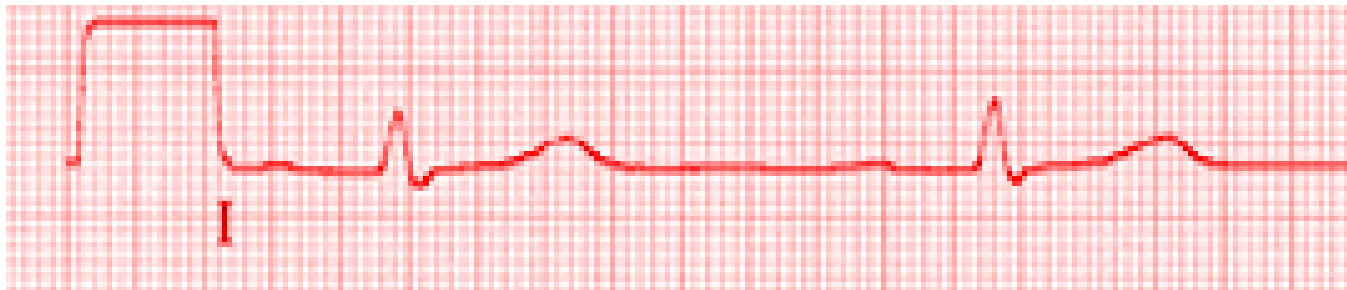
Ταχύτητα



Ταχύτητα = 25 mm/sec

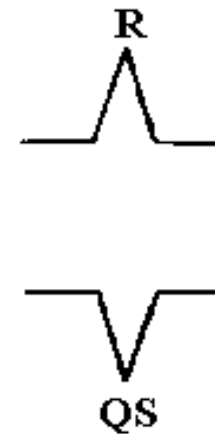
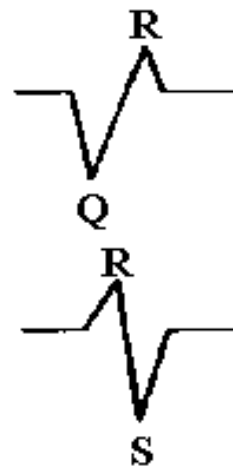
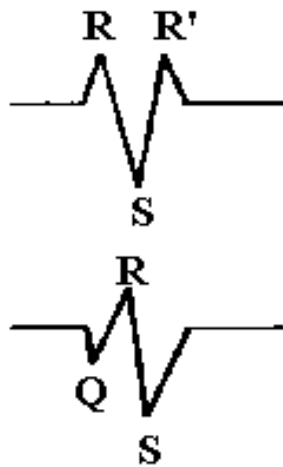
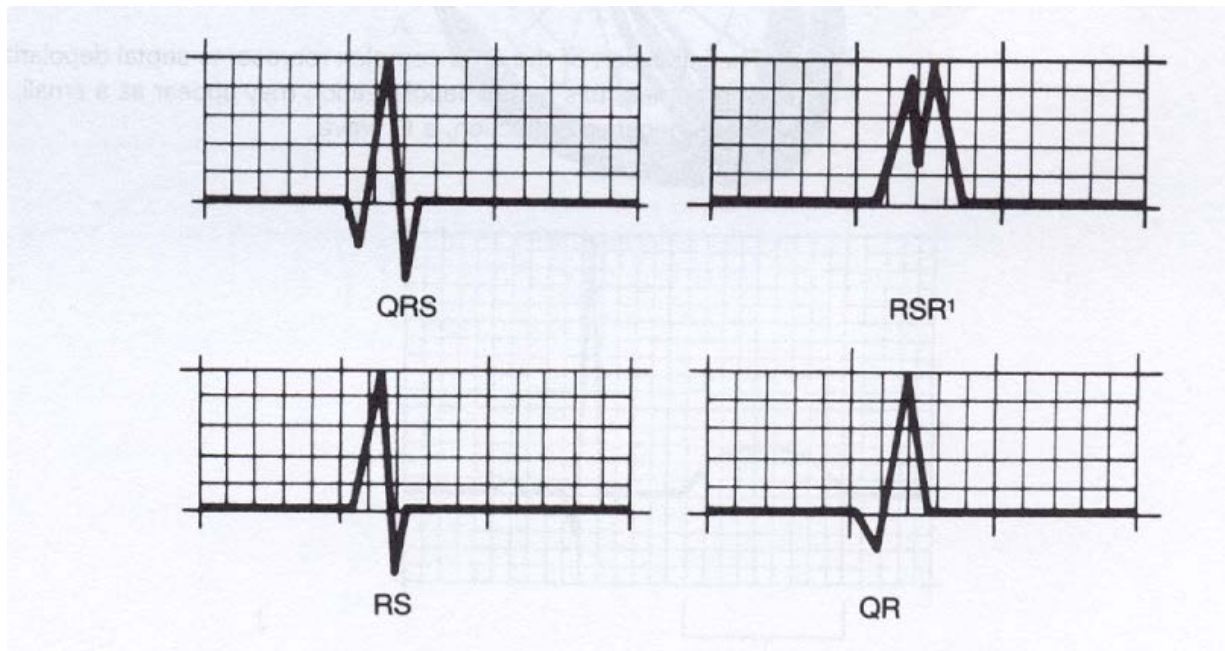


Ταχύτητα = 50 mm/sec
Ευαισθησία 1mV = 10 mm

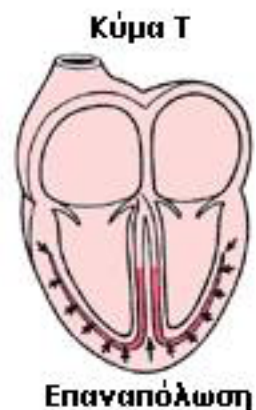
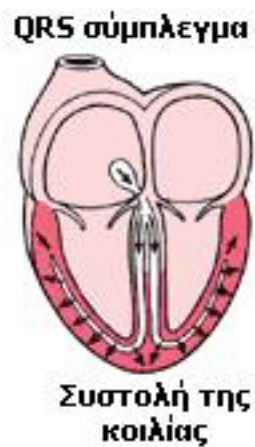
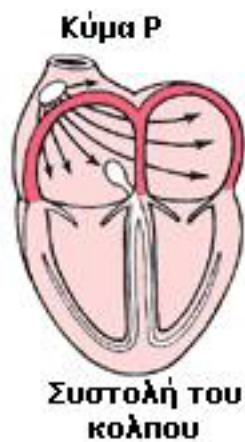
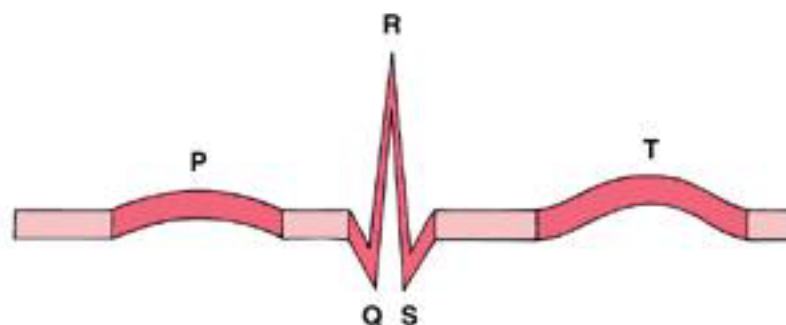


Ταχύτητα = 100 mm/sec

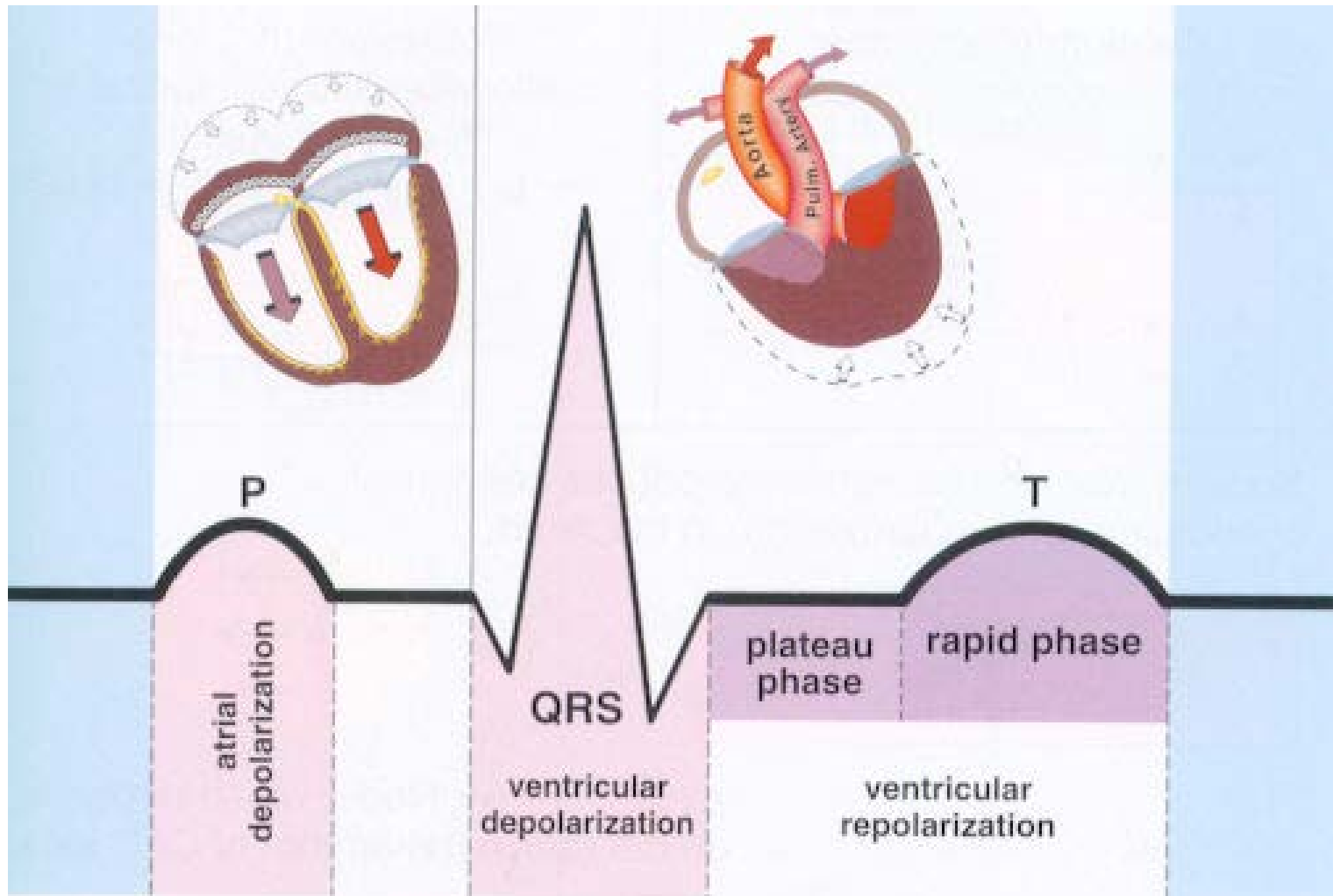
Ονοματολογία επαρμάτων



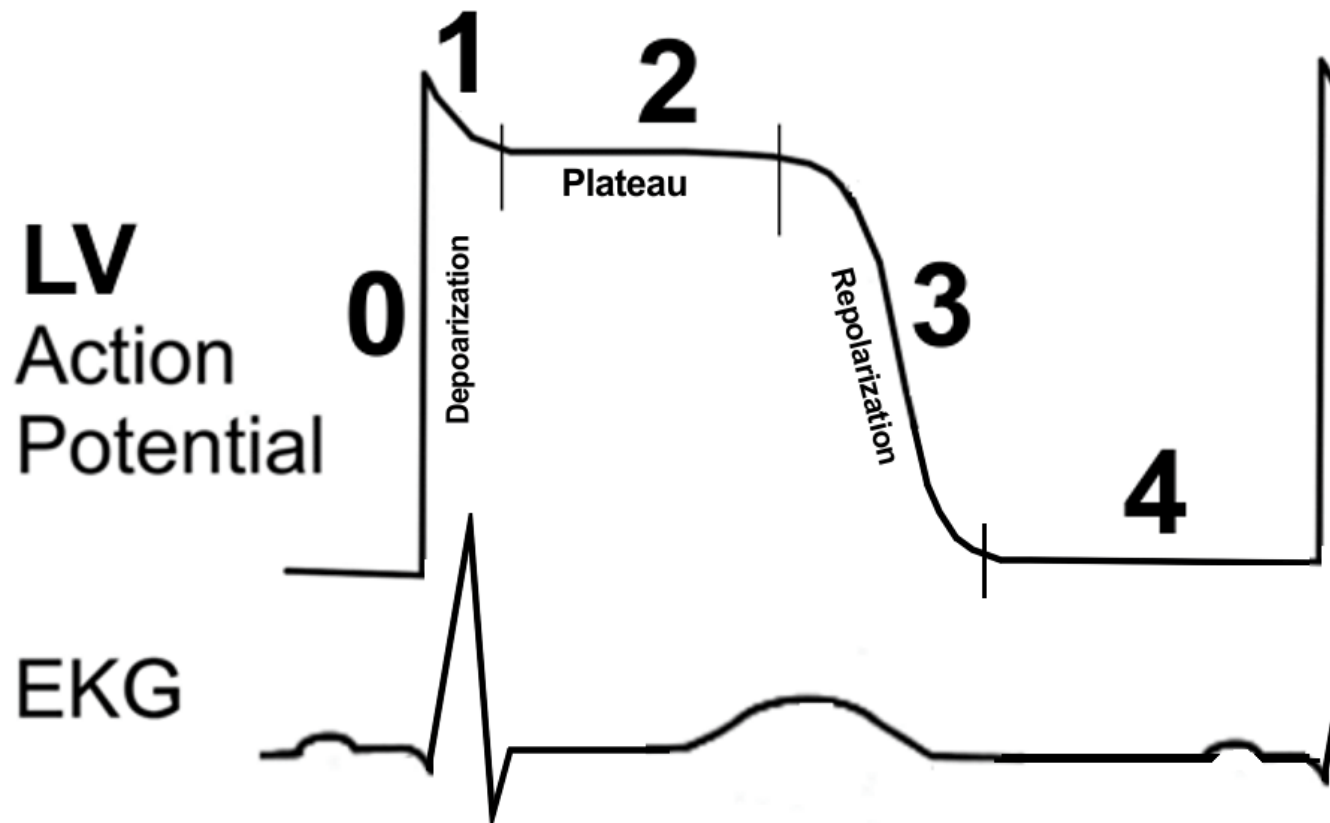
Επάρματα και συμπλέγματα



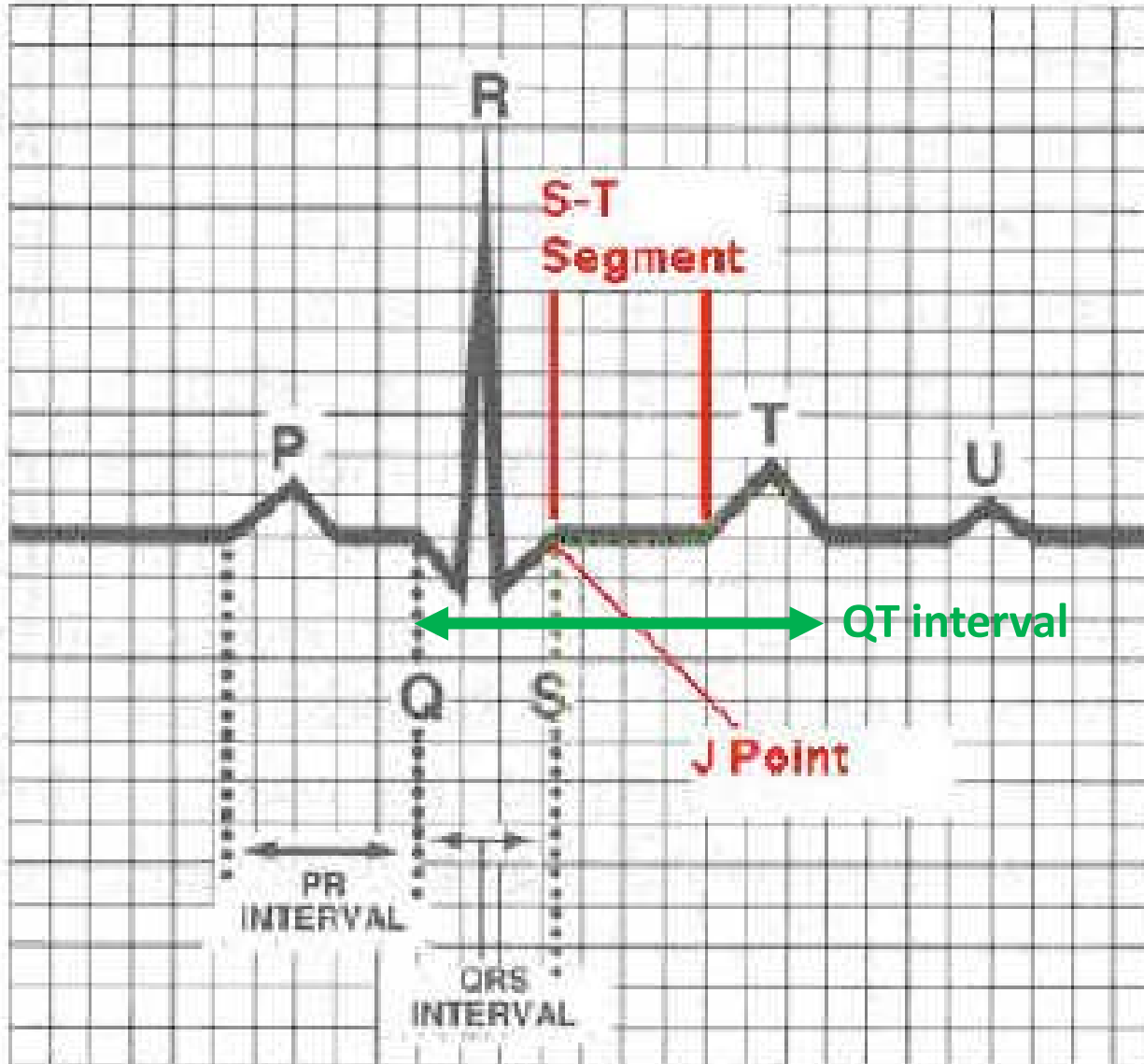
Επάρματα και συμπλέγματα



Δυναμικό ενέργειας και ΗΚΓ

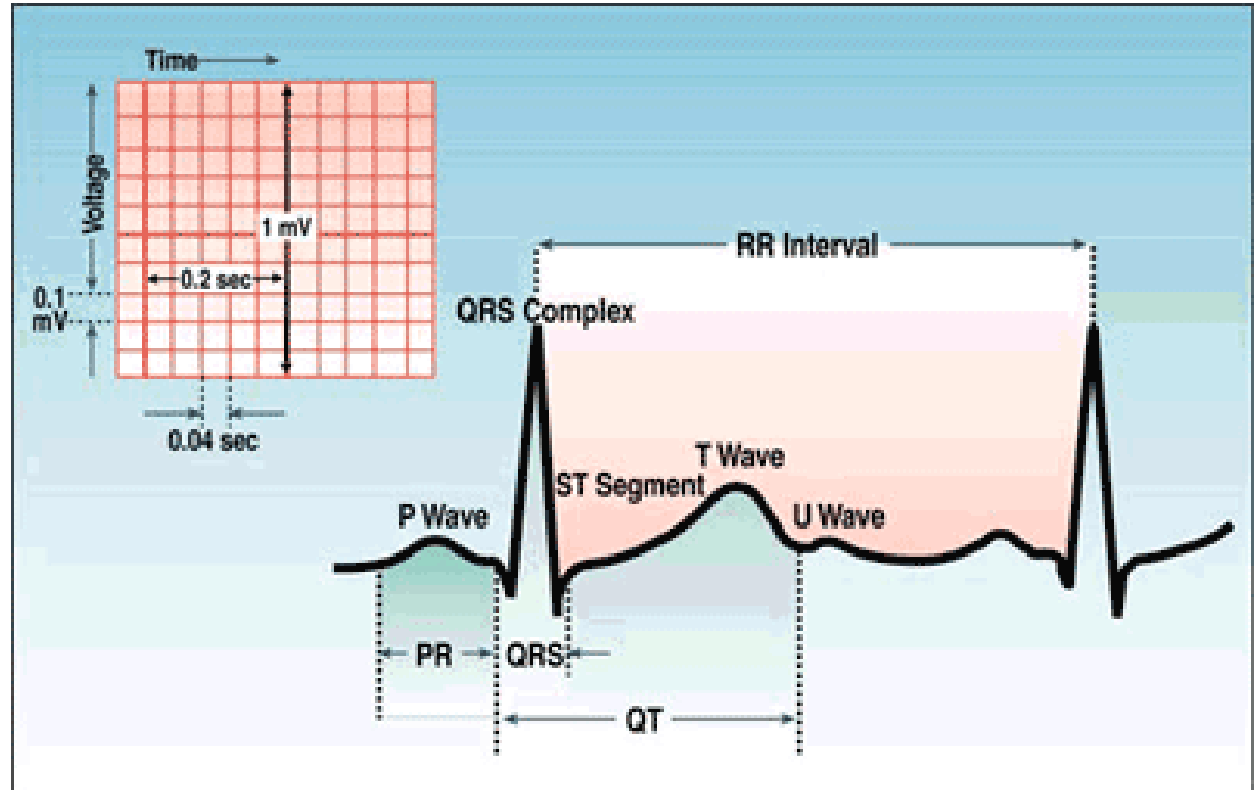


Διαστήματα και τμήματα

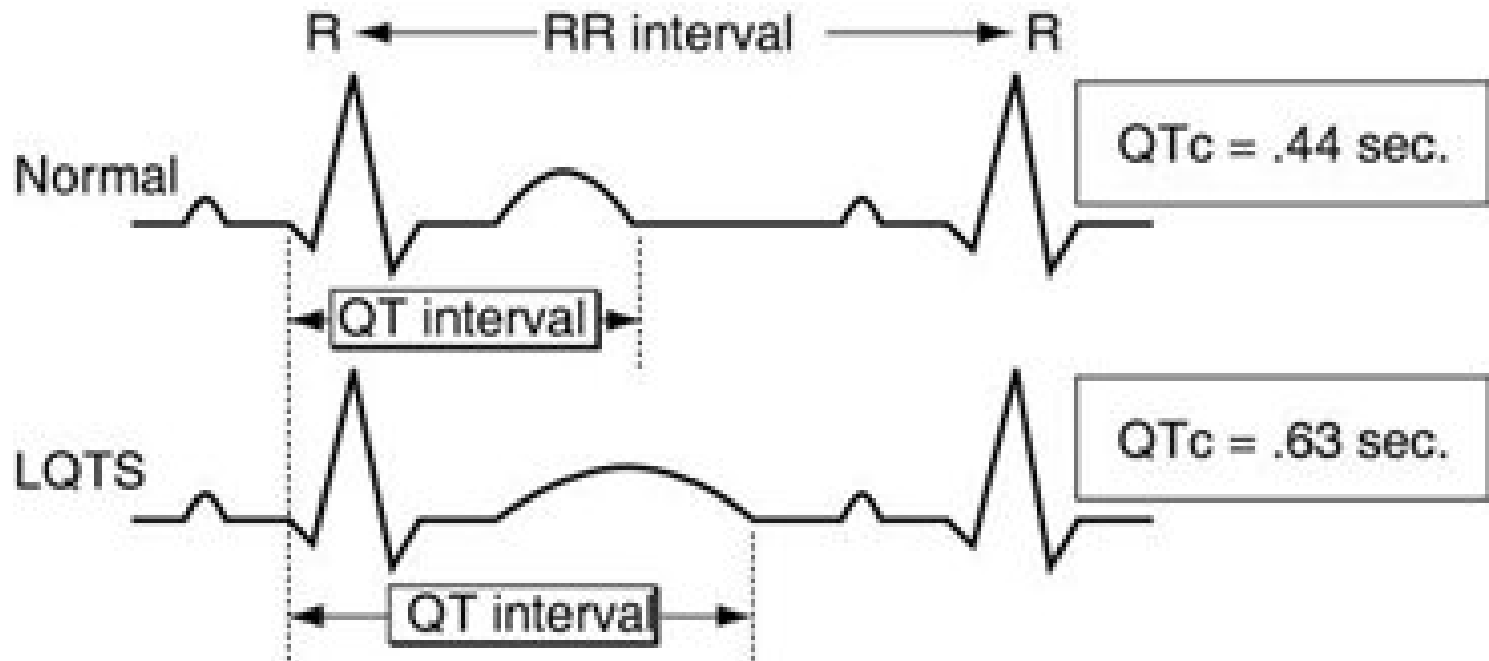


Διαστήματα και τμήματα

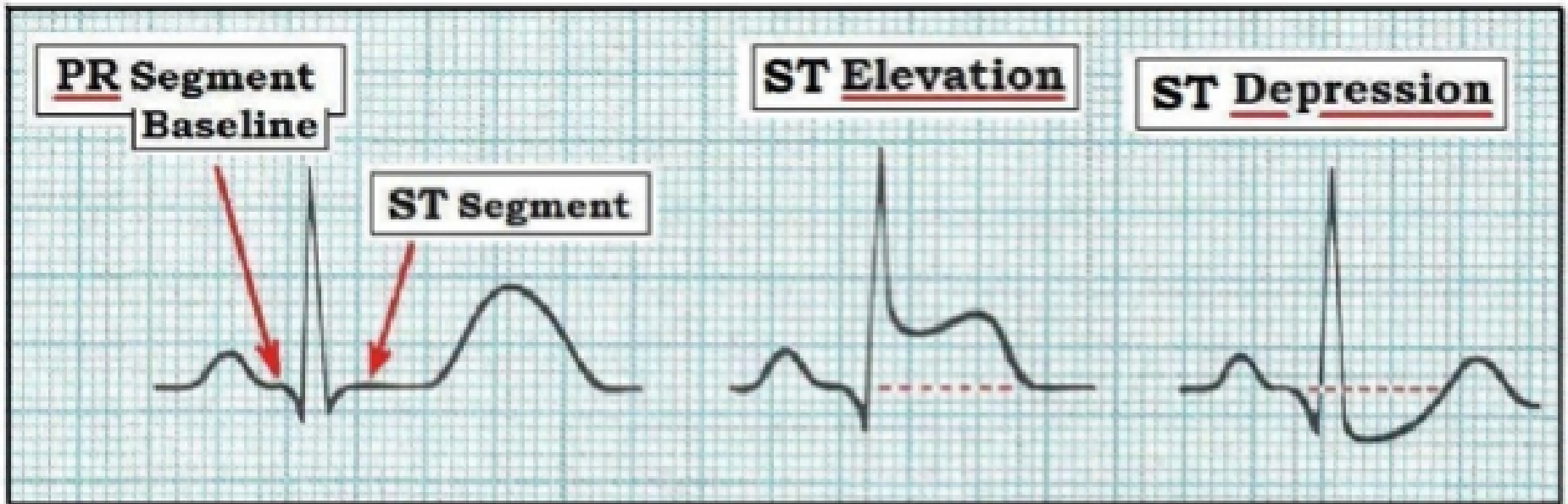
- PR διάστημα
<0.20 s
- QRS σύμπλεγμα
<0.12 s
- QT δι'
<0.45 s



Μέτρηση και διόρθωση QT διαστήματος



Ανάσπαση και κατάσπαση τμημάτων



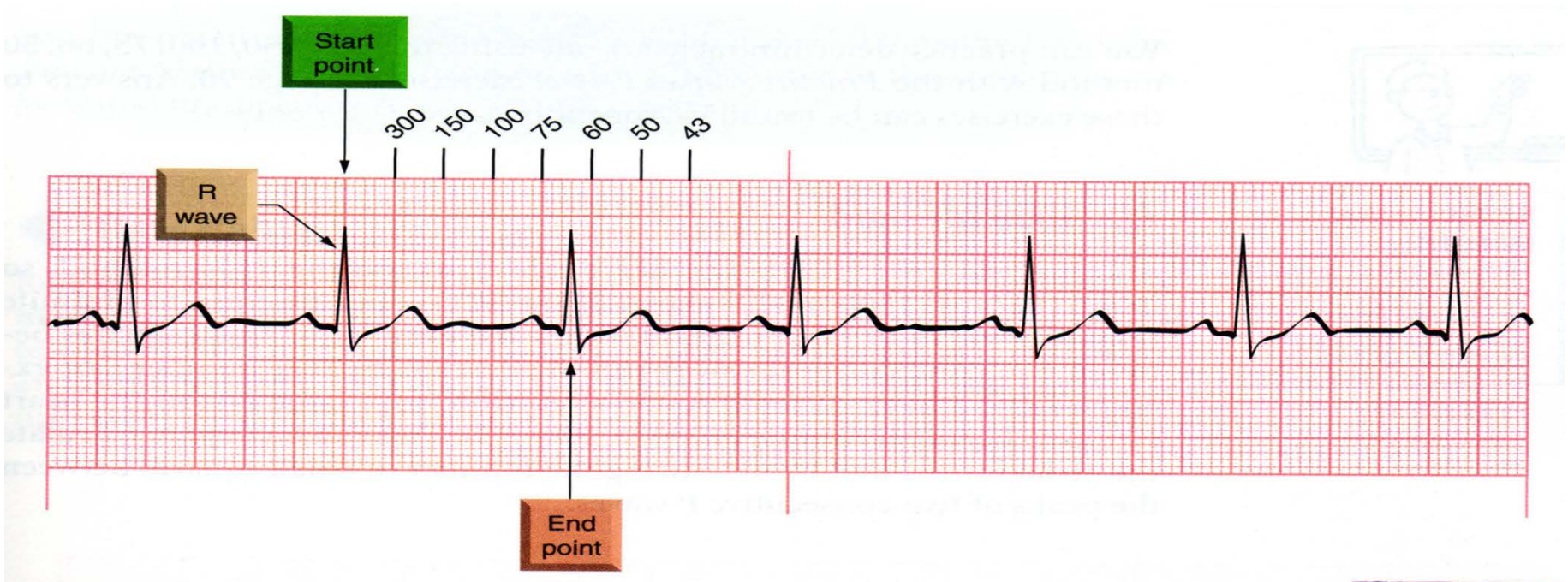
Μελέτη ΗΚΓ

Μελέτη ΗΚΓ

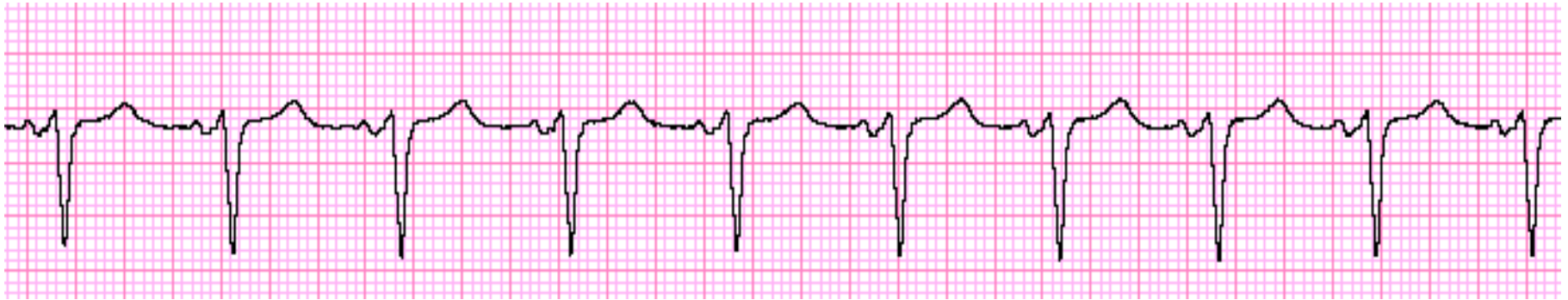
- Συχνότητα
- Ρυθμός
- Άξονας QRS
- Μορφολογικές αλλοιώσεις επαρμάτων ή διαστημάτων
- Διαταραχές ρυθμού

Συχνότητα

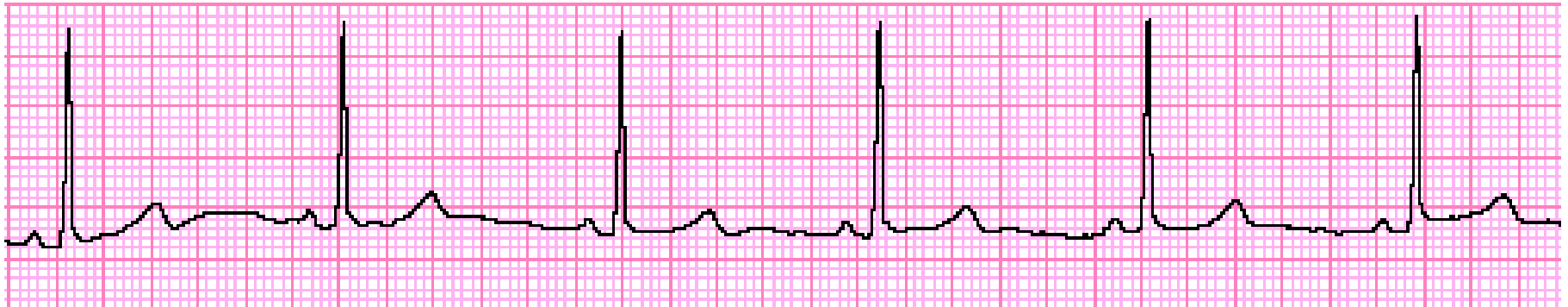
- $1500 / \#$ μικρά τετράγωνα μεταξύ RR



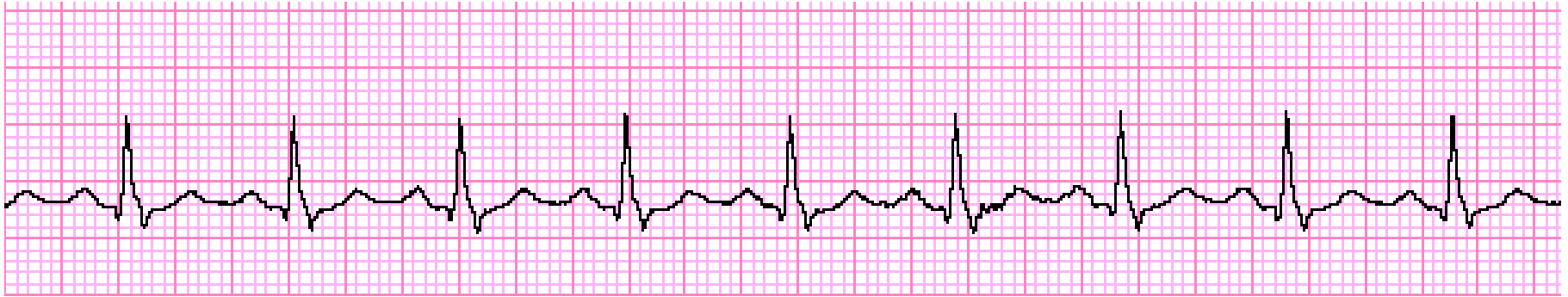
Συχνότητα?



Συχνότητα?

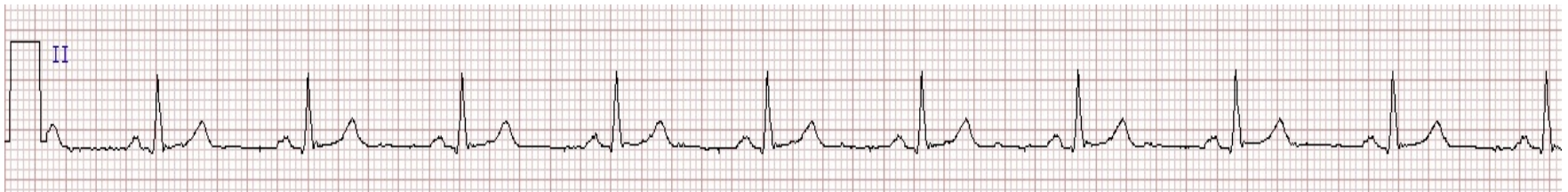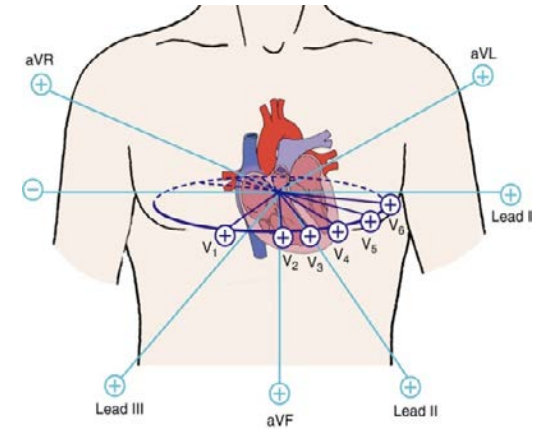


Συχνότητα?

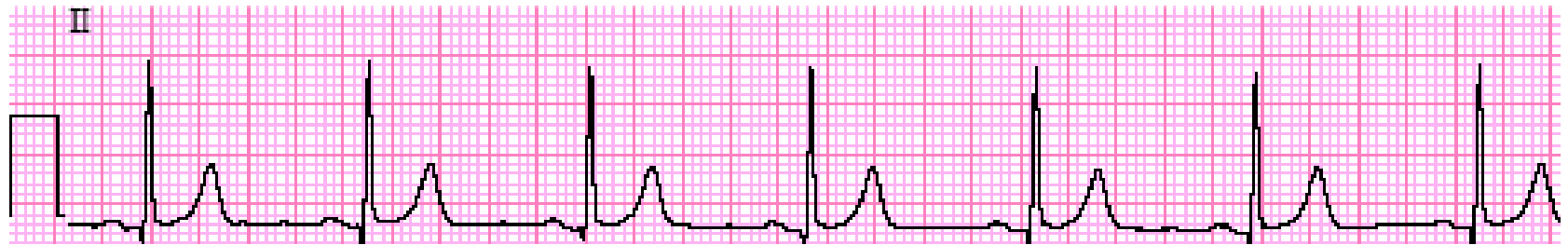


Ρυθμός

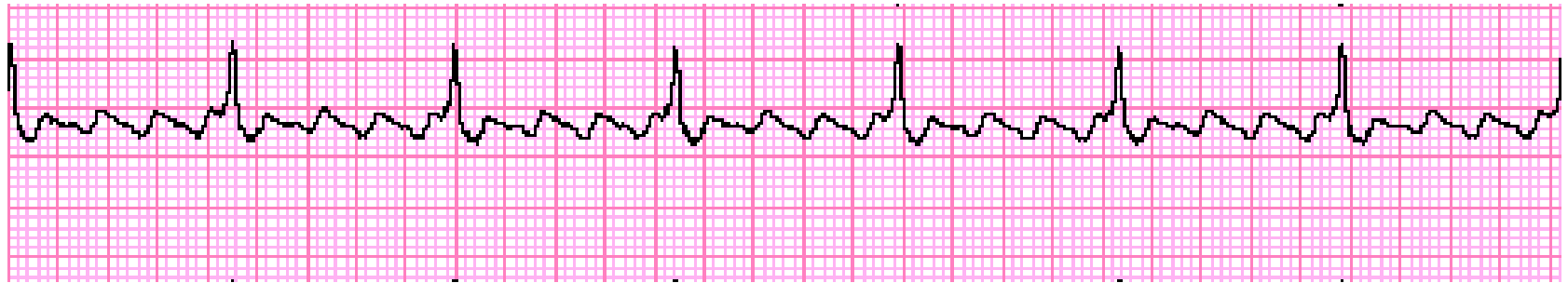
- Φλεβοκομβικός
 - P θετικό στην I, αρνητικό στην aVR
 - Κάθε P ακολουθούμενο από QRS
- Μη φλεβοκομβικός



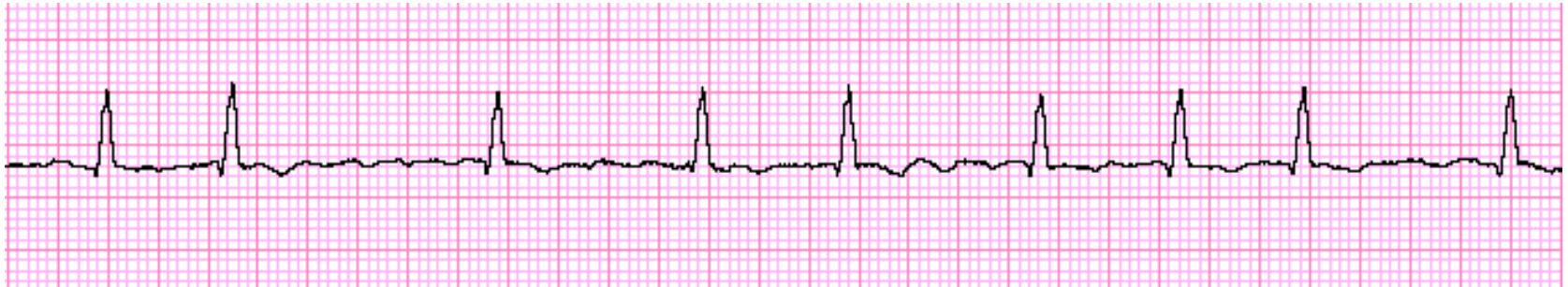Ρυθμός?



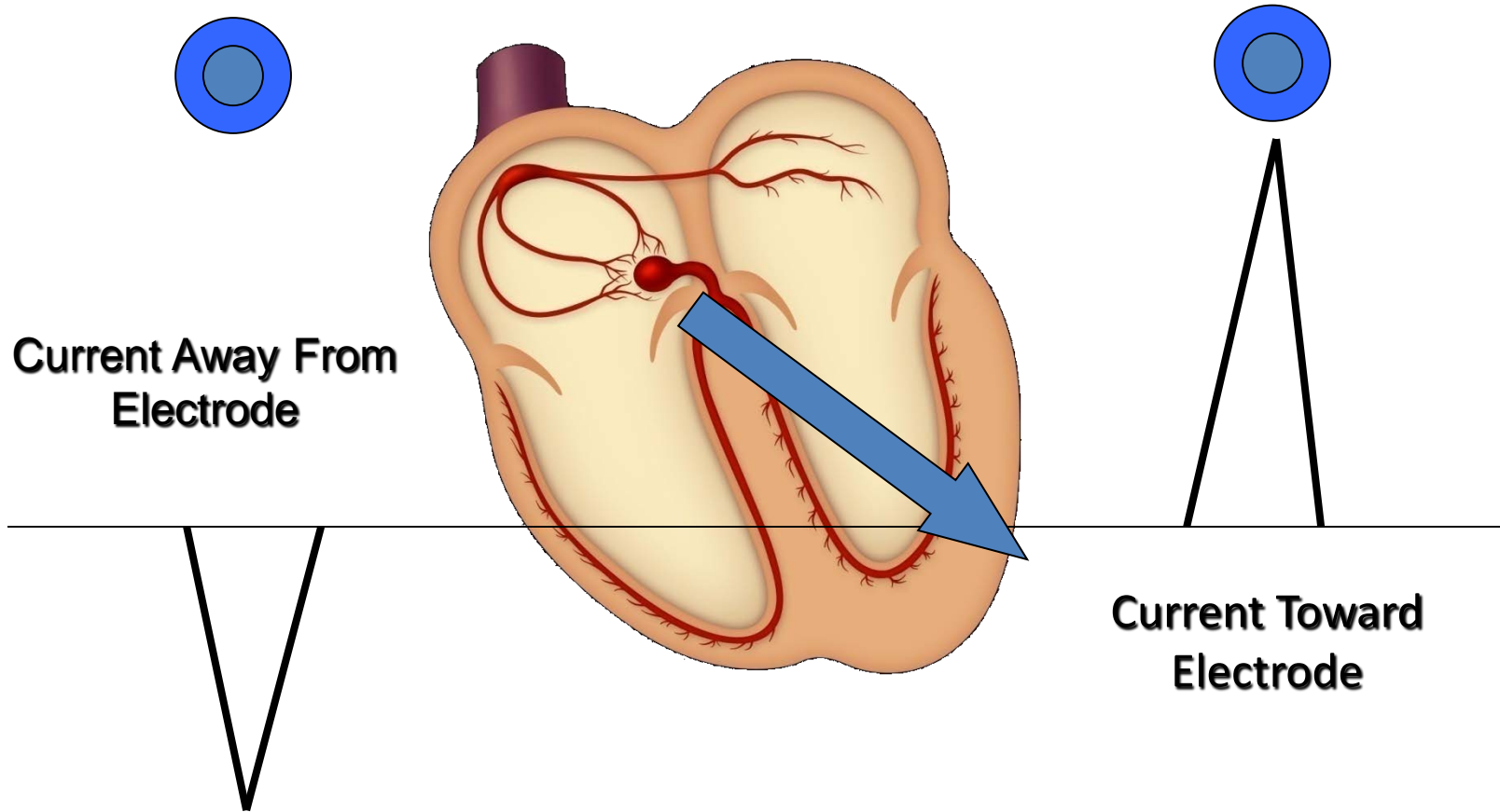
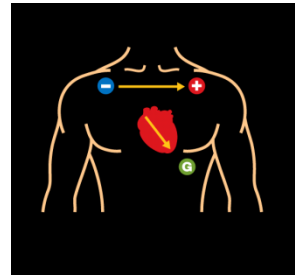
Ρυθμός?



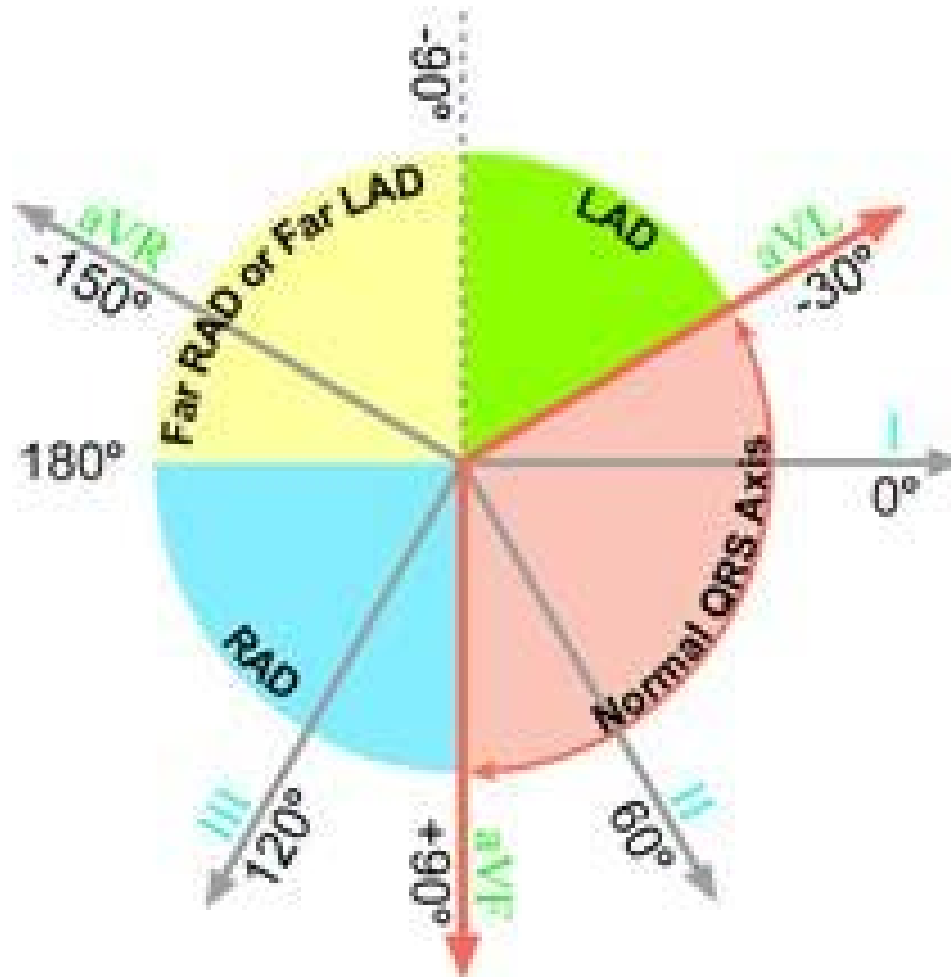
Ρυθμός?



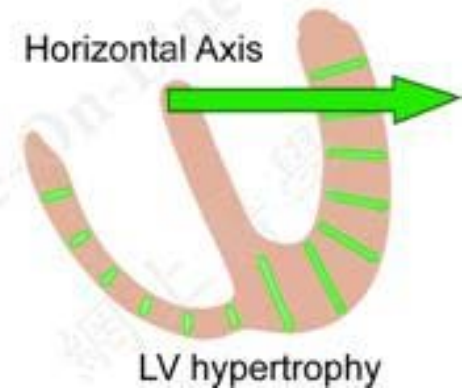
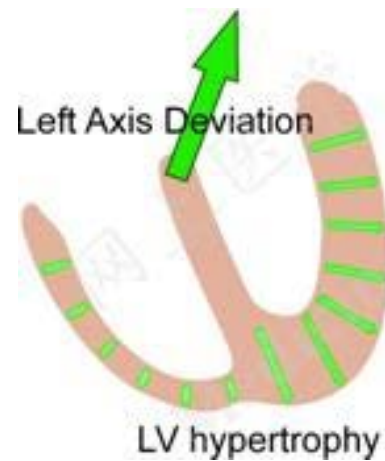
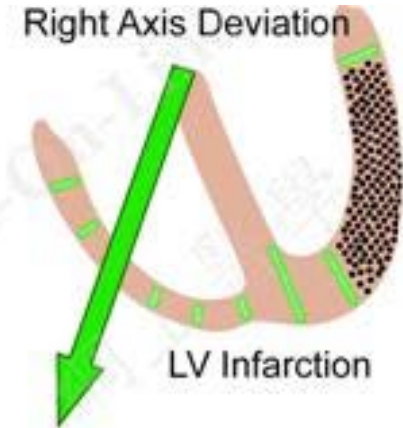
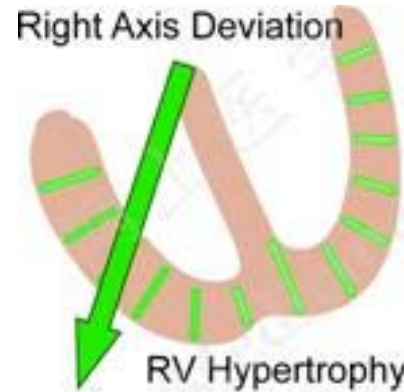
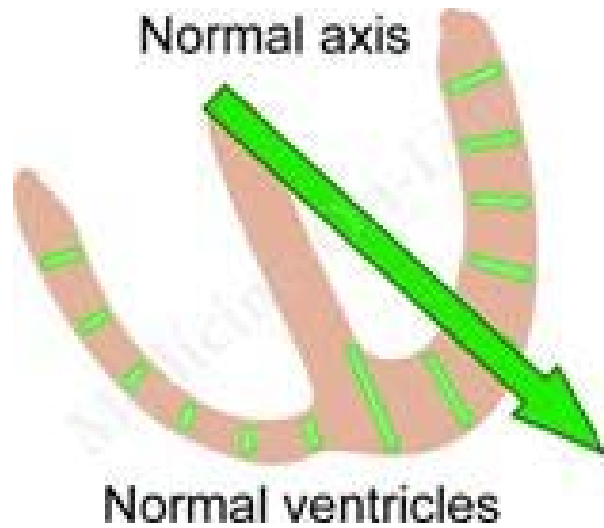
Άξονας QRS



Άξονας QRS



Άξονας QRS



Άξονας QRS

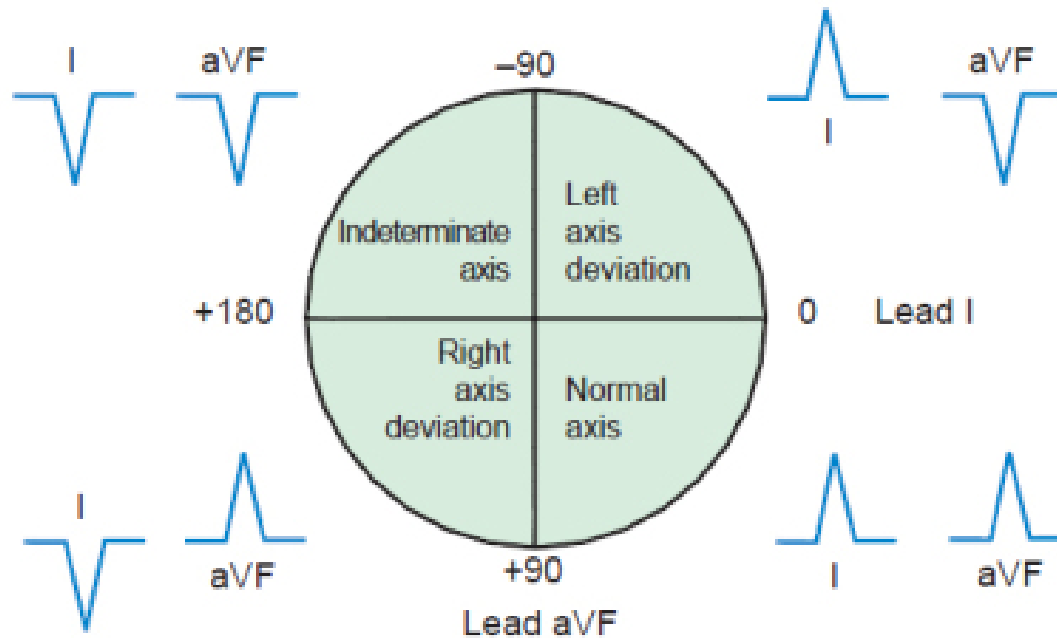
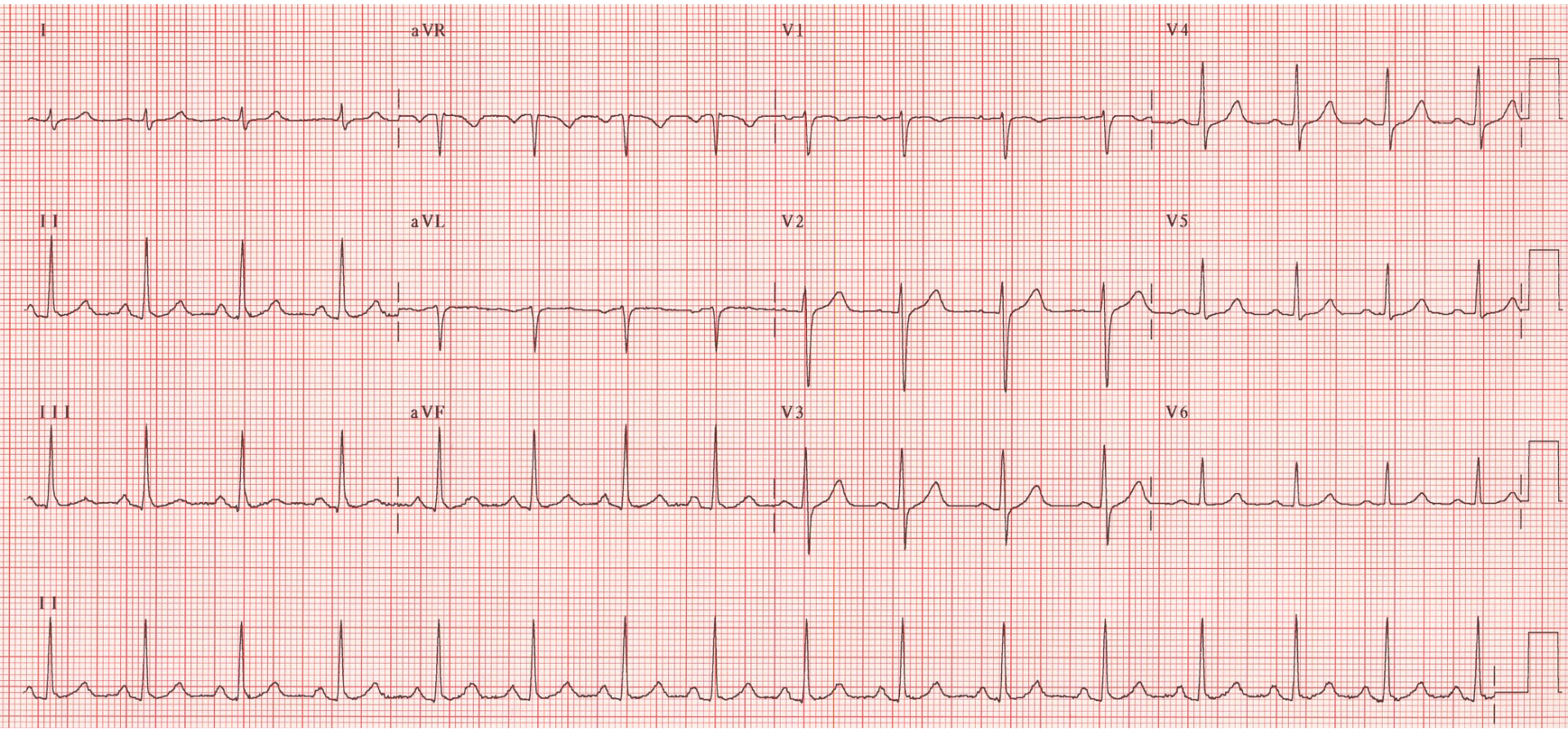


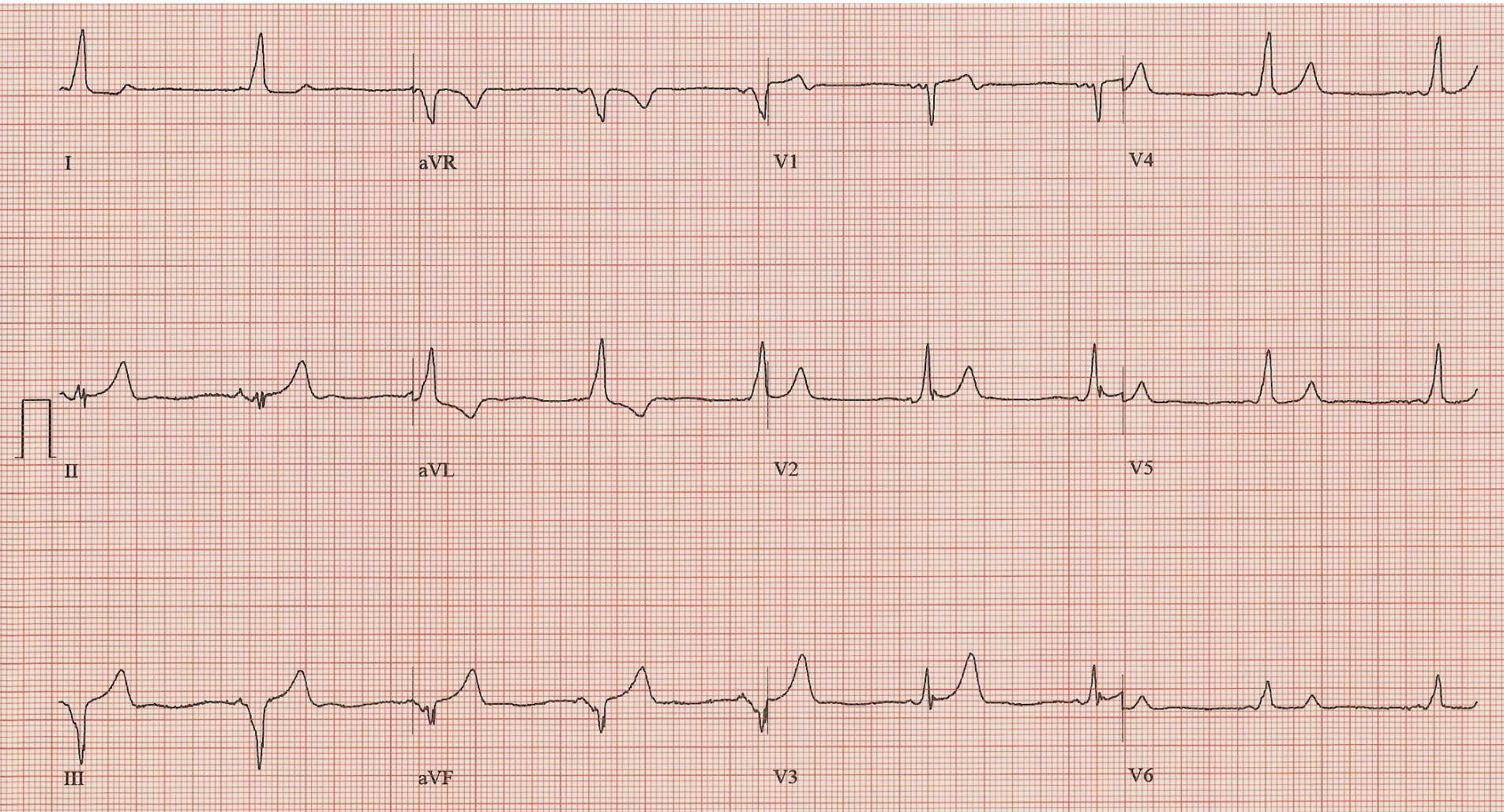
FIGURE 17-33 ▲ Determining electrical axis. To determine the axis of the heart, examine the direction of the QRS complex in leads I and aVF.

<i>Lead I</i>	<i>Lead aVF</i>	<i>Axis</i>
Negative	Negative	Indeterminate axis
Negative	Positive	Right axis deviation
Positive	Negative	Left axis deviation
Positive	Positive	Normal axis

Άξονας QRS?



Άξονας QRS?

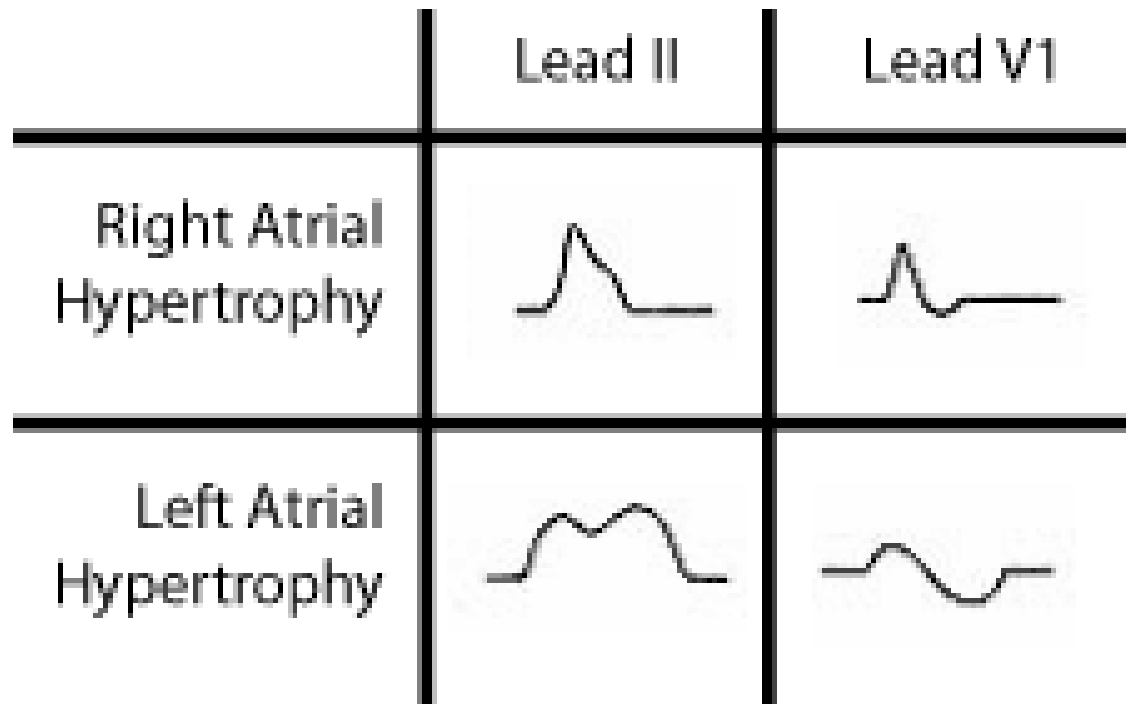


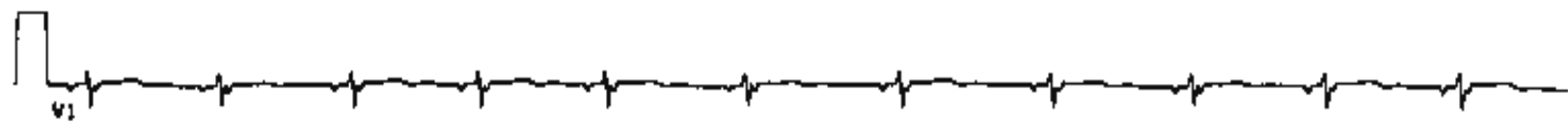

Μορφολογία

Κύματα P

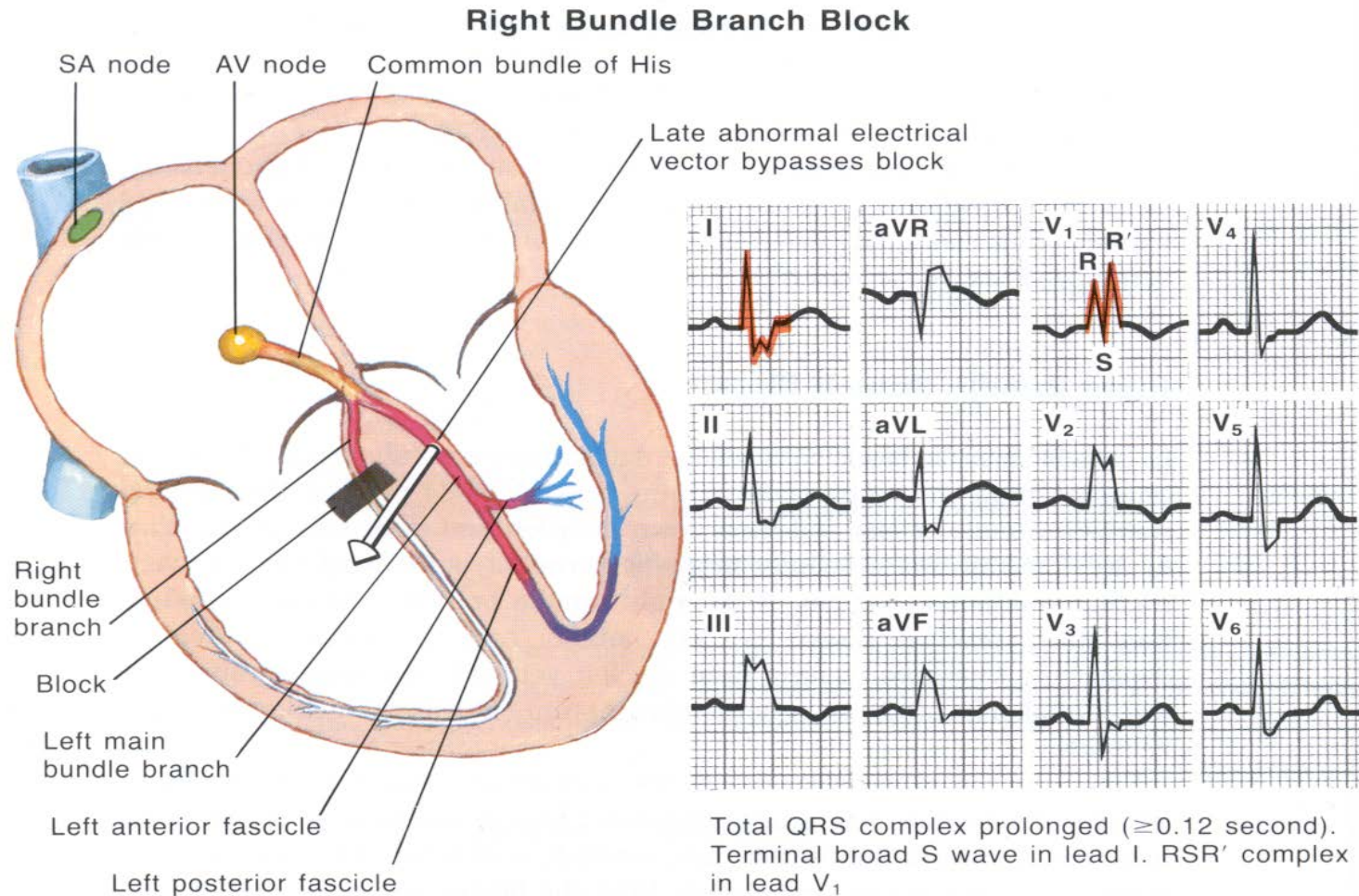
Normal:

- Height < 2.5 mm in lead II
- Width < 0.11 s in lead II





Σκελικοί αποκλεισμοί

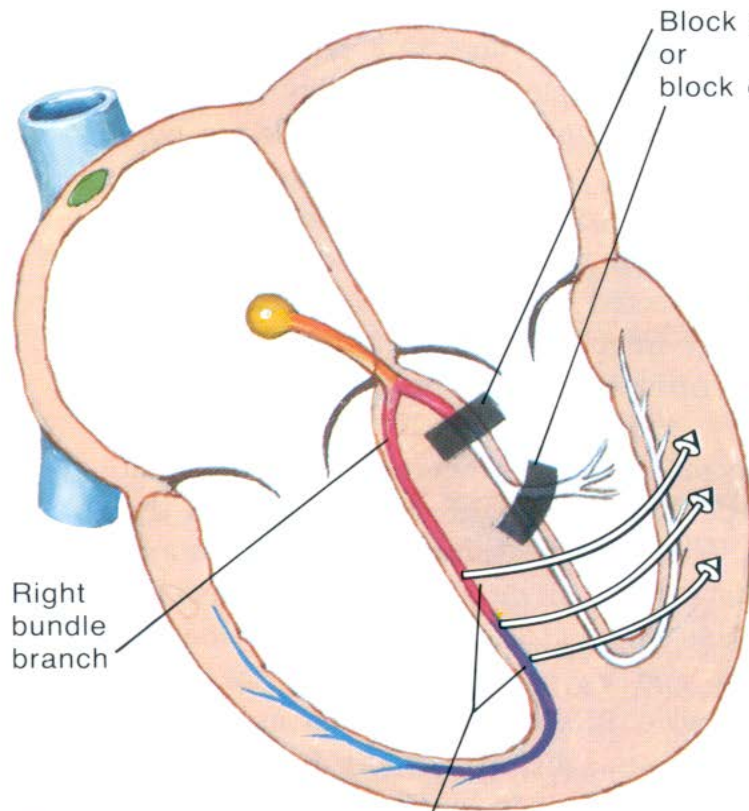


Σκελικοί αποκλεισμοί

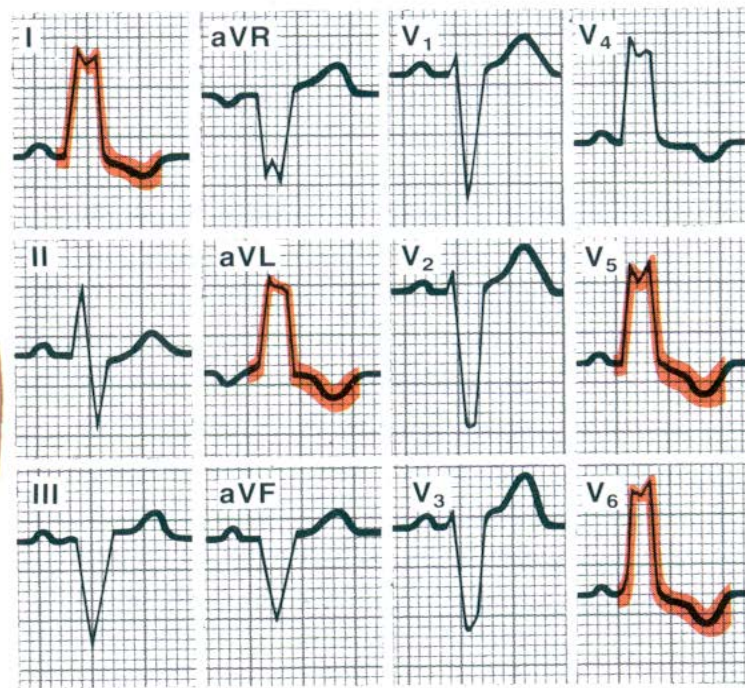
Left Bundle Branch Block

F. Netter M.D.

© Novartis

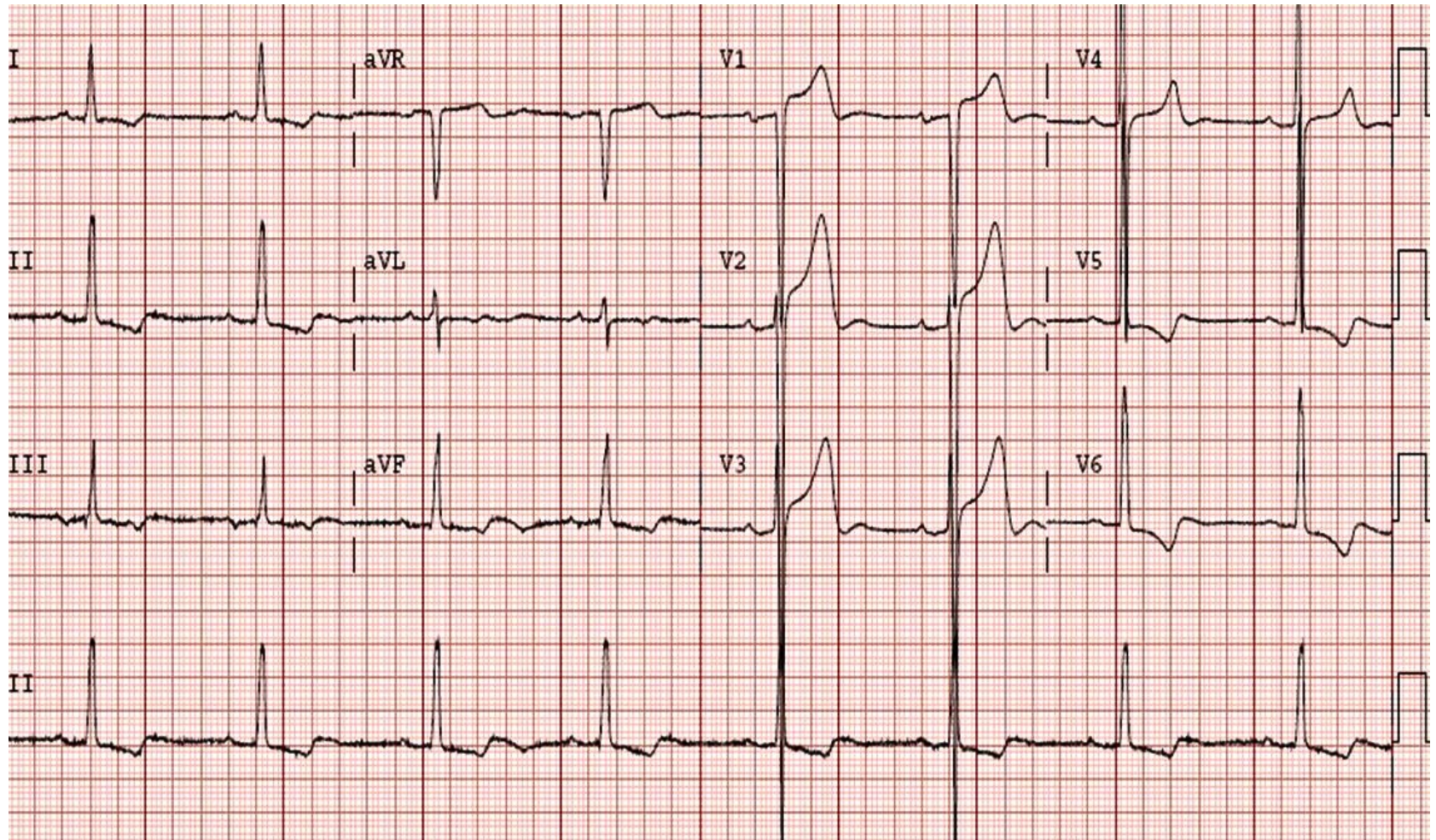


Electrical vector directed toward left ventricle as is normal, but delayed and prolonged

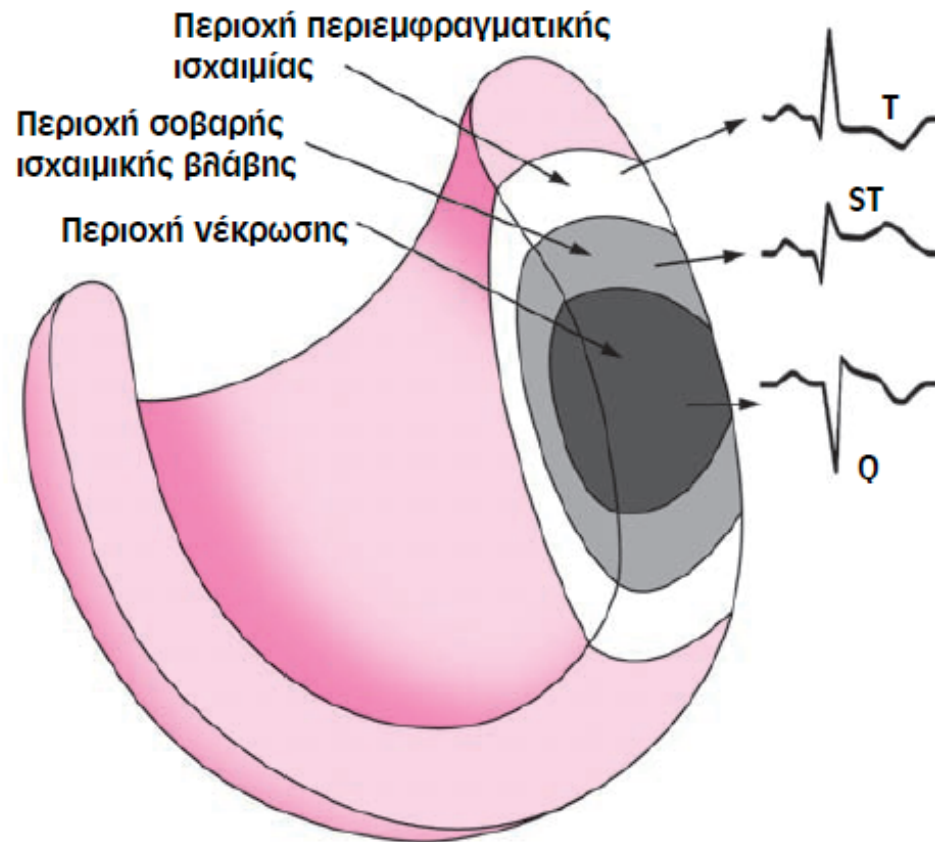


Wide QRS complex (≥ 0.12 second), with ST depressions and inverted T waves, particularly in leads I, aVL, V₅ and V₆

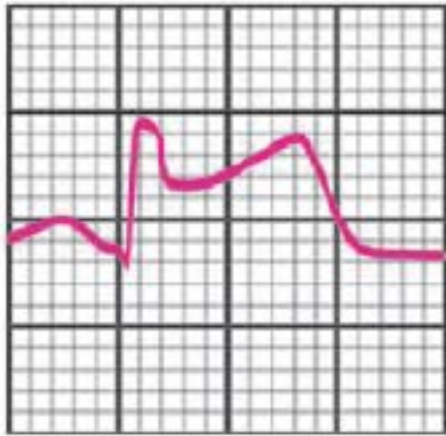
Υπερτροφία ΑΚ



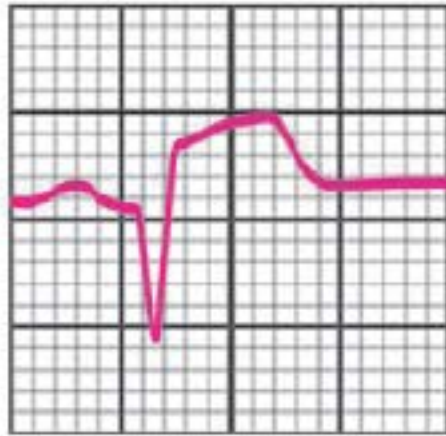
Έμφραγμα μυοκαρδίου



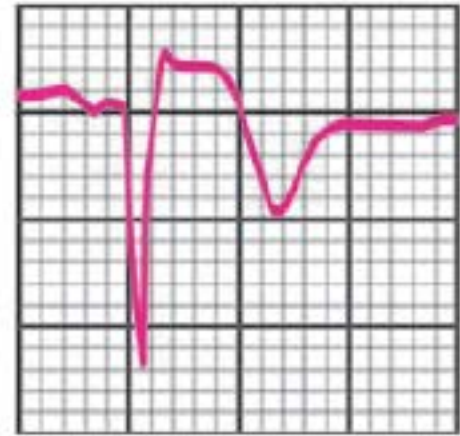
ΗΚΓ εξέλιξη σε ΕΜ



A





B



Γ

ST Elevation



Coved
(convex down)



"Frowny"



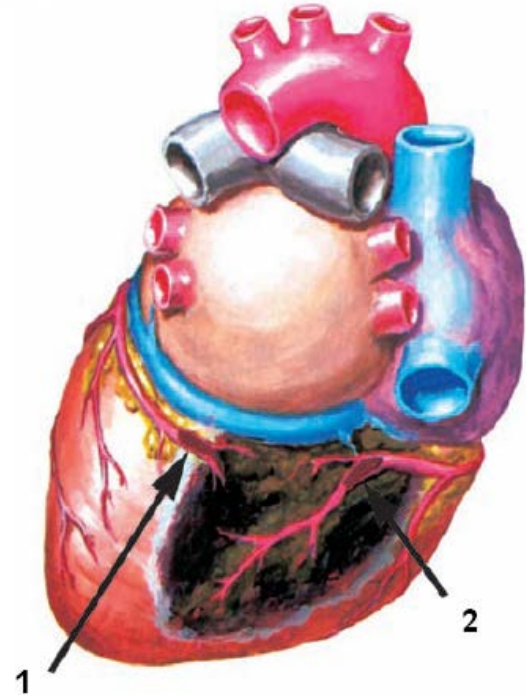
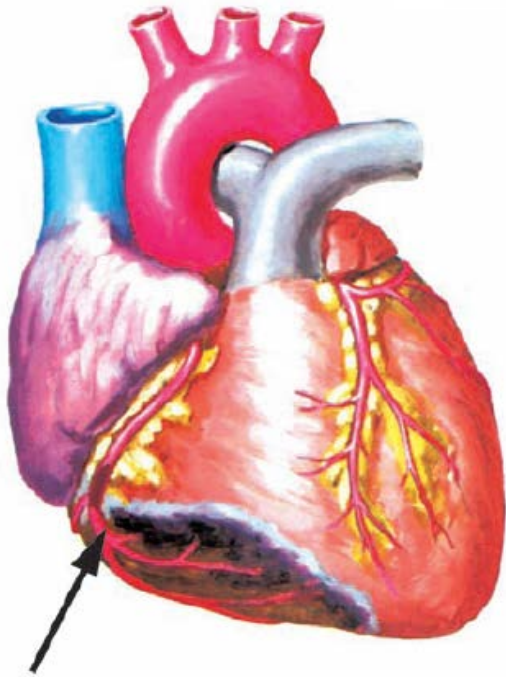
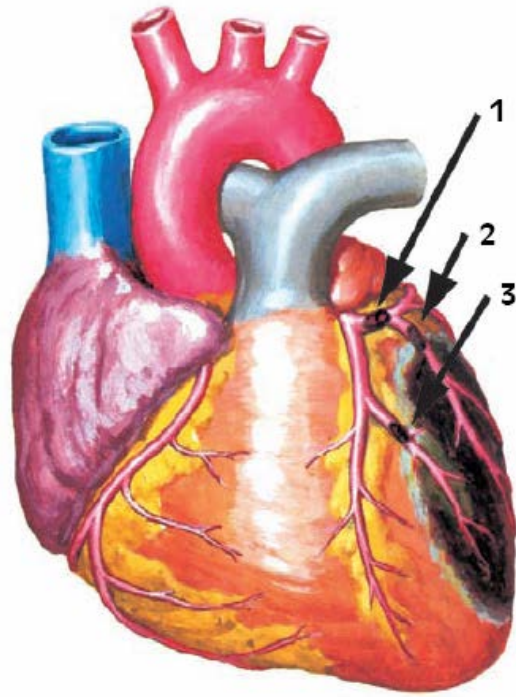
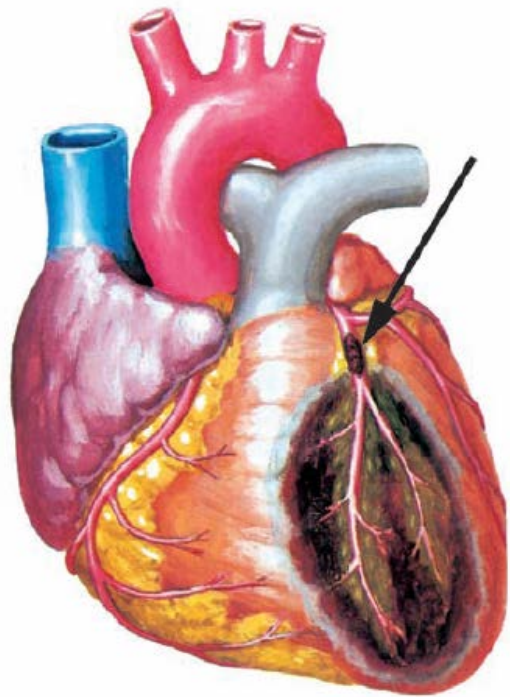
Concave up



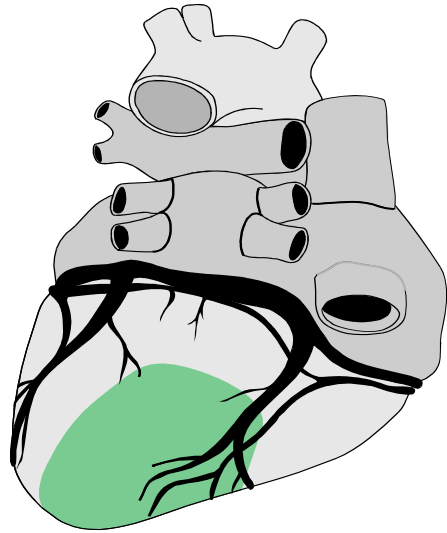
J Point
Notching

"Smiley"

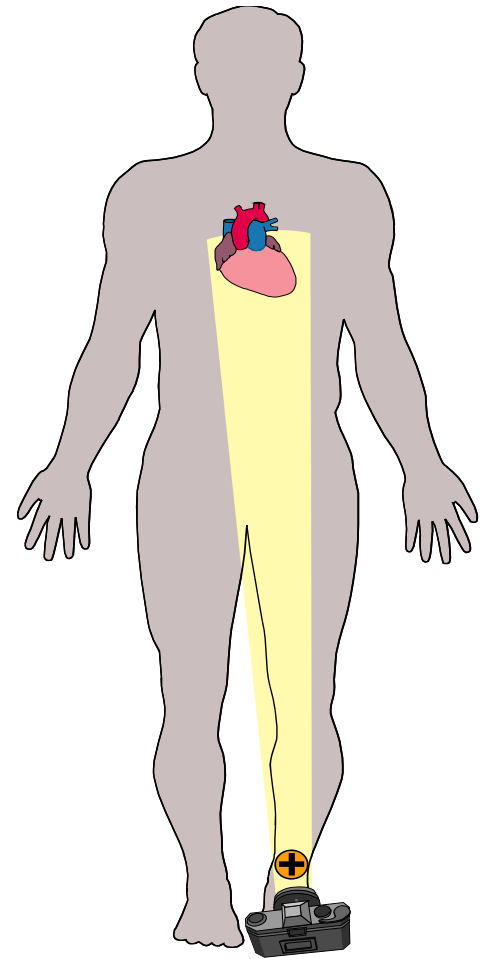


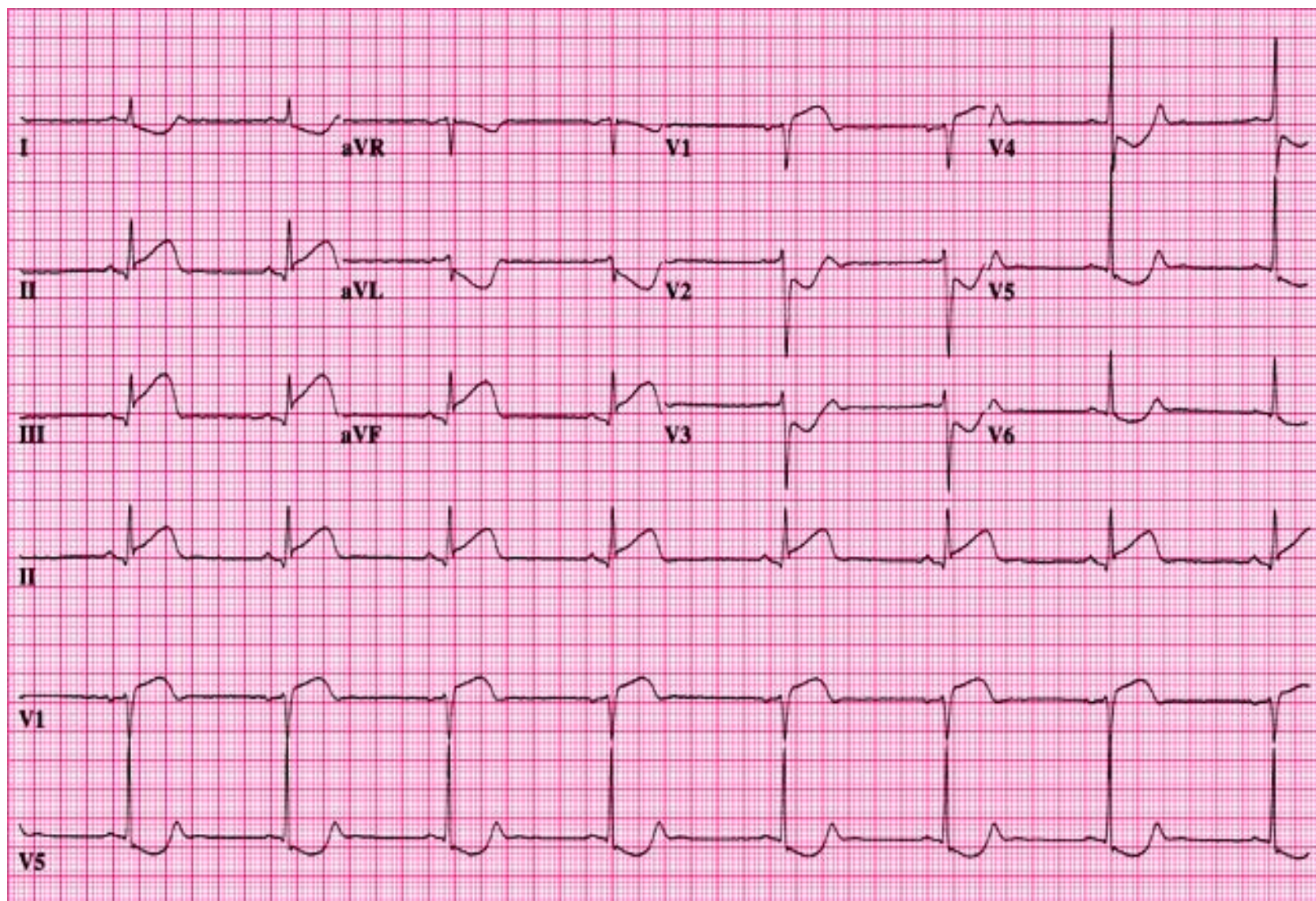


II, III, aVF = Κατώτερο τοίχωμα Δεξιά στεφ. α. (ή περισπωμένη)

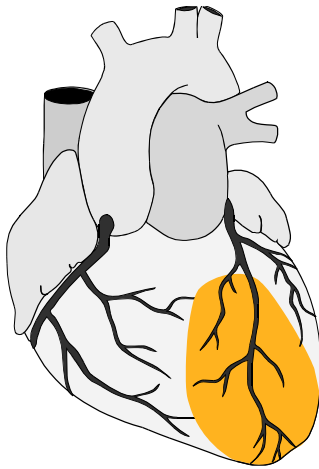


I	aVR	V1	V4
II	aVL	V2	V5
III	aVF	V3	V6

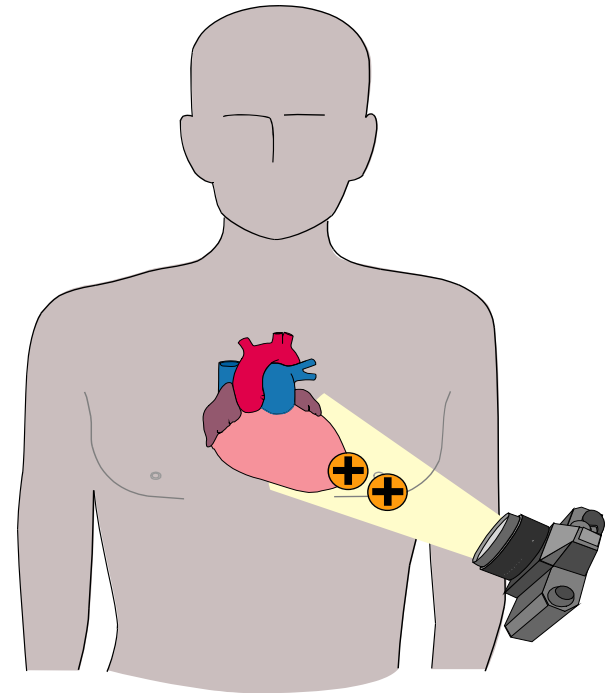


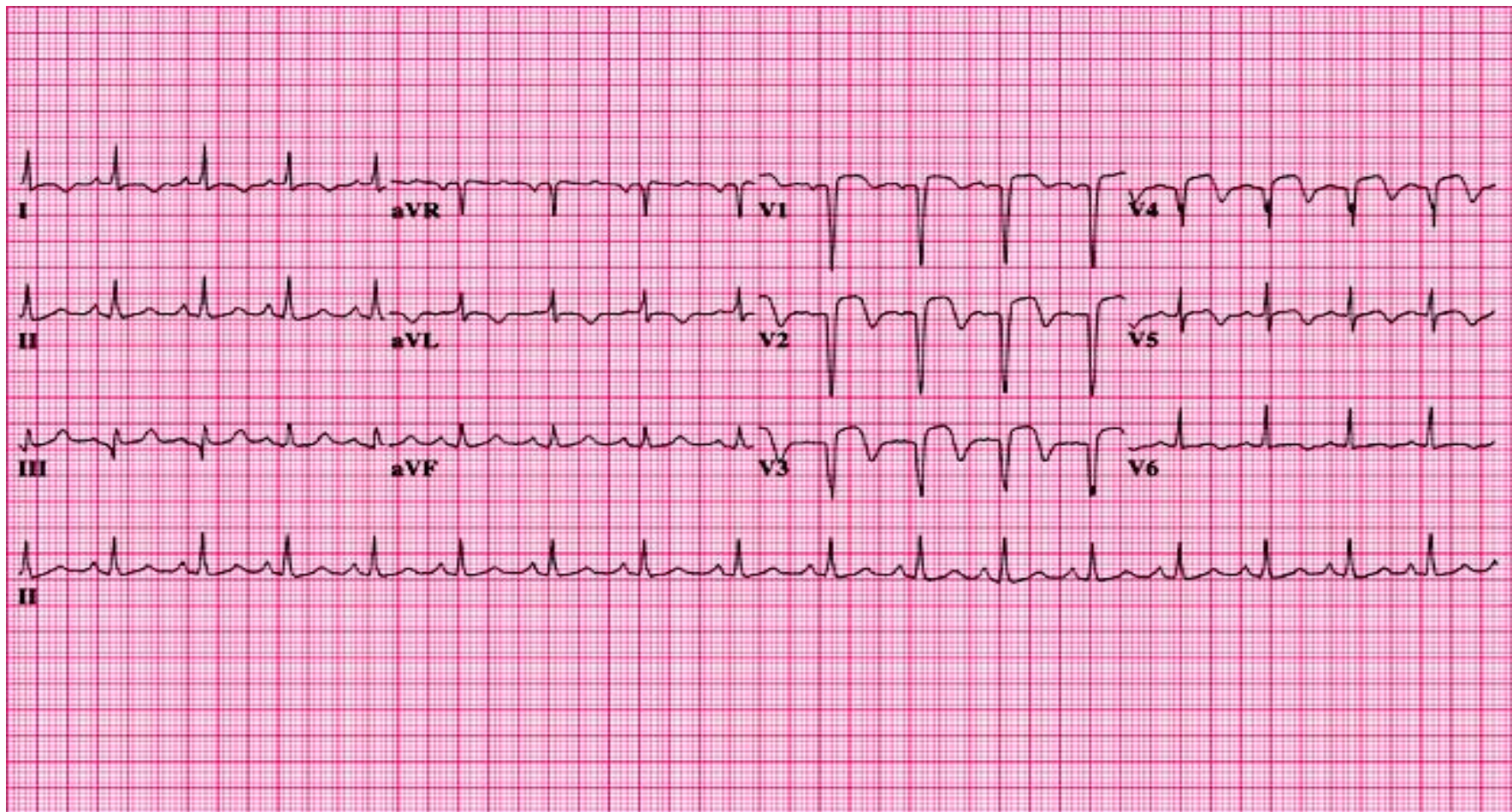


- V1, V2, V3, and V4 = Πρόσθιο τοίχωμα
- Πρόσθιος κατιών



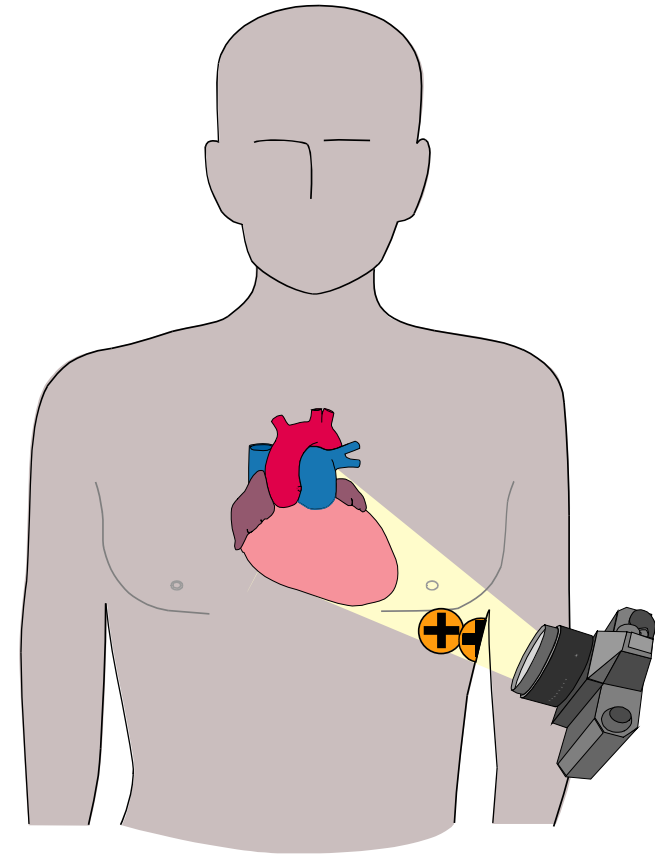
I	aVR	V1	V4
II	aVL	V2	V5
III	aVF	V3	V6



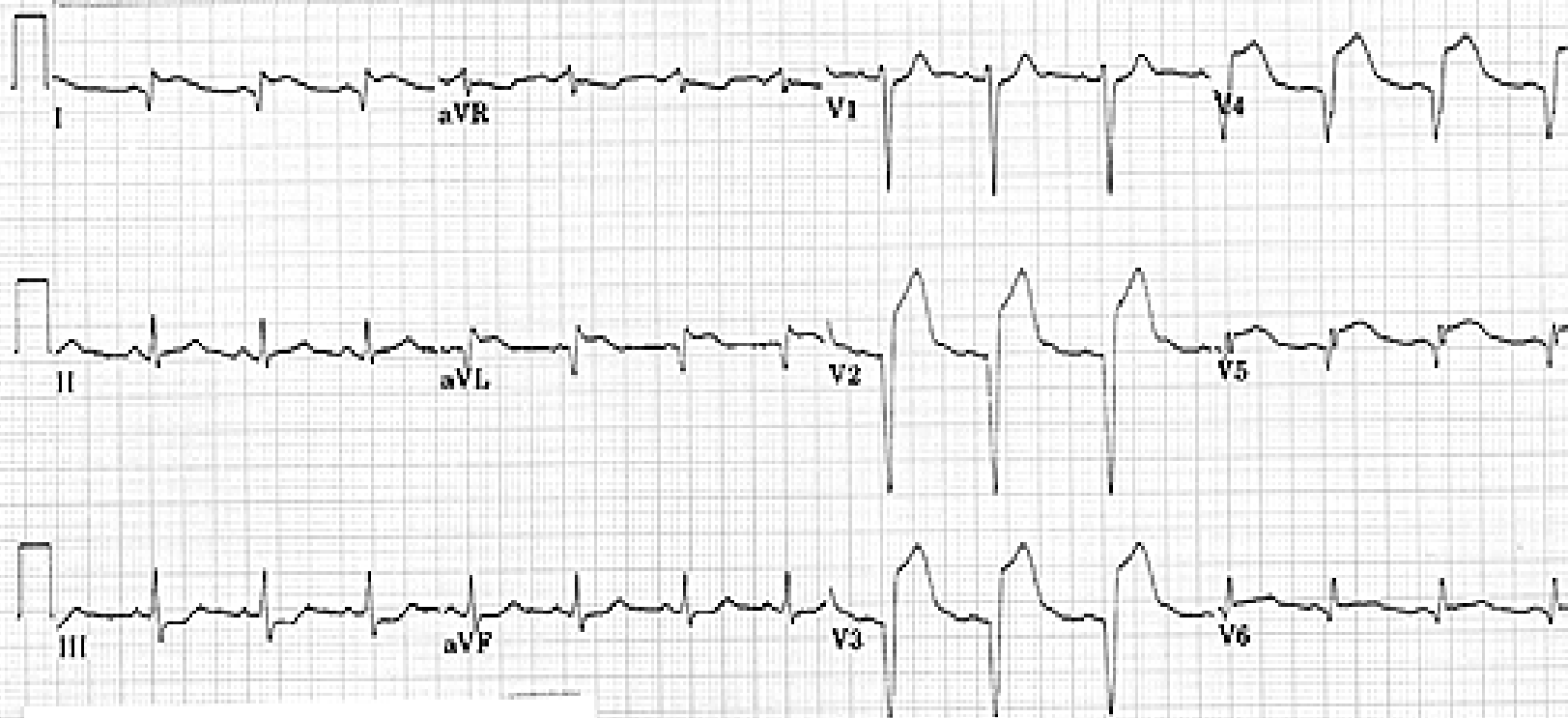


- I, aVL, V5 and V6= Πλάγιο τοίχωμα
- Περισπωμένη

I	aVR	V1	V4
II	aVL	V2	V5
III	aVF	V3	V6



07-MAR-1968 (28 yr)
Male Caucasian



ID: 497609526 18-MAY-1996 13:38

© 1997 Frank G. Yanowitz, M.D.

Διάγνωση?

